

Case Report

Retained intra-abdominal artery forceps – An unusual cause of intestinal strangulation

Anthony Ikemefuna Ugochukwu, Anthony Jude Edeh

Department of Surgery, Enugu State University of Science and Technology Teaching Hospital, Parklane, Enugu, Nigeria.

Citation: Ugochukwu AI, Edeh AJ. Retained intra-abdominal artery forceps - An unusual cause of intestinal strangulation. *North Am J Med Sci* 2011; 3: 339-343.

doi: 10.4297/najms.2011.3339

Abstract

Context: Surgical instruments and materials continue to be retained in the peritoneal cavity despite precautionary measures. Even though uncommon it is also under-reported and carries serious medico-legal consequences. Gauzes and sponges (gossypiboma) are the most commonly retained materials and intra-abdominal retained artery forceps are much rarer but when they do occur lead to chronic abdominal pain and can be a rare cause of intestinal obstruction or strangulation with significant morbidity and mortality. **Case Report:** We present a case of intraabdominal retained artery forceps in a 70-years-old lady who underwent laparotomy with splenectomy for a large spleen in a peripheral hospital. Upon discharge she continued to complain of intermittent abdominal pain of increasing severity. 12 months later she presented to us with an acute (surgical) abdomen requiring another laparotomy. At laparotomy she had strangulated/gangrenous lower jejunal and upper ileal bowel loops, the small bowel mesentery of this area being tightly trapped between the jaws of the retained artery forceps. She had gut resection and enteroanastomosis. Unfortunately she died from continuing sepsis on the second post-operative day. **Conclusion:** Retained instruments in intra-abdominal surgery can cause serious complication and should be treated surgically. High index of suspicion and appropriate investigations like plain abdominal X-ray, abdominal ultrasound and CT and MRI scans should be instituted in patients who develop chronic abdominal symptoms following laparotomy. Preventive measures against retained instruments must follow strict laid down protocols for surgical instruments handling in theatre.

Keywords: Retained intra-abdominal artery forceps, chronic abdominal pain, intestinal strangulation, gossypiboma, significant morbidity and mortality.

Correspondence to: Dr. A.I. Ugochukwu, Department of Surgery, Enugu State University of Science and Technology Teaching Hospital (ESUTTH), Parklane, Enugu, Nigeria. Email: aiugochukwu @ yahoo.com

Introduction

Retained foreign body in the abdominal cavity following surgery is a recurrent problem. However the incidence is grossly underestimated [1] and rarely reported [2]. The rarity of reported cases may be due to medico - legal implications or the surgeon's unwillingness to advertise his errors. The incidence of retained foreign body in literature is 1 per 1000 to 1500 laparotomies [3]. Locally here, the incidence is not documented but it is suspected that the incidence is of a higher magnitude bearing in mind the level of socio-economic development in our environment. With increasing awareness of the public to their rights and privileges, this medico-legal problem will in the near future assume the front burner in our legal field.

Retained foreign body in peritoneal cavity is one of the known but avoidable complications of abdominal surgery. It is more liable to occur when surgery is done in a non-ideal environment and negligence or ignorance on part of the medical personnel. It is the responsibility of the operating surgeon and the theatre staff to ensure that no foreign body is left inside the peritoneal cavity before closure of the abdominal cavity.

Retained foreign bodies are of various types and include sponges/gauzes (Gossypiboma or Texilloma), artery forceps, other metal instruments, surgical needles, surgical drains, and rubber tubes. The surgical sponge/gauze (gossypiboma) constitutes the most frequently

encountered object because of its common usage, small size and amorphous structure [4]. Retained artery forceps are much rarer. Gossypiboma produces two types of reactions, either aseptic fibrinous or exudative reactions. Fibrinous reaction will result in adhesions, pseudotumour effect and intestinal obstruction. Exudative reaction will give rise to abscess formation resulting in peritonitis, fistula formation, tender abdominal mass and gut perforation [5]. In contrast retained artery forceps remain inert and induce their effects through mechanical means giving rise to pressure effects resulting in abdominal pain or direct tissue/viscus injury leading to tissue strangulation or perforation of viscus leading to for example peritonitis or vascular injury resulting in hemorrhage.

The clinical presentation of retained intra-abdominal foreign material may be acute or delayed [6, 7]. Such patient present in the surgical units with increasing abdominal pain, abdominal mass, discharging sinus, intra-abdominal abscesses and acute or sub-acute intestinal obstruction. Whilst many patients will present within days or few weeks after the initial surgery and have a re-laparotomy for retrieval of the foreign body, some patients with intra-abdominal foreign material may go unnoticed for years or even decades. However many of this subset of patients will have chronic abdominal symptoms such as abdominal pain or discomfort. The pre-operative diagnosis is based on high index of suspicion. The pre-operative diagnosis is based on history, clinical examination, plain abdominal radiographs, ultrasound, CT and MRI scans. Yet some patients are diagnosed on operating table during re-laparotomy. Generalized peritonitis, systemic complications and presentation of acute intestinal obstruction are associated with high mortality [8].

We present a case of retained artery forceps causing intestinal strangulation managed in our centre and review the possible factors that led to the retained artery forceps and advice on possible preventive measures.

Case Report

A 70yr old woman (E.N) presented to our accident and emergency unit as a referral from a cottage (peripheral) hospital with a complaint of sudden exacerbation of her chronic abdominal pain, associated now with abdominal distension, vomiting, absolute constipation and fever of four days duration. 12 months prior to presentation she had laparotomy with splenectomy for large spleen suspected to be due to Tropical splenomegaly syndrome (TSS). The surgery was performed by a surgical specialist in a peripheral hospital. Few weeks following the splenectomy, she started complaining of intermittent abdominal pains of worsening severity which culminated in her present complaint. She had paid severe visits to the surgeon who did her splenectomy and had analgesis and antispasmodics prescribed and was always reassured that the abdominal pain will abate with time. No investigations were ordered.

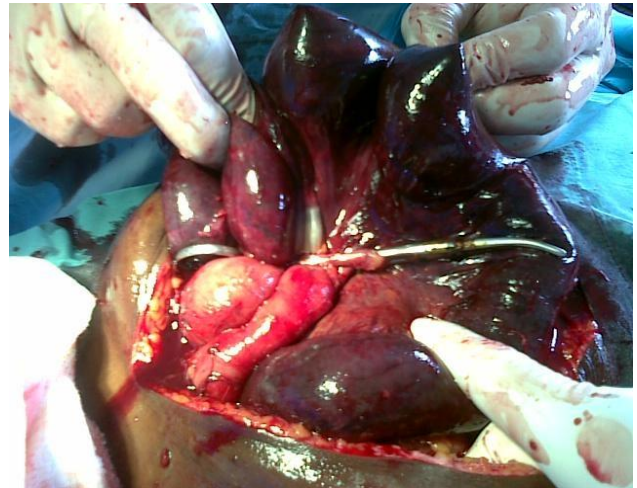


Fig.1 Showing artery forceps trapping the small bowel mesentery. The jaws of the artery is seen trapping the small bowel mesentery with the handle in the right iliac fossa and the tip towards the duodeno-jejunal junction. Loops of gangrenous small bowel are held up by an assistant above the artery forceps.

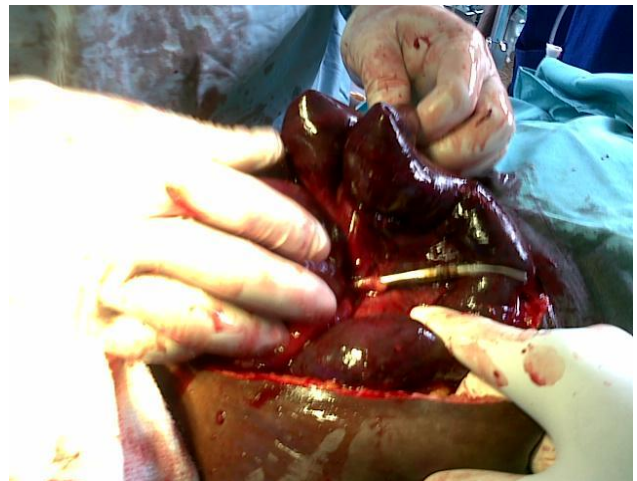


Fig. 2 Showing artery forceps across small bowel mesentery. The lower jaw of the artery forceps crossing the small bowel mesentery. Notice loops of gangrenous small bowel held up by the surgeon.

Examination revealed an acutely ill looking, toxic, pale and dehydrated elderly lady in respiratory distress, blood pressure of 80/50mmHg, pulse rate of 120/min and low volume, respiratory rate 40/min and a temperature of 38.4°C. Abdominal examination revealed a distended abdomen with a midline scar from the epigastrium to the symphysis pubis. No visible peristalsis but generalized tenderness, guarding and rebound. Bowel sounds were infrequent and rectum was empty but warm on digital rectal examination. Chest examination revealed severe dyspnoea and bilateral basal rales. A clinical diagnosis of generalized peritonitis complicating intestinal obstruction, septic shock and acute respiratory distress syndrome (ARDS) were made. Resuscitation was started with IV saline infusions, IV ceftriazone (third generation cephalosporins), IV metronidazole, nasogastric tube suction, and urethral catheterization (for urinary output monitoring). She had two pints of blood transfused pre-operatively. Intermittent oxygen therapy was also

administered for low Pao₂. Investigation showed packed cell volume of 22%, urea of 11.5 mmol/L, normal electrolytes and urinalysis. Plain chest and abdominal (erect and supine) X-ray were ordered but were not done because the poor state of patient prevented her movement to the X-ray suit. However, she had abdominal pelvic ultrasound, which showed dilated bowel loops and large volume of intraperitoneal fluid. The need for adequate resuscitation delayed surgery for about 12 hours. At laparotomy 3 liters of flacculent smelling hemorrhagic peritoneal fluid was found. The jaws of a large size artery forceps were seen tightly trapping the small bowel mesentery from its distal extremity to half way up towards the duodeno-jejunal flexure with the tips of forceps pointing toward the duodeno-jejunal junction and the handle located in the right iliac fossa. This led to ischemic gangrene of about 65cm of the small bowel involving the distal third of jejunum and upper two thirds of the ileum. There were no pulsations on the ileal and jejunal arteries distal to the trapping artery forceps (Figures 1 and 2).

The gangrenous loops of bowel were resected and primary enteroanastomosis fashioned. Liberal peritoneal lavage with normal saline was carried out. Abdominal wound was closed with drainage tube in situ. The patient had a turbulent post-operative phase and was managed in our Critical Care Unit (CCU). However, 12-hours post-operatively she died most probably from continuing sepsis. The relatives declined post-mortem examinations.

Discussion

Despite the awareness of the dangers of and the precautionary measures aimed to prevent them retained instruments continue to occur especially in the peritoneal cavity. Retained foreign body in a patient after surgery is an uncommon but dangerous error and it is grossly underestimated [1]. However many of the cases of retained foreign body are not reported [2]. The rarity of the reported cases may be due to medico-legal reasons or the surgeon's unwillingness to advertise his errors or complacency of his colleagues in exposing him, in order not to jeopardize his professional life or to protect him from medico-legal issues that might ensue. In literature the incidence of retained foreign body is quoted as 1: per 1000 to 1500 laparotomies [3]. Here in our environment, the incidence is unknown because no local data exist. However, given the level of our socio-economic and manpower development in health care, it is strongly suggested that the incidence in our environment is much higher than quoted in the literature. In our environment people are gradually beginning to appreciate their rights and privileges and the authors suspect that in the years ahead the medico-legal issues associated with retained foreign bodies following surgery will be in the front burner.

The most common retained foreign body is abdominal sponge (gossypiboma) because of its common usage and amorphous structure [4]. Whilst gossypiboma elicits two types of responses—aseptic fibrinous and exudative

reaction [5], retained metals like artery forceps are inert. The clinical presentation of retained materials may be acute or delayed [6, 7]. While many retained foreign materials are identified and retrieved immediately or shortly after surgery some may remain unidentified for years or decades [8, 9]. Intra-abdominal retained artery forceps are much rarer. Qamar [10], Champ [11] and Nasir [12] found one case each of retained artery forceps in their reviews of eleven, fifteen and ten cases respectively of retained foreign bodies in the abdominal cavity. Retained metal like artery forceps are inert and exert their effect through mechanical means like direct tissue damage causing ischemia, pressure effect giving rise to pain and discomfort [12], or forming an axis on which loops of bowel entangle leading to intestinal obstruction and strangulation or a loop of bowel going through the 'eye' of the retained artery forceps and getting trapped leading to strangulation [13]. They may also penetrate hollow organs for example gut leading to peritonitis or blood vessels leading to hemorrhage. In our case, the artery forceps through its clinching jaws caused ischemia (direct tissue damage) leading to strangulation and gangrene of small bowel loops.

Metal retained materials are said to usually give rise to acute symptoms months or years after the operation. Fadiora [13] and Godara [14] noted in their cases that their patients presented with acute symptoms after 2^{1/2} years and 2 years respectively of their initial surgical operations. Our patient presented 12 months after surgery. However, in all cases of retained artery forceps in the abdominal cavity cited in literature, the patients had chronic recurrent abdominal pains or colic's months or years before onset of acute (surgical) abdomen [13, 14]. Our patient had months of recurrent abdominal pain before the acute (surgical) abdomen.

In the literature most of the reported cases of retained artery forceps were operated in the peripheral hospitals [10, 15]. Our patient had surgery at which retained forceps occurred in a peripheral hospital. In most of the peripheral hospitals in developing countries like ours, qualified medical personnel are few and auxiliaries most times inexperienced are called in to help in the operating theatre. Therefore, any surgeon working in a peripheral hospital who decides to undertake any major surgery must assume full responsibility of preventing retained instruments and must involve his assistants and auxiliaries in his anxiety. Also in most of hospital theatres, adequate equipment and facilities are lacking, improvisation is key to many procedures and with this disasters are common including retained instruments.

A recent retrospective study found that retained instruments and sponges following an operation occurred more frequently in emergency surgery, especially where there was an unplanned change in the operative procedure, in patients with high mean body mass index [2, 16]. Others noted that huge intra-abdominal tumors or masses and severe intra-operative hemorrhage are risk factors for

retained instrument [17]. Our patient had laparotomy for a large spleen extending well below the umbilicus. Other risk factors are fatigued surgical team, staff changes during operation, and failure to account for all sponges and instruments, leaving closure of abdominal wound to a junior, sometimes inexperienced [18].

The surgeon remains the head of the surgical team and must assume full responsibility for what he puts on the patient even though the general custom and practice is to delegate the task of counting sponges and other instruments to the nurses. The responsibility of the surgeon is even more important and pertinent in peripheral hospitals where trained peri-operative nurses are very scarce, and the surgeon uses nurse auxiliaries- who are most times untrained. The surgeon must ensure his assistants understand his anxiety on retained foreign body.

The following precautionary measures are likely to reduce the incidence of retained instruments:

- *Double sponge/instrument count, before and after surgery.*
- *Number of sponges and instruments are clearly written in the theatre black board provided for this purpose.*
- *All large sponges (abdominal mops) applied into the peritoneal cavity should have long ribbon attached to the sponge and the ribbon must remain outside the main laparotomy wound.*
- *Avoid use of small gauze inside the abdominal cavity; only use large abdominal mops (sponges with long ribbon attached).*
- *The surgeon must develop the attitude of thorough ‘final sweep’ (visual and manual) of the abdominal cavity to ensure no instruments or sponges are left inside the abdominal cavity before commencement of the wound closure.*
- *Uses of sponges with radio-opaque markers are advised but these materials are not easily available to us here. Also advocated is radiographic screening of high risk operative procedures before patients leave the operating room, even when counts are documented as correct. This is ideal but not feasible in a developing world setting.*

In our environment and especially for surgeon operating in peripheral hospitals where the incidence of retained materials are much more commoner, the surgeon must assume full responsibility. He must rely on his own ability of making absolutely sure that all the procedures adopted for prevention of retained materials in wounds are carried

out. No reliance should be placed on other theatre staffing since the short comings of these staff are obvious. These measures are even more pertinent when operating on a high risk patient for retained instruments.

Exploratory laparotomy remains the mainstay of treatment to retrieve retained intra-abdominal foreign material. Other methods include laparoscopic removal and ultrasound assisted retrieval [19, 20] Rarely small sponges and gauzes can discharge via the rectum spontaneously. It is advocated that patient who present with chronic abdominal discomfort, pain or colic's, after laparotomy should be subjected to thorough history taking, clinical examination and should have plain abdominal X-rays, supplemented by ultrasound scan, and perhaps CT scan and possibly MRI scan. Adoption of this procedure will lead to early diagnosis of retained foreign materials, before the patient develops acute (surgical) abdomen. Our case illustrated the need for earlier diagnosis and management.

Conclusion

A case of retained large artery forceps following splenectomy for large spleen is presented. Retained foreign body is avoidable and could be a costly error as our case illustrates. The need for the surgeon (especially the rural surgeon) who operates in the abdominal cavity to assume the ‘‘Captain of ship doctrine’’ cannot be over emphasized. All preventive protocols must be observed under the strict guidance and full responsibility of the surgeon especially the rural surgeon. The need to investigate properly a patient who complains of chronic abdominal symptoms following laparotomy should be encouraged as this will aid in making early diagnosis of retained foreign material before more serious complications of intestinal obstruction or strangulation, or peritonitis, intra-abdominal abscesses or entero-cutaneous fistula supervenes.

References

1. Grag M, Aggarawal AD. A review of medicolegal consequences of gossypiboma. J Indian Acad Forensic Med 2010; 32(4): 358-361.
2. Gawande AA, Student DM, Orar EJ, Brennan TA, Zinner MJ. Risk factors for retained instruments and sponges after surgery. N Engl J Med 2003; 348 (3): 229-235.
3. Rappaport W, Hayness K. The retained surgical sponge following intra abdominal surgery: A continuing problem. Arch Surg 1990;125:405-407.
4. Lincourt AE, Harrell A, Cristiano J, Sechrist C, Kercher K, Heniford BT. Retained foreign bodies after surgery. J Surg 2007;138: 170-174.
5. Gupta NM, Chandhary A, Nada V, Malik AK. Retained surgical sponge after laparotomy, unusual presentation. Dis colon rectum 1985; 28: 451-453.
6. Gonzalez-Ojeda A, Rodriguez-Alcantar DA, Arenas-Marquez H, et al. Retained foreign bodies following intraabdominal surgery. Hepatogastroenterology 1999; 46: 808-812.

7. Wang CF, Cipolla J, Seamon MJ, Lindsey DE, Stawicki SP. Gastro-intestinal complications related to retained surgical foreign bodies (RSFB): a concise review. *OPUS 12 Scientist* 2009; 3 : 11-18.
8. Roumen RM, Weerdenburg HP. MRI features of a 24-year old gossypiboma. A case report. *Acta Radiol* 1988; 39 : 176-178.
9. Hadrami J, Rojas M, deFenoyl O, et al. Pulmonary textiloma reviewed by haemoptysis 12 years after thoracotomy. *Rev Med Intern* 1998;19:826-829.
10. Qamar SA, Jamil M, Idrees T, Sobia H. Retained foreign bodies; After intraabdominal surgery - a continuing problem. *Professional Med J* 2010; 17(2): 218-222.
11. Champa S, Tariq WK, Abdul S. Retained surgical foreign bodies: Can these be prevented? *Pak J Med Sci* 2010; 26(1): 15-19.
12. Nasir GAA. Missed instruments and surgical sponge (gauze and pack) *Internet J Surg* 2009; 20:(1): 3-9.
13. Fadiora SO, Olatoke SA, Bello To, Adeoti ML, Agodirin SO. Intestinal obstruction from forgotten artery forceps, a case report. *West Afr J Med* 2004; 23 (4): 330-331.
14. Godara R, Sen J, Singh R, Ahuja V, Dhingra A, Godara S. Retained forceps: An unusual cause of intestinal obstruction. *Asian J Surg* 2008; 31(3): 148-150.
15. Khan MI, Muneer M, Ahmad G, et al. Sinus formation due to foreign bodies. *The professionals*. 2004;11:11-15.
16. Wang CF, Stawicki SP, Cook CH, et al. proceedings of the Central Surgical Association Annual Meeting, Sarasota. Florida (March 7, 2009)
17. Bani-Hani KE, Gharuibeh KA, Yagahan RJ. Retained surgical sponge (gossypiboma). *Asian J Surg* 2005; 28: 109-115.
18. Murad M, Bari V. Gossypiboma - a case report. *Pak J Med Sci* 2003;19:138-140.
19. Jain M, Jain R, Sawhney S. Gossypiboma: ultrasound guided removal. *J Clin Ultrasound* 1995;23: 321-323.
20. Uranus S, Schauer C, Pfeifer J, Dagdoglu A. Laparoscopic removal of large laparotomy pad forgotten in site. *Surg Laparosc Endosc* 1995; 5: 77-79.