

Positive HIV Screening Test in a Patient with Rapidly Progressive Interstitial Lung Disease: A Case Report

Xue Chen^{1,*}, Miaotian Cai^{2,*}, Yingmin Ma², Tong Zhang^{1,*}, Yulin Zhang^{2,3,*}

¹Beijing Key Laboratory for HIV/AIDS Research, Clinical and Research Center for Infectious Diseases, Beijing Institute of Hepatology, Beijing Youan Hospital, Capital Medical University, Beijing, People's Republic of China; ²Department of Respiratory and Critical Care Medicine, Beijing Institute of Hepatology, Beijing Youan Hospital, Capital Medical University, Beijing, People's Republic of China; ³Beijing Research Center for Respiratory Infectious Diseases, Beijing, People's Republic of China

*These authors contributed equally to this work

Correspondence: Yulin Zhang, Department of Respiratory and Critical Care Medicine, Beijing Institute of Hepatology, Beijing Youan Hospital, Capital Medical University, Beijing, People's Republic of China, Email yulinzhang@ccmu.edu.cn; Tong Zhang, Beijing Key Laboratory for HIV/AIDS Research, Clinical and Research Center for Infectious Diseases, Beijing Institute of Hepatology, Beijing Youan Hospital, Capital Medical University, Beijing, 100069, People's Republic of China, Email zt_doc@ccmu.edu.cn

Objective: Interstitial lung diseases (ILDs) comprise a heterogeneous group of disorders characterized by inflammation and fibrosis of the pulmonary interstitium, posing significant challenges in identifying their underlying causes. Pneumocystis pneumonia (PCP) is the leading cause of ILD in people living with HIV (PLWH). In individuals with connective tissue diseases, ILD is a frequent complication with significant morbidity and mortality.

Methods: A case is presented that details the intricate diagnostic process of rapidly progressive interstitial lung disease (RP-ILD).

Results: The patient initially presented with clinical features consistent with ILD, including progressive respiratory symptoms and radiological findings typical of pulmonary inflammation. Coupled with a positive HIV screening result, these findings led to an initial misdiagnosis of PCP, a common opportunistic infection in PLWH. However, despite standard anti-PCP treatment, the patient's condition did not improve, prompting further diagnostic evaluations. Subsequent investigations revealed the presence of serum anti-melanoma differentiation-associated gene 5 (anti-MDA5) antibody, a biomarker strongly associated with rapidly progressive ILD in clinically amyopathic dermatomyositis (CADM).

Conclusion: This case report offers a novel perspective on the diagnostic process of ILD, particularly emphasizing the importance of distinguishing false-positive antibodies caused by autoimmune diseases in the context of positive HIV screening tests, thereby improving the accuracy of RP-ILD diagnosis and mitigating the mortality burden associated with this condition.

Keywords: interstitial lung disease, HIV false positive, Anti-MDA5 antibody, clinically amyopathic dermatomyositis, autoimmune diseases

Introduction

Interstitial lung diseases (ILDs) refer to a group of diffuse lung parenchymal diseases with high morbidity and mortality that can occur in various types of connective tissue diseases, including rheumatoid arthritis, systemic lupus erythematosus, polymyositis or dermatomyositis (DM), and mixed connective tissue disease.^{1,2} Clinical amyopathic dermatomyositis (CADM), a distinct subclass of DM, is characterized by typical skin manifestations without muscle weakness, along with usually normal creatine kinase (CK) levels and electromyographic findings.³ Patients with CADM are sometimes affected by rapidly progressive ILD (RP-ILD), which can be fatal, is resistant to immunosuppressive treatments, and carries a high mortality rate.^{4,5} In addition, 60–70% of patients with CADM have anti-melanoma differentiation-related gene 5 (anti-MDA5) antibodies,⁶ which have been reported to be associated with severe, progressive, and often fatal ILD.

We herein describe a patient with anti-MDA5 antibody-associated CADM complicated by RP-ILD, who was initially found to have a false-positive HIV screening result. It is easy for this condition to be misdiagnosed as PCP, which is the most common opportunistic infection in people living with HIV (PLWH). This case is reviewed to discuss the diagnostic and therapeutic process of CADM-associated ILD in the context of a false-positive HIV screening result.

Case Report

A 47-year-old man developed recurrent fever and progressive dyspnea in February. Outpatient tests revealed no abnormalities in routine blood work or respiratory pathogen antibody testing. He was initially diagnosed with pneumonia based on chest CT findings 10 days after the onset of illness, and was treated with empiric antibiotics for a week without improvement. He was then hospitalized for further treatment. After hospitalization, laboratory tests revealed elevated C-reactive protein, procalcitonin and lactate dehydrogenase, decreased partial pressures of carbon dioxide (PaCO₂) and oxygen (PaO₂) (Table 1). Pulmonary function tests revealed restricted ventilation dysfunction with a moderate reduction in oxygen diffusion capacity. Chest CT findings suggested severe ILD, characterized by diffuse ground-glass opacities, reticular patterns, patchy infiltrates, and bronchovascular bundle thickening in both lungs (Figure 1 A-C). Before proposing a bronchoscopic examination, infectious disease screenings, including HIV, HBV, HCV, and syphilis, were performed as part of the preoperative assessment. Notably, it was found that the

Table 1 Laboratory Test Results on Admission

Test item	Time				Normal range
	1 st day of Admission	4 th day of Admission	7 th day of Admission	9 th day of Admission	
WBC counts (10 ⁹ cells/L)	4.66	4.47	12.86	-	3.5–9.5
Neutrophils percentage (%)	90.5	86.4	89.6	-	40–75
Monocyte percentage (%)	2.6	2.9	5.8	-	3–10
Lymphocyte percentage (%)	5.6	10.5	4.4	-	20–50
RBC counts (10 ¹² cells/L)	3.96	3.83	4.05	-	4.3–5.8
Hemoglobin (g/L)	117	112	118	-	130–175
SGPT (U/L)	32	48	51	-	9–50
SGOT (U/L)	42	59	49	-	15–40
Total Protein (g/L)	53.4	56.4	59.6	-	65–85
Albumin (g/L)	29.8	31.5	32.9	-	40–55
CK (U/L)	237	224	235	245	50–310
LDH (U/L)	372	552	-	-	120–250
ESR (mm/hr)	65	96	77	-	<15
PCT (ng/mL)	0.08	0.07	0.24	-	<0.1
hsCRP (mg/L)	-	52.8	7.7	-	0–3
HIV Duo	>1.0	>1.0	-	-	<0.9
HIV Ab confirmation test	-	-	negative	-	negative
CD4 ⁺ T cell count (cells/ μ L)	241	-	189	-	410–1590
CD8 ⁺ T cell count (cells/ μ L)	95	-	80	-	190–1140
HIV RNA load (copies/mL)	TND	-	TND	-	TND
Plasma (1,3) beta-D-glucan (pg/mL)	89	201.4	10	-	<60
Influenza A/B Virus RNA	TND	TND	TND	-	TND
Cryptococcus Ag	negative	-	-	-	negative
Anti-EBV-EA IgM	negative	-	-	-	negative
Anti-EBV-VCA IgM	negative	-	-	-	negative
Anti-CMV IgM	positive	-	-	-	negative
Anti-CMV IgG	negative	-	-	-	negative
Anti-TOX IgM	negative	-	-	-	negative

(Continued)

Table 1 (Continued).

Test item	Time				Normal range
	1 st day of Admission	4 th day of Admission	7 th day of Admission	9 th day of Admission	
Anti-TOX IgG	negative	-	-	-	negative
Anti-MDA5 Ab	-	-	positive (+++)	-	negative
pH	7.42	7.495	7.474	7.249	7.350–7.450
PaCO ₂ (mmHg)	29.7	26.2	24.2	38.1	35–45
PaO ₂ (mmHg)	81.8	56.3	63.8	38.2	75–110
PAO ₂ (mmHg)	115.6	118.3	122	104.2	-
PA-aO ₂ (mmHg)	33.8	62	58.2	66	15–20
SaO ₂ (%)	96.8	91.9	94	63.9	75–99

Abbreviations: WBC: White blood cell, RBC: Red blood cell, SGPT: Serum glutamic pyruvic transaminase, SGOT: Serum glutamic oxaloacetic transaminase, CK: Creatine Kinase, LDH: Lactate dehydrogenase, ESR: Erythrocyte sedimentation rate, PCT: Procalcitonin, hsCRP: High-sensitivity C-reactive protein, Ab: Antibody, HIV: Human Immunodeficiency Virus, RNA: Ribonucleic Acid, EBV: Epstein-Barr virus, CMV: Cytomegalo virus, EA: Early antigen, VCA: Viral capsid antigen, TOX: Toxoplasma, MDA5: Melanoma differentiation-related gene 5. Ag: Antigen, IgM: Immunoglobulin M, IgG: Immunoglobulin G, pH: Potential of hydrogen, PaCO₂: Partial pressures of carbon dioxide, PaO₂: Partial pressure of oxygen, PAO₂: Alveolar partial pressure of oxygen, PA-aO₂: Partial pressure of alveolar oxygen minus arterial oxygen, SaO₂: Oxygen saturation, +++ indicates a strong positive result for the specified marker or test.

patient's HIV screening test was positive, with a CD4⁺ T cell count of 241 cells/ μ L, which decreased to 189 cells/ μ L 5 days later. HIV viral load was persistently undetectable, and the levels of serum (1, 3)- β -d-glucan and lactate dehydrogenase were elevated (Table 1). The patient was initially suspected of PCP, the most common opportunistic infection in people living with HIV, based on his clinical presentation, laboratory results, and CT findings. Despite 5 days of anti-PCP treatment, his condition did not improve; pneumocystis jirovecii was not detected in the sputum sample, and follow-up HIV nucleic acid tests were both negative (Table 1). The patient's pulmonary condition rapidly worsened. Additionally, he recalled the onset of a scalp rash one month prior, raising concern for interstitial lung disease associated with dermatomyositis. Finally, CADM was suspected based on myalgia-free facial rashes and normal serum levels of CK. Critically, the anti-MDA5 antibody was strongly positive, confirming the diagnosis of CADM and predicting a grave prognosis. Once diagnosed, the patient was treated with immunosuppressive drugs, including intravenous glucocorticoids, immunoglobulins, and oral tacrolimus. However, the treatment failed, and the patient died on the ninth day of hospitalization.

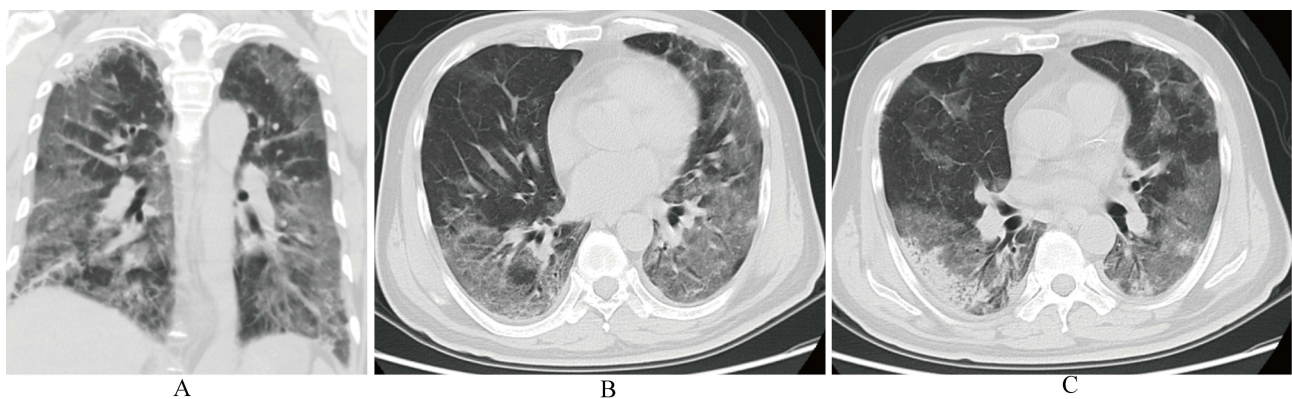


Figure 1 Chest computed tomography (CT) scan. (A) Sagittal chest CT scan shows bilateral thoracic cage is symmetrical, diffuse ground-glass opacities and reticular patterns are observed in both lungs; (B) Coronal view demonstrates bronchovascular bundle thickening in both lungs, with diffusely distributed ground-glass opacities and reticular patterns. Bilateral pleural thickening is also observed; (C) Multiple ground-glass opacities are observed in the subpleural regions and along the bronchovascular bundles in both lungs, accompanied by localized interlobular septal thickening, most pronounced in the subpleural areas, patchy consolidations and air bronchograms are also visible.

Discussion

The false-positive result of the HIV screening test complicated the diagnostic and treatment process in this patient. By sharing this case, insights are provided for clinical practitioners, highlighting the challenges posed by false-positive results in HIV testing and the importance of further evaluation and confirmation before treatment decisions are made.

Diagnosis of CADM can be challenging in certain patients, as they may lack characteristic muscle manifestations and exhibit atypical skin lesions following hospitalization. In addition, CADM-associated RP-ILD is associated with a high mortality rate, underscoring the importance of early identification and effective management of these individuals. As demonstrated in our reported case, the patient with a positive anti-MDA5 antibody status presented with rapidly progressive and ultimately fatal ILD. Currently, there is a lack of randomized controlled trials evaluating treatments for ILD associated with MDA5 antibody-positive CADM. Existing studies suggest that early administration of high-dose systemic corticosteroids in combination with other immunosuppressants, such as calcineurin inhibitors and/or cyclophosphamide, may offer the most significant survival benefit for patients with RP-ILD.^{7,8} Additionally, tofacitinib and rituximab may provide benefit for refractory rashes and RP-ILD in MDA5-DM patients.^{9,10} Given the high mortality risk in this population, early diagnosis and intervention are critical.

False-positive HIV screening tests in CADM patients have not been previously reported. The current 4th generation HIV test, which is the leading method for HIV screening, narrows the window period by identifying HIV-1/2 antibodies and HIV p24 antigens with sensitivity and specificity above 99%.¹¹ However, misdiagnosis of the 4th generation HIV test has been reported in some cases. For example, *Sethi et al* have demonstrated for the first time that SARS-CoV-2 antigen/antibody exhibits cross-reactivity with commercial chemiluminescence immunoassay methods, leading to false positive results.¹² Moreover, autoimmune diseases such as SLE and RA, pregnancy, viral infections, and hematologic malignancy may result in false-positive HIV tests.^{13–16} Therefore, it is speculated that false-positive HIV screening may be related to CADM or DM due to cross-reactivity of antigens. As an autoimmune disease, the pathogenesis of DM is complex and not yet fully clarified and involves genetic, environmental, and immune mechanisms. The genetic association of DM is primarily related to human leucocyte antigen (HLA) class II alleles, supporting the role of an immune response driven by T cells.^{17,18} Interestingly, autoimmunity during HIV-1 infection contributes to titers of autoantibodies to HLA molecules and increases other surface markers of CD4⁺ T cells.¹⁹ Given the immunopathogenesis of CADM/DM and HIV, it is hypothesized that the immune response to CADM/DM is likely to exhibit immune activation that cross-reacts with HIV antigens, further contributing to HIV false positives. The limitation of our report is the lack of retained participant samples for further validation, which prevents us from determining whether the false positives in HIV testing were attributable to antibody cross-reactivity.

Conclusion

In summary, anti-MDA5 antibody-positive CADM with RP-ILD as the primary manifestation is a rare clinical entity with a dismal prognosis and high mortality. While the immune response can result in false-positive HIV screening due to antigen cross-reactivity, this may lead to delayed diagnosis of CADM and ILD. In light of this reported case, it is essential to acknowledge the importance of conducting a thorough assessment of factors beyond HIV-related conditions in individuals with no history of HIV exposure but who test positive on HIV screening. This necessitates a comprehensive investigation into alternative underlying causes.

Ethics Approval and Informed Consent

All identifying information has been removed or anonymized throughout the manuscript. Informed consent was obtained from next-of-kin of the patient for publication of all related materials. All patient data was handled in accordance with applicable data protection regulations, ensuring that any information collected was stored securely and accessed only by authorized personnel. This study was approved by the Medical Ethics Committee of Beijing YouAn Hospital, Capital Medical University. And we confirm that institutional approval was not required to publish the case details, as all patient information has been anonymized and there are no identifying details included in the manuscript.

Consent for Publication

Written informed consent was obtained from the next-of-kin of the patient for publication of identifying images or other personal or clinical details of this case report.

Acknowledgments

We are thankful to the patient for the support given in providing the data.

Author Contributions

All authors made a significant contribution to the work reported, whether that is in the conception, study design, execution, acquisition of data, analysis and interpretation, or in all these areas; took part in drafting, revising or critically reviewing the article; gave final approval of the version to be published; have agreed on the journal to which the article has been submitted; and agree to be accountable for all aspects of the work.

Funding

National Natural Science Foundation of China (82241072, 82072271); the Beijing Natural Science Foundation (7222095); Research and application of characteristic clinical diagnosis and treatment technology in Beijing (Z221100007422055); Beijing research center for respiratory infectious diseases project (BJRID2024-001), Beijing Hospitals Authority's Ascent Plan (DFL20221502).

Disclosure

The authors declare that they have no competing interests.

References

1. Joy GM, Arbib OA, Wong CK, et al. Prevalence, imaging patterns and risk factors of interstitial lung disease in connective tissue disease: a systematic review and meta-analysis. *EuropeRespira Rev.* 2023;32(167).
2. Maher TM. Interstitial Lung Disease: a Review. *JAMA.* 2024;331(19):1655–1665.
3. Fornaro M, Girolamo F, Giannini M, et al. Clinical, histologic and prognostic features of clinically amyopathic dermatomyositis. *Clin Exp Rheumatol.* 2024;42(2):288–294.
4. Mukae H, Ishimoto H, Sakamoto N, et al. Clinical differences between interstitial lung disease associated with clinically amyopathic dermatomyositis and classic dermatomyositis. *Chest.* 2009;136(5):1341–1347.
5. Wang W, Sun X, Xu Y, Tan W, Liu Y, Zhou J. Prognostic analysis of MDA5-associated clinically amyopathic dermatomyositis with interstitial lung disease. *Immun Inflamm Dis.* 2024;12(6):e1332.
6. Wu W, Guo L, Fu Y, et al. Interstitial Lung Disease in Anti-MDA5 Positive Dermatomyositis. *Clinical Review Allergy Immunology.* 2021;60(2):293–304.
7. Romero-Bueno F, Diaz Del Campo P, Trallero-Araguás E, et al. Recommendations for the treatment of anti-melanoma differentiation-associated gene 5-positive dermatomyositis-associated rapidly progressive interstitial lung disease. *Semin Arthritis Rheum.* 2020;50(4):776–790.
8. McPherson M, Economidou S, Liampas A, Zis P, Parperis K. Management of MDA-5 antibody positive clinically amyopathic dermatomyositis associated interstitial lung disease: a systematic review. *Semin Arthritis Rheum.* 2022;53:151959.
9. Mao -M-M, Xia S, Guo B-P, et al. Ultra-low dose rituximab as add-on therapy in anti-MDA5-positive patients with polymyositis /dermatomyositis associated ILD. *Respir Med.* 2020;172:105983.
10. Ida T, Furuta S, Takayama A, et al. Efficacy and safety of dose escalation of tofacitinib in refractory anti-MDA5 antibody-positive dermatomyositis. *RMD Open.* 2023;9(1).
11. Chavez P, Wesolowski L, Patel P, Delaney K, Owen SM. Evaluation of the performance of the Abbott ARCHITECT HIV Ag/Ab Combo Assay. *J Clin Virol.* 2011;52:S51–S55.
12. Tan SS, Chew KL, Saw S, Jureen R, Sethi S. Cross-reactivity of SARS-CoV-2 with HIV chemiluminescent assay leading to false-positive results. *J Clin Pathol.* 2021;74(9):614.
13. Bukhari S, Dirweesh A, Amodu A, Nadeem M, Wallach SL. A Case of False-Positive HIV Test in a Patient With Newly Diagnosed Hodgkin Lymphoma and Literature Review. *Cureus.* 2020;12(10).
14. Esteva MH, Blasini AM, Ogly D, Rodriguez MA. False positive results for antibody to HIV in two men with systemic lupus erythematosus. *Ann Rheum Dis.* 1992;51(9):1071–1073.
15. Lasmanovich R, Atias D, Mor O, Obolski U. False-positive HIV screening tests during the COVID-19 pandemic, a passing trend? *AIDS.* 2023;37(15):2430–2432.
16. Jian L, Liang W, Zhang Y, et al. Systemic lupus erythematosus patient with false positive results of antibody to HIV: a case report and a comprehensive literature review. *Technol Health Care.* 2015;23(1).
17. Thompson C, Piguet V, Choy E. The pathogenesis of dermatomyositis. *Brit j Dermatol.* 2018;179(6):1256–1262.
18. Chen Z, Wang Y, Kuwana M, et al. HLA-DRB1 Alleles as Genetic Risk Factors for the Development of Anti-MDA5 Antibodies in Patients with Dermatomyositis. *J Rheumatol.* 2017;44(9):1389–1393.
19. Zandman-Goddard G, Shoenfeld Y. HIV and autoimmunity. *Autoimmun Rev.* 2002;1(6):329–337.

Infection and Drug Resistance

Dovepress

Publish your work in this journal

Infection and Drug Resistance is an international, peer-reviewed open-access journal that focuses on the optimal treatment of infection (bacterial, fungal and viral) and the development and institution of preventive strategies to minimize the development and spread of resistance. The journal is specifically concerned with the epidemiology of antibiotic resistance and the mechanisms of resistance development and diffusion in both hospitals and the community. The manuscript management system is completely online and includes a very quick and fair peer-review system, which is all easy to use. Visit <http://www.dovepress.com/testimonials.php> to read real quotes from published authors.

Submit your manuscript here: <https://www.dovepress.com/infection-and-drug-resistance-journal>