


# Outcomes of Cartilage-Sparing Wide Local Excision for Primary Melanoma of the External Ear

Alisa Yamasaki, MD<sup>1,2</sup>, Michael P. Wu, MD<sup>1,2</sup>,  
 and Kevin S. Emerick, MD<sup>1,2</sup>

OTO Open  
 2020, Vol. 4(1) 1–4  
 © The Authors 2020  
 Article reuse guidelines:  
[sagepub.com/journals-permissions](http://sagepub.com/journals-permissions)  
 DOI: 10.1177/2473974X20903124  
<http://oto-open.org>  


No sponsorships or competing interests have been disclosed for this article.

## Abstract

**Objective.** To describe outcomes after cartilage-sparing wide local excision for primary melanoma of the external ear.

**Study Design.** Retrospective analysis of patients undergoing external ear melanoma excision using a cartilage-sparing approach at a university-based tertiary care center between 2010 and 2018.

**Setting.** University-based tertiary care center.

**Subject and Methods.** Chart review was performed for all patients over age 18 who were treated for melanoma of the external ear at Massachusetts Eye and Ear between 2010 and 2018. Patients with melanoma in situ or with melanomas in noncartilaginous areas of the ear (eg, lobule) were excluded.

**Results.** A total of 8 patients underwent cartilage-sparing excision. Sentinel lymph node biopsy was performed in 7 patients, with positive lymph nodes in 1 of 7 cases. Positive margins and local recurrence occurred in 1 of 8 (12.5%) patients during a mean (SD) follow-up time of 22.5 (15.1) months (SE, 5.3 months). No distant metastasis or death was observed.

**Conclusion.** Cartilage-sparing wide local excision for melanoma of the external ear is a surgical approach that enables surgeons to follow guideline-recommended oncologic excision margins but has the added benefit of improved post-operative aesthetic outcomes as well as reconstructive options through preservation of the auricular cartilage framework.

## Keywords

external ear melanoma, cartilage-sparing excision, melanoma excisional margins, melanoma outcomes, melanoma recurrence rate, melanoma survival

Received July 22, 2019; accepted January 9, 2020.

Cutaneous melanoma is the fifth most prevalent cancer in the United States,<sup>1</sup> and cutaneous melanomas of the head and neck region comprise 25% to 30% of all cases.<sup>2,3</sup> Wide local excision (WLE) is the gold-standard treatment, with excision margins based on microscopic tumor thickness as recommended by the 2016 National Comprehensive Cancer Network (NCCN) guidelines.<sup>4</sup> Despite established guidelines, surgical excision margins for melanomas of the head and neck have been highly variable in practice due to the significant functional and cosmetic implications of lesions in close proximity to many critical vessels, nerves, and organs.<sup>5</sup> For melanomas of the external ear, a range of surgical margins has been reported, from wedge resection to complete auricectomy.<sup>6,7</sup> Historically, excision has included the underlying perichondrium and cartilage in addition to the overlying melanoma lesion.<sup>8,9</sup> These cartilage-excising approaches limit reconstructive options to basic closure techniques such as the standard wedge closure. On the other hand, a cartilage-sparing approach has the potential to maintain the functional and aesthetic qualities of the external ear by preserving a cartilaginous framework for reconstruction. Here, we examine outcomes of cartilage-sparing excision of external ear melanoma through a single-institution analysis of 8 patients. The primary outcome examined was disease-specific survival and overall survival, with secondary outcome measures of margin status, need for re-resection, locoregional recurrence rate, and distant metastasis rate.

<sup>1</sup>Department of Otolaryngology, Massachusetts Eye and Ear, Boston, Massachusetts, USA

<sup>2</sup>Harvard Medical School, Boston, Massachusetts, USA

Poster presented at American Academy of Otolaryngology–Head and Neck Surgery Foundation Annual Meeting; October 7–10, 2018; Atlanta, Georgia.

## Corresponding Author:

Kevin S. Emerick, MD, Department of Otolaryngology, Massachusetts Eye and Ear, 243 Charles Street, Boston, MA 02114, USA.  
 Email: [kevin\\_emerick@meei.harvard.edu](mailto:kevin_emerick@meei.harvard.edu)



## Methods

A retrospective chart review of patients over the age of 18 diagnosed with melanoma of the external ear was performed after review and approval from the Massachusetts Eye and Ear Human Studies Committee. Patients presented to Massachusetts Eye and Ear for evaluation and follow-up during an 8-year period between 2010 and 2018. Radial and gross margins were based on margins documented in operative reports, with confirmation of margins using pathology reports. The deep margin in all cases was cartilage, with perichondrium included in the resection. All patients who underwent surgery at Massachusetts Eye and Ear had surgery performed by the senior author of the study (K.S.E.). Patients with melanoma in situ or melanoma in a location where a cartilage-sparing technique was not applicable, such as the lobule, were excluded from analysis. Patients with staging  $\geq$ T1b melanoma with high-risk features (ie, melanoma depth  $\geq$  0.75 to 1.0 mm and presence of ulceration or mitoses) were offered sentinel lymph node biopsy (SLNB).

## Results

The mean (SD) age of patients undergoing cartilage-sparing excision of melanoma of the external ear was 53.5 (16.8) years (SE, 5.9; range, 29-76 years) (**Table 1**). Five of 8 patients were male (63%). The mean (SD) follow-up time was 22.5 (15.1) months (SE, 5.3; range, 3.6-46.2 months). The most common primary site for external ear melanoma was the helix, accounting for 6 of 8 (75%) patients, and the most common histologic subtype was superficial spreading melanoma, accounting for 4 of 8 (50%) cases. The mean (SD) tumor thickness was 1.18 (0.62) mm (SE, 0.22; range, 0.17-2.17), with no ulceration seen in 7 of 8 tumors (88%). Mitotic rate was  $\geq$ 1 per mm<sup>2</sup> in 7 of 8 tumors (88%).

All patients underwent a 1-cm surgical margin except for 1 patient who had T3 disease with a tumor thickness of 2.17 mm (**Table 2**), for which a 2-cm margin was used. All surgical defects were reconstructed during the primary resection using full-thickness skin grafts (FTSGs) (**Figure 1**). One patient had positive surgical margins based on pathology (**Table 2**), with microscopic evidence of tumor approaching but not invading beyond the deep margin of perichondrium. None of the patients had evidence of direct invasion of cartilage on permanent pathology. No patients received adjuvant therapy.

Seven of 8 patients (88%) underwent SLNB (**Table 2**). One patient had positive SLNB (2 of 15 nodes) with positive surgical margins as above. This patient also had subsequent local recurrence at 33.6 months, which was excised including the underlying cartilage with completion neck dissection also performed. No additional pathologic nodes were identified (**Table 2**). No patients had distant metastasis. Overall and disease-specific survival were 100% during the follow-up period for all patients.

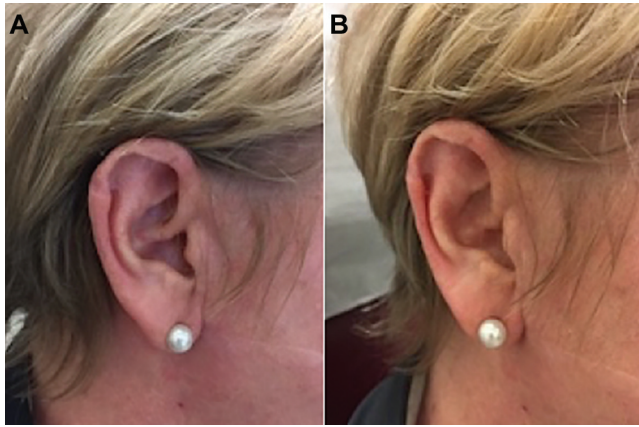
**Table 1.** Patient Demographics and Tumor Characteristics (n = 8).

Characteristic	Value
Age, y	
Mean (SD)	53.5 (16.8)
SE	5.9
Range	29-76
Sex, No. (%)	
Male	5 (63)
Female	3 (38)
Follow-up, mo	
Mean (SD)	22.5 (15.1)
SE	5.3
Range	3.6-46.2
Overall survival, No. (%)	8 (100)
Disease-specific survival, No. (%)	8 (100)
Local or regional recurrence, No. (%)	1 (12.5)
Distant metastasis, No. (%)	0
Primary tumor location, No. (%)	
Helix	6 (75)
Postauricular	1 (12.5)
Triangular fossa	1 (12.5)
Histologic subtype, No. (%)	
Superficial spreading tumors	4 (50)
Unclassified/other tumors	4 (50)
Ulceration, No. (%)	
Absent	7 (88)
Present	1 (13)
Primary tumor mitotic rate, No. (%)	
<1 per mm <sup>2</sup>	1 (13)
$\geq$ 1 per mm <sup>2</sup>	7 (88)
Tumor T stage, No. (%)	
T1a	1 (13)
T1b	3 (38)
T2a	2 (25)
T2b	1 (13)
T3a	1 (13)
Lymph node status, No. (%) <sup>a</sup>	
Positive	1 (14)
Negative	6 (86)
Thickness/Breslow depth, mm	
Mean (SD)	1.18 (0.62)
SE	0.22
Range	0.17-2.17

<sup>a</sup>Lymph node status was based on 7 of 8 cartilage-sparing patients who underwent sentinel lymph node biopsy and/or neck dissection.

## Discussion

Large studies of the optimal surgical management of melanoma of the external ear are lacking, but recent literature suggests that the prognosis of this tumor may be more favorable than previously thought. Less aggressive surgical approaches have become increasingly common.<sup>6-8</sup> In this



**Figure 1.** Postoperative photo of cartilage-sparing excision of melanoma of the superior helix with primary reconstruction using a full-thickness skin graft. (A) En face view. (B) Oblique view.

small series, we report 100% overall and disease-specific survival over a mean follow-up time of 22.5 months and a 12.5% recurrence rate, with no recurrences among node-negative patients, suggesting that cartilage-sparing excision can provide good oncologic control while enabling reconstructive options with the potential for better aesthetic outcomes.

The existing melanoma literature assumes a standard deep margin of excision to the next fascial layer, which is perichondrium in the case of the external ear.<sup>10</sup> Based on histopathologic examination of ear melanoma resection specimens, invasion of the cartilage is rare, even in melanomas as thick as 11 mm.<sup>11,12</sup> Theoretically, excising down to the level of the cartilage—by removing the tough perichondrial layer while preserving the cartilage itself—should provide equivalent primary tumor disease control to cartilage removal and should similarly capture any adjacent areas containing lymphatics. In the 1 local recurrence of this series, pathologic analysis of the recurrent lesion found no tumor cells in the underlying cartilage. However, this patient had a positive SLNB, suggesting that lymphatic spread had already occurred.

Our results support a cartilage-sparing approach for WLE with radial margins consistent with NCCN recommendations. Nationwide, 58% of all melanoma excisions are performed with radial margins less than 1 cm, with even higher nonadherence to margin recommendations in the head and neck region due to cosmetic concerns.<sup>5</sup> Cartilage-sparing excisions allow simple and cosmetically acceptable reconstruction options such as FTSG, and a cartilage-sparing approach may thus preserve reconstructive options to enable oncologic surgeons to more comfortably fully excise the recommended 1- to 2-cm radial margin.

Future work will be required to quantify both the cosmetic and oncologic consequences of cartilage-sparing excision. Patient-reported outcome instruments such as the Patient Outcomes of Surgery-Head/Neck and the FACE-Q Skin Cancer Module have recently begun to quantify outcomes metrics specific to interventions of the head and neck

**Table 2.** Summary of Tumor Characteristics, Surgical Margins, Recurrence, and Mean Follow-up.

Age, y/ Sex		Thickness, mm	Ulceration/ Mitoses/ NV Invasion	Staging	Primary Lesion Location	Histology	Surgery	Radial Margin, cm <sup>a</sup>	Deep Margin, cm	Margin Status	LR/RR	Follow-up, mo
50/M		0.17	No/0/NA	T1aN0M0	Triangular fossa	Unclassified	WLE, FTSG	1 (0.5)	0.2	Negative	No	11.2
55/F		1.0	No/2/No	T1bN0M0	Helix	SSM	WLE, SLNB, FTSG	1 (0.5)	0.4	Negative	No	3.6
29/F		0.78	No/3/NA	T1bN0M0	Helix	Unclassified	WLE, SLNB, FTSG	1 (0.9)	0.2	Negative	No	28.9
34/F		1.55	No/1/NA	T2aN0M0	Helix	Unclassified	WLE, SLNB, SND, FTSG	1 (1)	0.2	Negative	No	4.3
49/M		0.9	No/2/NA	T1bN0M0	Helix	NA	WLE, SLNB, FTSG	1 (NA)	0.2	Negative	No	25.7
73/M		1.2	Yes/2/No	T2bN0M0	Helix	SSM	WLE, SLNB, FTSG	1 (0.9)	0.3	Negative	No	46.2
62/M		2.17	No/10/No	T3aN0M0	Helix	SSM	WLE, SLNB, FTSG	2 (1.4)	NA	Negative	No	24.5
76/M		1.7	No/5/No	T2aN2M0	Posterior auricle	SSM	WLE, SLNB, FTSG, SND	1 (0.6)	0.1	Positive	Yes (33.6 mo)	35.2

Abbreviations: FTSG, full-thickness skin graft; LR/RR, local recurrence/regional recurrence; NA, not available; NV, neurovascular; SLNB, sentinel lymph node biopsy; SND, selective neck dissection; SSM, superficial spreading melanoma; WLE, wide local excision.

<sup>a</sup>Radial margins are based on gross margins described in the operative report, with final radial margins based on the pathology report in parentheses.

such as patient-perceived facial appearance, appearance-related psychosocial distress, and anxiety regarding cancer recurrence.<sup>13-15</sup> From an oncologic perspective, assuming 5-year recurrence-free survival in the cartilage-excising group to be 79%,<sup>6</sup> detecting a hazard ratio of 0.8 in favor of cartilage-excising excision over cartilage-sparing resection would require 125 patients in each arm of a potential study. Given the challenges of obtaining such a large number of external ear melanoma cases, continued data aggregation through smaller case series may be the most realistic approach.

## Conclusion

Cartilage-sparing excision for T1 or T2 stage melanoma of the external ear is a surgical option that facilitates reconstruction while allowing 1- to 2-cm radial excision margins. Given the significant functional and aesthetic implications of WLE involving cartilage of the auricle, cartilage-sparing approaches to resection should be considered. Most important, this may increase compliance with achieving the 1- to 2-cm radial margins recommended by the 2016 NCCN guidelines.

## Author Contributions

**Alisa Yamasaki**, conception and study design interpretation of data, data acquisition and analysis, drafting and critical revision of manuscript, final approval of manuscript, accountable for all aspects of work; **Michael P. Wu**, data acquisition and analysis, critical revision of manuscript, final approval of manuscript, accountable for all aspects of work; **Kevin S. Emerick**, conception and study design, interpretation of data, critical revision of manuscript, final approval of manuscript, accountable for all aspects of work.

## Disclosures

**Competing interests:** None.

**Sponsorships:** None.

**Funding source:** None.

## References

1. National Cancer Institute. Cancer stat facts: melanoma of the skin. 2017. <https://seer.cancer.gov/statfacts/html/melan.html>. Accessed October 7, 2017.
2. Goldsmith HS. Melanoma: an overview. *CA Cancer J Clin*. 1979;29:194-215.
3. Bono A, Bartoli C, Maurichi A, Moglia D, Tragni G. Melanoma of the external ear. *Tumori*. 1997;83:814-817.
4. Coit DG, Thompson JA, Algazi A, et al. Melanoma, Version 2.2016, NCCN Clinical Practice Guidelines in Oncology. *J Natl Compr Canc Netw*. 2016;14:450-473.
5. Wasif N, Gray RJ, Bagaria SP, Pockaj BA. Compliance with guidelines in the surgical management of cutaneous melanoma across the USA. *Melanoma Res*. 2013;23:276-282.
6. Jahn V, Breuninger H, Garbe C, Moehle M. Melanoma of the ear: prognostic factors and surgical strategies. *Br J Dermatol*. 2006;154:310-318.
7. Pockaj BA, Jaroszewski DE, DiCaudo DJ, et al. Changing surgical therapy for melanoma of the external ear. *Ann Surg Oncol*. 2003;10:689-696.
8. Byers RM, Smith JL, Russell N, Rosenberg V. Malignant melanoma of the external ear: review of 102 cases. *Am J Surg*. 1980;140:518-521.
9. Cole DJ, Mackay GJ, Walker BF, Wooden WA, Murray DR, Coleman JJ. Melanoma of the external ear. *J Surg Oncol*. 1992;50:110-114.
10. Grotz TE, Markovic SN, Erickson LA, et al. Mayo Clinic consensus recommendations for the depth of excision in primary cutaneous melanoma. *Mayo Clin Proc*. 2011;86:522-528.
11. Sartore L, Giatsidis G, Reho F, Tanzillo G, Campana L, Salmasso R. Ear melanoma: influence of perichondrium involvement in evaluating surgical strategy. *Eur Arch Otorhinolaryngol*. 2012;269:1685-1690.
12. Craig ES, Nagarajan P, Lee ES, Lazova R, Turner J, Narayan D. The perichondrium in auricular melanomas: implications for surgical management. *Otolaryngol Neck Surg*. 2013;148:431-435.
13. Cano SJ, Browne JP, Lamping DL, Roberts AHN, McGrouther DA, Black NA. The Patient Outcomes of Surgery—Head/Neck (POS-Head/Neck): a new patient-based outcome measure. *J Plast Reconstr Aesthet Surg*. 2006;59:65-73.
14. Lee EH, Klassen AF, Nehal KS, Cano SJ, Waters J, Pusic AL. A systematic review of patient-reported outcome instruments of nonmelanoma skin cancer in the dermatologic population. *J Am Acad Dermatol*. 2013;69:e59-e67.
15. Lee EH, Klassen AF, Cano SJ, Nehal KS, Pusic AL. FACE-Q Skin Cancer Module for measuring patient-reported outcomes following facial skin cancer surgery. *Br J Dermatol*. 2018;179:88-94.