

Available online at [www.sciencedirect.com](http://www.sciencedirect.com)

ScienceDirect

journal homepage: [www.elsevier.com/locate/radcr](http://www.elsevier.com/locate/radcr)

## Case Report

# Large cholelithiasis with cholecystoduodenal fistula ☆☆☆

Akshay Gupta, DO<sup>a</sup>, Jayme D. Lieberman, MD, MBA<sup>b</sup>, Fernando S. Isaza, MD<sup>b</sup>, Charles J. Browning, MD<sup>b</sup>, Shawn M. Quinn, DO<sup>a,\*</sup>

<sup>a</sup>Lehigh Valley Health Network, Department of Emergency and Hospital Medicine/USF Morsani College of Medicine, Cedar Crest Boulevard & I-78, Allentown 18103 PA, USA

<sup>b</sup>Lehigh Valley Health Network, Department of Surgery/USF Morsani College of Medicine, Cedar Crest Boulevard & I-78, Allentown 18103 PA, USA

## ARTICLE INFO

## Article history:

Received 14 October 2020

Revised 18 December 2020

Accepted 24 December 2020

## Keywords:

Cholelithiasis

Fistula

Gastroenterology

## ABSTRACT

Cholelithiasis is a common gastrointestinal pathology that can lead to rare complications including cholecystoduodenal fistulas and GI hemorrhage. Diagnosing cholelithiasis and cholecystoduodenal fistulas in the emergency department (ED) using computed tomography (CT) imaging despite nonspecific and variable symptoms is critical in determining management strategies for medically complex patients. An 87-year-old medically complex female presented to the ED in hemorrhagic shock after several episodes of hematemesis, hematochezia, and other nonspecific gastrointestinal symptoms. A CT of the abdomen/pelvis was performed revealing cholecystitis with a large 6-cm stone; additionally, a biliary enteric fistula was noted with blood products in the gallbladder. This case highlights the importance of CT imaging in the setting of gastrointestinal bleeding with cholelithiasis and biliary enteric fistula diagnosis, and discusses potential management strategies of these diagnoses in medically complex patients.

© 2020 The Authors. Published by Elsevier Inc. on behalf of University of Washington.

This is an open access article under the CC BY-NC-ND license (<http://creativecommons.org/licenses/by-nc-nd/4.0/>)

## Introduction

Cholelithiasis is one of the most common gastrointestinal diseases with risk factors including female sex, increasing age, dyslipidemia, hyperinsulinism, and obesity [1]. In some

cases, large stones (>2.5 cm) can cause complications including cholecystitis, obstructive cholangitis, gallstone pancreatitis, and, in rare cases, biliary enteric fistulas, which can lead to gallstone ileus [1,2]. Even more rarely, they cause upper gastrointestinal bleeding and subsequent shock [3]. Biliary enteric fistulas are most often found during surgery, and pose

☆ Competing Interests: None.

☆☆ Funding: This research did not receive any specific grant from funding agencies in the public, commercial, or not-for-profit sectors.

\* Acknowledgments: Authors would like to acknowledge the efforts of Samantha Esposito for her assistance in scholarly preparation of the case.

\* Corresponding author.

E-mail address: [Shawn\\_M.Quinn@lvhn.org](mailto:Shawn_M.Quinn@lvhn.org) (S.M. Quinn).

<https://doi.org/10.1016/j.radcr.2020.12.056>

1930-0433/© 2020 The Authors. Published by Elsevier Inc. on behalf of University of Washington. This is an open access article under the CC BY-NC-ND license (<http://creativecommons.org/licenses/by-nc-nd/4.0/>)

a challenge to diagnose preoperatively due to nonspecific and variable symptoms [3–5]. However, use of computed tomography (CT) images and ultrasonography can accurately identify cholelithiasis, cholecystitis, and biliary enteric fistulas for optimal management in the emergency department (ED).

The present case discusses an 87-year-old female patient that presented to the ED with gastrointestinal bleeding and epigastric abdominal pain leading to a diagnosis of cholecystitis with a 6-cm stone and a cholecystoduodenal fistula. This case highlights the importance of using CT imaging to diagnose large cholelithiasis and cholecystoduodenal fistulas despite nonspecific symptoms, and potential management strategies in medically complex patients.

## Case Report

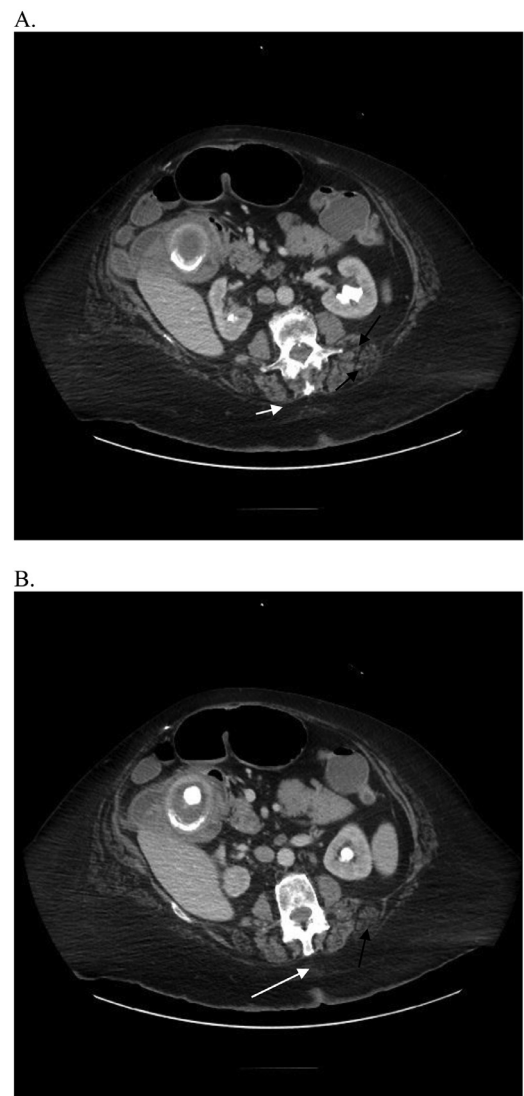
An 87-year-old female presented to ED with mild epigastric pain, hematemesis, and hematochezia with loose stools about 15 minutes after eating dinner. The patient had a history of gastroesophageal reflux disease, dementia, peripheral vascular disease, hypertension, hyperlipidemia, hypothyroidism, and a previous transient ischemic attack, for which she was taking Plavix. On physical exam she was tachycardic (HR 112) with an initial blood pressure of 100/70 mmHg. She was tender to palpation in the midepigastic area. A CT of the abdomen/pelvis was performed revealing cholecystitis with a large 6-cm stone. Additionally, a biliary enteric fistula was noted with blood products in the gallbladder (Figs. 1 and 2).

Due to multiple episodes of hematemesis, worsening tachycardia, and hypotension, the patient was admitted to the Intensive Care Unit where she was intubated and sedated. The patient was found to have a hemoglobin 9.8 g/dL and platelets 317 thou/cmm, and required an internal jugular central catheter for hemodynamic support. An Esophagogastroduodenoscopy (EGD) was performed due to worsening condition.

EGD revealed a nonbleeding, visible vessel with an adherent clot that was controlled using HemoSpray. The patients' hematemesis was noted likely to be secondary to bleeding from the visible vessel, however, there were no signs of active bleeding. Additionally, during the procedure, several gastric polyps and retained clots were noted in the stomach. The patient was subsequently discharged to her previous skilled nursing facility to begin home hospice if her condition declined.

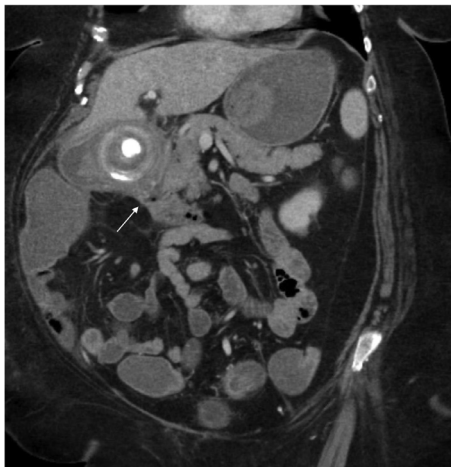## Discussion

Cholelithiasis is a common gastrointestinal disease with risk factors including increased age, diabetes, obesity, women, and among others [1]. Although the majority of patients with cholelithiasis are asymptomatic, they have the potential to cause detrimental complications, especially when they are greater than 2.5 cm in diameter [1]. Inflammation and large cholelithiasis can create pressure in the gallbladder causing erosion through the gallbladder wall leading to biliary-enteric



**Fig. 1 – Computed Tomography (CT) image of the patient's abdomen from the axial view. (A) Cholecystitis (white arrow). (B) Focal wall defect in the medial gallbladder (black arrow) and 6-cm stone (white arrow)**

fistula formation [6]. Biliary-enteric fistulas are a rare complication of cholelithiasis with an incidence rate of 0.5%–0.9% [4]. Those that cause upper gastrointestinal bleeding and shock are even more infrequent [3]. Chronic cholecystitis is the primary cause of biliary-enteric fistulas, the majority of which are categorized as cholecystoduodenal fistulas as seen in the present patient [4]. Symptoms of cholecystoduodenal fistulas are nonspecific and variable, including right upper quadrant abdominal pain, hematemesis, low blood pressure, weight loss, and cholangitis, posing a diagnostic challenge in the ED with the majority of findings occurring during surgery [4,5]. Because of delayed diagnosis and complications that arise from large cholelithiasis, it is essential to maintain a broad differential diagnosis for abdominal pain with upper gastrointestinal bleeding, especially in elderly patients with severe pain [4,5]. The use of CT imaging is critical for preoperative di-



**Fig. 2 – Computed Tomography (CT) image of the patient's abdomen from the coronal view. The biliary enteric fistula is indicated by the white arrow.**

agnosis and allows for visualization of cholelithiasis, fistulas, air in the bile duct, and contraction of the gallbladder [1,3].

Treatment of large cholelithiasis and biliary enteric fistulas includes cholecystectomy, resection of the fistula, and intraoperative cholangiography, however more conservative measures can be taken for patients not suited for surgery [2–4]. Nevertheless, in cases with large cholelithiasis causing cholecystoduodenal fistulas, even if asymptomatic, cholecystectomy may be indicated due to concerns of large cholelithiasis ability to cause gallbladder cancer [2]. In cases where the patient is not fit for surgery and/or has multiple comorbidities, percutaneous cholecystostomy may be used to avoid higher morbidity rates associated with cholecystectomy in these patients [1,7]. Unfortunately, this can cause discomfort to the patient, and is only temporary in controlling symptoms [7]. Therefore in the present case, where the patient had many comorbidities and was not suited for surgery, it was elected to maintain the patient's comfort with conservative treatment of cholelithiasis.

### Author contributions

All authors provided substantial contributions to manuscript content. All authors gave final approval of the version of the article to be published.

### Declaration

No written consent has been obtained from the patients as there is no patient identifiable data included in this case report and the patient is deceased.

### REFERENCES

- [1] Abraham S, Rivera HG, Erlikh IV, Griffith LF, Kondamudi VK. Surgical and nonsurgical management of gallstones. *Am Fam Physician* 2014;89(10):795–802.
- [2] Freeman MH, Mullen MG, Friel CM. The progression of cholelithiasis to gallstone ileus: do large gallstones warrant surgery? *J Gastrointest Surg* 2016;20:1278–80.
- [3] Mohammed N, Godfrey EM, Subramnian V. Cholecysto-duodenal fistula as the source of upper gastrointestinal bleeding. *Endoscopy* 2013;45:E250–1.
- [4] McCreery R, Meigh M. An unusual presentation of cholecystoduodenal fistula: abdominal pain out of proportion to exam. *CPC-EM* 2019;3(3):305–6.
- [5] Aguilar-Espinosa F, Maza-Sánchez R, Vargas-Solís F, Guerrero-Martínez GA, Medina-Reyes JL, Flores-Quiroz PI. Cholecystoduodenal fistula, an infrequent complication of cholelithiasis: our experience in its surgical management. *Rev Gastroenterol Méx* 2017;82(4):287–95.
- [6] Fedele S, Lobascio P, Carbotta G, Balducci G, Laforgia R, Sederino MG, et al. Gallstone ileus in a ninety-two years old cholecistomized patient after endoscopic biliary sphincterotomy: a case report. *G Chir* 2017;38(6):299–302.
- [7] Yeung B, Toeh AYB. Endoscopic management of gallbladder stones: can we eliminate cholecystectomy? *Curr Gastroenterol Rep* 2016;18:42–7.