

Simultaneous central nervous system complications of *C. neoformans* infection

Alejandra González-Duarte,¹
Jesus Higera Calleja,² Vicente Gijón Mitre,
Guillermo Garcia Ramos¹

¹Department of Neurology;

²Neuroradiology of the Instituto Nacional de Ciencias Médicas y Nutrición Salvador Zubirán, Mexico City, México

Abstract

The most common neurological manifestation of *Cryptococcus neoformans* infection is meningitis. Other less common manifestations include parenchymal central nervous system (CNS) granulomatous disease, hydrocephalus and stroke. *C. neoformans* is often suspected in immunodepressed patients, but it can be easily overlooked in otherwise healthy patients. This paper provides a detailed clinical description of a patient without immunosuppression who developed multiple simultaneous neurological manifestations after the infection with *C. neoformans*.

Case Report

A 52-year old woman presented to the emergency department with acute headache that began seven days before her arrival. Her headache had been severe since onset, increased when lying supine or performing the Valsalva maneuver and improved slightly upon standing. She also had frequent episodes of projectile vomiting and neck stiffness. Her medical history was otherwise normal. She was not under corticosteroid or immunosuppressive treatments, nor undergoing chemotherapy or radiotherapy. She lived on a farm and had daily contact with hens and other farm animals.

The neurological examination was remarkable for bilateral papilledema, photophobia, and nuchal rigidity. Peripheral leukocyte count was 8.4 cells/mm³. The rest of the laboratory parameters were non-revealing, including two negative HIV serologies and one negative HIV viral load. Laboratory tests failed to reveal the existence of other immunological deficits. A PPD skin test was negative. A brain computerized tomography (CT) showed marked dilatation of the lateral and third ventricles and a hypodense lesion in the right caudate nucleus. Cerebro spinal fluid (CSF) analysis revealed 89 leukocytes/ μ L (92% monocytes, 8% poly-

morphonucleates (PMN), increased total proteins of 81 mg/dL, glucose of 44 mg/dL (corresponding blood glucose 116 mg/dL), and two positive latex agglutination tests for cryptococcal antigen. CSF polymerase chain reaction (PCR) for tuberculosis was negative. Additional CSF testing also included negative herpes simple virus, herpes zoster virus and Epstein-Barr virus PCR, and negative bacterial, viral and acid-fast bacillus cultures. Treatment with amphotericin B was initiated and the headache improved dramatically. Two days later, a brain magnetic resonance imaging (MRI) showed hydrocephalus, an infarct in the right caudate nucleus (Figure 1) and marked gadolinium enhancement of the arachnoidal meninges and surrounding the vessels (Figure 2) at the basilar region. A small meningeal collection adjacent to the clivus was also noted (Figure 2). The MRA was normal. A transcranial Doppler ultrasound showed asymmetric blood flow suggestive of small vessel vasculopathy. Dexametasone was added to prevent further infarcts. A lumbar puncture after three weeks of treatment showed 50 leukocytes/ μ L (71% monocytes, 29% PMN), proteins 36 mg/dL, and glucose 54 mg/dL (corresponding blood glucose 96 mg/dL). Symptoms resolved completely and the patient was discharged after three weeks with fluconazole and prednisone without neurological sequelae.

Discussion

C. neoformans is a free-living fungus found throughout the world, often isolated from soil associated with avian excreta. CNS infection may occur rarely in immunocompetent hosts.^{1,4} Before the HAART era, the incidence of CNS *C. neoformans* infection in immunocompetent hosts was estimated to be 0.8 cases per million persons per year.¹ Possibly 10-40% of HIV-negative patients with cryptococcosis, do not have

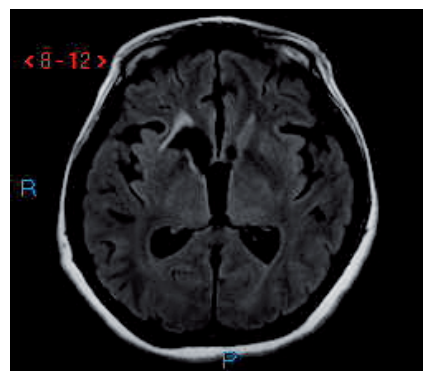


Figure 1. T1 Axial MRI showing severe dilatation of the lateral and third ventricles and a lesion in the region of the right caudate nucleus.

Correspondence: Alejandra González-Duarte, Instituto Nacional de Ciencias Médicas y Nutrición Salvador Zubirán, Vasco de Quiroga 15 Sección 16, Tlalpan, México D.F., CP 01400, México. E-mail: alegdb@aol.com

Key words: *Cryptococcus neoformans*, hydrocephalus, vasculitis, stroke, neuroinfections.

Received for publication: 22 September 2009.

Revision received: 10 December 2009

Accepted for publication: 11 December 2009.

This work is licensed under a Creative Commons Attribution 3.0 License (by-nc 3.0).

©Copyright A.González-Duarte et al., 2009

Licensee PAGEPress, Italy

Neurology International 2009; 1:e22

doi:10.4081/ni.2009.e22

a known immune disorder.⁵

Without prompt diagnosis, cryptococcal infections of the nervous system can cause severe neurological disability and death. Immunocompetent hosts usually show a more acute onset of signs and symptoms, less positive India ink stains, lower titers of CSF antigen (less than 1:1024), higher CSF host cells, less cryptococemia or extracranial sites involved, less parenchymal brain lesions, and lower intracranial pressure when compared to HIV-positive patients.^{1,5} CSF latex antigen cryptococcal agglutination test has a high sensitivity of 92% in CSF.¹ In seronegative patients the polysaccharide antigen test may be the only positive test in earlier infections.⁵

The optimal duration of treatment for non-AIDS patients remains uncertain. For otherwise healthy hosts with CNS disease, amphotericin B plus flucytosine for 6-10 weeks is recommended.⁵ An alternative to this regimen is amphotericin B plus flucytosine for two weeks, followed by fluconazole for a minimum of ten

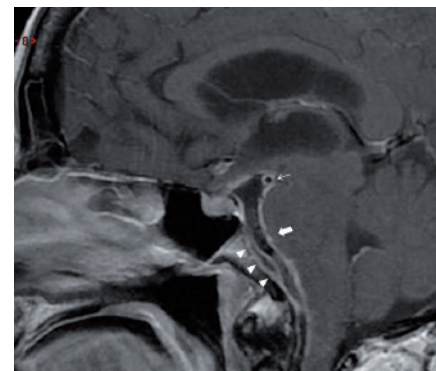


Figure 2. T1 Sagittal MRI with gadolinium showing ventricular dilatation, basal arachnoiditis (thick arrow), perivascular enhancement (thin arrow) and a dural collection dorsal to the clivus (arrow heads).

weeks.⁶ The relapse rate in immunocompetent patients is estimated at 15-25%. Maintenance therapy with fluconazole is not warranted, and antifungal drug therapy must be individualized. Although the use of steroids is not described in vasculopathy associated with *C. neoformans*, steroids have shown greater improvement or stabilization in other infectious vasculopathies.

Conclusions

Cryptococcus neoformans infection is rarely suspected in non-HIV patients. This produces a considerable diagnostic delay and worsens the prognosis in otherwise healthy patients.⁷ As in this case, intracranial hypertension and basilar meningitis due to CNS cryptococcosis are the most common manifestations. Less common complications include communicating or non-communicating hydrocephalus, subdural

collections and stroke due to vasculitis. The diagnosis of CNS cryptococcosis can be rapidly achieved by detection of cryptococcal antigen titers in the CSF. The length of antifungal treatment and the determination of the optimal dose, duration and benefit of steroid therapy in associated vasculopathy await studies with larger case numbers.

References

1. Eric Searls D, Sico J, Bulent Omay S, Bannykh S, Kuohung V, Baehring J. Unusual presentations of nervous system infection by cryptococcus neoformans. *Clin Neurol Neurosurg* 2009;111:638-42.
2. Yamagami T, Nomura T, Imagawa K, et al. A case of cerebral cryptococcosis, with special reference to computerized tomography findings. *No Shinkei Geka* 1984; 12: 725-9.
3. Scalzini A, Castelnuovo F, Puoti M, Cristini G. A case of cryptococcal meningoencephalitis and focal cerebral vasculitis with transient immunodeficiency. *Acta Neurol (Napoli)* 1990;12:301-4.
4. Gologorsky Y, DeLaMora P, Souweidane MM, Greenfield JP. Cerebellar cryptococcoma in an immunocompetent child. Case report. *J Neurosurg* 2007;107:314-7.
5. Sloan D, Dlamini S, Paul N, et al. Treatment of acute cryptococcal meningitis in HIV infected adults, with an emphasis on resource-limited settings. *Cochrane Database Syst Rev* 2008 8:CD005647.
6. Saag MS, Graybill RJ, Larsen RA, et al. Practice guidelines for the management of cryptococcal disease. *Infectious Diseases Society of America. Clin Infect Dis* 2000; 30:710-8.
7. Carniato A, Scotton PG, Miotti AM, Mengoli C. *Cryptococcus neoformans* meningoencephalitis among apparently immunocompetent patients: description of two cases. *Infez Med* 2009;17:41-5.