


The similarities and differences between pleuroparenchymal fibroelastosis and idiopathic pulmonary fibrosis

Chronic Respiratory Disease
Volume 16: 1–9
© The Author(s) 2019
Article reuse guidelines:
sagepub.com/journals-permissions
DOI: 10.1177/1479973119867945
journals.sagepub.com/home/crd


Hiroshi Ishii¹ , Yoshiaki Kinoshita², Hisako Kushima³,
Nobuhiko Nagata¹ and Kentaro Watanabe⁴

Abstract

The idiopathic form of pleuroparenchymal fibroelastosis (PPFE) is categorized as a rare idiopathic interstitial pneumonia in the current classification. The majority of PPFE cases are idiopathic, but many predisposing factors or comorbidities have been reported. Although histological PPFE is predominantly located in the upper lobes, which are less often affected by fibrosis in patients with idiopathic pulmonary fibrosis (IPF), the clinical course of PPFE is seemingly similar to that of IPF. However, upper lobe fibroelastosis has various clinical and physiological characteristics that differ from those of IPF, including a flattened thoracic cage and a marked decrease in the forced vital capacity (FVC) but with a preserved residual volume. Compared with IPF, the decrease in the walking distance is mild despite the markedly decreased FVC in PPFE, and chest radiograph more frequently shows the elevation of bilateral hilar opacities with or without tracheal deviation. The prognosis may be related to the development of fibrosing interstitial pneumonia in the lower lobes with elevated levels of serum Krebs von den Lungen-6; however, there is marked variation in the pathogenesis and clinical features in PPFE. A proposal of the diagnostic criteria for idiopathic PPFE with and without surgical lung biopsy, which has recently been published, may be useful.

Keywords

Pleuroparenchymal fibroelastosis, idiopathic pulmonary fibrosis, clinical similarity, clinical difference, diagnostic criteria

Date received: 26 April 2019; accepted: 7 July 2019

Introduction

Pleuroparenchymal fibroelastosis (PPFE) was first reported by Frankel et al.,¹ who described five patients with pulmonary fibrosis predominantly involving the upper lobes. This disease was named according to its unique histology, and the idiopathic form is now listed as a rare idiopathic interstitial pneumonia (IIP) in the classifications of the American Thoracic Society and the European Respiratory Society.² Although histological PPFE is predominantly located in the upper lobes, which are less commonly affected by fibrosis in patients with idiopathic pulmonary fibrosis (IPF), the clinical course of PPFE

¹ Department of Respiratory Medicine, Fukuoka University Chikushi Hospital, Fukuoka, Japan

² Department of Pathology, Fukuoka University Hospital, Fukuoka, Japan

³ Department of Respiratory Medicine, Fukuoka University Hospital, Fukuoka, Japan

⁴ Department of Respiratory Medicine, Nishi Fukuoka Hospital, Fukuoka, Japan

Corresponding author:

Hiroshi Ishii, Department of Respiratory Medicine, Fukuoka University Chikushi Hospital, 1-1-1 Zokumyoin, Chikushino, Fukuoka 818-8502, Japan.
Email: hishii@fukuoka-u.ac.jp



Table 1. Patient background characteristics.

	PPFE	IPF
Age of onset, years old	20–80 years old	>50 years old
Gender	Male = female	Male > female
Genetic factor	Occasional	Not rare
Medical history, comorbidity	Recurrent respiratory infections, ^a treatment for malignancies, organ transplantations ^b	No specific diseases
Pneumothorax	Frequent	Occasional
Autoimmune diseases, autoantibodies	Rheumatoid arthritis, microscopic polyangiitis, ulcerative colitis, etc.	(Occasionally) rheumatoid factor, antinuclear antibody
Dust exposure	Asbestos, etc.	None
Smoking history	About 30%	>50%

PPFE: pleuroparenchymal fibroelastosis; IPF: idiopathic pulmonary fibrosis.

^aNontuberculous mycobacteriosis, aspergillosis, etc.

^bChemotherapy, radiotherapy.

progresses slowly and is similar to that of chronic fibrosing interstitial pneumonias, such as IPF. Since the report by Frankel et al.,¹ an increasing number of studies have examined PPFE and there is increased interest in the clinical similarities and differences between PPFE and IPF.

The aim of this review is to evaluate the similarities and differences between PPFE and IPF for further understanding of these diseases.

The similarities and differences between PPFE and IPF

Clinical background characteristics

1. Age of onset: The age at the onset in PPFE patients is wide-ranging (from 20s to 80s) and therefore dissimilar to IPF, which tends to affect older individuals. Young patients are predisposed to develop late-onset transplantation-associated PPFE when they undergo bone marrow transplantation due to hematopoietic disorders (Table 1).
2. Gender: Although more men are affected by IPF than women, there is no gender preponderance in PPFE. However, the number of reports on PPFE is relatively smaller at present than that of reports on IPF.
3. Genetic factor: Some investigators have reported PPFE in siblings^{1,3,4} and a pair of parents and their child,⁴ and PPFE with a family history of other pulmonary fibrosis has also been reported.^{5,6} Hereditary disposition may be responsible for the age at the onset in some patients with PPFE. IPF is idiopathic by

definition. However, genetic factors may not be rare in IPF,^{7,8} because a part of IPF cases are familial and even more present either hereditary or sporadic genetic mutations which seem to play a major role in the pathogenesis of the disease.^{9,10}

4. Medical history and comorbidities: Compared with IPF, throughout its long clinical course, PPFE patients can develop recurrent respiratory infections with progressive contraction of upper lobes. Although *Aspergillus* infection and *Mycobacterium* infection have been reported as causes of infection-related PPFE,^{6,11,12} whether the PPFE-like lesions are induced by these infections or latent PPFE creates suitable developmental conditions for these infectious agents is unclear. Respiratory infections, such as aspergillosis as an opportunistic infection, are also observed in the end stage of IPF.

It is well-known that PPFE can occur after bone marrow^{6,13,14} or lung transplantation,^{15,16} probably due to the chronic phase of graft-versus-host disease, administered alkylating agents, or chronic rejection. PPFE might be a special form of radiation injury, extending to nonirradiated areas to form irreversible pulmonary fibrosis. Hamada et al. reported a patient with cyclophosphamide-induced pulmonary fibrosis and elastosis with pleural thickening after treatment for breast cancer.¹⁷

5. Pneumothorax: Compared with IPF, many patients with PPFE experience recurrent pneumothorax. Multiple bullae in the upper lobe of the lung that appear in the course of

the disease may be torn and cause recurrent pneumothorax.

6. Autoimmune diseases and autoantibodies: Although IPF is idiopathic, ankylosing spondylitis,¹⁸ ulcerative colitis,¹⁹ and psoriasis²⁰ were previously reported as underlying diseases in PPFE. Pulmonary upper lobe fibrosis and cavitation in patients with rheumatoid diseases have also been reported.²¹ Pleuroparenchymal disease in collagen vascular disease might share common histological features with PPFE. Some reports^{1,6,22} have described positivity for rheumatoid factor and antinuclear antibody in patients with PPFE, suggesting the role of autoimmune mechanisms in the pathogenesis of the disease in some patients. Enomoto et al. reported that radiologic PPFE-like lesion in patients with connective tissue disease-related interstitial lung disease was not uncommon and was associated with poor prognosis.²³ In addition, we showed in a recent report²⁴ that a histological PPFE pattern was found in 12 of 24 patients with autoimmune disease-related interstitial lung disease (50%), and a histological PPFE pattern as the dominant pattern of fibrosis was found in 2 of the 24 patients (8%).
7. Dust exposure: Although IPF is idiopathic, occupational exposure to certain types of dust, such as asbestos or aluminum, is an important factor that induces PPFE.^{13,25–28} In general, pneumoconiosis, such as asbestosis, silicosis, and berylliosis, may present as upper lobe fibrosis, although the PPFE pattern has not been histologically demonstrated in these pneumoconioses. As the interstitial connective tissue response in asbestosis is fibroelastotic rather than fibrotic,²⁹ with pleural thickening, asbestos exposure might directly induce the pathology of PPFE.
8. Smoking history: Smoking does not appear to have any effect on the occurrence of PPFE. Previous studies^{1,4,6,11,13,20,22,25,27,28,30–34} indicated that the rate of current and former smokers was approximately 30% among PPFE patients and was over 50% among IPF patients, showing a marked difference between PPFE and IPF.

Clinical and laboratory findings

1. Clinical symptoms: Most patients with both PPFE and IPF present with a slow onset.

Table 2. Clinical and laboratory findings.

	PPFE	IPF
Pattern of onset	Slowly	Slowly
Early symptom	Exertional dyspnea, dry cough, chest pain	Exertional dyspnea, dry cough
Emaciation	Noticeable	Modest
Flat chest	Noticeable, progressive	None
Finger clubbing	Rare	Frequent
Fine crackles	About half cases	Most cases
Serum KL-6	Normal to slightly elevated	Elevated
Serum SP-D	Elevated	Elevated
Serum SP-A	Normal or elevated	Normal or elevated

PPFE: pleuroparenchymal fibroelastosis; IPF: idiopathic pulmonary fibrosis; KL-6: Krebs von den lungen-6; SP: surfactant protein.

However, the clinical characteristics should be separately discussed in idiopathic and secondary forms of PPFE. A considerable number of patients with PPFE have underlying diseases or conditions that might be relevant to its occurrence and development. The main symptoms in patients with PPFE and IPF are dry cough and exertional dyspnea. Such symptoms appear insidiously. Chest pain due to pneumothorax may be the first symptom in some patients with PPFE. Many patients with PPFE complain of weight loss (Table 2).

2. Physical findings: Compared with IPF, patients with PPFE are often associated with a slender stature.^{3,4,11,30,32,35} “Flattened thoracic cage” is also a characteristic physical finding in PPFE.^{3,33,36} A flattened thoracic cage is observed in patients with not only idiopathic PPFE but also secondary PPFE. A flattened thoracic cage, which may result from a congenital disposition or may be a secondary change of the thorax due to the shrinkage of the upper lung lobes through the long process of fibrosis, may inhibit the compliance of the lungs and the blood flow in the upper lobes, leading to a ventilation-perfusion imbalance.

Finger clubbing, which is often seen in patients with IPF, has been rarely reported in patients with PPFE.^{33,37}

A number of case studies of PPFE have reported that crackles are audible in about half or less than half of

patients,^{1,6,11,14,25–28,30–33,35,38} indicating that crackles are audible less frequently in PPFE than in IPF.

3. Laboratory findings: Krebs von den Lungen-6 (KL-6) is a reliable serum marker that is used for the diagnosis of interstitial lung diseases,^{39–41} such as IPF. Our recent report⁴² suggests that pulmonologists should be aware that the time course of the serum KL-6 levels in untreated patients with IPF is heterogeneous and can naturally decline in association with disease progression. Serum KL-6 is usually within the normal range or around the upper normal range limit in patients with PPFE.^{6,22,26,27,31–33,43} Histologically, PPFE is a fibrotic lung disease, but it is not an interstitial pneumonia, such as usual interstitial pneumonia (UIP) and nonspecific interstitial pneumonia (NSIP), in which KL-6 is highly expressed in the regenerated type II pneumocytes, migrating into the bloodstream.⁴¹ However, as the disease progresses, the level tends to increase in PPFE.^{11,43,44} UIP-like lesions may contribute to the increase in the serum levels of KL-6. We have reported that an elevated level of serum KL-6 was suggestive of a poor prognosis for patients with PPFE and that lower lung lesions were more frequently observed in non-survivors than in survivors of PPFE.³³ Serum surfactant protein D (SP-D) may be elevated in PPFE.^{22,33,37,43}

Physiology

1. Pulmonary function test: In both PPFE and IPF, forced vital capacity (FVC) and total lung capacity (TLC) are decreased, but the ratio of the forced expiratory volume in 1 second (FEV₁)/FVC is increased. Fibrotic collapse of the upper lobes leads to the compensatory overinflation of the lower lobes, resulting in an increased ratio of residual volume (RV)/TLC in PPFE,^{16,22,33,43} which is a characteristic functional impairment that is not usually seen in IPF. We showed that the RV/TLC ratio was significantly correlated with the gender, age and physiological variables (GAP) scores and negatively correlated with the FVC and body mass index (BMI).³³ This strongly suggests that the RV/TLC ratio increases with the progression of the disease and emaciation. We also demonstrated that such functional

Table 3. Pulmonary function test findings.

		PPFE	IPF
Spirometry	FVC	Decrease	Decrease
	FEV ₁ /FVC (%)	Increase	Increase
Lung volume fraction	TLC	Decrease	Decrease
	RV/TLC (%)	Increase	Immutable to decrease
Gas exchange capacity	DLco	Decrease	Decrease
Six-minute walk distance		Decrease	Marked decrease

PPFE: pleuroparenchymal fibroelastosis; IPF: idiopathic pulmonary fibrosis; FVC: forced vital capacity; FEV₁: forced expiratory volume in 1 second; TLC: total lung capacity; RV: residual volume; DLco: diffusing capacity for carbon monoxide.

abnormalities seemed to be related to the deformity of chest cage, that is, as the thoracic cage becomes flattened, the FVC decreases, but the RV/TLC increases (Table 3).^{33,36}

Gas exchange impairment also appears as a restrictive impairment. The diffusing capacity of carbon monoxide (DLco) is decreased. However, the diffusing capacity is normal or minimally reduced when DLco is divided by alveolar volume (DLco/VA).³⁷

2. Six-minute walk distance: Compared with the results for IPF reported by other investigators,^{45–47} the decrease in walking distance was mild despite the markedly decreased FVC.³³ Similarly, the lowest SpO₂ did not fall as extensively as it does in cases of IPF. Preserved alveolar structures in PPFE might be partly responsible for minimizing the decreased walking distance and SpO₂ during exercise. Furthermore, a slender body build might also contribute to the preservation of the walking capacity.⁴⁸

Radiology

1. Chest radiograph: In contrast to IPF, wherein lower lung field predominance reticular opacities are observed, irregularly thickened apical parts and reticular opacities appear in the bilateral upper lung fields in PPFE. Such a finding may be incidentally observed in a medical checkup for PPFE patients. Later, chest radiograph (Figure 1) more frequently shows the elevation of bilateral hilar opacities compared with IPF, with or without tracheal deviation.⁴⁹

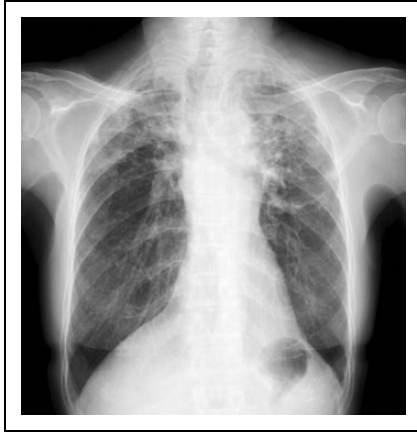

Figure 1. Representative chest radiograph of a PPFE patient (56-year-old woman) showing reticular opacities in the bilateral upper lung fields and the elevation of bilateral hilar opacities with a rightward deviation of the trachea. PPFE: pleuroparenchymal fibroelastosis.

A lateral view demonstrates an abnormally narrowed anterior–posterior thoracic dimension due to a flattened thoracic cage in PPFE (Table 4).

2. Chest computed tomography (CT): In patients with IPF, lower lung lobe and peripheral area predominance UIP pattern or probable UIP pattern⁵⁰ are observed. In patients with PPFE, multiple subpleural areas of airspace consolidation with traction bronchiectasis, subpleural nodular or reticular opacities in the lung parenchyma are found in upper lung lobes bilaterally, but changes in the middle and lower lobes are minimal (Figure 2). In the early phases of PPFE, the disease may be not distinguishable from pulmonary apical cap or fibroelastic scar in high-resolution computed tomography (HRCT). A follow-up imaging is therefore pivotal in these patients. As the disease progresses, the opacities

described above extend to the adjacent lobes. At the advanced stage of PPFE, fibrotic shadows extend to the lower lung fields, and the diaphragm is elevated with the loss of the bilateral lung volume. Multiple bullae and cystic lesion often appear in the upper lung fields, which may be responsible for pneumothorax and allow *Aspergillus* infection. Isolated reticular opacities or honeycombing sometimes appear in the subpleural areas of lower lobes, which raises the possibility of the combination of PPFE with other patterns of interstitial pneumonia.^{6,11,16,33}

Histology

PPFE is histologically characterized by subpleural fibrosis with a mixture of elastic tissue and dense collagen but without the architectural distortion frequently seen in IPF.¹ In other words, mainly in the upper lobes, there is alveolar collapse with subpleural atelectatic induration and the proliferation of elastosis and intraluminal organization or intra-alveolar fibrosis with or without fibrously thickened pleura. Such pathological features of PPFE are totally different from those of IPF. However, the histology patterns in the lower lobes range from PPFE, UIP, to histologically unclassifiable interstitial pneumonia.³³ In addition, our recent work has demonstrated that IPF occasionally shows intense elastosis in the upper lobes, based on whole-slide image analysis using the specimens of autopsy or pneumonectomy for lung transplantation.⁵¹ Such cases are histologically indistinguishable from PPFE, suggesting that there may be histologically borderline cases of PPFE and IPF (Table 5).

PPFE patterns are identified in the upper lungs without difficulty on both CT images and in histology specimens; in contrast, the lower lungs have

Table 4. Chest imaging findings.

	PPFE	IPF
Distribution	Upper field predominance	Lower field predominance
Upward shift of hilar structures	Frequent	None to occasional
Tracheal deviation	Frequent	Sometimes
HRCT pattern		
Upper lung field	Multiple subpleural areas of airspace consolidation with traction bronchiectasis	None or nonspecific change
Lower lung field	None, PPFE, or other patterns	UIP pattern or probable UIP pattern

PPFE: pleuroparenchymal fibroelastosis; IPF: idiopathic pulmonary fibrosis; HRCT: high-resolution computed tomography; UIP: usual interstitial pneumonia.

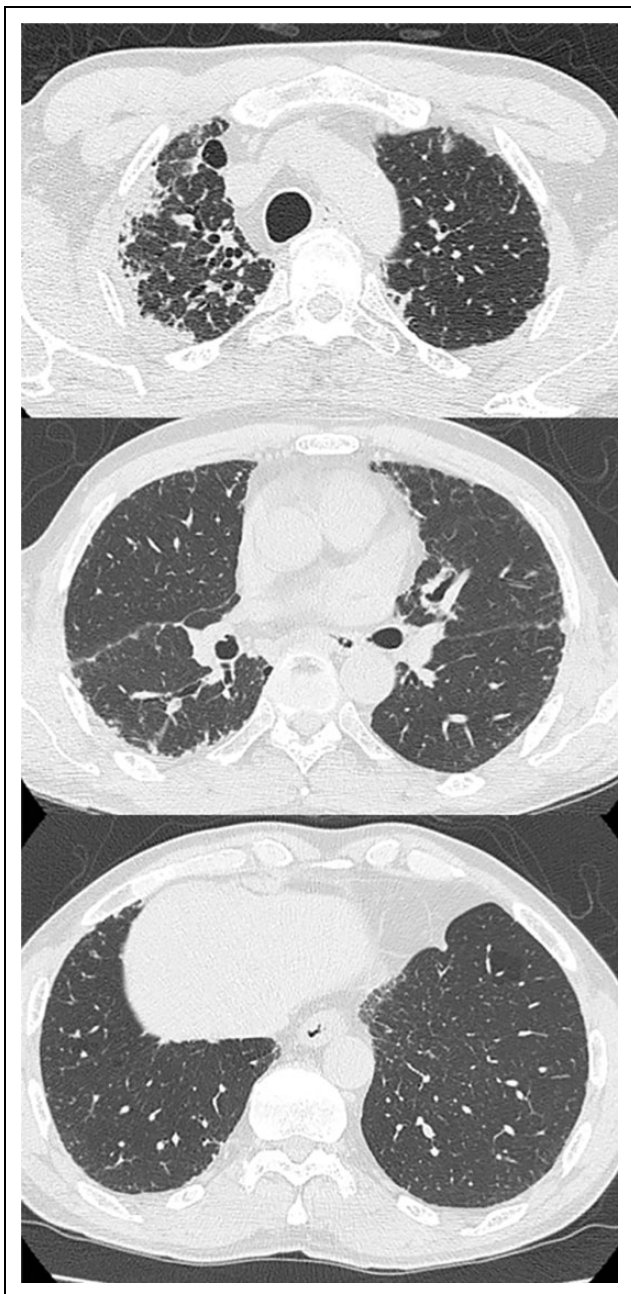

Figure 2. Representative chest CT scans of a PPFE patient (45-year-old man) showing subpleural airspace consolidation and reticular opacities predominantly in the upper lung lobes. PPFE: pleuroparenchymal fibroelastosis; CT: computed tomography.

complicated imaging findings and histology patterns. In the lower lungs, there are borderline patterns difficult to classify as simply UIP or PPFE on CT and histology specimens.⁵¹ Based on our observations over the years, we suspect that the progression of PPFE in the lower lungs largely depends on newly developed chronic fibrosing IP, UIP, or non-UIP,

Table 5. Histological findings.

	PPFE	IPF
Distribution	Upper field predominance	Lower field predominance
Histological pattern	Subpleural fibrosis with a mixture of elastic tissue and dense collagen, with/without UIP or other patterns of pulmonary fibrosis	UIP pattern
Lung architecture	Intact architecture	Architectural distortion
Old fibrosis	Septal elastosis and intra-alveolar collagenous fibers	Fibrotic scar and honeycombing consisting of collagenous fibers
Fibroblastic focus	None or minor	Major
Pleural lesion	None or thickening	None

PPFE: pleuroparenchymal fibroelastosis; IPF: idiopathic pulmonary fibrosis; UIP: usual interstitial pneumonia.

rather than on the progression of histological PPFE itself. As shown in Table 5, the distinctive trait of UIP is the fibroblastic focus with destructive fibrosis which is absent in PPFE. It would be interesting to search for these characteristics in the lower lobe fibrosis in patient with upper lobe fibrosis consistent with PPFE. It is probable that a rapid progression actually caused by a UIP in the lower lobe, therefore reducing the weight of PPFE.

Treatment and the prognosis

Idiopathic PPFE is usually slowly progressive and refractory to steroids or immunosuppressive agents. Antifibrotic agents for IPF, such as pirfenidone and nintedanib, seem useless or do not meet the indication of PPFE. In the advanced stage of PPFE, home oxygen therapy is necessary if the patient is hypoxemic, and infection control is important, as in IPF. Targeting the inhibition of elastosis instead of collagenosis might represent a novel therapeutic avenue in PPFE.

Previous reports found the median survival of patients with PPFE to be 7.3–11 years.^{16,33} This seems to be longer than that of IPF in Japan.⁵² However, disease progression of PPFE is highly variable: some patients show rapid progression,¹¹ while others have slow progression of 10–20 years following

clinical presentation.^{3,16} This might be caused by the varying underlying conditions or comorbidities or by coexisting fibrosing IP.

Conclusion

The clinical course of PPFE is seemingly similar to that of IPF. However, the clinical and physiological characteristics of upper lobe fibroelastosis differ from those of IPF, including a flattened thoracic cage and a marked decrease in the FVC but with a preserved RV. Compared with IPF patients, finger clubbing is uncommon and the decrease in the walking distance is mild despite the markedly decreased FVC in PPFE patients. The prognosis may be related to the development of fibrosing interstitial pneumonia in the lower lobes; however, there is marked variation in the pathogenesis and clinical features of PPFE.

The diagnostic criteria for IPF have been recently updated,⁵⁰ and cases presenting with typical UIP pattern on HRCT can be clinically diagnosed without a surgical lung biopsy (SLB). Although the current diagnostic criteria for PPFE are based on the histological findings by an SLB, we have few chances to perform an SLB for the diagnosis of PPFE. Our proposal concerning the criteria for the diagnosis of idiopathic PPFE with and without an SLB has recently been published.⁵³ Imaging criteria and physiological criteria using the RV/TLC and BMI are expected to be useful for discriminating idiopathic PPFE from a group of chronic IIPs when an SLB cannot be performed.

Acknowledgments

The authors would like to thank Dr Brian Quinn (Japan Medical Communication Inc.) for revising the English of this manuscript.


Declaration of conflicting interests

The author(s) declared no potential conflicts of interest with respect to the research, authorship, and/or publication of this article.

Funding

The author(s) received no financial support for the research, authorship, and/or publication of this article.

ORCID iD

Hiroshi Ishii  <https://orcid.org/0000-0002-2143-5922>

References

1. Frankel SK, Cool CD, Lynch DA, et al. Idiopathic pleuroparenchymal fibroelastosis: description of a novel clinicopathologic entity. *Chest* 2004; 126(6): 2007–2013.
2. Travis WD, Costabel U, Hansell DM, et al. An official American Thoracic Society/European Respiratory Society statement: update of the international multidisciplinary classification of the idiopathic interstitial pneumonias. *Am J Respir Crit Care Med* 2013; 188(6): 733–748.
3. Amitani R, Niimi A, and Kuse F. Idiopathic pulmonary upper lobe fibrosis. *Kokyu* 1992; 11: 693–699.
4. Shiota S, Shimizu K, Suzuki M, et al. Seven cases of marked pulmonary fibrosis in the upper lobe. *Nihon Kokyuki Gakkai Zasshi* 1999; 37(2): 87–96.
5. Kobayashi Y, Sakurai M, Kushiya M, et al. Idiopathic pulmonary fibrosis of the upper lobe: a case report. *Nihon Kokyuki Gakkai Zasshi* 1999; 37(10): 812–816.
6. Reddy TL, Tominaga M, Hansell DM, et al. Pleuroparenchymal fibroelastosis: a spectrum of histopathological and imaging phenotypes. *Eur Respir J* 2012; 40(2): 377–385.
7. Raghu G, Collard HR, Egan JJ, et al. An official ATS/ERS/JRS/ALAT statement: idiopathic pulmonary fibrosis: evidence-based guidelines for diagnosis and management. *Am J Respir Crit Care Med* 2011; 183(6): 788–824.
8. Daniil Z, Kotsiou OS, Grammatikopoulos A, et al. Detection of mitochondrial transfer RNA (mt-tRNA) gene mutations in patients with idiopathic pulmonary fibrosis and sarcoidosis. *Mitochondrion* 2018; 43: 43–52.
9. Leslie KO, Cool CD, Sporn TA, et al. Familial idiopathic interstitial pneumonia: histopathology and survival in 30 patients. *Arch Pathol Lab Med* 2012; 136(11): 1366–1376.
10. Nathan N, Giraud V, Picard C, et al. Germline SFTPA1 mutation in familial idiopathic interstitial pneumonia and lung cancer. *Hum Mol Genet* 2016; 25(8): 1457–1467.
11. Watanabe K, Nagata N, Kitasato Y, et al. Rapid decrease in forced vital capacity in patients with idiopathic pulmonary upper lobe fibrosis. *Respir Investig* 2012; 50(3): 88–97.
12. Kushima H, Ishii H, Kinoshita Y, et al. Chronic pulmonary aspergillosis with pleuroparenchymal fibroelastosis-like features. *Intern Med* 2019; 58(8): 1137–1140.

13. Becker CD, Gil J, and Padilla ML. Idiopathic pleuroparenchymal fibroelastosis: An unrecognized or misdiagnosed entity? *Mod Pathol* 2008; 21(6): 784–787.
14. von der Thusen JH, Hansell DM, Tominaga M, et al. Pleuroparenchymal fibroelastosis in patients with pulmonary disease secondary to bone marrow transplantation. *Mod Pathol* 2011; 24(12): 1633–1639.
15. Hirota T, Fujita M, Matsumoto T, et al. Pleuroparenchymal fibroelastosis as a manifestation of chronic lung rejection? *Eur Respir J* 2013; 41(1): 243–245.
16. Yoshida Y, Nagata N, Tsuruta N, et al. Heterogeneous clinical features in patients with pulmonary fibrosis showing histology of pleuroparenchymal fibroelastosis. *Respir Investig* 2016; 54(3): 162–169.
17. Hamada K, Nagai S, Kitaichi M, et al. Cyclophosphamide-induced late-onset lung disease. *Intern Med* 2003; 42(1): 82–87.
18. Davies D. Ankylosing spondylitis and lung fibrosis. *Q J Med* 1972; 41(164): 395–417.
19. Singh R, Sundaram P, and Joshi JM. Upper lobe fibrosis in ulcerative colitis. *J Assoc Physicians India* 2003; 51: 515–517.
20. Bourke S, Campbell J, Henderson AF, et al. Apical pulmonary fibrosis in psoriasis. *Br J Dis Chest* 1988; 82(4): 444–446.
21. Petrie GR, Bloomfield P, Grant IW, et al. Upper lobe fibrosis and cavitation in rheumatoid disease. *Br J Dis Chest* 1980; 74(3): 263–267.
22. Kusagaya H, Nakamura Y, Kono M, et al. Idiopathic pleuroparenchymal fibroelastosis: consideration of a clinicopathological entity in a series of Japanese patients. *BMC Pulm Med* 2012; 12: 72.
23. Enomoto Y, Nakamura Y, Colby TV, et al. Radiologic pleuroparenchymal fibroelastosis-like lesion in connective tissue disease-related interstitial lung disease. *PLoS One* 2017; 12(6): e0180283.
24. Kinoshita Y, Watanabe K, Ishii H, et al. Pleuroparenchymal fibroelastosis as a histological background of autoimmune diseases. *Virchows Arch* 2019; 474(1): 97–104.
25. Davies D, Crowther JS, and MacFarlane A. Idiopathic progressive pulmonary fibrosis. *Thorax* 1975; 30(3): 316–325.
26. Kaneko Y, Kikuchi N, Ishii Y, et al. Upper lobe-dominant pulmonary fibrosis showing deposits of hard metal component in the fibrotic lesions. *Intern Med* 2010; 49(19): 2143–2145.
27. Inuzuka K, Yasui M, Waseda Y, et al. A case of repeated bilateral pneumothorax associated with upper lobe predominant fibrosis in an aluminum processing worker. *Nihon Kokyuki Gakkai Zasshi* 2010; 48(7): 492–496.
28. Piciocchi S, Tomassetti S, Casoni G, et al. High resolution CT and histological findings in idiopathic pleuroparenchymal fibroelastosis: features and differential diagnosis. *Respir Res* 2011; 12: 111.
29. Wick MR, Kendall TJ, and Ritter JH. Asbestosis: demonstration of distinctive interstitial fibroelastosis: a pilot study. *Ann Diagn Pathol* 2009; 13(5): 297–302.
30. Fuke S, Betsuyaku T, Oizumi S, et al. A case of idiopathic pulmonary upper lobe fibrosis complicated by invasive pulmonary aspergillosis. *Nihon Kokyuki Gakkai Zasshi* 2003; 41(3): 196–201.
31. Nei T, Kawamoto M, Satoh E, et al. A case of suspected idiopathic pulmonary upper lobe fibrosis (Ami-tani disease) with acute exacerbation. *Nihon Kokyuki Gakkai Zasshi* 2009; 47(2): 116–121.
32. Morimoto A, Mochizuki Y, Nakahara Y, et al. Case of idiopathic pulmonary upper lobe fibrosis. *Nihon Kokyuki Gakkai Zasshi* 2010; 48(12): 944–949.
33. Ishii H, Watanabe K, Kushima H, et al. Pleuroparenchymal fibroelastosis diagnosed by multidisciplinary discussions in Japan. *Respir Med* 2018; 141: 190–197.
34. Ryu JH, Colby TV, Hartman TE, et al. Smoking-related interstitial lung diseases: a concise review. *Eur Respir J* 2001; 17(1): 122–132.
35. Nagashima O, Matsuno K, Tominaga S, et al. Esophageal diverticulum with idiopathic pulmonary upper lobe fibrosis. *Intern Med* 2013; 52(1): 159.
36. Harada T, Yoshida Y, Kitasato Y, et al. The thoracic cage becomes flattened in the progression of pleuroparenchymal fibroelastosis. *Eur Respir Rev* 2014; 23(132): 263–266.
37. Watanabe K. Pleuroparenchymal Fibroelastosis: its clinical characteristics. *Curr Respir Med Rev* 2013; 9: 229–237.
38. A case of idiopathic cavitation of lung demonstrated at the Postgraduate Medical School of London. *Br Med J* 1966; 1(5483): 345–348.
39. Yokoyama A, Kohno N, Hamada H, et al. Circulating KL-6 predicts the outcome of rapidly progressive idiopathic pulmonary fibrosis. *Am J Respir Crit Care Med* 1998; 158(5 Pt 1): 1680–1684.
40. Yokoyama A, Kondo K, Nakajima M, et al. Prognostic value of circulating KL-6 in idiopathic pulmonary fibrosis. *Respirology* 2006; 11(2): 164–168.
41. Ishikawa N, Hattori N, Yokoyama A, et al. Utility of KL-6/MUC1 in the clinical management of interstitial lung diseases. *Respir Investig* 2012; 50(1): 3–13.

42. Ishii H, Kushima H, Kinoshita Y, et al. The serum KL-6 levels in untreated idiopathic pulmonary fibrosis can naturally decline in association with disease progression. *Clin Respir J* 2018; 12(9): 2411–2418.
43. Watanabe S, Waseda Y, Takato H, et al. Pleuroparenchymal fibroelastosis: distinct pulmonary physiological features in nine patients. *Respir Investig* 2015; 53(4): 149–155.
44. Enomoto Y, Nakamura Y, Satake Y, et al. Clinical diagnosis of idiopathic pleuroparenchymal fibroelastosis: a retrospective multicenter study. *Respir Med* 2017; 133: 1–5.
45. Eaton T, Young P, Milne D, et al. Six-minute walk, maximal exercise tests: reproducibility in fibrotic interstitial pneumonia. *Am J Respir Crit Care Med* 2005; 171(10): 1150–1157.
46. Flaherty KR, Andrei AC, Murray S, et al. Idiopathic pulmonary fibrosis: prognostic value of changes in physiology and six-minute-walk test. *Am J Respir Crit Care Med* 2006; 174(7): 803–809.
47. Mura M, Ferretti A, Ferro O, et al. Functional predictors of exertional dyspnea, 6-min walking distance and HRCT fibrosis score in idiopathic pulmonary fibrosis. *Respiration* 2006; 73(4): 495–502.
48. Enright PL and Sherrill DL. Reference equations for the six-minute walk in healthy adults. *Am J Respir Crit Care Med* 1998; 158(5 Pt 1): 1384–1387.
49. Ishii H, Kinoshita Y, Kushima H, et al. The upward shift of hilar structures and tracheal deviation in pleuroparenchymal fibroelastosis. *Multidiscip Respir Med* 2019; 14: 10.
50. Raghu G, Remy-Jardin M, Myers JL, et al. Diagnosis of Idiopathic pulmonary fibrosis. An official ATS/ERS/JRS/ALAT clinical practice guideline. *Am J Respir Crit Care Med* 2018; 198(5): e44–e68.
51. Kinoshita Y, Watanabe K, Ishii H, et al. Proliferation of elastic fibres in idiopathic pulmonary fibrosis: a whole-slide image analysis and comparison with pleuroparenchymal fibroelastosis. *Histopathology* 2017; 71(6): 934–942.
52. Bando M, Sugiyama Y, Azuma A, et al. A prospective survey of idiopathic interstitial pneumonias in a web registry in Japan. *Respir Investig* 2015; 53(2): 51–59.
53. Watanabe K, Ishii H, Kiyomi F, et al. Criteria for the diagnosis of idiopathic pleuroparenchymal fibroelastosis: a proposal. *Respir Investig* 2019; 57(4): 312–320.