

POSTER PRESENTATION

Open Access

Comprehensive characterization of cardiac morphology and function in adult patients with phenylketonuria using CMR

Jan-Hendrik Hassel¹, Nikolaus Tilling², Lenka Bosanska², Bernhard Schnackenburg³, Daniel Messroghli¹, Alexander Berger¹, Rolf Gebker¹, Christopher Schneeweis¹, Eckart Fleck¹, Ursula Plöckinger², Sebastian Kelle^{1*}

From 17th Annual SCMR Scientific Sessions
 New Orleans, LA, USA. 16-19 January 2014

Background

Phenylketonuria (PKU) is one of the most common inherited metabolic disorders. The molecular pathway of neurological damage is not yet sufficiently understood. To date, there is a lack information about cardiac involvement related to the disease. This study aims to characterize cardiac morphology and function in adult patients with PKU using cardiovascular magnetic resonance (CMR).

Methods

28 patients with PKU (age 30 ± 9 years/mean \pm SD) underwent a comprehensive CMR protocol at a 1.5T CMR scanner (Philips, Achieva) including assessment of left ventricular (LV) volume and mass. In addition, T1 measurements pre- and post-administration of gadolinium for evaluation of extra corporeal volume (ECV) and tagging for quantitative analysis of left ventricular circumferential strain (Ecc) were performed. 8 healthy age-matched volunteers underwent a similar protocol and served as

controls for the ECV values. LV parameters and Ecc were compared to reference values from previous studies with similar data setup [1-3].

Results

CMR exams were successfully performed in all patients. As shown in Figure 1 LV mass index was reduced to the lower 95% confidence interval of the reference values [4,5] in each subgroup. ECV showed no significant difference between PKU patients (0.27 ± 0.03 /mean \pm SD) and the control group (0.28 ± 0.02 /mean \pm SD) (Figure 2) $p = 0.15$. PKU patients had higher Ecc values ($= -0.22\%$) compared to reference values (Ecc = -0.20%) with similar segmental patterns.

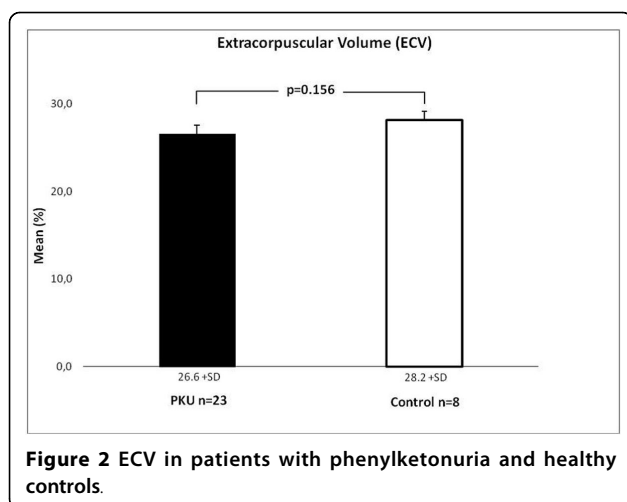
Conclusions

The results of this study indicate that in PKU patients compared to healthy controls LV mass indexed to BSA is reduced to the reference values; we found increased

Tbl.1	N	EDVI LV [ml/m ²]	Reference Range	ESVI LV [ml/m ²]	Reference Range	SVI LV [ml/m ²]	Reference Range	Mass Index LV [g/m ²]	Reference Range
F 20-29	6	88.53 $\pm 23,32$	82 (65-99)	35.74 $\pm 11,50$	28 (19-37)	52.79 $\pm 13,40$	54 (42-66)	44.25 $\pm 7,43$	62 (47-77)
F 30-39	5	74.98 $\pm 11,19$	79 (62-96)	33.39 $\pm 4,43$	27 (17-36)	41.59 $\pm 7,59$	53 (40-65)	36.05 $\pm 6,43$	62 (47-77)
F 40-49	3	90.31 $\pm 2,43$	76 (59-93)	34.63 $\pm 6,29$	25 (16-34)	55.68 $\pm 3,86$	51 (39-63)	42.96 $\pm 6,73$	63 (48-77)
M 20-29	7	88.69 $\pm 13,40$	86 (68-103)	42.28 $\pm 5,53$	30 (19-41)	46.41 $\pm 8,91$	56 (44-68)	50.05 $\pm 11,27$	76 (59-93)
M 30-39	5	87.90 $\pm 17,62$	83 (66-101)	40.40 $\pm 10,84$	29 (18-39)	47.51 $\pm 8,06$	55 (43-67)	41.47 $\pm 10,35$	75 (59-92)
M 40-49	2	75.90 $\pm 7,45$	81 (64-99)	38.44 $\pm 4,53$	27 (17-38)	37.45 $\pm 2,92$	54 (42-66)	33.08 $\pm 11,05$	75 (58-91)
F=female M=male		mean \pm SD	mean (95% confidence interval)	mean \pm SD	mean (95% confidence interval)	mean \pm SD	mean (95% confidence interval)	mean \pm SD	mean (95% confidence interval)

Figure 1 left ventricular mass index (LVMI) in patients with phenylketonuria separated after age and sex.

¹Cardiology, German Heart Institute Berlin, Berlin, Germany
 Full list of author information is available at the end of the article



average Ecc parameters and normal ECV values. Further investigations in larger patient groups and older PKU patients are necessary for evaluation of cardiac involvement of the disease over time and its consequences.

Funding

None.

Authors' details

¹Cardiology, German Heart Institute Berlin, Berlin, Germany. ²Interdisziplinäres Stoffwechsel-Centrum, Charité-Universitätsmedizin Berlin, Campus Virchow-Klinikum, Berlin, Germany. ³Philips Healthcare Systems, Hamburg, Germany.

Published: 16 January 2014

References

1. Kuijjer, et al: Three-dimensional myocardial strains at end-systole and during diastole in the left ventricle of normal humans. *J Cardiovasc Magn Reson* 2002, **4**(3):341-351.
2. Moore, et al: Three-dimensional systolic strain patterns in the normal human left ventricle: characterization with tagged MR imaging. *In Radiology* 2000, **214**(2):453-466.
3. Young, et al: Three-dimensional left ventricular deformation in hypertrophic cardiomyopathy. *In Circulation* 1994, **90**(2):854-867.
4. Maceira, et al: Normalized left ventricular systolic and diastolic function by steady state free precession cardiovascular magnetic resonance. *In J Cardiovasc Magn Reson* 2006, **8**(3):417-426.
5. Maceira, et al: Reference right ventricular systolic and diastolic function normalized to age, gender and body surface area from steady-state free precession cardiovascular magnetic resonance. *In Eur Heart J* 2006, **27**(23):2879-2888.

doi:10.1186/1532-429X-16-S1-P246

Cite this article as: Hassel et al.: Comprehensive characterization of cardiac morphology and function in adult patients with phenylketonuria using CMR. *Journal of Cardiovascular Magnetic Resonance* 2014 **16**(Suppl 1):P246.

Submit your next manuscript to BioMed Central and take full advantage of:

- Convenient online submission
- Thorough peer review
- No space constraints or color figure charges
- Immediate publication on acceptance
- Inclusion in PubMed, CAS, Scopus and Google Scholar
- Research which is freely available for redistribution

Submit your manuscript at
www.biomedcentral.com/submit

