

Intravitreal Bevacizumab (Avastin) as an Adjuvant Therapy for Choroidal Carcinoid Metastasis

Saeed Karimi¹, Amir Arabi¹, Toktam Shahraki¹

¹Ophthalmic Research Center, Shahid Beheshti University of Medical Sciences, Torfe Medical Center, Tehran, Iran

Abstract

Purpose: To report a case of choroidal carcinoid metastasis with neovascularization of the optic disc and macular edema that was treated with three sessions of intravitreal anti-vascular endothelial growth factor (anti-VEGF) as an adjuvant therapy with photodynamic therapy (PDT).

Methods: A 16-year-old patient with a diagnosis of lung carcinoid tumor presented to an ophthalmology clinic with a complaint of decreased vision in his right eye. Fundus examination revealed choroidal carcinoid metastasis in addition to neovascularization of the optic disc. Macular optical coherence tomography revealed cystoid macular edema and subretinal fluid. The patient was treated with PDT in addition to three sessions of intravitreal anti-VEGF injections.

Results: Following the treatment, the new vessels regressed, and visual acuity improved. Furthermore, central retinal thickness reduced significantly. The tumor size reduced significantly over a follow-up period of 6 weeks.

Conclusion: Choroidal carcinoid metastasis may be complicated by neovascularization of optic disc, which responds favorably to intravitreal injections of bevacizumab.

Keywords: Carcinoid, Choroidal metastasis, Vascular endothelial growth factors

Address for correspondence: Amir Arabi, Number 22, 17 Eastern Alley, Northern Sarafha Street, Saadat-Abad, Tehran, Iran.

E-mail: amir_arab_91@yahoo.com

Submitted: 06-Nov-2019; **Revised:** 26-Feb-2020; **Accepted:** 02-Mar-2020; **Published:** 12-Dec-2020

INTRODUCTION

Carcinoid tumors arise from neuroendocrine cells generally from the lungs or gastrointestinal (GI) tract.¹ Carcinoid tumor is linked to ophthalmology as the tumors can metastasize to the eye and orbit. Nowadays, it is clearly understood that GI tumors characteristically metastasize to the orbit, whereas those originating from the lungs prefer the uveal tract, mainly the choroid, followed by the iris and ciliary body.²

Previous studies have indicated the role of several growth factor families in carcinoid development and progression, including vascular endothelial growth factor (VEGF).³ In a study by Zhang *et al.*, the secretion of VEGF in carcinoid tumors was confirmed.³ According to their findings and present knowledge, we know that carcinoid tumors secrete

VEGFs, and the issue may be correlated with aggressiveness of the disease.⁴

The chief ophthalmoscopy finding in ocular metastases is choroidal amelanotic masses, which can be seen in multiple sites and bilaterally. Herein, we report a unique case of choroidal carcinoid metastasis, where in addition to typical metastatic choroidal mass, neovascularization of the optic disc was the prominent finding on ophthalmoscopy. As it can be related to VEGF secretion from the tumor, we will report the effect of multiple intravitreal injections of anti-VEGFs as adjuvant therapy on neovascularization of optic disc, subretinal fluid (SRF) improvement, and decrease in tumor size.

Access this article online

Quick Response Code:



Website:
www.jcurrophthalmol.org

DOI:
10.4103/JOCO.JOCO_54_20

This is an open access journal, and articles are distributed under the terms of the Creative Commons Attribution-NonCommercial-ShareAlike 4.0 License, which allows others to remix, tweak, and build upon the work non-commercially, as long as appropriate credit is given and the new creations are licensed under the identical terms.

For reprints contact: WKHLRPMedknow_reprints@wolterskluwer.com

How to cite this article: Karimi S, Arabi A, Shahraki T. Intravitreal bevacizumab (Avastin) as an adjuvant therapy for choroidal carcinoid metastasis. *J Curr Ophthalmol* 2020;32:420-2.

CASE REPORT

A 16-years-old Persian male presented to our medical center with a complaint of decreased visual acuity from 2 months earlier. The patient was a known case of bronchial carcinoid for 7 months ago, and he had been treated with systemic octreotide. The patient denied receiving any other systemic drug, including systemic bevacizumab. He had no history of any other medical or ocular condition, and no family history for the ocular disease was detected. Ophthalmic examination showed a corrected distance visual acuity of 6/10 in the right eye and 10/10 in the left eye. Intraocular pressure was normal and relative afferent pupillary defect was negative. Anterior segment examinations were normal. On funduscopy, there was a white-yellowish elevated choroidal mass in the right eye associated with a prominent optic disc neovascularization and cystoid macular edema in the same eye [Figures 1 and 2]. A smaller mass was found in the left eye. On fluorescein angiography, there were well-defined hyperfluorescent zones around superior vascular arcade of the right eye in favor of new vessels, associated with late-phase leakage from the abnormal vessels. Metastatic mass was seen as a round hypofluorescent lesion, and no sign of capillary non-perfusion was seen on angiogram [Figure 1]. On macular optical coherence tomography, SRF was detected in the right eye.

According to the clinical examination and patient's history, supported by ancillary tests results, the patient was diagnosed with choroidal carcinoid metastasis, associated with optic disc neovascularization and macular edema. He was treated with three monthly intravitreal anti-VEGF factor (bevacizumab) injections in the right eye and photodynamic therapy (PDT) with standard-fluence PDT (83 s; 50 J/cm) using verteporfin for metastatic masses of both the eyes. The PDT was performed

2 days after the first visit, and the first injection was done within a week from the diagnosis. During the follow-up period, systemic therapeutic regimen of the patient did not change by the oncology service. Six weeks after the completion of the treatment, neovascularization of the optic disc was regressed, and SRF was absorbed, causing improvement of central visual acuity to 8/10 in the right eye. In addition, the size of the metastatic tumor was dramatically reduced [Figure 2]. On a 6-month follow-up examination, there was no recurrence of neovascularization and macular edema, and the metastatic tumor base diameter remained to be near 1.5 disc diameter with a thickness of <1.5 mm. It is notable that the consent form was obtained from the patient to publish his clinical data and documents.

DISCUSSION

Ocular screening is not regularly done to search for carcinoid metastasis to the eye. However, it should be considered in any carcinoid tumor patient with visual symptoms.⁵ Bronchoalveolar system is the most common localization of the carcinoid tumor with metastasis to the uveal tract, while such metastases from a mediastinal carcinoid are rare.⁶ It has been assumed that 2.2% of the uveal tract metastases belong to carcinoid tumors.⁷ Appropriate diagnosis might be supportive in conserving the eyes and improving the quality of life through the improvement of visual acuity,⁸ where external-beam radiotherapy and proton-beam irradiation, photocoagulation, and brachytherapy have been used to treat choroidal carcinoid metastasis.^{9,10}

There are a few reports about PDT for choroidal carcinoid metastasis. In 2004, following no response to external-beam radiation and chemotherapy, PDT resulted in a 33% and

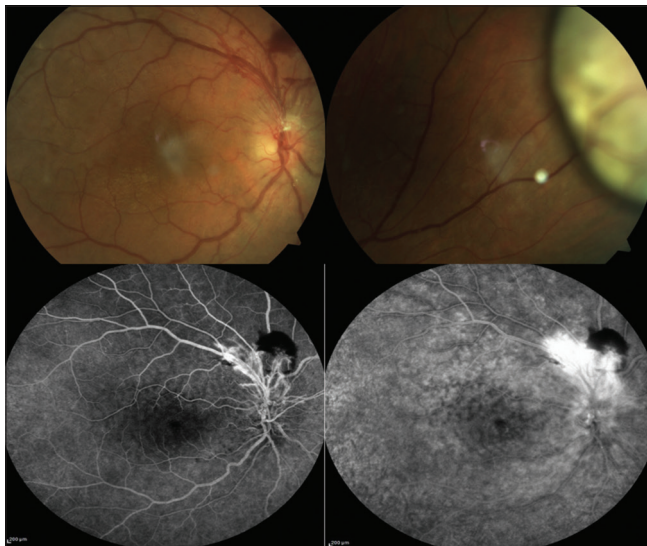


Figure 1: Upper row. Color fundus photo of posterior pole of the right eye (right). Note new vessels near the optic disc. Amelanotic carcinoid metastatic mass in the right eye (left). Lower row. Early phase (left) and late phase (right) of fundus angiogram revealing neovascularization with leakage

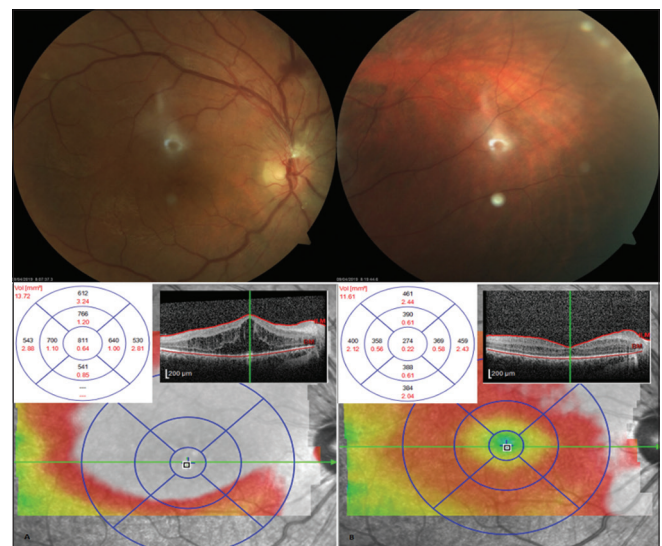


Figure 2: Upper row. After treatment with photodynamic therapy and three intravitreal bevacizumab injections, neovascularization of the optic disc regressed (left), and the size of the tumor decreased (right). Lower row. En-face and cross-sectional macular optical coherence tomography images show absorption of macular edema after treatment

25% reduction in basal diameter and thickness of the mass, respectively, as well as a resolution of SRF and improvement of visual acuity.¹¹ In 2013, primary PDT for the treatment of carcinoid metastasis resulted in a reduction in tumor size.⁸ In 2018, as a secondary treatment after external-beam radiotherapy and somatostatin analog, PDT improved the visual acuity, mainly through the absorption of SRF.¹² According to the present literature, the mean time of response onset following PDT for carcinoid choroidal metastasis has not been determined. In the last report published about the PDT as the primary treatment of ocular carcinoid metastasis, on a 1-year follow-up, the treated metastasis showed a 50% reduction in thickness.¹³

Carcinoid tumors are well known to express VEGF, and the expression in resected tumors has also been shown to correlate with metastases and poor prognosis.⁴ Furthermore, in the same study, it has been found that anti-VEGF therapy results in a more notable reduction of tumor blood flow and objective tumoral response than other methods.⁴

In our case, in addition to predictable findings of amelanotic choroidal lesions in favor of metastatic nature of ocular involvement, there was a prominent neovascularization in the optic disc. According to the findings mentioned above, choroidal carcinoid metastases, following their origin and nature, can produce VEGF. Elevation of this pro-angiogenic factor in ocular circulation can potentially cause formation of new abnormal vessels in the retina. Accordingly, added to the PDT, three sessions of monthly intravitreal bevacizumab (IVB), with a dosage of 1.25 mg, were included in the management of the patient.

According to our knowledge, choroidal carcinoid metastasis with prominent neovascularization of optic disc has not been reported in literature. Furthermore, intravitreal anti-VEGF agents have been used occasionally for ocular carcinoid, mostly with the purpose of accelerating absorption of SRF.¹³ Herein, we used three scheduled injections of IVB, as an adjuvant therapy for carcinoid choroidal metastasis, added to PDT. The therapy resulted in the regression of neovascularization, absorption of SRF, and dramatic decrease in tumor size, and all these happened over a period of 6 weeks after the third IVB.

In conclusion, we reported a case of carcinoid choroidal metastasis treated primarily with PDT and multiple IVB injections, where in addition to regression of new vessels and absorption of SRF, the treatment caused a significant reduction in tumor size, over a period time shorter than those reported in previous cases treated with PDT.

Declaration of patient consent

The authors certify that they have obtained all appropriate patient consent forms. In the form, the legal guardian has given his consent for images and other clinical information to be reported in the journal. The guardian understands that names and initials will not be published and due efforts will be made to conceal identity, but anonymity cannot be guaranteed.

Financial support and sponsorship

Nil.

Conflicts of interest

There are no conflicts of interest.

REFERENCES

- Oberg K. Neuroendocrine gastrointestinal and lung tumors (carcinoid tumors), the carcinoid syndrome, and related disorders. In: Melmed SP, Larsen PR, Polonsky KS, Kronenberg HM, editors. *Williams Textbook of Endocrinology*. 13th ed. Philadelphia, PA: Elsevier; 2016.
- Harbour JW, De Potter P, Shields CL, Shields JA. Uveal metastasis from carcinoid tumor. Clinical observations in nine cases. *Ophthalmology* 1994;101:1084-90.
- Zhang J, Jia Z, Li Q, Wang L, Rashid A, Zhu Z, *et al.* Elevated expression of vascular endothelial growth factor correlates with increased angiogenesis and decreased progression-free survival among patients with low-grade neuroendocrine tumors. *Cancer* 2007;109:1478-86.
- Yao JC, Phan A, Hoff PM, Chen HX, Charnsangavej C, Yeung SC, *et al.* Targeting vascular endothelial growth factor in advanced carcinoid tumor: A random assignment phase II study of depot octreotide with bevacizumab and pegylated interferon alpha-2b. *J Clin Oncol* 2008;26:1316-23.
- Guo Y, Shao C, Blau T, Tannappel A, Koch KR, Heindl LM. Ocular metastasis of bronchial typical carcinoid. *J Thorac Oncol* 2018;13:1422-3.
- Hernández-Ayuso I, Rodríguez-Reyes AA, Ríos Y Valles-Valles D, Kawakami-Campos PA, Herrera Cifuentes SL. Just another metastatic carcinoid tumour to the uveal tract. *Saudi J Ophthalmol* 2018;32:355-7.
- Shields CL, Shields JA, Gross NE, Schwartz GP, Lally SE. Survey of 520 eyes with uveal metastases. *Ophthalmology* 1997;104:1265-76.
- Kawakami S, Wakabayashi Y, Goto H. A case of presumed choroidal metastasis from carcinoid tumor treated by photodynamic therapy with verteporfin. *Clin Ophthalmol* 2013;7:2003-6.
- Gragoudas ES, Carroll JM. Multiple choroidal metastasis from bronchial carcinoid treated with photocoagulation and proton beam irradiation. *Am J Ophthalmol* 1979;87:299-304.
- Minning CA Jr, Davidorf FH, Makley TA Jr, Bruce RA Jr. Metastatic carcinoid to the choroid. *Retina* 1982;2:223-30.
- Harbour JW. Photodynamic therapy for choroidal metastasis from carcinoid tumor. *Am J Ophthalmol* 2004;137:1143-5.
- Chu CK, El-Annan J. Photodynamic therapy for choroidal carcinoid metastasis. *Can J Ophthalmol* 2018;53:e13-6.
- Sangani R, Mazloumi M, Dalvin LA, Shields CL. PDT as Primary Therapy for Choroidal Metastases From Carcinoid Tumor. *Retina Today* 2019. Available from: <https://www.retinatoday.com/articles/2019-mar/pdt-as-primary-therapy-for-choroidal-metastases-from-carcinoid-tumor?c4src=topic:oncology:feed>. [Last accessed on 2020 Feb 26].