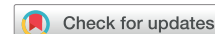

Effusive-Constrictive Pericarditis due to Immune Reconstitution Inflammatory Syndrome following Tuberculous Pericarditis



Yllka Latifi, MD, Remo Gugelmann, MD, Johannes Rigger, MD, Benjamin Preiswerk, MD, Urs Eriksson, MD, Franz R. Eberli, MD, and Alain M. Bernheim, MD, *Zurich, St. Gallen, and Wetzikon, Switzerland*

INTRODUCTION

Tuberculous pericarditis is the most common cause of pericarditis worldwide. The mortality in the preantibiotic era ranged from 80% to 90%.¹ With modern treatment, mortality lies between 8% and 17% in human immunodeficiency virus– (HIV-) negative patients and between 17% and 34% in HIV-positive patients. In patients with tuberculous pericarditis and recurrence of pericarditis and/or pericardial effusion after initiation of therapy, the possibility of tuberculosis-associated immune reconstitution inflammatory syndrome (TB-IRIS) should be considered as a differential diagnosis in both in HIV-positive and -negative patients.²

CASE PRESENTATION

A 37-year-old male patient presented to the emergency room due to epigastric pain of 3 days' duration that was accompanied by fever and shortness of breath. Moreover, he reported weight loss of 5 kg in the past weeks prior to presentation. The patient emigrated from Somalia 19 years ago, and his former medical record was unremarkable. He reported, however, that some of his flatmates were recently diagnosed with tuberculosis (TB). On admission, blood pressure was 125/89 mm Hg with no evidence of pulsus paradoxus, heart rate 99/minute, oxygen saturation 96% on room air, and body temperature 38.0°C (100.4°F). Clinical examination showed no signs of overt heart failure; in particular, neck veins were not distended, jugular venous examination did not identify marked Y-descent, and no pericardial knock or rub was noted.

Laboratory tests revealed mild anemia, normal leukocyte counts, slightly elevated liver enzymes, and normal thyroid hormone levels.

Transthoracic echocardiography showed a large pericardial effusion with no signs of chamber collapse (Figure 1, Video 1).

Differential diagnosis included infectious pericarditis (viral, bacterial, tuberculous), malignant pericardial effusion, or pericardial effu-

sion related to systemic diseases (e.g., lupus erythematosus, rheumatoid arthritis). In particular, given the patient's exposure to flatmates with TB and marked weight loss over the past weeks, tuberculous pericarditis had to be considered.

A pericardiocentesis was performed, and 800 mL of straw-colored clear fluid was drained. Fluid analyses revealed a positive polymerase chain reaction (PCR) for TB and a positive culture. Adenosine desaminase was elevated at 109 IU/L. HIV testing was negative. Therapy with isoniazid, rifampicin, pyrazinamide, and ethambutol was initiated (no drug resistance was detected). The patient's symptoms steadily improved, and he was discharged after 15 days in good general condition, free of fever and without residual pericardial effusion or signs of constrictive physiology on an echocardiographic examination.

Two weeks after discharge, the patient complained of progressive shortness of breath and position-dependent chest pain (pain in the supine position, alleviated by sitting up) and was, therefore, readmitted to the hospital.

At the time of his second presentation, the patient was noted to have distended neck veins with a paradoxical rise in jugular venous pressure on inspiration (Kussmaul's sign), blood pressure of 126/89 mm Hg, an elevated heart rate of 100 bpm, oxygen saturation of 94% without supplemental oxygen, and body temperature of 37.4°C (99.2°F). Cardiac and pulmonary auscultation were unremarkable.

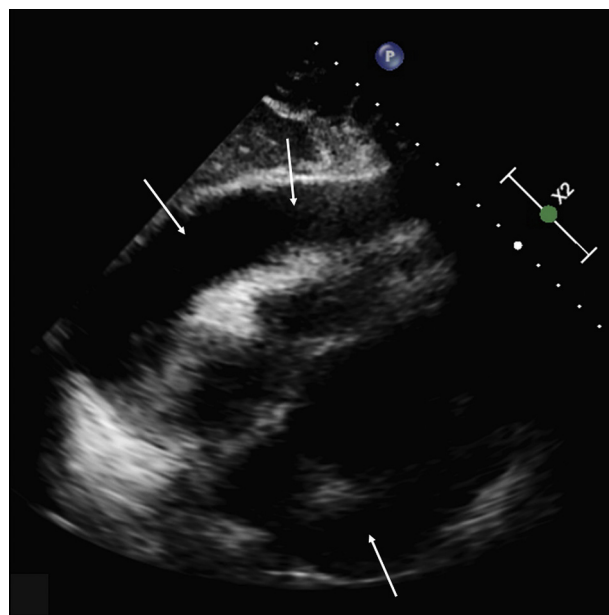


Figure 1 Subcostal view showing a large, circumferential pericardial effusion (arrows).

From the Department of Cardiology (Y.L., R.G., F.R.E., A.M.B.) and Division of Internal Medicine, Infectious Diseases Service (B.P.), Triemli Hospital, Zurich, Switzerland; Department of Cardiology, Kantonsspital St. Gallen, St. Gallen (J.R.), and Division of Cardiology, GZO, Zurich Regional Health Center, Wetzikon (U.E.), Switzerland.

Keywords: Echocardiography, Tuberculous pericarditis, Immune reconstitution inflammatory syndrome

Conflicts of interest: The authors reported no actual or potential conflicts of interest relative to this document.

Copyright 2020 by the American Society of Echocardiography. Published by Elsevier Inc. This is an open access article under the CC BY-NC-ND license (<http://creativecommons.org/licenses/by-nc-nd/4.0/>).

2468-6441

<https://doi.org/10.1016/j.case.2020.10.012>

VIDEO HIGHLIGHTS

Video 1: Subcostal four-chamber view showing a large, circumferential pericardial effusion.

Video 2: Apical four-chamber view showing thickened pericardial space due to a mainly organized pericardial effusion. A left pleural effusion is also seen.

Video 3: Parasternal short-axis view showing “septal bounce.”

Video 4: Subcostal view showing slightly distended inferior vena cava with diminished collapse and spontaneous echo contrast.

Video 5: Follow-up echocardiography (apical four-chamber view) showing almost complete resolution of pericardial thickening and absence of septal shifting with respiration.

View the video content online at www.cvcasejournal.com.

Transthoracic echocardiography showed an organized, moderate-sized pericardial effusion that was located predominantly over the inferior and lateral left heart. Localized anterolateral myocardium-pericardium attachment, where the myocardium appeared to be fused with the pericardium, was noted (Figure 2, Video 2). Spectral Doppler echocardiographic signs of constrictive physiology were present. This included respiratory variability of the pulsed-wave

Doppler signal across the mitral valve, with the first peak inspiratory early diastolic inflow (E) velocities decreasing by 25% compared with the first expiratory E velocity, and of the tricuspid valve inflow, with the first peak expiratory E velocities decreasing by 57% compared with the first inspiratory E velocity. Annulus reversus was observed on tissue Doppler imaging of the septal and lateral mitral annulus, with the lateral e' being smaller than septal e' (Figure 3). Two-dimensional echocardiography in the parasternal short-axis view showed “septal bounce” (Video 3). No early diastolic collapse of the right ventricle was seen. The inferior vena cava was slightly dilated and showed diminished collapse and spontaneous echo contrast (Video 4).

Computed tomography of the chest confirmed severe thickening of the pericardial space caused by an organized pericardial effusion with only trace amounts of fluid content (Figure 4). There was no evidence of pericardial calcification. Additionally, enlarged mediastinal lymph nodes and a large, fluid left-sided pleural effusion were noted.

Based on these findings, the differential etiologies included recurrent TB, either in the setting of tuberculostatic-drug resistance or mal-compliance, new manifestation/dissemination of TB (mainly lung TB), or occurrence of IRIS.

Given the organized appearance of the pericardial effusion with only a small amount of fluid, we refrained from repeated pericardiocentesis. Pleurocentesis was performed, and 800 mL of straw-colored fluid was drained (Figure 5). Adenosine desaminase, mycobacterium TB PCR, and culture were negative. Subsequent bronchoscopy and bronchoalveolar lavage were also negative for the presence of pulmonary TB.

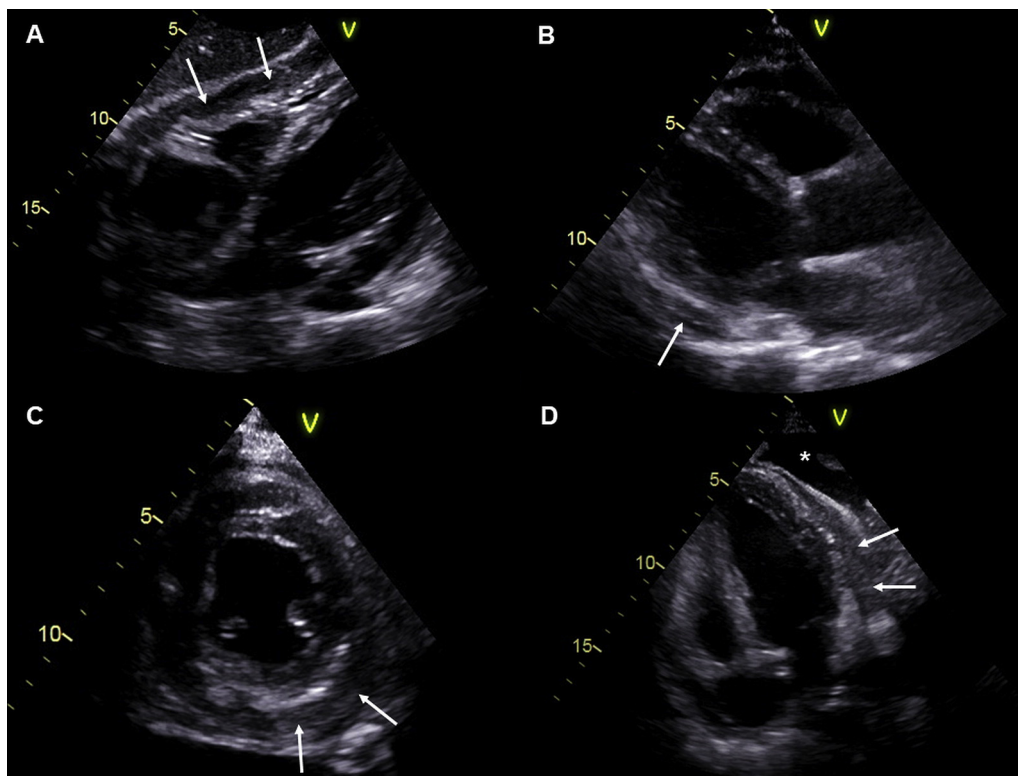


Figure 2 Subcostal four-chamber (A), parasternal long-axis (B), parasternal short-axis (C), and apical four-chamber views (D) showing a thickened pericardial space due to a mainly organized pericardial effusion (arrows) that is predominantly located over the inferior and lateral left heart. In the apical four-chamber view, a left pleural effusion can additionally be seen (asterisk, D).

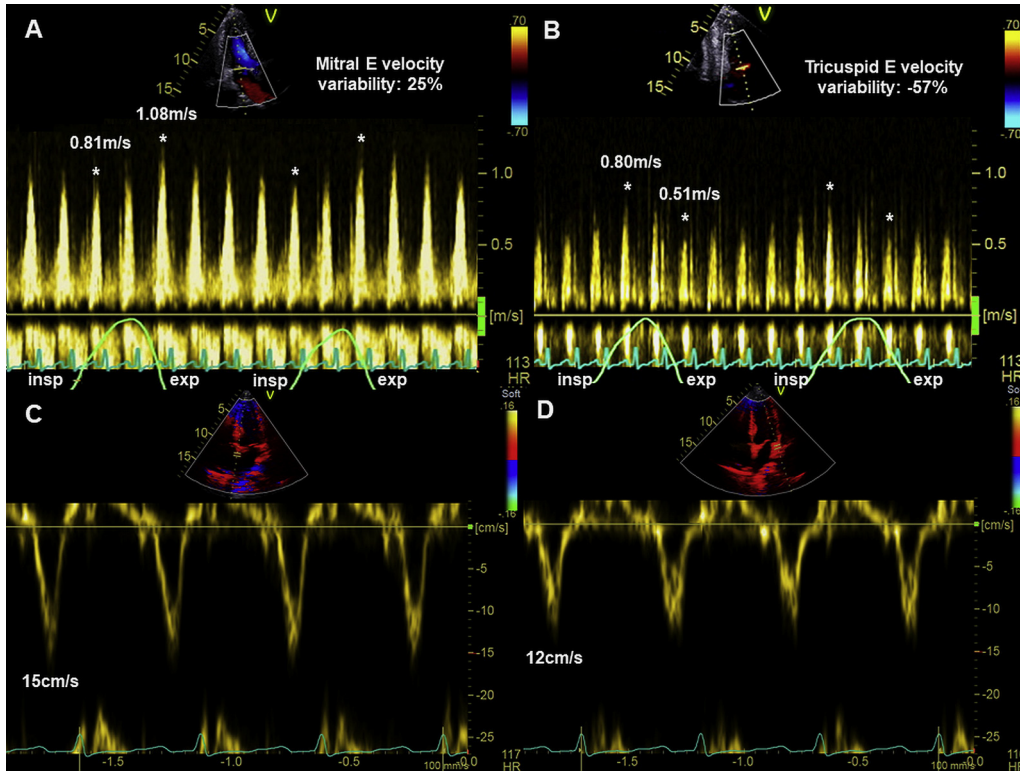


Figure 3 Pulsed-wave Doppler-derived mitral (A) and tricuspid (B) early inflow velocities (E) showing a respiratory variability with the mitral E decreasing with inspiration (A) and the tricuspid E increasing with inspiration (B), respectively. Peak E velocities on the first beat of inspiration and on the first beat of expiration are indicated (asterisk). Respirometer is shown at the bottom of panels A and B. Tissue Doppler images of the septal (C) and lateral (D) mitral annulus exhibit annulus reversus, i.e., smaller e' values in the lateral compared with the septal mitral annulus. Exp, Expiration; insp, inspiration.

Since there was no evidence for dissemination of TB as the reason for the observed pericardial and pleural effusions, IRIS was suspected. The patient was started on prednisone (initial dose of 1 mg/kg body weight, tapered over the following 6 months).

After the initiation of prednisone, the patients' symptoms improved rapidly. A follow-up echocardiogram showed almost

complete regression of pericardial thickening and pericardial effusion with no significant spectral Doppler signs of constriction (Figures 6 and 7, Video 5). The patient was completely asymptomatic and able to resume his daily activities. The patient provided consent, and the local ethics committee approved the publication of this case report.

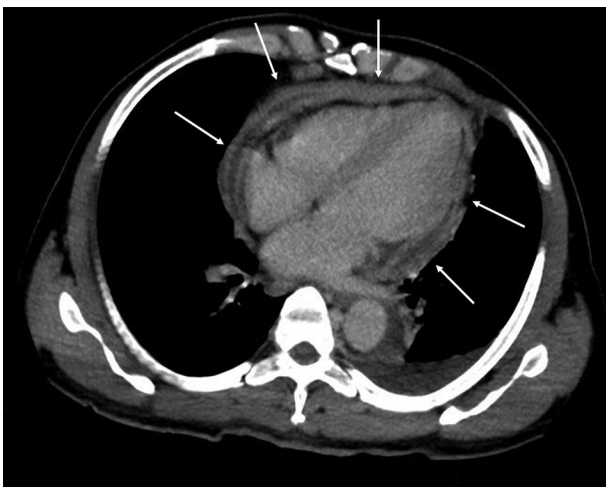


Figure 4 Computed tomography, axial view, showing increased pericardial thickness (arrows) without calcification.

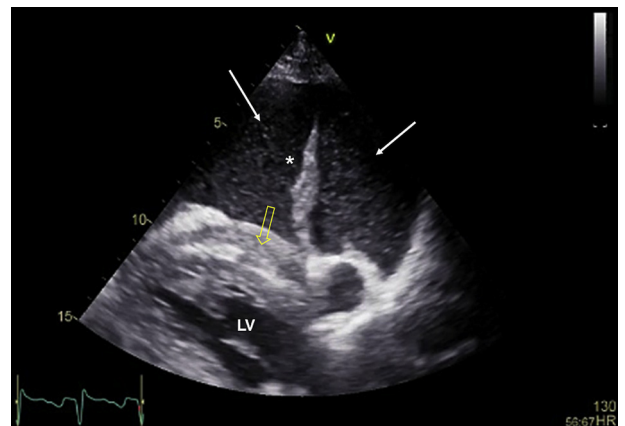


Figure 5 Transthoracic echocardiography, oblique apical view, showing large left-sided pleural effusion (white arrows) and organized pericardial effusion (yellow double arrow). An atelectatic lung segment is visualized within the pleural effusion (asterisk).

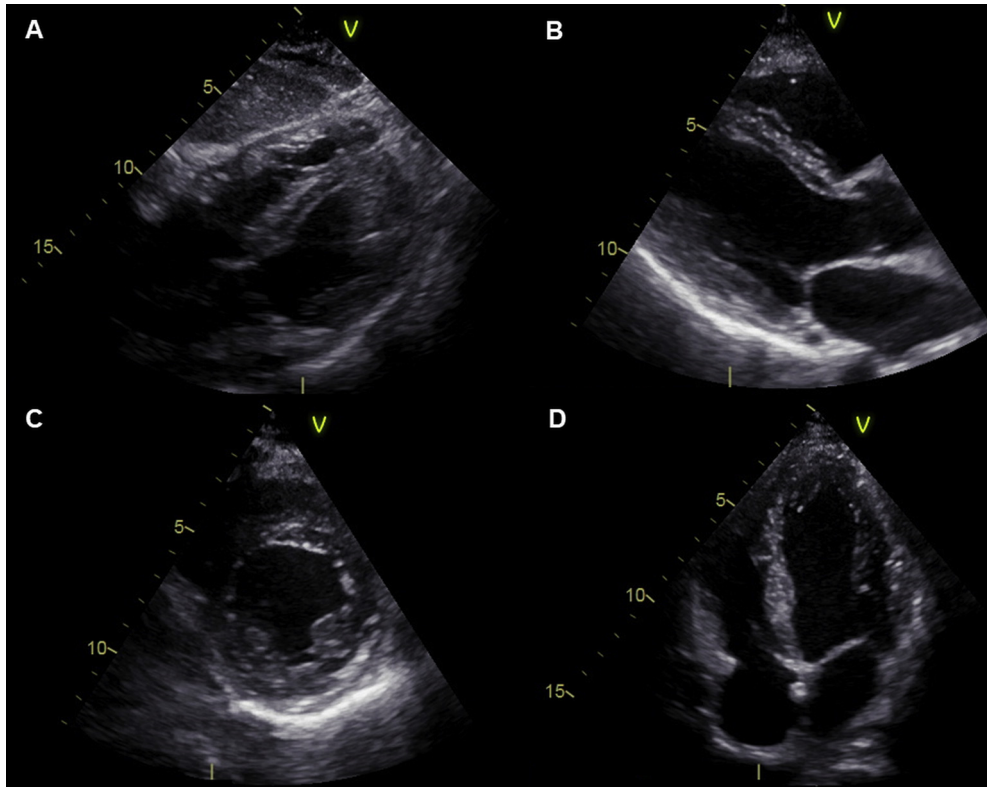


Figure 6 Follow-up echocardiography showing almost complete resolution of pericardial thickening. **(A)** Subcostal four-chamber, **(B)** parasternal long-axis, **(C)** parasternal short-axis, and **(D)** apical four-chamber views.

DISCUSSION

Tuberculosis-associated IRIS refers to an excessive immune response against mycobacteria (alive or dead) that results in a paradoxical worsening or recurrence of preexisting tuberculous lesions (or even manifestation of new lesions) in patients on effective anti-TB treatment. The pathophysiology is incompletely understood; it occurs in 2%-23% of HIV-negative and in 15.7% of HIV-positive patients following treatment of TB.² Tuberculosis-associated IRIS can manifest at any time point after anti-TB treatment is commenced, even after treatment completion.

The definition of TB-IRIS has changed several times over the past decade. The most recent definition requires the following four criteria: (1) initial improvement of TB-related symptoms and/or radiographic findings under adequate anti-TB treatment, (2) paradoxical deterioration of TB-related symptoms and/or radiologic findings at the primary or at new locations during or after appropriate anti-TB treatment, (3) absence of conditions that reduce the efficacy of anti-TB drugs (e.g., poor compliance, drug resistance, drug malabsorption, drugs side effects), and (4) exclusion of other possible causes of clinical deterioration.³

Tuberculous pericarditis is the most common form of pericarditis with pericardial effusion worldwide, accounting for >90% of cases in HIV-positive and 50%-70% of cases in HIV-negative patients. In developed countries, however, pericarditis most commonly results from viral infection, and TB accounts for less than 4% of cases.^{4,5}

In the United States, the incidence of TB has been steadily decreasing over the past decade. This is driven by a rapid decrease in the incidence in U.S.-born patients, while the incidence in non-U.S.-born patients has remained virtually unchanged.⁶

Clinical presentation of TB pericarditis can vary, ranging from pericardial effusion, to effusive-constrictive pericarditis, to chronic constrictive pericarditis.¹ Diagnosis is established by the presence of tuberculous mycobacteria in pericardial fluid, by PCR, by culture, or by histologic examination of a pericardial biopsy. Lymphocytic pericardial exudate accompanied by an elevated unstimulated interferon-gamma, adenosine desaminase or lysozyme level is considered corroborating evidence.

One of the most feared complications of tuberculous pericarditis is its progression to constrictive pericarditis. Evolution toward fixed constriction usually develops within 6 months of presentation with effusive-constrictive pericarditis.¹ Before modern anti-TB drug regimens were available, 50% of patients developed constriction. This was reduced to 17%-40% with modern tuberculostatic drugs. According to the most recent European Society of Cardiology guidelines, use of corticosteroids in TB pericarditis has a class IIb, level of evidence C indication.⁵ One randomized controlled trial showed that the addition of prednisolone to the antituberculous regimen within the first week of the diagnosis of TB pericarditis significantly decreased the relative incidence of constrictive pericarditis by 44%, regardless of HIV status. However, the 6-week course of prednisolone was linked to a significant increase in the incidence of HIV-associated malignancies in HIV-positive patients, and the primary composite outcome of the study, consisting of death from any cause, cardiac tamponade requiring pericardiocentesis, and pericardial constriction, was not significantly reduced by use of prednisolone.⁷ High-dose corticosteroid treatment has been recognized as a risk factor for recurrence in patients with (mainly postviral) pericarditis.^{8,9} Therefore, corticosteroids were not added to the patient's initial anti-TB regimen.

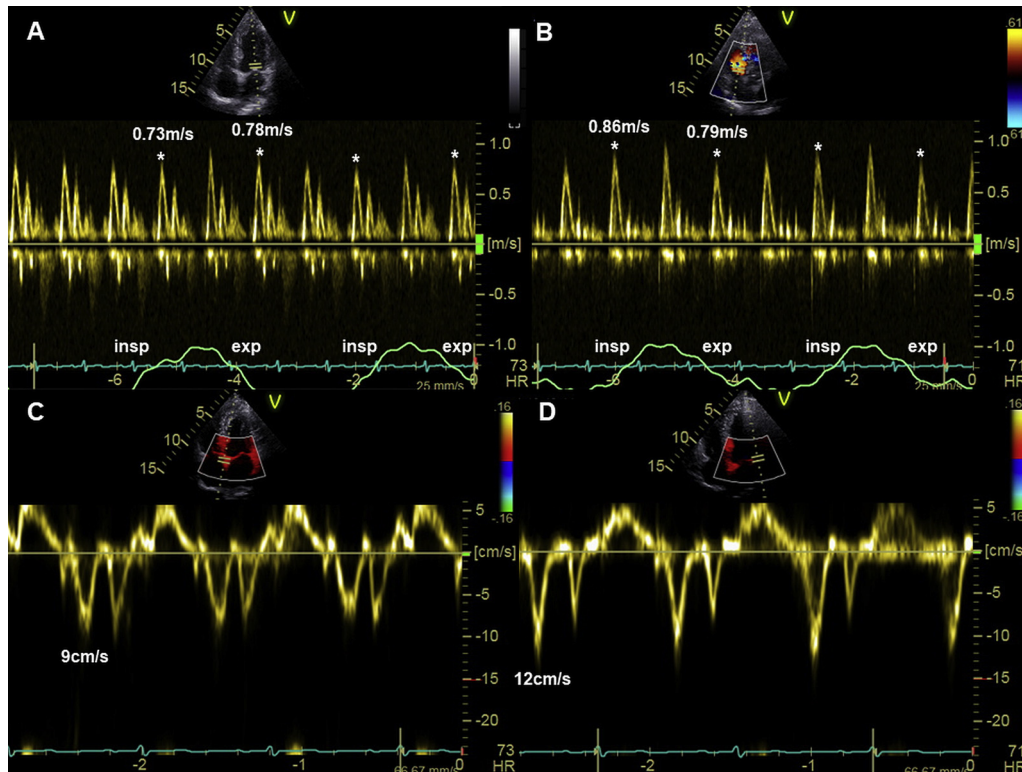


Figure 7 Pulsed-wave Doppler derived mitral (A) and tricuspid (B) inflow velocities showing mild residual respiratory variability. Peak early inflow velocities (E) on the first beat of inspiration and on the first beat of expiration are indicated (*asterisk*). Tissue Doppler imaging of the septal (C) and lateral (D) mitral annulus exhibits a normalized pattern, with e' values being higher in the lateral compared to the septal annulus. *Exp*, Expiration; *insp*, inspiration.

Multimodality imaging plays an important role in the management of patients with suspected constrictive or effusive-constrictive pericarditis. Echocardiography is usually the first-line diagnostic tool used in these patients. This imaging modality may be particularly useful for detection of functional changes associated with constrictive physiology. Echocardiographic hallmarks include bounce of the ventricular septum, with the septum shifting toward the left ventricle with inspiration, decrease in mitral E velocity in the first beat of inspiration by usually more than 25% compared to the first peak expiratory E velocity, decrease in the tricuspid E velocity in the first beat of expiration by more than 40% compared with the first peak inspiratory E velocity, increase of diastolic flow reversal in the hepatic vein with expiration, and preserved or increased tissue Doppler-derived early diastolic mitral annular velocity (e'), with the lateral e' frequently being lower than the medial e' (annulus reversus). Computed tomography and cardiac magnetic resonance imaging are frequently used as second-line imaging modalities in patients with signs of constriction. Computed tomography may, among others, accurately assess pericardial thickness and detect presence, extent, and localization of calcification within the pericardial space. Cardiac magnetic resonance imaging may also detect pericardial thickening and is able to assess presence and extent of pericardial inflammation. Using cine sequences, functional alterations, such as respirophasic variation in septal motion, may additionally be shown by cardiac magnetic resonance imaging.¹⁰

CONCLUSION

Our case illustrates how TB-IRIS can present several weeks after effective anti-TB treatment is started for tuberculous pericarditis.

The delayed recurrence of symptoms may have pointed to several potential differential diagnoses. Apart from TB-IRIS, inadequate treatment due to drug resistance or malcompliance or disease manifestation/progression in other organs had to be considered.

The presented case of TB-IRIS-associated effusive-constrictive pericarditis also highlights the role of the host's immune system in the pathogenesis of effusion and progression to constrictive pericarditis, a process that may, at least in some TB pericarditis cases, be curtailed by timely initiation of corticosteroids. The use of corticosteroids, however, needs to be carefully weighed against the potential harm of an immunosuppressive therapy in a patient with TB.

SUPPLEMENTARY DATA

Supplementary data related to this article can be found at <https://doi.org/10.1016/j.case.2020.10.012>.

REFERENCES

1. Mayosi BM, Burgess LJ, Doubell AF. Tuberculous pericarditis. *Circulation* 2005;112:3608-16.
2. Lanzafame MVS. Tuberculosis-immune reconstitution inflammatory syndrome. *J Clin Tuberc Other Mycobact Dis* 2016;3:6-9.
3. Geri C, Passeron A, Heym B, Arlet JB, Pouchot J, Capron L, et al. Paradoxical reactions during treatment of tuberculosis with extrapulmonary manifestations in HIV-negative patients. *Infection* 2013;41:537-43.
4. Mayosi BM. Contemporary trends in the epidemiology and management of cardiomyopathy and pericarditis in sub-Saharan Africa. *Heart* 2007;93:1176-83.

5. Adler Y, Charron P, Imazio M, Badano L, Baron-Esquivias G, Bogaert J, et al. 2015 ESC guidelines for the diagnosis and management of pericardial diseases: the Task Force for the Diagnosis and Management of Pericardial Diseases of the European Society of Cardiology (ESC) Endorsed by: the European Association for Cardio-Thoracic Surgery (EACTS). *Eur Heart J* 2015;36:2921-64.
6. Schwartz NG, Price SF, Pratt RH, Langer AJ. Tuberculosis—United States, 2019. *MMWR Morb Mortal Wkly Rep* 2020;69:286-9.
7. Mayosi BM, Ntsekhe M, Bosch J, Pandie S, Jung H, Gumedze F, et al. Prednisolone and *Mycobacterium indicus pranii* in tuberculous pericarditis. *N Engl J Med* 2014;371:1121-30.
8. Imazio M, Adler Y. Treatment with aspirin, NSAID, corticosteroids, and colchicine in acute and recurrent pericarditis. *Heart Fail Rev* 2013;18:355-60.
9. Imazio M, Demichelis B, Parrini I, Cecchi E, Demarie D, Ghisio A, et al. Management, risk factors, and outcomes in recurrent pericarditis. *Am J Cardiol* 2005;96:736-9.
10. Klein AL, Abbara S, Agler DA, Appleton CP, Asher CR, Hoit B, et al. American Society of Echocardiography clinical recommendations for multimodality cardiovascular imaging of patients with pericardial disease: Endorsed by the Society for Cardiovascular Magnetic Resonance and Society of Cardiovascular Computed Tomography. *J Am Soc Echocardiogr* 2013;26:965-101215.