

 **Case Report** 

# Organ Protection for Radical Debridement to Prevent Recurrence of Infection after Zone 1 Thoracic Endovascular Aortic Aneurysm Repair: A Case Report

Yojiro Koda, MD,<sup>1</sup> Hirohisa Murakami, MD, PhD,<sup>2</sup> Hitoshi Matsuda, MD, PhD,<sup>3</sup> and Nobuhiko Mukohara, MD, PhD<sup>2</sup>

We present the case of a 73-year-old man with stent graft infection, who had undergone thoracic endovascular aortic aneurysm repair with a supra-aortic bypass from the right axillary to the left common carotid and axillary arteries. The procedure included total stent graft removal, radical debridement, and in situ graft replacement via left anterolateral thoracotomy. Cerebral perfusion from the left axillary artery and cardioplegia using an occlusion balloon with moderate hypothermia were performed to reinforce organ protection. Staged omentopexy was performed the next day after initial replacement with non-contaminated instruments. The postoperative course was uneventful. No recurrence of infection has been found for 3 years.

**Keywords:** thoracic endovascular aortic aneurysm repair, stent graft infection, staged omentopexy

## Introduction


Stent graft infection after thoracic endovascular aortic an-

<sup>1</sup>Division of Cardiovascular Surgery, Kobe University Hospital, Kobe, Hyogo, Japan

<sup>2</sup>Department of Cardiovascular Surgery, Hyogo Brain and Heart Center, Himeji, Hyogo, Japan

<sup>3</sup>Department of Cardiovascular Surgery, National Cerebral and Cardiovascular Center, Suita, Osaka, Japan

Received: October 15, 2019; Accepted: January 17, 2020  
Corresponding author: Hitoshi Matsuda, MD, PhD. Department of Cardiovascular Surgery, National Cerebral and Cardiovascular Center, 5-7-1 Fujishirodai, Suita, Osaka 565-8565, Japan  
Tel: +81-6-6833-5012, Fax: +81-6-6872-7486  
E-mail: hitmat@mist.ocn.ne.jp

 ©2020 The Editorial Committee of Annals of Vascular Diseases. This article is distributed under the terms of the Creative Commons Attribution License, which permits use, distribution, and reproduction in any medium, provided the credit of the original work, a link to the license, and indication of any change are properly given, and the original work is not used for commercial purposes. Remixed or transformed contributions must be distributed under the same license as the original.

eurysm repair (TEVAR) is a rare but potentially fatal complication. The 30-day mortality rate is reportedly 11%,<sup>1</sup> and stent graft infection after TEVAR has higher mortality than that after abdominal endovascular aortic aneurysm repair, due to the higher rate of fistula formation of nearby organs and more invasive surgeries with cardiopulmonary bypass sometimes with hypothermia.<sup>2,3</sup>

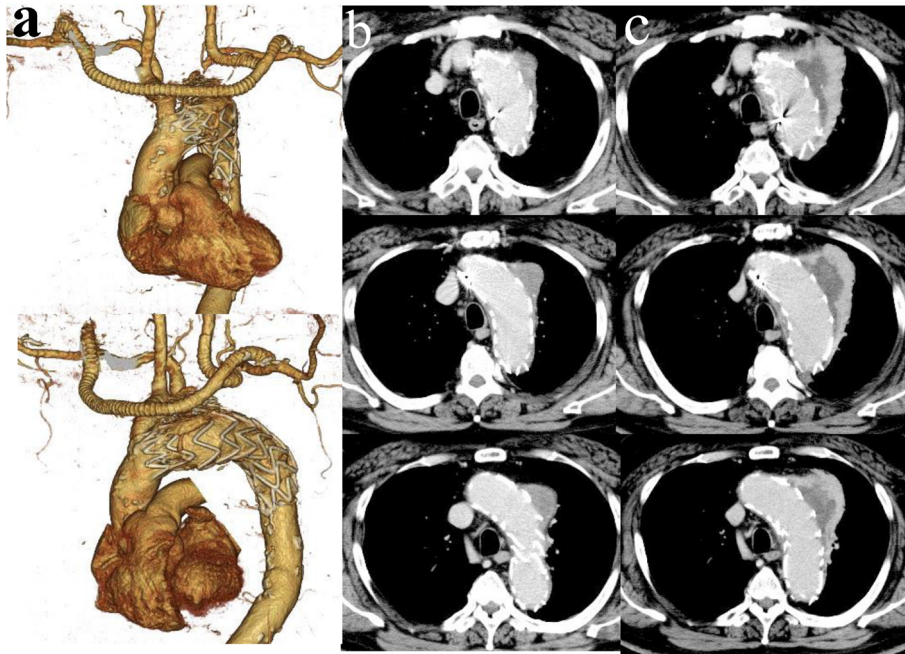
This report concerns a patient who successfully underwent replacement from aortic arch to descending aorta via left anterolateral thoracotomy with careful surgical procedures, for stent graft infection after debranching TEVAR with zone 1 landing.

## Case Report

A 73-year-old man was referred to our institute for persistent high fever. He had undergone successful debranching TEVAR for a 56-mm thoracic aortic aneurysm 2 years before with the Valiant Thoracic Stent Graft (Medtronic Inc., Santa Rosa, CA, USA) concomitant with a supra-aortic bypass from the right axillary to the left common carotid and axillary arteries. The postoperative course after the initial TEVAR had been uneventful, and neither migration nor endoleak has been detected (Figs. 1a and 1b).

At re-admission, laboratory tests showed white cell count of 6,500/ $\mu$ L and C-reactive protein level of 6.00 mg/dL, but the blood culture test revealed no organisms. Enhanced computed tomography showed enlargement of the distal aortic arch aneurysm treated with TEVAR and aneurysmal wall enhancement without endoleak (Fig. 1c). The patient was diagnosed with a mycotic aneurysm and stent graft infection, after which empiric antibiotics, including meropenem and vancomycin, were started. However, as high fever remained refractory and the patient was complicated by chest pain, urgent surgery was indicated 5 days after admission.

Via left anterolateral thoracotomy and through the fourth intercostal space, the upper ascending, arch and

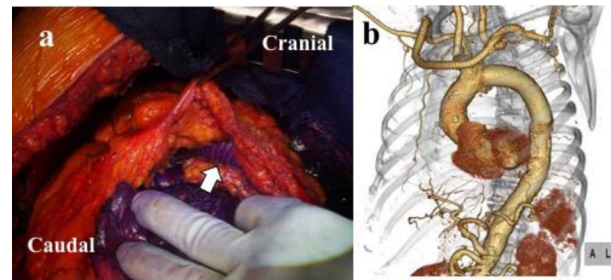


**Fig. 1** a, b: Three-dimensional and horizontal computed tomography 1 week after initial thoracic endovascular aortic aneurysm repair. c: Horizontal computed tomography at re-admission.

proximal descending aorta, including the mycotic aneurysm, were exposed. Cardiopulmonary bypass was established with venous drainage from the right atrium through the left femoral vein and arterial return to the left femoral (17Fr) and left axillary (12Fr) arteries. Additional drainage was obtained from the main pulmonary artery, and the patient was cooled down to 25°C.

First, following the longitudinal opening of the aortic aneurysm wall between the landing zones, massive grey malodorous pus was encountered. After vigorous lavage around the stent graft and debridement of the aneurysm wall, cardiac arrest was attained with systemic administration of potassium (20 mEq). The descending aorta distal to the stent graft and the brachiocephalic artery were clamped, and separate perfusion of the upper and lower bodies was initiated.

The stent graft was carefully detached from the proximal landing zone, and a balloon catheter (Pruitt Occlusion & Perfusion Catheters, LeMaitre Vascular Inc., Burlington, MA, USA) was inserted inside the ascending aorta for antegrade infusion of cardioplegia. The stent graft was then totally removed from the distal landing zone, and meticulous debridement of the aortic wall between the brachiocephalic artery and distal landing zone and of infected tissue was carried out. The infection did not spread to a proximal edge metal without fabric in the stent graft and the aortic wall within 1.5 cm behind the brachiocephalic artery. The aortic arch was reconstructed with a tube graft (J-graft, Japan Lifeline Co. Ltd., Tokyo,



**Fig. 2** a: Wrapping of the synthetic graft with the omental pedicle. Arrow shows the synthetic graft. b: Three-dimensional computed tomography 1 week after surgery.

Japan) behind the brachiocephalic artery, which supplies all supra-aortic branches. Weaning from cardiopulmonary bypass was uneventful, and the thoracotomy was closed temporarily. The surgery, cardiopulmonary bypass, and cardiac arrest lasted 448, 159, and 103 min, respectively. The required blood transfusion was 12 units of packed red blood cell and 10 units of platelets.

The thoracotomy was opened the next day by means of a small laparotomy. Omentopexy, wrapping of the arch prosthetic graft with the omental pedicle, was performed under dissemination of gentian violet (Fig. 2a). The procedure included perfect hemostasis and meticulous lavage with non-contaminated surgical instruments.

Because *Listeria monocytogenes* was detected on the wall of the mycotic aneurysm and stent graft, intravenous antibiotic therapy with ampicillin was continued for 6

weeks. After no recurrence of infection was confirmed with computed tomography and laboratory findings (Fig. 2b), the patient was discharged home with hoarseness, which spontaneously disappeared 3 months later. No recurrence of infection has been found for 3 years.

## Discussion

Satisfactory outcomes of open aortic repair after TEVAR have been reported.<sup>2)</sup> However, when there is an indication of an infectious state, such as a mycotic aneurysm or stent graft infection, short- and long-term outcomes are worse than those for other indications including endoleak, dilatation of false lumen, and retrograde type A aortic dissection.<sup>4)</sup> As stent graft infection is complicated by persistent sepsis and extensive debridement of infected tissue and explantation of the stent graft needs extensive surgeries, while postoperative morbidity and mortality are likely to be more frequent.<sup>1)</sup>

Even when the causative organism is not resistant to antibiotics, the complete debridement of infected tissue is the basic and most important procedure to be performed. In this case, it was not advisable to preoperatively clamp the aorta at both sides of the stent graft, distal to the brachiocephalic artery and proximal descending aorta, to achieve complete debridement in view of the anticipated severe adhesion. Moderate hypothermia (25°C) was used mainly in preparation for the open distal anastomosis as well as for the open proximal anastomosis. The hypothermic condition made it possible to secure "step by step" complete debridement by (1) removal of pus discharge and partial removal of infected tissue with lavage before aortic clamping, (2) safe cardiac arrest with systemic potassium infusion followed by antegrade cardioplegia, and (3) resection of residual aortic and surrounding tissues. Perfusion from the left axillary artery was also useful as it allowed complete cerebral perfusion without interruption only by simple clamping of the brachiocephalic artery. In case we needed to extend debridement for active infection, we could extend several centimeters both proximal with the reconstruction of the brachiocephalic artery and distal directions with the utilization of open distal anastomosis during hypothermic circulatory arrest of the lower body.

Complete debridement usually needs a long time while secure cardiac protection is another key concern. The cardiac arrest in our case lasted >100 min so that a single systemic infusion of high-dose potassium would have been insufficient. Use of the balloon catheter in the ascending aorta to deliver cardioplegia reinforced cardiac protection.

As an additional measure to prevent recurrent infection, we performed staged omentopexy on the day after initial

graft replacement. The staged omentopexy required additional work but confirmed that hemostasis was complete, thus allowing for additional meticulous lavage with non-contaminated surgical instruments.

The selection of graft material is essential to treat infectious aortic disease including stent graft infection. Good long-term outcomes of aortic replacement with homograft for infectious aortic disease have been demonstrated.<sup>5)</sup> However, in this particular reported case, we applied aortic replacement using a standard prosthetic graft due to the emergent situation under the limited availability of a homograft.

## Conclusion

We performed a successful replacement from the aortic arch to the descending aorta via left anterolateral thoracotomy with careful surgical procedures, for stent graft infection after debranching TEVAR with zone 1 landing.

## Disclosure Statement

None declared.

## Author Contributions

Study conception: YK, HM (Hitoshi Matsuda), NM

Data collection: YK

Investigation: HM (Hirohisa Murakami), YK

Writing: YK, HM (Hitoshi Matsuda)

Critical review and revision: all authors

Final approval of the article: all authors

Accountability for all aspects of the work: all authors

## References

- 1) Smeds MR, Duncan AA, Harlander-Locke MP, et al. Treatment and outcomes of aortic endograft infection. *J Vasc Surg* 2016; 63: 332-40.
- 2) Murphy EH, Szeto WY, Herdrich BJ, et al. The management of endograft infections following endovascular thoracic and abdominal aneurysm repair. *J Vasc Surg* 2013; 58: 1179-85.
- 3) Roselli EE, Abdel-Halim M, Johnston DR, et al. Open aortic repair after prior thoracic endovascular aortic repair. *Ann Thorac Surg* 2014; 97: 750-6.
- 4) Ikeno Y, Miyahara S, Koda Y, et al. Early and long-term outcomes of open surgery after thoracic endovascular aortic repair. *Interact Cardiovasc Thorac Surg* 2018; 27: 574-80.
- 5) Kitamura S, Yagihara T, Kobayashi J, et al. Mid- to long-term outcomes of cardiovascular tissue replacements utilizing homografts harvested and stored at Japanese institutional tissue banks. *Surg Today* 2011; 41: 500-9.