

Aortopulmonary Fistula Presenting without an Endoleak after Thoracic Endovascular Aortic Repair

Giacomo Sica, M.D., Ph.D.¹, Gaetano Rea, M.D.¹, Giorgio Bocchini, M.D.¹,
Romilda Lombardi, M.D.², Massimo Muto, M.D.¹, Tullio Valente, M.D.¹

¹Division of Radiology, Department of Diagnostic Imaging, Monaldi Hospital,

²Division of Radiology, Department of Diagnostic Imaging, AO Rummo

Herein, we report the case of a 60-year-old man, a smoker with a history of arterial hypertension and diabetes mellitus. After computed tomography (CT) for an episode of hemoptysis, the patient underwent elective thoracic endovascular aortic repair (TEVAR) because of a degenerative aneurysm of the descending thoracic aorta. The area of perianeurysmal pulmonary atelectasis reported on the CT scan was not considered. Three months later, he developed an aortopulmonary fistula without endoleaks. Although TEVAR is a relatively safe procedure, no detail should be overlooked in the preoperative evaluation in order to avoid life-threatening complications. Further, the effectiveness and modality of prolonged antibiotic prophylaxis and/or preoperative respiratory physiotherapy should be assessed in such cases.

Key words: 1. Endovascular procedures
2. Aortic aneurysm
3. Pulmonary atelectasis
4. Complication
5. Physiotherapy

Case report

Herein, we report the case of a 60-year-old man, a smoker with a history of arterial hypertension, diabetes mellitus, and recent unspecified retinal vein thrombosis treated with heparin and oral anticoagulants. In the emergency department (ED), following an episode of hemoptysis, the patient underwent thoracic contrast-enhanced multidetector computed tomography (CE-MDCT) revealing ground-glass opacities (GGO) in the left lung parenchyma for hemorrhagic alveolitis, associated with small consolidation areas in the presence of normal blood inflammatory indices (serum C-reactive protein, erythrocyte sed-

imentation rate, and white blood cell count). Further, the CE-MDCT revealed a saccular aneurysm of the left side wall of the descending thoracic aorta with a maximum transverse diameter of 57 mm and atelectasis of the surrounding lung parenchyma compressed by the aneurysm (Fig. 1). The saccular aneurysm was considered to be of atherosclerotic nature, considering the relatively high incidence of atherosclerotic saccular aneurysms [1]; the lack of clearly suggestive computed tomography (CT) signs for an infected aneurysm; the absence of fever, interscapular or back pain, or coughing; completely normal inflammatory indices; and no history of high-energy trauma or bladder cancer. Moreover, considering the

Received: November 10, 2016, Revised: February 22, 2017, Accepted: March 29, 2017, Published online: August 5, 2017

Corresponding author: Giacomo Sica, Division of Radiology, Department of Diagnostic Imaging, Monaldi Hospital, Via L. Bianchi, Naples, Italy

(Tel) 39-08119812582 (Fax) 39-08119812582 (E-mail) gsica@sirm.org

© The Korean Society for Thoracic and Cardiovascular Surgery. 2017. All right reserved.

© This is an open access article distributed under the terms of the Creative Commons Attribution Non-Commercial License (<http://creativecommons.org/licenses/by-nc/4.0>) which permits unrestricted non-commercial use, distribution, and reproduction in any medium, provided the original work is properly cited.

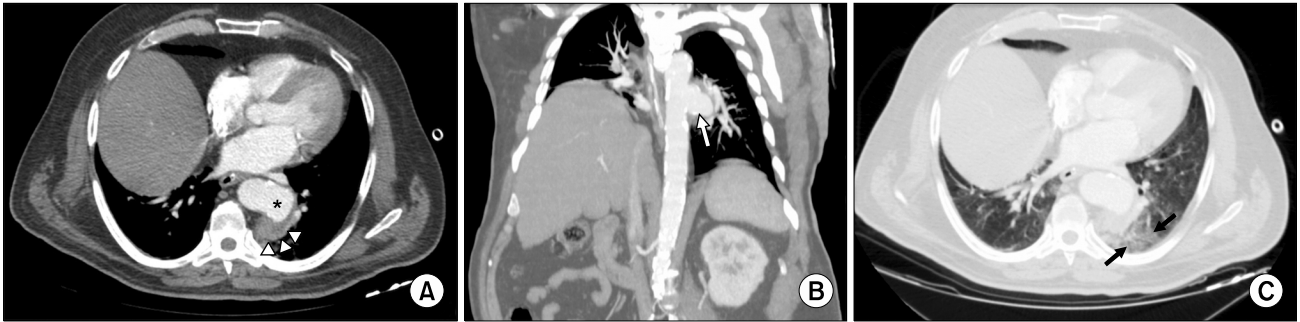

Fig. 1. Contrast-enhanced multidetector computed tomography showing (A) a saccular aneurysm (asterisk) and perianeurysmal atelectasis (arrowheads), (B) favorable position of the aneurysm in reformatted coronal oblique multiplanar reconstruction (arrow), and (C) the presence of ground-glass opacities (arrows).

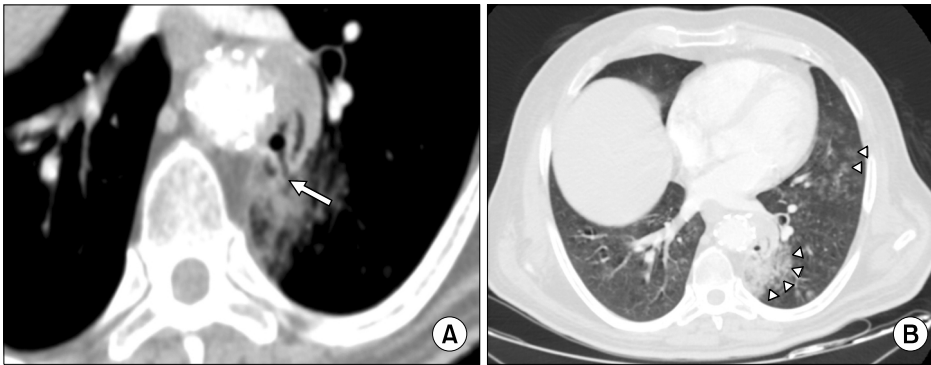


Fig. 2. Minimum intensity projection reformation (A) shows the presence of a significant proportion of air in the aneurysmal sac with a linear air image with an interruption of the aortic wall (arrow); (B) an axial contrast-enhanced multidetector computed tomography scan showing reduction of atelectasis and an increase in ground-glass opacities (arrowheads) in the absence of endoleaks.

favorable anatomical location of the aneurysm and the spontaneous cessation of hemoptysis, elective thoracic endovascular aortic repair (TEVAR) was carried out. However, after approximately 3 months, the patient returned to the ED with a new episode of hemoptysis, and therefore underwent multiphase CE-MDCT, which excluded a pulmonary embolism, showing the correct positioning of the endoprosthesis, the total absence of an endoleak, size reduction of the aortic aneurysm sac for thrombus retraction, size reduction of the parenchymal lung atelectasis, the onset of air bubbles in the excluded aneurysmal sac with a linear arrangement of air and an interruption of the aortic wall in the minimum intensity projection reformation, and persistent GGO that explained the new episode of hemoptysis (Fig. 2). Therefore, the patient was hospitalized again. Since the inflammatory markers were normal and the patient had neither fever nor chest pain in the absence of the CE-MDCT signs of a stent-graft infection, we decided upon nonoperative management, reserving the possibility of open aortic repair if the hemoptysis

worsened and pending the performance of positron emission tomography-CT if a stent-graft infection was suspected. Fortunately, after 5 days, CE-MDCT imaging showed a significant reduction of air in the aneurysmal sac and a reduction of the GGO along with lung consolidation. Therefore, the patient was discharged with home care (Fig. 3). One week after being discharged from the hospital, the patient returned to our clinic completely asymptomatic and his blood tests confirmed the normality of the inflammatory markers. After 1 month, a follow-up CT scan confirmed a gradual improvement of the thoracic findings.

Discussion

Aortopulmonary and aortobronchial fistulas (ABPFs) are a rare but feared condition that, favored by the long course of the aorta and due to its elevated intraluminal pressure, may arise as a life-threatening postoperative complication. Although the incidence of ABPFs is reported to be relatively high after open

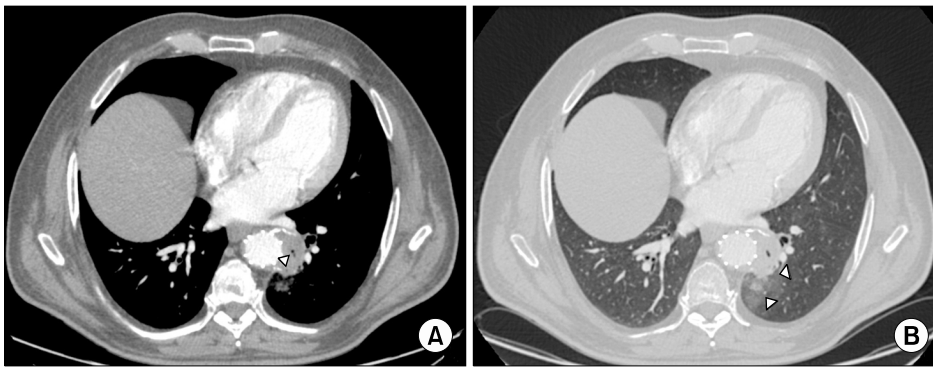


Fig. 3. Axial contrast-enhanced multidetector computed tomography scan showing (A) an absence of endoleaks and a reduction of the air in the aneurysmal sac (arrowhead) with restoration of the wall integrity and (B) a significant reduction of atelectasis and ground glass opacities (arrowheads).

surgery, this complication has also been reported after TEVAR in the literature [2,3]. TEVAR is known to be a valid alternative to open surgery and is often the first therapeutic solution for the treatment of thoracic aortic disease, particularly in patients in whom the presence of a comorbidity contraindicates traditional surgery [4-6]. However, even though TEVAR is relatively safe, several complications related to this procedure have been reported in the literature. In particular, ABPFs have a relatively low incidence, ranging from 0.56% to 0.8% [2,3], but an infection of the stent graft is feared, often requiring repair with open surgery [4,5]. In ABPFs, hemoptysis is often the only symptom and depends on the fistula entity. CE-MDCT can be used to identify changes in the adjacent lung as consolidation or rarely, the flooding of the intravenous contrast medium into the lung tissue or airways. Sometimes, intragraft or perigraft air is an indirect sign that may be the only sign of a fistula. Leukocytosis, fever, and chest pain are nonspecific clinical findings in the case of a serious graft infection. In such cases, CE-MDCT can show aortic wall thickening, perigraft soft tissue or fluid collection, pseudo-aneurysm, perigraft air or an increasing amount of air on serial imaging examinations, adjacent soft-tissue stranding, abscess formation, and graft thrombosis or expansion [3]. This case shows that even in the overall evaluation before a relatively safe procedure such as TEVAR, no MDCT detail can be overlooked, even a minor detail such as the limited area of atelectasis. In fact, longstanding atelectasis may indicate adherence to the aneurysmal aortic wall that is already lacking elasticity. Furthermore, chronic pulsatile compression of a progressively degenerative aneurysm that expands into the lung parenchyma and the airways could cause a local in-

flammatory response with a further formation of adhesions. Despite the excellent positioning of the endoprosthesis and the total absence of endoleaks, in the considered case, the reduction of the aneurysmal sac size that comes from thrombus retraction might be associated with better expansion of the periaortic lung parenchyma (no longer compressed), and cause traction on the wall of the aneurysmal sac, thereby causing an aortopulmonary fistula. Furthermore, vigorous coughing due to hemoptysis can increase the amount of air, further emphasizing the interruption of the aortic wall and air embolism into the excluded aneurysmal sac [7]. Fortunately, the patient never presented with leukocytosis, fever, or chest pain; hemoptysis, although important, was limited, considering the absence of an endoleak, and required only prudent admission to a highly specialized department.

Some authors have argued that many endoprostheses are placed off-label and that some indications of TEVAR are often bold and not adequately proven [2,5]. However, this case shows that even when all the indications stated in the international guidelines are observed [8], TEVAR, which is relatively easy a favorable position and extent, with a regular diameter and optimal length of the healthy proximal and distal landing zones, may be complicated by dangerous events, such as an ABPF, if small MDCT details are underestimated in the preoperative assessment. Furthermore, the present case supports the viewpoint of other authors who have recommended a multidisciplinary approach for determining the type of treatment for thoracic aortic disease depending on the functional anatomy, pathology, and comorbidity of the case being treated [8]. Further multicenter studies are needed to encourage the development of additional preoperative risk stratification tools that

must take into account the smaller MDCT details that are often not considered in a pre-TEVAR evaluation, but might still be responsible for undesirable post-operative complications requiring conversion to open repair. Finally, although encouraging studies on respiratory physiotherapy before cardiothoracic and abdominal surgery have been reported in the literature [9-11], currently, the role of this procedure, which is generally associated with prolonged antibiotic prophylaxis, has never been considered when it is performed before endovascular procedures. Therefore, respiratory physiotherapy, a safe and relatively inexpensive practice, could be introduced before elective TEVAR procedures with associated perianeurysmal pulmonary atelectasis to avoid potentially catastrophic postoperative complications, such as an ABPF or a peri-stent-graft infection, even in the absence of endoleaks.

Conflict of interest

No potential conflict of interest relevant to this article was reported.

References

1. Shang EK, Nathan DP, Boonn WW, et al. *A modern experience with saccular aortic aneurysms*. J Vasc Surg 2013; 57:84-8.
2. Czerny M, Reser D, Eggebrecht H, et al. *Aorto-bronchial and aorto-pulmonary fistulation after thoracic endovascular aortic repair: an analysis from the European Registry of Endovascular Aortic Repair Complications*. Eur J Cardiothorac Surg 2015;48:252-7.
3. Valente T, Rossi G, Rea G, et al. *Multidetector CT findings of complications of surgical and endovascular treatment of aortic aneurysms*. Radiol Clin North Am 2014;52:961-89.
4. Coselli JS, Spiliotopoulos K, Preventza O, de la Cruz KI, Amarasekara H, Green SY. *Open aortic surgery after thoracic endovascular aortic repair*. Gen Thorac Cardiovasc Surg 2016;64:441-9.
5. Roselli EE, Abdel-Halim M, Johnston DR, et al. *Open aortic repair after prior thoracic endovascular aortic repair*. Ann Thorac Surg 2014;97:750-6.
6. Kim JT, Yoon YH, Lim HK, Yang KH, Baek WK, Kim KH. *Thoracic endovascular stent graft repair for aortic aneurysm*. Korean J Thorac Cardiovasc Surg 2011;44:148-53.
7. Irwin RS. *Complications of cough: ACCP evidence-based clinical practice guidelines*. Chest 2006;129(1 Suppl):54S-58S.
8. Erbel R, Aboyans V, Boileau C, et al. *2014 ESC guidelines on the diagnosis and treatment of aortic diseases: document covering acute and chronic aortic diseases of the thoracic and abdominal aorta of the adult. The Task Force for the Diagnosis and Treatment of Aortic Diseases of the European Society of Cardiology (ESC)*. Eur Heart J 2014; 35:2873-926.
9. Varela G, Ballesteros E, Jimenez MF, Novoa N, Aranda JL. *Cost-effectiveness analysis of prophylactic respiratory physiotherapy in pulmonary lobectomy*. Eur J Cardiothorac Surg 2006;29:216-20.
10. Katsura M, Kuriyama A, Takeshima T, Fukuhara S, Furukawa TA. *Preoperative inspiratory muscle training for postoperative pulmonary complications in adults undergoing cardiac and major abdominal surgery*. Cochrane Database Syst Rev 2015;(10):CD010356.
11. Mans CM, Reeve JC, Elkins MR. *Postoperative outcomes following preoperative inspiratory muscle training in patients undergoing cardiothoracic or upper abdominal surgery: a systematic review and meta analysis*. Clin Rehabil 2015;29:426-38.