

PHENOTYPIC VARIABILITY OF 17Q12 MICRODELETION SYNDROME – THREE CASES AND REVIEW OF LITERATURE

Țuțulan-Cuniță A^{1*}, Pavel AG¹, Dimos L¹, Nedelea M^{1,3,4},
Ursuleanu A², Neacșu AT^{1,#}, Budișteanu M^{3,6,7}, Stambouli D¹

*Corresponding Author: Andreea Țuțulan-Cuniță, Cytogenomic Medical Laboratory, 35 Calea Floreasca, Bucharest, 14453, Romania, Tel: 0040212331354, Fax: 0040212331357, E-mail: cunita@cytogenomic.ro

ABSTRACT

Chromosome 17q12 microdeletion syndrome is a contiguous gene deletion syndrome caused by an 1-2 Mb loss, characterized by multicystic dysplastic kidneys or other urinary system anomalies starting in utero, including autism or maturity-onset diabetes of the young in its postnatal phenotype. Here, we report on three cases (two prenatal and one postnatal) with distinct and novel clinical presentations as compared with a large number of reviewed patients, thus emphasizing the phenotypic variability of this syndrome and the consequent difficulties in genetic counselling. Prenatal hyperechogenic multicystic kidneys, as well as other urinary tract anomalies, should be considered a marker, therefore indicating the necessity of comprehensive genetic testing, and autism should also be acknowledged as a possible clinical presentation, postnatally.

Keywords: 17q12 microdeletion syndrome, autism, multicystic kidney, ultrasound marker, urinary tract anomalies.

INTRODUCTION

Chromosome 17q12 microdeletion syndrome (MIM 614527) is a contiguous gene deletion syndrome caused by a 1-2.5 Mb loss [1, 2, 3], with a widely variable phenotype ranging from prenatal multicystic dysplastic kidneys or other urinary system anomalies to postnatal pancreatic dysfunction (maturity onset diabetes of the young type 5 – MODY5) in approx. 40% of patients, or neurodevelopmental disorder (mild to moderate intellectual disability, speech delay, autistic features, schizophrenia, rarely epilepsy) in approx. 50% of patients [1, 3]. Facial dysmorphisms (frontal bossing, malar flattening, micrognathia, retrognathia, downslanting palpebral fissures, depressed nasal bridge) have been described, as well as pancreatic atrophy, liver abnormalities, genital anomalies in both sexes or Mullerian dysplasia or aplasia in females, transient neonatal hypercalcemia, and neonatal cholestasis [1-2, 4-7]. The same genetic defect has been associated with Mayer-Rokitansky-Kuester-Hauser syndrome, suggesting the existence of a continuous spectrum of phenotypes associated with 17q12 microdeletion [5]. However, to date, no correlation between the deletion size and gene content and clinical phenotype has been established. Moreover, patients with similar phenotypes were reported, carrying mutations in *HFN1B* gene [1].

Deletion of 17q12 is incompletely penetrant and its expressivity is highly variable, ranging from severe anomalies, leading to kidney failure before birth, to mild or no problems at all. While 70% of deletions occur de novo, instances where the deletion was inherited from an asymptomatic parent have been reported [6].

The critical region at 17q12 is flanked by polymorphic segmental duplications and contains at least 15 genes, out of which *HFN1B* and *LHX1* are hypothesized to be

¹ Cytogenomic Medical Laboratory, Bucharest, Romania

² Obstetrics & Gynecology Clinic, Prof. Dr. Ioan Cantacuzino Clinical Hospital, Bucharest, Romania

³ Medical Genetics Department, Carol Davila University of Medicine, Bucharest, Romania

⁴ Medical Genetics Department, Filantropia Clinical Hospital, Bucharest, Romania

⁵ Pediatric Neurology Clinic, Prof. Dr. Alex. Obregia Clinical Hospital of Psychiatry, Bucharest, Romania

⁶ Medical Genetics Laboratory, Victor Babes National Institute of Pathology, Bucharest, Romania

⁷ Faculty of Medicine, Titu Maiorescu University, Bucharest, Romania

Current Address: Personal Genetics, Bucharest, Romania

essential for renal function, neuropsychiatric conditions, and female genital anomalies [2, 8]. Many of the remaining genes, such as *CCL* and *TBC1D*, have multiple copies as normal population variants and are not likely to be dosage sensitive. Reciprocal duplications are associated with intellectual disability and epilepsy, though asymptomatic individuals have also been described [1].

While the overall prevalence of 17q12 deletion syndrome is unknown, a Danish study estimated its country prevalence as 1.6:1,000,000 [7]. Wan *et al.* (2019) [9] found that 4.2% of fetuses carried a 17q12 deletions spanning between 1.42-1.58 Mb in a cohort of 126 pregnancies with renal anomalies detected by ultrasound.

In this article, we present 3 new cases of 17q12 deletions and review a large number of the reports, covering 92 patients with this genetic anomaly. Patients were selected based on their renal disorder phenotype or, if asymptomatic and carrying the deletion, the presence of a renal phenotype in a first degree relative. Patients with a primary diagnosis of Mullerian dysplasia or aplasia, Mayer-Rokitansky-Kuester-Hausler syndrome or only MODY5 were not included in the current study. However, given the complexity and the wide variability of the phenotype, from asymptomatic to lethal, the genetic counseling is therefore difficult and conversations about the implications of 17q12 microdeletion must continue.

MATERIALS AND METHODS

Patient A was a 19-year-old gravida 1, referred for genetic testing at 24 weeks. She was selected due to a unilateral multicystic dysplastic kidney of the fetus, without other anomalies and with a normal fetal growth. The results of the biochemical screening for chromosomal aneuploidies were not available.

Patient B was a 26-year-old gravida 1, referred for genetic testing at 17 weeks. She was selected due to megacystitis (defined as the sagittal dimension of the bladder (mm) greater than gestational age (weeks) plus 12), single umbilical artery, choroid plexus cyst, and possibly absent ductus arteriosus. First trimester biochemical screening results showed a high risk for chromosomal aneuploidies (1/56 for trisomy 21, 1/107 for trisomy 13, and 1/193 for trisomy 18; cutoff 1/250). In both cases, amniotic fluid was collected for analysis.

Patient C was a 7 year 5 months old boy, referred to genetic investigations following a diagnosis of autism spectrum disorder with developmental delay. He is the second child of healthy, nonconsanguineous parents born at 39 weeks, after a normal pregnancy, except for an ultrasound image of hydronephrosis in the right kidney at 22 weeks of gestation. With a birth weight of 2,850 g, a length

of 52 cm, and an Apgar score of 7 due to some breathing difficulties, the patient had good postnatal adaptation. His developmental landmarks were delayed (he held his head at 7 months, sat at 12 months, walked at 1 year and 7 months, and pronounced first syllables at 1 year and 8 months, with his first words at 5 years). Hydronephrosis was surgically corrected at 12 months. He was diagnosed with autism spectrum disorder (ASD) at 3 years and started applied behavior analysis (ABA) therapy as well as speech therapy and cognitive stimulation at the age of 4. Currently, he attends his final year of kindergarten, with satisfactory results, though with socialization difficulties. The family history revealed the presence of a maternal cousin with cognitive delay and epilepsy. Clinical evaluation showed macrocephaly (occipitofrontal circumference 58 cm, +4.3 SD), dysmorphic facial features (deep set eyes, synophris, long philtrum, anteverted nostrils, posteriorely rotated ears, abnormal teeth, micrognathia); prominent occiput; joint hyperlaxity, single palmar crease, spindle-shaped fingers, clinodactyly of the fifth finger; inverted nipples; small phallus and bilateral cryptorchidism; hirsutism; poor fine and gross motor skills, hypotonia, language and speech problems (poor language production, inability to understand complex orders, echolalia, polymorphic dyslalia); mild intellectual disability (IQ 60); social skills deficit with poor eye contact, difficulties in interaction with other persons, stereotyped behavior, low tolerance to frustration. An MRI investigation showed a mild bilateral frontal atrophy and a small frontobasal subarachnoidian cyst.

Genetic counselling of the patients was done by a clinical geneticist. Written informed consent on the use of their data for scientific purposes was given by the patients (A, B) or patient's legal guardian (C). Array-CGH was performed on an Agilent Technologies 60K platform according to the supplied protocol for patients A and B, while SNP array (Affymetrix) on a 750K platform was carried out for C patient. Following genetic analysis, pregnancies of patients A and B were terminated, without pursuing any further investigations.

Written informed consent on the use of their data for scientific purposes was given by all patients, in compliance with international and national regulations. Patient C was investigated within the frame of research project EEA RO-NO 6/2019, in accordance with the above regulations and approved by the institutional Ethics Committee, no. 33/Nov. 26, 2019.

RESULTS

The fetus of patient A carried a microdeletion with a minimal size of 1.35 Mb at 17q12, 34,817,422-36,168,104 (hg19), encompassing 18 genes: *PIGW*, *ACACA*, *HNF1B*,

ZNHIT3, GGNBP2, DHRS11, LHX1, AATF, TADA2A, DUSP14, DDX52, MYO19, MRMI, MIR2909, SNORA90, C17ORF78, SYNRG, MIR378. The fetus of patient B exhibited a 1.31 Mb loss at 17q12, 34,851,537-36,168,104 (hg19), encompassing the same 18 genes. A conventional karyotype was also performed in both cases, showing normal chromosomal complements.

Patient C presented a 1.80 Mb deletion at 17q12 at 34,475,679-36,283,807 (hg19) including *CCL3L3, CCL3L1, CCL4L2, TBC1D3C, TBC1D3G, TBC1D3H, PIGW, ACACA, HNF1B, ZNHIT3, GGNBP2, DHRS11, LHX1, AATF, TADA2A, DUSP14, DDX52, MYO19, MRMI, MIR2909, SNORA90, C17ORF78, SYNRG, MIR378.*

In neither case was parental DNA available for further investigation.

DISCUSSION

While the number of reported prenatal cases of 17q12 microdeletion is increasing and its clinical description is continuously updated, the phenotypic variability of this syndrome and the difficulties it raises in genetic counseling invite a broader discussion regarding the molecular mechanisms underlying this condition and their correlation with clinical presentations. Decramer *et al.* (2017) [10] suggest that about 20% of prenatal hyperechogenic kidney cases are caused by 17q12 deletions, though O'Donnelly *et al.* (2014) [11] hypothesize it to be the second most common genetic anomaly in fetuses with abnormal ultrasound results and a normal karyotype, following 22q11.21 deletion, at a similar frequency with 16p13.11 deletion. 17q12 deletion is also among the ten most common microdeletions in children with unexplained neurodevelopmental disorders [12].

Our report describes three cases with prenatal urinary tract anomalies (multicystic dysplastic kidney, megabladder, and hydronephrosis, respectively); two of the pregnancies were subsequently terminated, while the third case had developmental delay and ASD. All our patients carry only one functional copy of four genes classified as pathogenic in OMIM: *PIGW, ACACA, ZNHIT3, HNF1B*, as well as the *LHX1* gene. While the mechanism causing megabladder in the fetus of patient B cannot be traced unequivocally to 17q12 deletion, the presence of urinary tract abnormalities in the clinical phenotype of this syndrome suggests a plausible causal relationship.

As illustrated in table 1, prenatal phenotypes associated with 17q12 microdeletion cover a large spectrum of ultrasound markers, from none to hyperechogenic, multicystic, or enlarged kidneys, absent unilateral kidney, and hydronephrosis. These markers can be detected as early as 15 weeks of gestation [35], along with other findings (in-

testinal obstruction, congenital diaphragmatic hernia, lung anomalies, persistent left superior vena cava, poly- or oligohydramnios etc.). Two of our cases fall within the beginning of this spectrum, with single urinary tract abnormalities and with normal fetal growth. It is estimated that prenatal renal cysts are detected in more than half of the patients with postnatal kidney anomalies and that, regardless cyst detection in utero, most patients develop or increase their number in the first year of life [10]. Our reviewed cases include two sets of twins (P30-31, P44-45) carrying identical deletions. P30-31 twins exhibited similar prenatal phenotypes while progressing discordantly following birth, some patients presented prenatal kidney abnormalities which resolved after birth, while others did not show any anomaly upon prenatal ultrasound, but postnatal developmental delay and neuropsychiatric symptoms (Table 1). Moreover, the reviewed literature describes patients with mild phenotypes, who were diagnosed with 17q12 microdeletion syndrome only after having an affected pregnancy or due to other primary complaints such as hypomagnesemia and subsequent investigations leading to renal disorder (e.g. P92 – Table 1). Difficulties in reviewing medical records and attaining an accurate medical history, particularly in adult and elder patients, make, however, statistics ultimately unreliable.

Among the reviewed patients, 42.7% had kidney anomalies, at least 30.7% exhibited some degree of developmental delay, and 65.3% had neuropsychiatric features such as autism, intellectual disability of variable severity, or attention deficit. Thus, the neuropsychiatric phenotypes appear to be more frequent among the patients with 17q12 microdeletion than renal disorder. Among other phenotypes described in these patients were fetal diaphragmatic hernia (4.3%) and amniotic fluid anomalies (polyhydramnios 12%; oligohydramnios 2.1%; anhydramnios 1.1%) in prenatal cases, and in postnatal cases, digestive tract anomalies, particularly related to liver and pancreas (24%), cardiovascular anomalies (10.7%), skeletal anomalies (14.7%), facial dysmorphism (24%). Ocular anomalies, diabetes, and hypomagnesemia were also described, albeit rarely. The broad spectrum of observed phenotypes emphasizes, once more, the high variability of this syndrome, adding to a 34.4% incomplete penetrance estimated in the case of this deletion [36].

For 45.3% of the cases, family history included potentially related phenotypes, though with only 37.3% being genetically confirmed. 10 out of 92 patients inherited the microdeletion from either a mildly affected or an affected parent, while 4 out of 92 inherited it from an asymptomatic parent. Although dedicated databases such as DECIPHER and CNV Morbidity Map of Developmental Delay list large numbers of cases with this genetic aberration, two deletions are also found in the Control section of the last morbidity map (Figure 1), proving, in accordance with

Table 1. Clinical data of the patients and reviewed cases.

Pat. no.	Sex, age	Deletion size / coordinates	Prenatal				Postnatal										Ref		
			Urinary system	DH	Other anomalies	Amniotic fluid	Urinary system	LBW/Growth delay	Respiratory	Digestive	Cardiovascular	Neurological	Muscular	Bone	Genital	Facial dysmorphism		Other	Relative with possibly related clinical phenotype
1.	Fetus# n/a	1.42 Mb 34,822,465-36,243,365 (hg19)	HN	-	-	-	-	-	-	-	-	-	-	-	-	-	-	-	9
2.	Fetus n/a	1.48 Mb 34,832,294-36,316,144 (hg19)	Left MCDK	-	-	-	-	-	-	-	-	-	-	-	-	-	-	C	13
3.	Fetus# n/a	1.58 Mb 34,822,465-36,404,104 (hg19)	bDK	-	-	-	-	-	-	-	-	-	-	-	-	-	-	-	9
4.	Fetus n/a	1.58 Mb 34,822,465-36,404,104 (hg19)	Right MCDK	-	-	-	-	-	-	-	-	-	-	-	-	-	-	C	13
5.	Fetus# n/a	1.59 Mb 34,822,456-36,410,720 (hg19)	bHK	-	-	-	-	-	-	-	-	-	-	-	-	-	-	-	14
6.	Fetus# n/a	1.74 Mb 31,836,750-33,582,750 (hg17) [34,762,637-36,252,627 (hg19)]	bMDK UTA	-	-	-	-	-	-	-	-	-	-	-	-	-	-	-	1
7.	Fetus# 17 weeks	1.32 Mb 34,851,537-36,168,104(hg19)	UTA	-	+	-	-	-	-	-	-	-	-	-	-	-	-	-	Patient B current study
8.	Fetus, male# 18 wks brother of P49	1.75 Mb 34,653,178-36,402,867 mat (hg19)	bHK, bHN, UTA (18 wks) MK, HN, UTA (21 wks)	-	-	-	-	-	-	-	-	-	-	-	-	-	-	+C	15
9.	Fetus, female# 19 wks	1.39 Mb 31,890,483-33,281,801 (hg18) [34,816,370-36,207,688 (hg19)]	bHK (at 19 wks) bHK, MCK (at 25 wks)	+	-	-	-	-	-	-	-	-	-	-	-	-	-	-	16
10.	Fetus# 22 weeks	1.57 Mb 34,815,551-36,383,538 (hg19)	bHK (22 weeks)	-	-	-	-	-	-	-	-	-	-	-	-	-	-	-	17
11.	Fetus, male# 22 wk son of P79, brother of P25	n/a n/a, pat	bHK, bDK, one cyst	-	+	-	-	-	-	-	-	-	-	-	-	-	-	+C	7
12.	Fetus# 22 wks	1.58 Mb 34,822,465-36,404,136 (hg19)	HK, MDK	-	-	-	-	-	-	-	-	-	-	-	-	-	-	-	18
13.	Fetus 22 wks	1.58 Mb 34,822,492-36,404,104 (hg19)	HK, bHN	-	-	-	-	-	-	-	-	-	-	-	-	-	-	-	18
14.	Fetus# 23 wks	1.60 Mb 34,822,465-36,418,529 (hg19)	HK, bDK	-	-	-	-	-	-	-	-	-	-	-	-	-	-	-	18
15.	Fetus 23 wks	1.94 Mb 34,475,679-36,410,720 (hg19)	HK, left MCDK	-	-	-	-	-	-	-	-	-	-	-	-	-	-	-	18
16.	Fetus# 24 weeks	1.35 Mb 34,817,422-36,168,104 (hg19)	MDK	-	-	-	-	-	-	-	-	-	-	-	-	-	-	-	Patient A current study
17.	Fetus 24 wks offspring of P80	1.42 Mb 34,822,465-36,244,332 (hg19)	HK, MDK	-	-	-	-	-	-	-	-	-	-	-	-	-	-	+C	18

Continues on the next page

Continuation of the previous page

18.	Fetus 24 wks	1.42 Mb 34,822,465-36,243,365 (hg19)	HK	-	-	-	-	-	-	-	-	-	-	-	-	-	-	-	-	-	-	-	18	
19.	Fetus 24 wks	1.49 Mb 34,822,465-36,307,773 (hg19)	left HK, right MCDK	-	-	-	-	-	-	-	-	-	-	-	-	-	-	-	-	-	-	-	18	
20.	Fetus [#] 24 wks	1.60 Mb 34,822,465-36,418,529 (hg19)	bMCDK, bilateral cystic adenomatoid malformation	-	+	-	-	-	-	-	-	-	-	-	-	-	-	-	-	-	-	-	18	
21.	Fetus 25 wks	1.49 Mb 34,822,465-36,316,144 (hg19)	HK	-	-	-	-	-	-	-	-	-	-	-	-	-	-	-	-	-	-	-	18	
22.	Fetus 26 wks	1.58 Mb 34,822,465-36,404,555 (hg19)	HMDK	-	-	-	-	-	-	-	-	-	-	-	-	-	-	-	-	-	-	-	18	
23.	Fetus, male [#] 32 wks	1.93 Mb 34,477,479-36,404,104 (hg19)	bHMDK	-	+	-	-	-	-	-	-	-	-	-	-	-	-	-	-	-	-	-	19	
24.	Fetus [#] 32 wks	1.93 Mb 34,477,479-36,404,104 (hg19)	bHMDK	-	-	-	-	-	-	-	-	-	-	-	-	-	-	-	-	-	-	-	18	
25.	Fetus, female [#] 34 wks daughter of P79, sister of P11	n/a n/a, pat	bHK	-	-	-	-	-	-	-	-	-	-	-	-	-	-	-	-	-	-	+	7	
26.	n/a ^s n/a	1.58 Mb 34,822,465-36,404,555 (hg19)	HK	-	-	-	-	-	-	+	-	-	-	-	-	-	-	-	-	-	-	-	9	
27.	Male 1 m.o. son of P83	n/a n/a, mat	-	-	+	-	-	-	-	-	-	-	-	-	-	-	OHA	bMCK	+	-	-	-	+C	7
28.	Female 4 m.o.	1.49 Mb 34,822,465-36,311,009 (hg19)	HK	-	+	-	-	-	-	+	-	-	-	-	-	-	PHA	-	-	-	-	-	-	20
29.	Male 4 m.o.	1.43 Mb 31,889,297-33,323,037 (hg18) [34,815,184-36,248,924 (hg19)]	MK	-	-	-	-	-	-	+	-	-	-	-	-	-	OHA	MK	+	-	-	+	-	2
30.	Male 5 m.o. twin of P31	1.59 Mb 34,822,465-36,418,529 pat (hg19)	bHK mild renal PCD	-	+	-	-	-	-	-	-	-	-	-	-	-	PHA	HMK PCD AF	+	-	-	-	+ C	20
31.	Male 5 m.o. twin of P30	1.59 Mb 34,822,465-36,418,529 pat (hg19)	bHK mild renal PCD	-	-	-	-	-	-	-	-	-	-	-	-	-	-	bHMK AF	+	-	-	-	+ C	20
32.	n/a 7 m.o.	1.48 Mb 34,822,465, 36,307,773 (hg19)	RPS	-	-	-	-	-	-	-	-	-	-	-	-	-	-	-	-	-	-	-	-	9
33.	Male 7 m.o. son of P76	1.69 Mb 31,635,490-33,323,002 mat (hg18) [34,611,377-36,248,889 mat (hg19)]	bMK	-	+	-	-	-	-	-	-	-	-	-	-	-	-	bMK	+	-	-	+	+ C	4
34.	Male 9 m.o. son of P85	1.60 Mb 34,856,085-36,455,391 mat (hg19)	HK	-	-	-	-	-	-	-	-	-	-	-	-	-	PHA	MK	+	-	-	-	+ C	21
35.	Male 1 y 9 m.o. son of P88	1.38 Mb 31,893,783-33,277,865 mat (hg18) [34,819,670-36,203,752 mat (hg19)]	-	-	-	-	-	-	-	-	-	-	-	-	-	-	-	-	-	-	+	-	+ C	12
36.	Female 1 y 10 m.o.	1.38 Mb 31,893,783-33,277,865 (hg18) [34,819,670-36,203,752 (hg19)]	-	-	-	-	-	-	-	-	-	-	-	-	-	-	-	-	-	-	+	-	-	12

Continues on the next page

Continuation of the previous page

54.	Female 7 y.o. sibling of P34	1.40 Mb 31,923,035-33,323,544 mat (hg18) [34,848,922-36,249,431 mat (hg19)]	-	-	-	-	-	-	-	-	-	-	-	-	-	-	-	-	-	-	-	-	+C	22	
55.	Male 7 y.o.	n/a n/a	-	-	-	-	-	-	-	-	-	-	-	-	-	-	-	-	-	-	-	-	-	-	7
56.	Male 7 y.o.	1.38 Mb 31,893,783-33,277,865 (hg18) [34,819,670-36,203,752 (hg19)]	-	-	-	-	-	-	-	-	-	-	-	-	-	-	-	-	-	-	-	-	-	-	12
57.	Male 7 yrs 5 mo	1.80 Mb 34,475,679-36,283,807(hg19)	HN (22 weeks)	-	-	-	-	-	-	-	-	-	-	-	-	-	-	-	-	-	-	-	-	-	Patient C current study
58.	Male 8 y 8 m.o.	n/a n/a	-	-	-	-	-	-	-	-	-	-	-	-	-	-	-	-	-	-	-	-	-	-	27
59.	Male 9 y.o.	1.83 Mb 31,543,857-33,371,626 (hg18) [34,519,744-36,335,380 (hg19)]	HK, MCK, PY, HY	-	-	-	-	-	-	-	-	-	-	-	-	-	-	-	-	-	-	-	-	-	23
60.	Female 10 y.o. sister of P52, daughter of P89	n/a n/a, mat	-	-	-	-	-	-	-	-	-	-	-	-	-	-	-	-	-	-	-	-	-	-	7
61.	Male 10 y.o.	1.38 Mb 31,893,783-33,277,865 (hg18) [34,819,670-36,203,752 (hg19)]	-	-	-	-	-	-	-	-	-	-	-	-	-	-	-	-	-	-	-	-	-	-	12
62.	Male 10 y.o. son of P82	1.78 Mb 34,468,470-36,248,889 mat (hg19)	bHMK	-	-	-	-	-	-	-	-	-	-	-	-	-	-	-	-	-	-	-	-	-	21
63.	Female 12 y.o.	n/a n/a	-	-	-	-	-	-	-	-	-	-	-	-	-	-	-	-	-	-	-	-	-	-	27
64.	Female 12 y.o.	1.73 Mb 31,593,883-33,323,002 (hg18) [34,569,770-36,248,889 (hg19)]	bHMK	-	-	-	-	-	-	-	-	-	-	-	-	-	-	-	-	-	-	-	-	-	4
65.	Male 12 y.o.	1.38 Mb 31,893,783-33,277,865 (hg18) [34,819,670-36,203,752 (hg19)]	-	-	-	-	-	-	-	-	-	-	-	-	-	-	-	-	-	-	-	-	-	-	12
66.	Male 12 y.o.	1.43 Mb 34,816,255-36,244,358 (hg19)	-	-	-	-	-	-	-	-	-	-	-	-	-	-	-	-	-	-	-	-	-	-	5
67.	Female 13 y.o.	1.43 Mb 31,889,297-33,323,037 (hg18) [34,815,184-36,248,924 (hg19)]	MK	-	-	-	-	-	-	-	-	-	-	-	-	-	-	-	-	-	-	-	-	-	2
68.	Female 14 y.o.	n/a n/a	MCK	-	-	-	-	-	-	-	-	-	-	-	-	-	-	-	-	-	-	-	-	-	7
69.	Male 15 y 8 m.o.	1.42 Mb n/a	-	-	-	-	-	-	-	-	-	-	-	-	-	-	-	-	-	-	-	-	-	-	27
70.	Male 17 y.o.	1.89 Mb 34,464,879-36,352,140 (hg19)	-	-	-	-	-	-	-	-	-	-	-	-	-	-	-	-	-	-	-	-	-	-	28
71.	Female 18 y.o.	1.42 Mb n/a	-	-	-	-	-	-	-	-	-	-	-	-	-	-	-	-	-	-	-	-	-	-	27

Continues on the next page

Continuation of the previous page

72.	Female 18 y.o.	1.50 Mb n/a	-	-	-	-	-	-	-	-	-	-	-	-	-	-	-	-	-	-	-	-	-	-	29
73.	Female 19 y.o.	1.38 Mb 31,893,783-33,277,865 (hg18) [34,819,670-36,203,752 (hg19)]	-	-	-	-	-	-	-	-	-	-	-	-	-	-	-	-	-	-	-	-	-	-	12
74.	Female 20 y.o.	1.43 Mb 31,889,297-33,323,037 (hg18) [34,815,184-36,248,924 (hg19)]	-	-	-	-	-	-	-	-	-	-	-	-	-	-	-	-	-	-	-	-	-	-	2
75.	Male 20 y.o.	1.40 Mb n/a	-	-	-	-	-	-	-	-	-	-	-	-	-	-	-	-	-	-	-	-	-	-	30
76.	Female 22 y.o. mother of P33	1.69 Mb 31,635,490-33,323,002 (hg18) [34,611,377-36,248,889 (hg19)]	left MCDK	-	-	-	-	-	-	-	-	-	-	-	-	-	-	-	-	-	-	-	-	-	4
77.	Male 22 y.o.	1.38 Mb 31,893,783-33,277,865 (hg18) [34,819,670-36,203,752 (hg19)]	-	-	-	-	-	-	-	-	-	-	-	-	-	-	-	-	-	-	-	-	-	-	12
78.	Female 26 y.o.	1.58 Mb 34,790,209-36,373,398 (hg19)	MCK	-	-	-	-	-	-	-	-	-	-	-	-	-	-	-	-	-	-	-	-	-	31
79.	Male 26 y.o. father of P48, P50	n/a n/a	-	-	-	-	-	-	-	-	-	-	-	-	-	-	-	-	-	-	-	-	-	-	7
80.	Female 28 y.o. mother of P67	1.42 Mb 34,822,465-36,244,332 (hg19)	HK	-	-	-	-	-	-	-	-	-	-	-	-	-	-	-	-	-	-	-	-	-	18
81.	Female 28 y.o.	1.80 Mb n/a	-	-	-	-	-	-	-	-	-	-	-	-	-	-	-	-	-	-	-	-	-	-	27
82.	Female 29 y.o. mother of P24	1.78 Mb 34,468,470-36,248,889 (hg19)	bHMK	-	-	-	-	-	-	-	-	-	-	-	-	-	-	-	-	-	-	-	-	-	21
83.	Female 30 y.o. mother of P56	n/a n/a	-	-	-	-	-	-	-	-	-	-	-	-	-	-	-	-	-	-	-	-	-	-	7
84.	Female 32 y.o. mother of P46	n/a n/a	-	-	-	-	-	-	-	-	-	-	-	-	-	-	-	-	-	-	-	-	-	-	7
85.	Female 32 y.o. mother of P14	1.59 Mb 34,856,085-36,455,391 (hg19)	-	-	-	-	-	-	-	-	-	-	-	-	-	-	-	-	-	-	-	-	-	-	21
86.	Female 35 y.o.	1.58 Mb 34,822,465-36,404,104 (hg19)	-	-	-	-	-	-	-	-	-	-	-	-	-	-	-	-	-	-	-	-	-	-	32
87.	Female 36 y.o.	1.58 Mb 34,790,209-36,373,398 (hg19)	-	-	-	-	-	-	-	-	-	-	-	-	-	-	-	-	-	-	-	-	-	-	31
88.	Female 37 y.o. mother of P87	1.38 Mb 31,893,783-33,277,865 (hg18) [34,819,670-36,203,752 (hg19)]	-	-	-	-	-	-	-	-	-	-	-	-	-	-	-	-	-	-	-	-	-	-	12

Continues on the next page

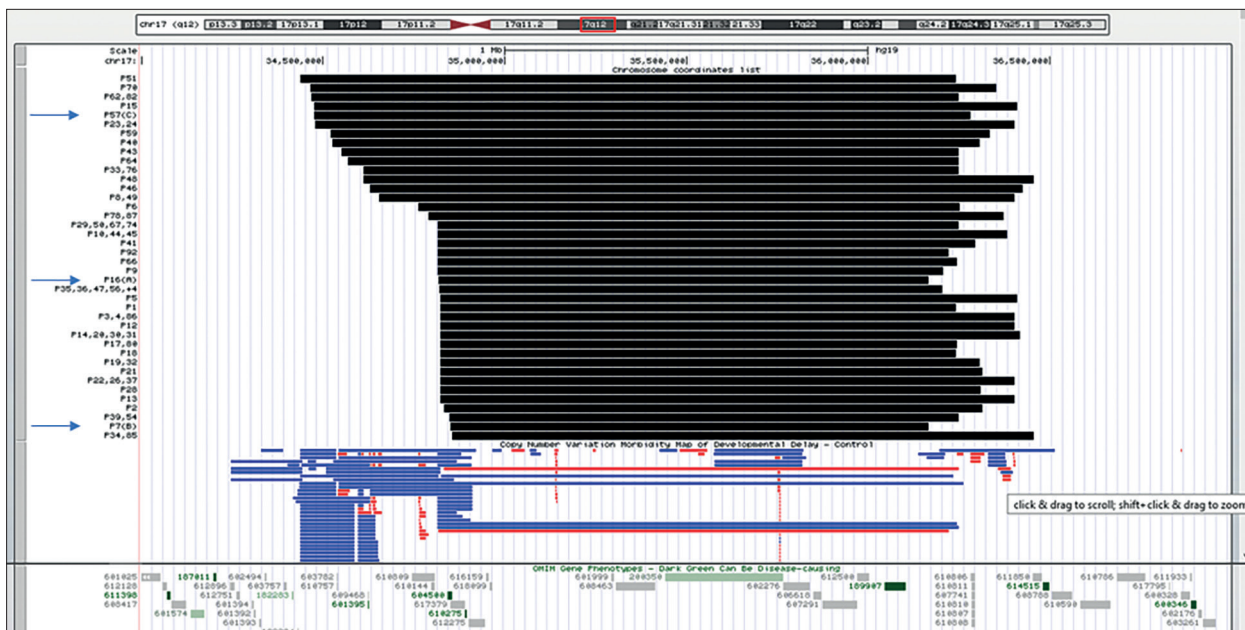


Figure 1. Graphical representation of the reported and reviewed deletions in UCSC browser. Patient ID is indicated according to Table 1. The arrows point the patients described in the current study.

with a partially overlapping clinical presentation with 17q12 deletion syndrome. Our first case strongly suggests that genetic testing should be considered for isolated or unilateral multicystic dysplastic kidneys, though current fetal medicine guidelines recommend invasive investigations only in bilateral forms or when other organs are involved (The FMF Foundation [40]). Nonetheless, 17q12 microdeletion should always be considered in patients with ASD, especially in association with developmental delay and kidney problems. 17q12 microdeletion syndrome is challenging due to the wide clinical spectrum and the high variability of this disorder even within the same family. In addition to the uncertainty regarding long-term postnatal outcome, more patients and more longitudinal studies should be considered in order to reach a higher degree of accuracy in the counselling of prospective parents.

ACKNOWLEDGEMENTS

The authors are grateful to the patients and their families. Also, we thank to Ms Eliza Rentea, MS, for technical assistance.

Declaration of Interest. The authors report no conflicts of interest. The authors alone are responsible for the content and writing of this article.

Funding Sources

Patient C was clinically investigated with support from the EEA RO-NO 6/2019 research grant.

REFERENCES

1. Mefford HC, Clauin S, Sharp AJ, Moller RS, Ullmann R, Kapur R *et al.* Recurrent reciprocal genomic rearrangements of 17q12 are associated with renal disease, diabetes, and epilepsy. *Am J Hum Genet.* 2007; 81: 1057–1069.
2. Nagamani SCS, Erez A, Shen J, Chumei L, Roeder E, Cox S *et al.* Clinical spectrum associated with recurrent genomic rearrangements in chromosome 17q12. *Eur J Hum Genet.* 2010; 18: 278-284.
3. Kasperavičiūtė D, Catarino CB, Chinthapalli K, Clayton LMS, Thom M, Martinian L *et al.* Uncovering genomic causes of co-morbidity in epilepsy: gene-driven phenotypic characterization of rare microdeletions. *PLoS ONE.* 6(8): e23182. doi:10.1371/journal.pone.0023182.
4. Dixit A, Patel C, Harrison R, Jarvis J, Hulton S, Smith N *et al.* 17q12 microdeletion syndrome: three patients illustrating the phenotypic spectrum, *Am J Med Genet A.* 2012; 158(9): 2317–2321.
5. Palumbo P, Antona V, Palumbo O, Piccione M, Nardello R, Fontana A *et al.* Variable phenotype in 17q12 microdeletions: clinical and molecular characterization of a new case, *Gene.* 2014; 538: 373–378.
6. Mitchel MW, Moreno-De-Luca D, Myers SM, Levy RV, Turner S, Ledbetter SH, *et al.* 17q12 recurrent deletion syndrome, *Gene Reviews*, initial post 2016.12.8, accessed 2020.12.14.

7. Rasmussen M, Vestergaard EM, Graakjaer J, Petkov Y, Bache I, Fagerberg C *et al.* 17q12 deletion and duplication syndrome in Denmark – a clinical cohort of 38 patients and review of literature. *Am J. Med Genet A.* 2016; 9999A: 1-9.
8. Laffargue F, Bourthoumieu S, Llanas B, Baudouin V, Lahoche A, Morin D *et al.* Towards a new point of view on the phenotype of patients with a 17q12 microdeletion syndrome. *Arch Dis Child.* 2015; 100: 259-264.
9. Wan S, Zheng Y, Dang Y, Song T, Chen B, Zhang J. Prenatal diagnosis of 17q12 microdeletion and microduplication syndrome in fetuses with congenital renal abnormalities. *Mol Cytogenet.* 2019; 12: 19-22.
10. Decramer S, Parant O, Beauflis S, Clauin S, Guillou C, Kessler S *et al.* Anomalies of the *TCF2* gene are the main cause of fetal bilateral hyperechogenic kidneys. *J. Am. Soc. Nephrol.* 2007; 18: 923-933.
11. Donnelly JC, Platt LD, Rebarber A, Zachary J, Grobman WA, Wapner RJ. Association of copy number variants with specific ultrasonographically detected fetal anomalies. *Obstetrics & Gynecol.* 2014; 124 (1): 83-90.
12. Moreno-De-Luca D, SGENE Consortium, Mulle JG, Simon Simplex Collection Genetics Consortium, Kaminsky EB, Sanders SJ *et al.* Deletion 17q12 is a recurrent copy number variant that confers high risk of autism and schizophrenia. *Am J Hum Genet.* 2010; 87(1): 618-630.
13. Xi Q, Zhu X, Wang Y, Ru T, Dai C, Wang Z *et al.* Copy number diagnosis variations in multicystic dysplastic kidney: update for prenatal diagnosis and genetic counseling. *Prenat Diagn.* 2016; 36: 463-468
14. Brabbing-Goldstein D, Reches A, Svirsky R, Bar-Shira A, Yaron Y – Dilemmas in genetic counseling for low-penetrance neuro-susceptibility loci detected on prenatal chromosomal microarray analysis. *Am J Obstetrics Gynecol.* 2017; <https://doi.org/10.1016/j.ajog.2017.11.559>.
15. Chen C-P, Chang S-D, Wang T-H, Wang L-K, Tsai J-D, Liu Y-P *et al.* Detection of recurrent transmission of 17q12 microdeletion by aCGH in a fetus with prenatally diagnosed hydronephrosis, hydroureter, and multicystic kidney, and variable clinical spectrum in the family. *Taiwanese J Obstetr Gynec.* 2013; 52: 551-557.
16. Hendrix NW, Clemens M, Canavan TP, Surti U, Rajkovic A. Prenatally diagnosed 17q12 microdeletion syndrome with a novel association with congenital diaphragmatic hernia. *Fetal Diagn Ther.* 2012; 31: 129-131.
17. Gilboa Y, Perlman S, Pode-Shakked N, Pode-Shaked B, Shrim A, Azaria-Lahov E *et al.* Prenatal diagnosis of 17q12 deletion syndrome: from fetal hyperechogenic kidneys to high risk for autism. *Prenat Diagn.* 2016; 36: 1027-1032.
18. Jing X-Y, Huang L-Y, Zhen L, Han J, Li D-Z. Prenatal diagnosis of 17q12 deletion syndrome: a retrospective case of series. *J Obstetrics Gynaecol.* 2019; <https://doi.org/10.1080/01443615.2018.1519693>
19. Li R, Fu F, Zhang Y-L, Li D-Z, Liao C. Prenatal diagnosis of 17q12 duplication and deletion syndrome in two fetuses with congenital anomalies. *Taiwanese Obstetrics & Gynecol.* 2014; 53: 579-582.
20. Yap P, McGillivray G, Norris F, Said JM, Kornman L, Stark Z. Fetal phenotype of a 17q12 microdeletion syndrome: renal echogenicity and congenital diaphragmatic hernia in 2 cases. *Prenat Diagn.* 2015; 35: 1265-1267.
21. Jones GE, Mousa HA, Rowley H, Houtman P, Vasudevan PC. Should we offer prenatal testing for 17q12 microdeletion syndrome to all cases with prenatally diagnosed echogenic kidneys? Prenatal findings in two families with 17q12 microdeletion syndrome and a review of the literature. *Prenat Diagn.* 2015; 35: 1336-1341.
22. George AM, Love DR, Hayes I, Tsang B. Recurrent transmission of a 17q12 microdeletion and a variable clinical spectrum. *Mol Syndromology.* 2012; 2(2): 72–75.
23. Loirat C, Bellanne-Chantelot C, Husson I, Deschenes G, Guignon V, Chabane N. Autism in three patients with cystic or hyperechogenic kidneys and chromosome 17q12 deletion. *Nephrol. Dial. Transplant.* 2010; 25: 3430-3433.
24. Quintero-Rivera F, Woo JS, Bomberg EM, Wallace WD, Peredo J, Dipple KM. Duodenal atresia in 17q12 microdeletion including *HNF1B*: A new associated malformation in this syndrome. *Am J Med Genet Part A.* 2014; 164A: 3076–3082.
25. Goumy C, Laffargue F, Eymard-Pierre E, Kemeny S, Gay-Bellile M, Gouas L *et al.* Congenital diaphragmatic hernia may be associated with 17q12 microdeletion syndrome. *Am J Med Genet Part A.* 2015; 167A: 250–253.
26. Kaman K, Soffer G, Mitson-Salazar A. 17q12 and atopy; missing pieces of the puzzle? Abstracts: Medically Challenging Cases Abstracts/Ann Allergy Asthma Immunol. 2019; 123: S64eS142\
27. Vasileiou G, Hoyer J, Thiel CT, Shaefer J, Zapke M, Krumbiegel M *et al.* Prenatal diagnosis of *HNF1-*

- associated renal cysts: need to differentiate intragenic variants from 17q12 microdeletion syndrome? *Prenat Diagn.* 2019; 39(12): 1136-1147.
28. Roberts JL, Gandomi SK, Parra M, Lu I, Gau C-L, Dasouki M *et al.* Clinical report of a 17q12 microdeletion with additionally unreported clinical features. *Case Rep Genet.* 2014; DOI: dx.doi.org/10.1155/2014/264947.
 29. Andersen BB, Schaffalitzky de Muckadell OB. [17q12 deletion as possible cause of agenesis of the dorsal pancreas and polycystic kidney disease]. *Ugeskrift for Laeger.* 2019; 181(47): Language:dan PMID: 31791446
 30. Siolos A, Merkoviti A, Georgiu I, Siomou E, Tigas S. Congenital anomaly of the kidney and urinary tract and MODY 5 due to 17q12 deletion syndrome; a case report. *Endocrine Abstracts 2020;70 AEP450* | DOI: 10.1530/endoabs.70.AEP450
 31. Roehlen N, Hilger H, Stock F, Gläser B, Guhl J, Schmitt-Graeff A *et al.* 17q12 deletion syndrome as a rare cause for diabetes mellitus type MODY5. *J Clin Endocrinol Metab.* 2018; 103(10): 3601-3610.
 32. Du T, Zeng N, Wen X, Zhu P, Li W. A rare combination of MODY and duodenal atresia in a patient: a case report. *BMC Med Genet.* 2020; 21: 24-28.
 33. Velamani S, Gonuguntla K, Perosevic N, Vigneault C. Severe resistant hypomagnesemia as the first clinical presentation of 17q12 microdeletion syndrome, Chest Annual Meeting, Medical Student/Resident Critical Care Posters, 2020.
 34. Li HJ, Groden C, Hoenig MP, Ray EC, Ferreira CR, Gahl W *et al.* Case report: coronary calcifications and hypomagnesemia in a patient with a 17q12 deletion involving *HNF1B*. *BMJ Nephrol.* 2019; 20: 353-358.
 35. Jiang YL, Qi QW, Zhou XY, Geng FF, Bai JJ, Hao N *et al.* Prenatal diagnosis of 17q12 microdeletion syndrome in fetal renal abnormalities. *Zhonghua Fu Chan Ke Za Zhi.* 2017; 52(10): 622-668.
 36. Rosenfeld JA, Coe BP, Eichler EE, Cuckle H, Shaffer LG. Estimates of penetrance for recurrent pathogenic copy-number variations. *Genet Med.* 2013; 15(6): 478-481.
 37. Clissold RL, Shaw-Smith C, Turnpenny P, Bunce B, Bockenbauer D, Kerecuk L *et al.* Chromosome 17q12 microdeletions but not intragenic *HNF1B* mutations link developmental kidney disease and psychiatric disorder. *Kidney Intl.* 2016; 90: 203–211.
 38. Laliève F, Decramer S, Heidet L, Baudouin V, Lahoche A, Llanas B *et al.* School level of children carrying a *HNF1B* variant or a deletion. *Eur J Hum Genet.* 2020; 28: 56–63.
 39. Murray PJ, Thomas K, Mulgrew CJ, Ellard S, Edghill EL, Bingham C *et al.* Whole gene deletion of the hepatocyte nuclear factor-1beta gene in a patient with the prune-belly syndrome. *Nephrol. Dial. Transplant.* 2008; 23: 2412–2415.
 40. The Fetal Medicine Foundation, <https://fetalmedicine.org/education/fetal-abnormalities/urinary-tract/multicystic-kidneys>, (accessed 2020, May 24)