

Available online at [www.sciencedirect.com](http://www.sciencedirect.com)
**ScienceDirect**
journal homepage: [www.elsevier.com/locate/radcr](http://www.elsevier.com/locate/radcr)
**Case report**
**Multi-organ infarction following percutaneous transhepatic esophageal variceal obliteration with glue injection: a case report** ☆☆☆

 Alireza Abrishami, M.D., MBA<sup>a</sup>, Mahsa Alborzi Avanaki, M.D.<sup>b</sup>, Nastaran Khalili, M.D., M.P.H.<sup>c,d</sup>, Mohammad Taher, M.D.<sup>e,f</sup>, Hossein Ghanaati, M.D.<sup>g,\*</sup>
<sup>a</sup> Department of Radiology, Shahid Labbafinejad Hospital, Shahid Beheshti University of Medical Sciences, Tehran, Iran

<sup>b</sup> Advanced Diagnostic and Interventional Radiology Research Center (ADIR), Tehran University of Medical Sciences, Tehran, Iran

<sup>c</sup> School of Medicine, Tehran University of Medical Sciences, Tehran, Iran

<sup>d</sup> Cancer Immunology Project (CIP), Universal Scientific Education and Research Network (USERN), Tehran, Iran

<sup>e</sup> Division gastroenterology & hepatology, Tehran University of Medical Sciences, Imam Khomeini Hospital Complex, Tehran, Iran

<sup>f</sup> Liver Transplantation Research Center, Tehran University of Medical Sciences, Tehran, Iran

<sup>g</sup> Advanced Diagnostic and Interventional Radiology Research Center (ADIR), Imam Khomeini Hospital Complex, Tehran University of Medical Sciences, Tehran, Iran

**A R T I C L E I N F O**
**Article history:**

Received 7 April 2021

Accepted 11 April 2021

**Keywords:**

Case report

Esophageal varices

Glue

Infarct

Transhepatic

**A B S T R A C T**

Percutaneous transhepatic variceal obliteration (PTVO) is currently one of the best treatment options for controlling acute recurrent bleeding in cirrhotic patients. Nevertheless, this procedure is associated with major and minor complications such as fever, pain, fatal intraperitoneal hemorrhage, and rarely, embolization of embolic agents to the systemic circulation. Only one study has reported systemic emboli following the use of glue-lipiodol mixture for percutaneous transhepatic embolization of esophageal varices and here we report another case of this complication. Here, we report a 44-year-old man presenting with multi-organ infarction following PTVO with glue-Lipiodol mixture. He was a known case of liver cirrhosis who was admitted for recurrent bleeding from esophageal varices. The patient became a candidate for transjugular intrahepatic portosystemic shunt surgery; however, he did not provide consent for this procedure. The patient eventually decided to undergo PTVO as an alternative option. Twelve hours after the procedure, the patient developed neurological symptoms such as left side weakness, dysarthria, and fecal incontinence. Further investigation showed glue particles in brain, liver, spleen and both lungs. Contrast echocardiography and splenoportography did not show any evidence of right-to-left shunt. Thus, conservative management was initiated for the patient, which resulted in the gradual improvement after three weeks. Prior evaluation with splenoportography and contrast echocardiography

☆ Acknowledgments: Not applicable

☆☆ Competing interests: The authors declare the existence of a financial/non-financial competing interest.

\* Corresponding author.

 E-mail address: [ghanaati@yahoo.com](mailto:ghanaati@yahoo.com) (H. Ghanaati).

<https://doi.org/10.1016/j.radcr.2021.04.032>

 1930-0433/© 2021 The Authors. Published by Elsevier Inc. on behalf of University of Washington. This is an open access article under the CC BY-NC-ND license (<http://creativecommons.org/licenses/by-nc-nd/4.0/>)

before performing PTVO may help in the early detection of any connection with systemic circulation. Also, based on the desired procedure, the most appropriate glue/Lipiodol ratio and injection technique should be selected to minimize the risk of adverse events.

© 2021 The Authors. Published by Elsevier Inc. on behalf of University of Washington.

This is an open access article under the CC BY-NC-ND license

(<http://creativecommons.org/licenses/by-nc-nd/4.0/>)

One of the most serious complications of hepatic cirrhosis is the development of esophageal varices. Gradual enlargement of the dilated veins and rupture of the esophageal varices can lead to severe and life-threatening acute hemorrhage [1]. The first step in the management of esophageal varices is to prevent acute bleeding by administering nonselective  $\beta$ -Blockers or performing endoscopic band ligation [2]. Nevertheless, if acute variceal bleeding occurs, a combination of vasoactive agents, antibiotics, blood transfusion and endoscopic band ligation is recommended as the standard treatment approach. In case of recurrent variceal bleeding despite conventional treatments, percutaneous transhepatic variceal obliteration (PTVO) is considered as an alternative option to control acute bleeding [3]. To date, only one study has reported systemic emboli and infarction as an adverse event following glue injection for PTVO of esophageal varix [4]. Herein, we report a patient with liver cirrhosis who developed neurological symptoms and visceral emboli 12 hours after left gastric vein embolization via PTVO.

## Case report

A 44-year-old man with autoimmune hepatitis was admitted for recurrent upper gastrointestinal bleeding, which was repeated every two weeks. The patient complained of severe, recurrent esophageal varices (F3 varices) and rectorrhagia from four years ago, despite compliance to medical treatment. His past medical history was negative for refractory ascites. Physical examination was unremarkable; Here is the list of the patient's drugs: Furosemide 40 mg two times a day, Spironolactone 25 mg once a day, Propranolol 10 mg once a day, Pantoprazole 40 mg once a day. Upon admission, significantly low hemoglobin and hematocrit levels were detected (Table 1); thus, several transfusions of packed red blood cells were administered. Considering the patients' medical history, he became a candidate for transjugular intrahepatic portosystemic shunt; however, he did not provide consent for this procedure. Percutaneous transhepatic variceal obliteration (PTVO) was suggested as an alternative option. The patient eventually agreed to undergo variceal embolization via PTVO for the treatment of his condition.

For PTVO, the patient underwent general anesthesia and percutaneous transhepatic puncture was performed under the guidance of ultrasound using an 18-gauge Chiba needle. Splenoportography and mesenteric venography revealed inferior mesenteric vein and superior mesenteric vein (IMV-SMV) confluence along with small serpiginous collaterals.

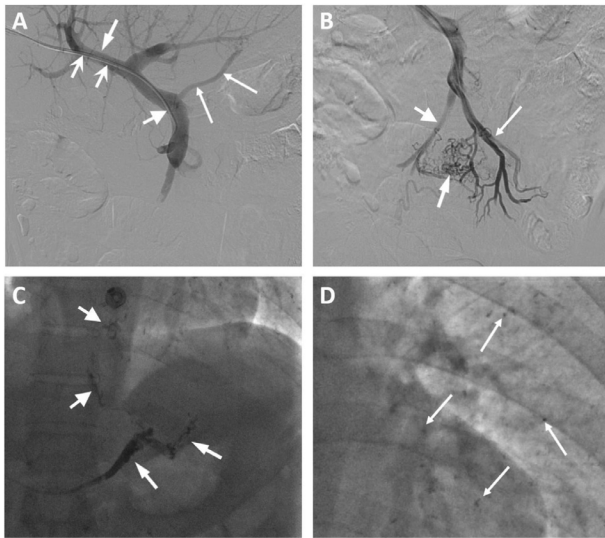
**Table 1 – Patients laboratory findings at the admission time.**

Lab test	Unit	Value	Normal range
Red Blood Cell	( $10^6/\text{mm}^3$ )	3.31	4.7–6.1
Hemoglobin	(g/dl)	7.4	13.5–17.5
Hematocrit	(%)	26.2	41–50
Platelet	( $10^3/\text{mm}^3$ )	130	150–450
Prothrombin Time	(s)	12.6	11–13.5
Partial thromboplastin time	(s)	32	26–40
International normalized ratio	(INR)	1.03	0.8–1.1
Aspartate transaminase	(U/L)	54.3	5–40
Alanine transaminase	(U/L)	40	7–56
Alkaline phosphatase	(U/L)	99.5	50–300
Bilirubin total	(mg/dl)	2	0.1–1.2
Bilirubin direct	(mg/dl)	1.2	<0.3
Albumin	(g/dl)	3.7	3.5–5.5

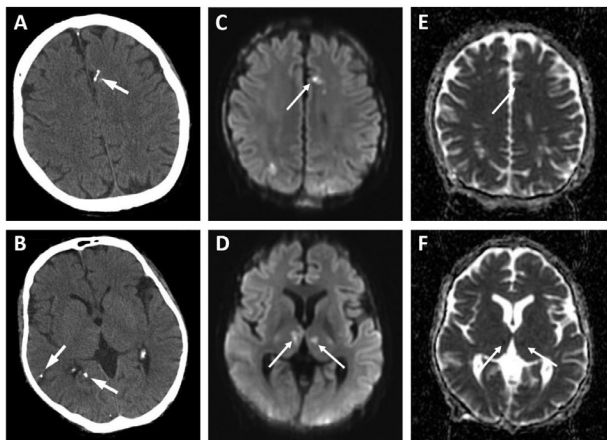
The left gastric vein (LGV) and the splenic vein flowed into the proximal part of the main portal vein and the IMV-SMV confluence, respectively (Fig. 1 A and B). Rectal varices and other collateral circulations connecting directly to the systemic circulation (such as the inferior vena cava) were not seen.

Super selective venography showed varix of the LGV and esophageal branches. Using the glue injection sandwich technique, embolization of the gastroesophageal varix was performed with 4.5 cc of glue (IFABOND surgical adhesive 1ml) and Lipiodol (Ethiodized oil 480 mg/ml) mixture, starting with a concentration of 25% (1:3) for esophageal varix and increasing to a concentration of 50% (1:1) for LGV (Fig. 1C).

Twelve hours after the procedure, while in the intensive care unit, the patient developed neurological symptoms such as left side weakness (muscle force: 4/5), dizziness, dysarthria, left eye ptosis and fecal incontinence. Nevertheless, the patient remained oriented and obeyed orders, and had a normal respiratory pattern. On neurological examination, both pupils were isochoric and reacted equally to light. There was no Ophthalmoparesis and flattened nasolabial folds were noted on the right side. Following the occurrence of these symptoms, neurologic and cardiac consultation was immediately requested. Computed tomography (CT) scan of the brain revealed multifocal, high-density lesions in the brain parenchyma and the subarachnoidal space. Brain magnetic resonance imaging showed multiple, restricted foci in the cortex, subcortex and basal ganglia of both cerebral hemispheres. The foci were also seen in the left cerebellar hemisphere and the right midbrain. These findings were compatible with acute ischemic lesions due to an embolic event (Fig. 2). Subsequent contrast echocardiography did



**Fig. 1** – Percutaneous transhepatic portography with selective catheterization of the coronary vein and inferior mesenteric vein–superior mesenteric vein confluence. (A) Portogram demonstrates a 6F vascular sheath (wide arrows) in a right portal vein branch (arrow) and a 5F Cobra catheter (thick arrow) within the main portal vein. The left gastric vein (thin arrows) confluence is noted in the proximal of the main portal vein. (B) Superior mesenteric venogram shows inferior mesenteric vein (thick arrow)–superior mesenteric (thin arrow) vein confluence with serpiginous varicoid collaterals (arrow). (C) The left gastric vein (arrow) and esophageal varix (thick arrow) are successfully occluded by glue-Lipiodol mixture. (D) Retrospective venogram evaluation shows multiple small foci in both lungs, in favor of glue-Lipiodol emboli (thin arrows).



**Fig 2** – (A, B) Axial brain CT images without iodinated contrast material. Note multiple high attenuation foci (glue-Lipiodol mixture emboli) (arrow) in the frontal lobe and the parieto-occipital lobe. (C-F) Multiple lesions appear as hyperintense lesions (thin arrow) on diffusion-weighted imaging and as hypointense lesions (thin arrow) in the frontal lobe and thalamus on apparent diffusion coefficient map. The lesions were considered as microinfarcts.

not show any evidence for the presence of an intracardiac shunt.

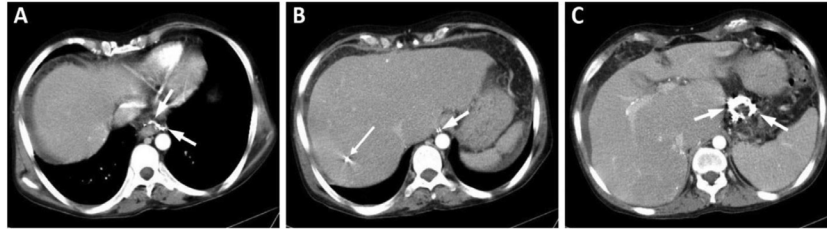
Conservative treatment including rehabilitation therapy was initiated for the patient, resulting in the improvement of neurological symptoms after approximately three weeks. Follow-up abdominal CT with iodinated contrast agent indicated successful embolization of the gastroesophageal varices although accompanied by minor infarction of the liver and spleen due to glue emboli (Fig. 3). Also, angiographic re-evaluation displayed multiple, small glue emboli in both lungs (Fig. 1D). After one and a half months from discharge, the patient has remained asymptomatic without any sign(s) of further neurologic abnormality.

## Discussion

Esophageal varices develop in approximately 50% of patients with liver cirrhosis; about one-third of these patients are at risk of variceal bleeding within two years. In the case of re-bleeding, about 20% of patients will not survive [5]. Patients with persistent severe acute bleeding or those with recurrent bleeding will require interventional hemostatic measures such as endoscopic sclerotherapy, band ligation, tissue adhesive injection or shunt surgery, in addition to medical therapy [5].

PTVO was first introduced in 1974 as a non-surgical approach for the management of esophageal variceal bleeding [6]. It is considered as an alternative approach for the treatment of gastroesophageal varices in patients with recurrent bleeding who are resistant to medical therapy and who are not suitable candidates for surgery. As with any other invasive procedure, PTVO is also associated with adverse effects including fatal intraperitoneal hemorrhage, hemopneumothorax, portal vein thrombosis or picture of intra-abdominal organs near the introductory site. Another rare but serious complication of PTVO is the introduction of therapeutic embolic agents to the systemic circulation [7].

Several studies have reported infarction following the use of embolic agents such as gel foam during transhepatic variceal obliteration [7,8]; however, only one study has previously reported systemic emboli following the use of glue for PTVO, as in our case [4]. Lee et al. reported a case of an 11-year-old girl with Caroli syndrome with a history of recurrent bleeding of grade III esophageal varices. Due to failed attempts of transjugular intrahepatic portosystemic shunt, the patient became a candidate for PTVO; however, she developed neurologic abnormalities 20 hours after the procedure. Further investigation revealed systemic embolization of glue particles found in the lung, kidney, liver, brain and stomach. There was no right-to-left shunt on contrast echocardiography and the patient improved gradually with conservative therapy within a month [4]. Other studies reported cases of systemic embolization following the injection of gel foam into the coronary and short gastric veins [7–9]. Autopsy of two cases showed numerous gel foam particles in different parts such as the lungs, brain, spleen and heart with no evidence of an intracardiac right-to-left shunt [7]. Interestingly, the entrance of particles into the pulmonary circulation has been reported in the



**Fig 3 – (A-C) Follow-up axial abdominopelvic CT with iodinated contrast, three days after embolization with glue-Lipiodol mixture. Successful left gastric vein and esophageal varix embolization (arrow) is evident in the gastrohepatic and para-esophageal spaces. A hyperdense focus is noted in the liver (segment VII) in favor of glue-Lipiodol emboli (thin arrow).**

autopsy of asymptomatic cases with normal perfusion scans who do not display any clinical signs of pulmonary emboli [8].

Numerous studies have reported systemic embolization and multi-organ infarction as a consequence of endoscopic sclerotherapy of esophageal varix using N-butyl-2-cyanoacrylate (hystoacryl). Endoscopic hystoacryl glue injection has been reported to be associated with cerebral and pulmonary embolization, superior mesenteric vein thrombosis, splenic vein thrombosis, portal vein thrombosis, and even cortical blindness [10–12].

It is proposed that two major communications including the portosystemic and porto-pulmonary anastomoses account for systemic embolization by creating right-to-left shunt as well as intracardiac right-to-left shunt [7]. Warren et al. reported three patients who developed spontaneous shunt from the left gastric vein directly to the inferior vena cava, resulting in embolization of the injected material to the pulmonary arteries [9]. In portal hypertension (PHT), a group of portosystemic collaterals such as paraesophageal anastomoses forms to help redirect the blood flow to the systemic circulation and reduce the pressure on the portal system. In PHT, bidirectional venous flow at the palisading zone of esophageal venous drainage provides a high-resistant portosystemic region, causing blood accumulation and varix formation. Esophageal and paraesophageal collaterals are supplied by the anterior and posterior branch of the LGV, respectively, and eventually drain into the left subclavian-brachiocephalic and azygos system. During percutaneous variceal obliteration, the inferior end of the esophagus anastomoses can cause pulmonary artery embolization via the azygos system but it is unlikely that particles larger than red blood cells can enter the systemic circulation through this pathway. A possible pathway is that portopulmonary anastomoses which result from the pressure difference between paraesophageal (high pressure) and pulmonary (low pressure) veins may provide a right-to-left shunt, facilitating the dissemination of embolic particles to the systemic circulation. The venous drainage of the pulmonary hilar region is via the azygos system; however, there are several microscopic anastomoses with pulmonary veins within the drainage of intrapulmonary bronchi, which result in bronchial-pulmonary collaterals that can be fed by the efferent veins of esophageal varices [7,13]; these communications also produce another pathway for injected particles to enter the systemic arterial circulation. Contrast echocardiography is one of the best avail-

able modalities for diagnosing portopulmonary anastomoses [14]. In this case, we performed contrast echocardiography and splenoportography, which revealed no right-to-left shunt except for an IMV–SMV confluence.

For successful embolization, the most efficient injection speed and optimal glue/Lipiodol ratio should be considered. Three major techniques of glue injection have been reported: A) continuous column method; a slow and continuous injection that forms a cast-like structure in the lumen, B) intermittent or pumping injection, and C) sandwich technique; the injection of glue with a bolus of dextrose. It seems that large intermittent injection of glue is more effective than the sandwich technique we used in preventing systemic embolization [15].

Another method mentioned in the literature is the balloon-assisted percutaneous transhepatic antegrade embolization approach. In this method, a balloon catheter is inserted into the desired veins and is then inflated proximal to the occlusion site. Subsequently, embolization of the major feeding veins is performed. This temporary balloon-assisted occlusion of veins can help in preventing ectopic embolization [16].

In addition to the injection technique, the glue/Lipiodol ratio varies depending on the diameter of the target vessel, blood velocity, and the distance of the lesion to the tip of the catheter. Increasing the proportion of Lipiodol delays glue polymerization; this is due to decreasing the contact of glue with plasma, which helps the mixture to move further and occlude a longer segment of the vessel [15]. In our study, a glue/Lipiodol mixture ratio of 1:3 resulted in systemic emboli. In the study by Lee et al., embolization occurred following the use of a very low glue concentration (1:16) [4]. Thus, it can be concluded that high concentration of glue ( $\geq 50\%$  of the mixture) is suitable for short segment occlusion as well as obliteration of dilated vessels without risk of glue migration [15].

It can be concluded that before performing the embolization procedure, precise evaluation with splenoportography may help in the early detection of any connection between the collateral and systemic circulation, and subsequently prevent unexpected complications. Also, if feasible, all patients should undergo contrast echocardiography before the embolization to check for the presence of possible cardiac anomalies. In addition, depending on the desired procedure, the most appropriate glue/Lipiodol ratio and injection technique must be selected. It is better not to use the sandwich technique due to an

increased risk of uncontrolled distribution of the glue/Lipiodol mixture and higher concentrations of glue are recommended for successful embolization. Still, the mechanism for systemic emboli following transhepatic embolization of esophageal varices in patients without portopulmonary communication is unclear and more studies are recommended to elucidate the exact pathway.

---

### Patient consent

The patient was informed about reporting a case and gave consent to participate in this study.

---

### Consent for publication

Consent was obtained from the patient to publish related medical information and images in medical publications.

---

### REFERENCE

- [1] Garcia-Tsao G, Bosch J. Management of varices and variceal hemorrhage in cirrhosis. *N Engl J Med* 2010;362(9):823–32.
- [2] Garcia-Tsao G, Sanyal AJ, Grace ND, Carey WD. Prevention and management of gastroesophageal varices and variceal hemorrhage in cirrhosis. *Am J Gastroenterol* 2007;102(9):2086–102.
- [3] Benner KG, Keeffe EB, Keller FS, Rösch J. Clinical outcome after percutaneous transhepatic obliteration of esophageal varices. *Gastroenterology* 1983;85(1):146–53.
- [4] Lee YM, Lee Y, Choe YH. Stroke after percutaneous transhepatic variceal obliteration of esophageal varix in Caroli syndrome. *Korean J Pediatr* 2013;56(11):500–4.
- [5] Habib A, Sanyal AJ. Acute variceal hemorrhage. *Gastrointest Endosc Clin N Am* 2007;17(2):223–52 v.
- [6] Lunderquist A, Vang J. Transhepatic catheterization and obliteration of the coronary vein in patients with portal hypertension and esophageal varices. *N Engl J Med* 1974;291(13):646–9.
- [7] Ellman BA, Curry TS 3rd, Glotzbach RE, Simpson PR. Systemic embolization as a complication of transhepatic venography. *Radiology* 1981;141(1):67–71.
- [8] Mendez G Jr, Russell E. Gastrointestinal varices: percutaneous transhepatic therapeutic embolization in 54 patients. *AJR Am J Roentgenol* 1980;135(5):1045–50.
- [9] Widrich WC, Robbins AH, Nabseth DC, Johnson WC, Goldstein SA. Pitfalls of transhepatic portal venography and therapeutic coronary vein occlusion. *AJR Am J Roentgenol* 1978;131(4):637–43.
- [10] Myung D-S, Chung C-Y, Park H-C, Kim J-S, Cho S-B, Lee W-S, et al. Cerebral and splenic infarctions after injection of N-butyl-2-cyanoacrylate in esophageal variceal bleeding. *World J Gastroenterol* 2013;19(34):5759–62.
- [11] Upadhyay AP, Ananthasivan R, Radhakrishnan S, Zubaidi G. Cortical blindness and acute myocardial infarction following injection of bleeding gastric varices with cyanoacrylate glue. *Endoscopy* 2005;37(10):1034.
- [12] Al-Hillawi L, Wong T, Tritto G, Berry PA. Pitfalls in histoacryl glue injection therapy for oesophageal, gastric and ectopic varices: A review. *World J Gastrointest Surg* 2016;8(11):729–34.
- [13] Philips CA, Arora A, Shetty R, Kasana V. A Comprehensive Review of Portosystemic Collaterals in Cirrhosis: Historical Aspects, Anatomy, and Classifications. *Int J Hepatol* 2016;2016:6170243.
- [14] Sano A, Nishizawa S, Sasai K, Imanaka K, Tanaka K, Hashimura T, et al. Contrast echocardiography in detection of portopulmonary venous anastomosis. *AJR Am J Roentgenol* 1984;142(1):137–40.
- [15] Takeuchi Y, Morishita H, Sato Y, Hamaguchi S, Sakamoto N, Tokue H, et al. Guidelines for the use of NBCA in vascular embolization devised by the Committee of Practice Guidelines of the Japanese Society of Interventional Radiology (CGJSIR), 2012 edition. *Jpn J Radiol* 2014;32(8):500–17.
- [16] Wang G, Meng D, Huang G, Pei Q, Zhao L, Shi Y, et al. Balloon-assisted percutaneous transhepatic antegrade embolization with 2-octyl cyanoacrylate for the treatment of isolated gastric varices with large gastrosplenic shunts. *BioMed Res Int* 2019;2019:2674758.