



Contents lists available at ScienceDirect

Indian Pacing and Electrophysiology Journal

journal homepage: www.elsevier.com/locate/IPEJ

Transhepatic permanent pacing in a child with complex cyanotic heart disease after total cavo pulmonary shunt (Kawashima repair)



Anilkumar Singhi, Ejaz Ahmed Sheriff, Kothandam Sivakumar*

Department of Pediatric Cardiology, Institute of CardioVascular Diseases, Madras Medical Mission, Chennai, 600037, India

ARTICLE INFO

Article history:

Received 23 November 2015

Received in revised form

2 April 2016

Accepted 18 June 2016

Available online 20 June 2016

Keywords:

Transhepatic access

Permanent pacing

Complete heart block

Endocardial screw-in lead

ABSTRACT

Complex cyanotic congenital heart diseases with left isomerism are sometimes associated with atrioventricular nodal conduction disturbances that may need permanent pacing. Surgical palliation in such anatomy connecting the superior vena cava to the pulmonary artery precludes a transvenous access for an endocardial pacing lead to the ventricles. Epicardial leads in these patients fail if the pacing thresholds are very high. We report transhepatic permanent ventricular lead implantation for a young boy with heterotaxy complicated by complete heart block.

Copyright © 2016, Indian Heart Rhythm Society. Production and hosting by Elsevier B.V. This is an open access article under the CC BY-NC-ND license (<http://creativecommons.org/licenses/by-nc-nd/4.0/>).

1. Introduction

Certain complex cyanotic congenital heart diseases in the setting of atrioventricular discordance, univentricular hearts and left isomerism can be associated with atrioventricular nodal conduction disturbances [1]. Bradycardia in these patients may adversely affect their precarious hemodynamics and often need permanent pacemaker implantation [2]. Bradycardia in these patients may be diagnosed either at birth or at a later age in the natural history of the disease. Surgical palliation in these complex anatomy involves cavo pulmonary anastomosis (Bidirectional Glenn shunt, Kawashima operation or Fontan surgery). Epicardial lead placement by thoracotomy or sternotomy and placement of pulse generator in the subrectus sheath in abdominal wall or in the subpleural pocket within the thorax is the standard therapy as transvenous ventricular lead placement is impossible after a cavo pulmonary shunt. This epicardial lead insertion carries a risk of higher pacing thresholds and need for more invasive surgery than a transvenous endocardial pacing [3]. We report percutaneous

placement of pacing lead through hepatic vein in a patient with left isomerism and complete heart block who underwent Kawashima operation.

2. Case report

A seven years old Kenyan patient with oxygen saturations of 80% was diagnosed with complex congenital heart disease. He had left isomerism, azygos continuation of interrupted inferior vena cava, common atrium, common atrioventricular valve, single ventricle, severe valvar and supra-valvar pulmonary stenosis. His preoperative electrocardiogram showed wandering pacemaker, complete heart block with ventricular rate of 45/minute (Fig. 1). Catheterization hemodynamics showed acceptable pulmonary artery pressures and pulmonary vascular resistance for univentricular palliation. His preoperative hospital admission was complicated by suppurative otitis media caused by *Pseudomonas aeruginosa*, which was treated by appropriate antibiotics.

He underwent Kawashima repair (surgical end to side anastomosis of superior vena cava to right pulmonary artery without ligation of the azygos vein which allows entire systemic venous return to reach pulmonary circulation with exception of the hepatic venous return), main pulmonary artery ligation and temporary epicardial ventricular pacing wire placement for pacing in the post operative period.

A permanent pacing lead and pulse generator was not

* Corresponding author. Head of department of Pediatric Cardiology, Institute of CardioVascular Diseases, Madras Medical Mission, 4A, Dr J J Nagar, Mogappair, Chennai 600037, India.

E-mail address: drkumarsiva@hotmail.com (K. Sivakumar).

Peer review under responsibility of Indian Heart Rhythm Society.

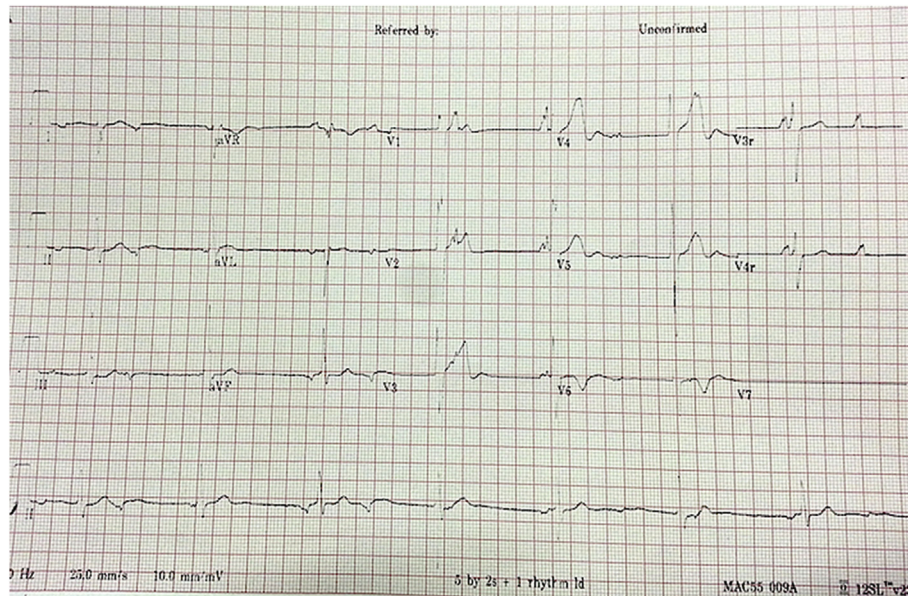


Fig. 1. Electrocardiogram showing complete heart block, ventricular rate 45 per minute, narrow QRS complexes and wandering pacemaker.

implanted in view of recent active ear infection. During the post-operative course in the intensive care, the ventricular pacing thresholds in the temporary epicardial leads were very high (12 mA in the constant voltage temporary pacemaker) and progressively increased raising doubts about the suitability of permanent epicardial pacing leads. An endocardial pacing lead placement was actively considered since the epicardial thresholds were unacceptable. In view of avoiding a second major surgery after recovery from a recent ear infection, he was planned for a transhepatic endocardial lead placement into the ventricles and connecting the pacing lead to a permanent generator in the subrectus sheath in the anterior abdominal wall. All antiplatelet and anticoagulant drugs were withdrawn before the procedure. Since echocardiogram showed good delineation of the hepatic veins, no additional tomographic imaging were performed.

Under ultrasound guidance transhepatic access was obtained through subxiphoid window through an appropriate hepatic vein tributary that finally reached the atrium. The liver was in midline and so both the right and left hepatic veins were converging towards the atrium in the subxiphoid area. A 0.025" short wire passed through this access to atrium and a short 6French introducer sheath was introduced into the atria. Even though a 7French introducer was recommended for the lead, a smaller sheath was chosen to give the lead a snug fit around the liver parenchyma and prevent a perilead bleeding. An endocardial screwing permanent pacing lead was manipulated into the apex of the single ventricle by shaping the stylet and lead tip was positioned to get appropriate pacing parameters. Since the heart was univentricular, the ventricular hypertrophy of the anterolateral wall had sufficient wall thickness for placing the screw-in lead and this reduced chances of perforation. The lead resistance was 600 Ω and pacing threshold was 0.4 V at a pulse width of 0.4 milliseconds. Once the lead tip was secured in the apex of the ventricle, a sufficient loop was added in the atrium to allow for growth of the cardiac chambers. A surgical pocket was created in the subrectus sheath and the pacing lead was connected to the generator (Fig. 2 and 3). Post procedure ultrasonogram showed no evidence of any local liver injury, hematoma or hepatic vein thrombosis. The child had a smooth post procedure recovery and was discharged on sixth day after the procedure.

Supplementary video related to this article can be found at <http://dx.doi.org/10.1016/j.ipej.2016.06.003>.

3. Discussion

Complete heart block is relatively common in certain forms of complex cyanotic congenital heart diseases that often need cavopulmonary shunts as their palliation. In any patient who had Glenn shunt, Kawashima shunt or Fontan surgery, epicardial permanent pacing is the usual standard of care. This often requires a major surgical procedure involving thoracotomy or sternotomy and is more morbid than a transvenous endocardial lead placement. Such an epicardial pacing can be done with either screw-in unipolar leads or forked buttoned bipolar leads. When there are fibrotic scars on the epicardial surface due to previous surgical adhesions, unipolar screw-in ventricular leads are often preferred to bipolar buttoned leads. The major difficulties encountered in epicardial leads include (i) need for thoracotomy or sternotomy in a compromised cyanotic patient which requires intubation anesthesia (ii) surgical dissection through the adhesions from the previous cardiac surgeries (iii) higher pacing thresholds in epicardial leads through the adhesion scars compared to endocardial leads (iv) higher chances of diaphragmatic pacing in the unipolar leads which are most often implanted during such epicardial placements. Chronic epicardial lead performance has historically been inferior, with higher pacing and lower sensing thresholds and earlier battery depletion rates than transvenous systems [4]. Higher lead failure rates are also noted, with one report observing a 40% failure rate of epicardial atrial leads within 5 years of implantation [5].

Transvenous access for any catheter or electrophysiology intervention is challenging in patients after Fontan and Kawashima surgeries where the catheters from jugular and femoral venous access don't reach the cardiac chambers. As an alternative access, transhepatic access has been tried for different transcatheter and electrophysiology intervention [1,2]. Placement of permanent pacing leads through hepatic veins in such instances were considered in the past [1]. This access was found to be safe and provided a viable alternative without any significant major complication [2]. In patients with extracardiac conduit Fontan surgery where a polytetrafluoro ethylene or dacron conduit bridges the inferior vena cava to the pulmonary artery, a sharp puncture through the conduit into the atrium was made with a Brokenbrough needle through transhepatic access to gain entry into the atrium followed by placement of a permanent pacing lead [2].

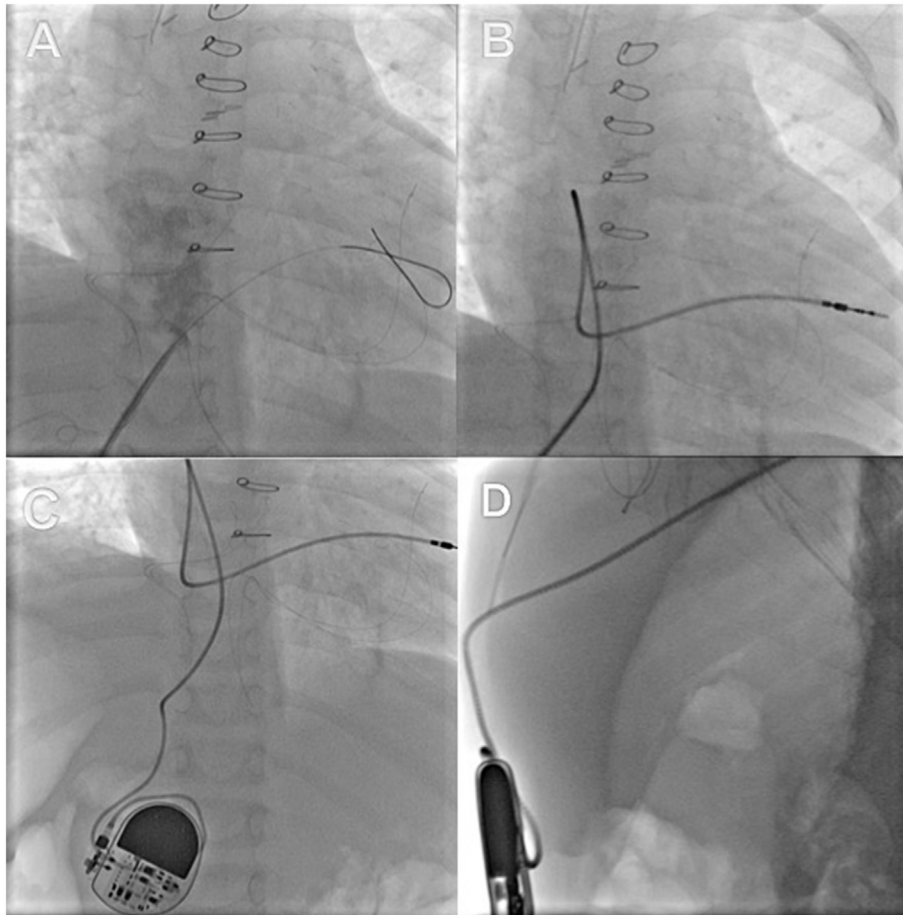


Fig. 2. Panel A shows percutaneous venous access through the right hepatic vein into the atria using a 0.025" guide wire; Panel B shows placement of a ventricular screw-in lead with a redundant loop in the atrium to account for somatic growth of the child; Panel C shows connection of the pulse generator to the pacing lead after creation of a right subrectus pocket; Panel D shows the lateral view of the lead coursing through the liver parenchyma from the subrectus pocket (Movie 1A, 1B, 1C, 1D).

This transhepatic route may not be feasible in patients with active liver disease, liver abscess or peritonitis. In such patients, direct puncture of the undersurface of the right pulmonary artery that overlies the atrial mass through the Glenn circuit will give a direct access to the atrium through the transverse sinus of the heart, which is a potential space. Recently a transvenous pacing in a patient after extracardiac conduit Fontan surgery was done through the subclavian route by placing a pacing lead from subclavian vein to atrium through this route [6].

Awareness about the utility of transhepatic access for permanent pacing in patients who donot have superior vena caval access will expand the horizon for such patients. It may be considered in patients who have high epicardial pacing thresholds too as a brighter alternative option. We opted for a 6French introducer sheath instead of the recommended 7French sheath to avoid leak of blood through the anterior capsule of the liver parenchyma following peeling of the sheath. Complications that might occur in this approach include hepatic bleed into the peritoneum or in the subcutaneous plane which may warrant drainage and transfusion of blood products. This can be circumvented by careful ultrasound guided puncture into the hepatic veins and ensuring optimal coagulation parameters prior to the procedure. We avoided all antiplatelet and anticoagulants prior to the procedure, and pre-treated with vitamin K to improve the hepatic synthesis of coagulation factors. Even though transient mild elevation of liver enzymes is very rarely reported from the traumatic entry into the liver, this is often clinically insignificant. Another concern is an increased risk of systemic thromboembolism from a transvenous

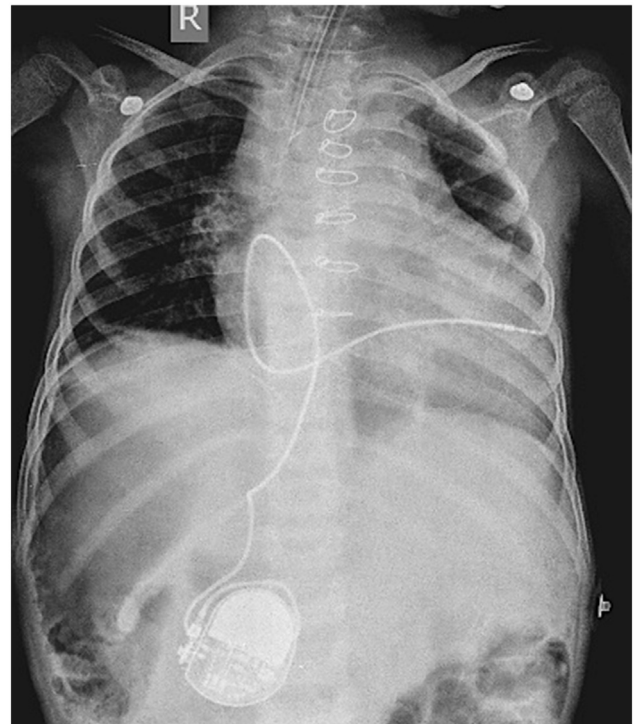


Fig. 3. Chest X ray in anteroposterior projection after the procedure showing the pulse generator and lead position in the ventricular apex. Features of left isomerism include bilateral horizontal left sided bronchus, midline liver and right sided gastric shadow.

lead in the systemic circulation [7]. However there was no clinically relevant increase in such events after transvenous lead compared to epicardial lead and aspirin and warfarin was not shown to be protective [3].

4. Conclusion

Transhepatic permanent pacing lead placement in patients after complex cyanotic heart disease palliations with Glenn shunt, Kawashima shunt or Fontan surgery is a safe and feasible alternative to open surgical epicardial pacing lead placement in carefully selected cases under echocardiographic guidance and with due procedural care.

Financial support

None.

Conflicts of interest

None.

References

- [1] Adwani SS, Sreeram N, DeGiovanni JV. Percutaneous transhepatic dual chamber pacing in children with Fontan circulation. *Heart* 1997;77:574–5.
- [2] Fishberger SB, Camunas J, Rodriguez-Fernandez H, Sommer RJ. Permanent pacemaker lead implantation via the transhepatic route. *Pacing Clin Electrophysiol* 1996;19:1124–5.
- [3] Takahashi K, Cecchin F, Fortescue E, Berul CI, Alexander ME, Walsh EP, et al. Permanent atrial pacing lead implant route after Fontan operation. *Pacing Clin Electrophysiol* 2009;32:779–85.
- [4] Heinemann MK, Gass M, Breuer J, Ziemer G. DDD pacemaker implantation after Fontan-type operations. *Pacing Clin Electrophysiol* 2003;26:492–5.
- [5] Cohen MI, Wernovsky G, Vetter VL, Wieand TS, Gaynor JW, Jacobs ML, et al. Sinus node dysfunction after a systematically staged Fontan procedure. *Circulation* 1998;98:3521I–8II.
- [6] Arif S, Clift PF, De Giovanni JV. Permanent trans-venous pacing in an extra-cardiac Fontan circulation. *Europace* 2015 May 19:euv110. Epub ahead of print.
- [7] Khairy P, Landzberg MJ, Gatzoulis MA, Mercier LA, Fernandes SM, Côté JM, et al. Epicardial versus endocardial pacing and thromboembolic events investigators. transvenous pacing leads and systemic thromboemboli in patients with intra-cardiac shunts: a multicenter study. *Circulation* 2006;113:2391–7.