



Contents lists available at ScienceDirect

## International Journal of Surgery Case Reports

journal homepage: [www.casereports.com](http://www.casereports.com)

# A case report on a left sided gallbladder: A rare finding during cholecystectomy



S. Nagendram\*, K. Lynes, A. Hamade

Queen Elizabeth The Queen Mother Hospital, East Kent Hospital Univeristy NHS Foundation Trust, United Kingdom

## ARTICLE INFO

### Article history:

Received 26 October 2017

Accepted 6 November 2017

Available online 14 November 2017

### Keywords:

Case report  
Laparoscopic  
Cholecystectomy  
Anatomy

## ABSTRACT

**INTRODUCTION:** Cholecystectomy is the surgical removal of gallbladder for symptomatic gallstones disease or where exist the risk of gallbladder malignancy. Its performed routinely across the globe often as day surgery. In this case report, we describe an incidental intra operative finding of a left sided gallbladder creating a technical challenge for the surgeon.

**CASE:** We describe the case of 35 year old female who presented with RUQ pain. Ultrasound examination revealed gallstones. Intraoperative findings during routine cholecystectomy were of a left sided gallbladder. The surgical procedure in performing laparoscopic surgery required an extra port placement for safe and effective dissection.

**DISCUSSION:** The finding of left sided gallbladder is a rare congenital anomaly and has a prevalence of 0.1–0.7%. A true left sided gallbladder is one that is found to the left of the ligamentum teres and falciform ligament and the cystic artery always crosses in front of the CBD from right to left. There are various abnormalities associated this anatomical variant from abnormality of the biliary tree to the porto-venous anatomy. Failure to recognise these variations can lead to serious complications especially in hepatobiliary surgery.

**CONCLUSION:** The finding of left sided gallbladder is an abnormality which is often discovered intraoperatively. It may provide the surgeon with operative challenges in performing the surgery safely and increase the incidence of morbidity. If there is any clinical suspicion of the presence of a left sided gallbladder, pre-operative CT angiography and/or intraoperative cholangiography should be performed to minimise the risk of intraoperative complications.

Crown Copyright © 2017 Published by Elsevier Ltd on behalf of IJS Publishing Group Ltd. This is an open access article under the CC BY-NC-ND license (<http://creativecommons.org/licenses/by-nc-nd/4.0/>).

## 1. Introduction

Cholecystectomy is one of the commonest surgical procedures performed. Indications for gallbladder surgery included biliary colic, cholecystitis, gallstone pancreatitis and risk factors for gallbladder cancer (polyp > 10 mm, porcelain gallbladder etc). Removal of the gallbladder is performed in the vast majority of cases laparoscopically using four small incisions; although open surgery remains an option in more difficult procedures. The risk of conversion to open procedure is stated as being between 1 and 5% [1–3]. It is increasingly being performed as day case surgery.

Left sided gallbladder is a rare finding often discovered incidentally during laparoscopic cholecystectomy. It is a congenital anomaly whereby the gallbladder is situated against the left lobe of the liver. Variation in anatomy may provide some operative challenges with an increased risk of morbidity, and the ability to

recognise any anatomical variations is a surgical skill that is vital in completing any surgical procedure safely. This work has been reported in line with the SCARE criteria [4].

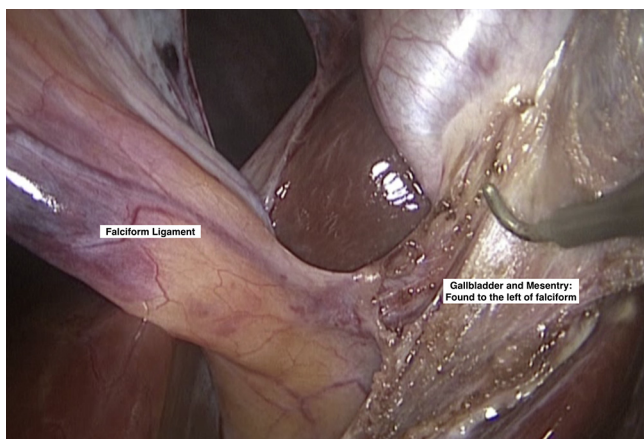
## 2. Case

A 35 year old female presented to the outpatient clinic with episodes of right upper quadrant pain for two to three months following the birth of her baby by normal vaginal delivery. The onset of pain usually followed consumption of her daily meals. There was no clinical history of jaundice, dark urine, pale stools or pruritus and she was a non-smoker with minimal alcohol intake. Her medical history included gastro-esophageal reflux, for which she was taking oral omeprazole; however, there were no other significant medical or surgical comorbidities. Clinical examination was grossly unremarkable; revealing a soft, non tender abdomen and blood results indicated that her liver function tests were all within normal range.

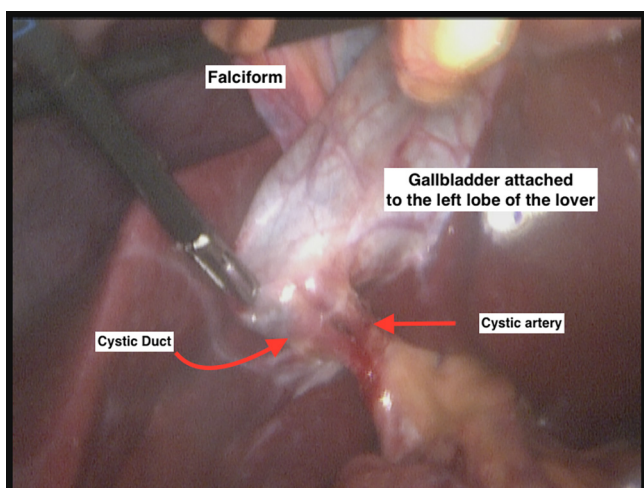
Ultrasonography of the abdomen showed a thin-walled gallbladder with multiple small calculi. The liver was large but demonstrated normal echo texture with no focal lesions. Her spleen

\* Corresponding author.

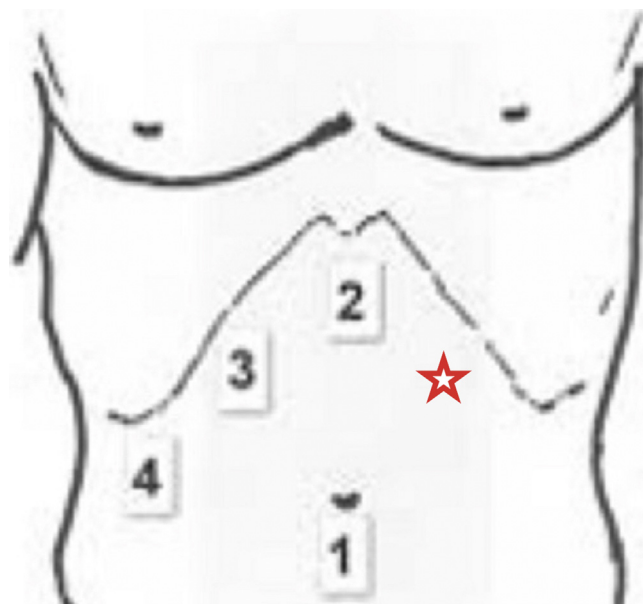
E-mail address: [snagendram@nhs.net](mailto:snagendram@nhs.net) (S. Nagendram).



Picture 1. XXX.



Picture 2. XXX.



Picture 3. XXX.

3. Discussion

The gallbladder is a small organ usually sited to the right side of the liver, typically found beneath segment IVb and V [5]. It is a hollow organ which opens into the biliary tree via the cystic duct, and its primary function is for the storage and concentration of bile produced by the liver, and subsequent release of this into the duodenum in response to the secretion of cholecystokinin by the cells of the duodenum and jejunum. During embryological development, the gallbladder and biliary tree develop from outpouchings of the duodenum at the end of the 4th week of gestation. This hepatic diverticulum divides into two parts: the cystic part and hepatic part. The cystic part is vacuolated and divides and expands, whilst the stalk develops to form the cystic duct [6].

There are a number of congenital variations in the anatomy of the gallbladder that have been described. This includes agenesis, duplication, wandering gallbladder, multiseptate and ectopic gallbladder. The gallbladder can also be found to be located in a variety of positions [7] (intrahepatic, left sided, transverse and retro – displaced).

The left sided gallbladder (LSG) can be found in either in situs inversus or as an isolated finding. It was first reported in 1856 by Hochstetter [8] who first described the finding on three separate specimens. The finding of left sided gallbladder is a rare congenital anomaly and has a prevalence of 0.1–0.7% [9]. A true left sided gallbladder is one that is found at the base of the segment III to the left of the ligamentum teres and falciform ligament and the cystic artery always crosses in front of the CBD from right to left. The cystic duct may join at either side of the common hepatic duct or even join the left hepatic duct directly [10]. Mediaposition is the displacement of the gallbladder to the base of segment IV but remains to the right of the round ligament and therefore is not a true LSG.

It has been previously postulated that a left sided gallbladder exists without situs inversus because of two possible embryological developmental modalities. The first concept is whereby a gallbladder develops on either side of the liver lobes, with the right sided gallbladder becoming atrophic and disappearing. This may be associated with development abnormality or failure in the development of structures of the right liver [11,12]. The second theory is of migration of the gallbladder to the left lobe, to lie to the left of the ligamentum teres. However, neither the theories described above

was at the upper end of the normal range at 140mm. Following clinical review, the patient was booked for a day case elective laparoscopic cholecystectomy.

Intraoperatively, an enlarged smooth liver was noted, and the gallbladder was found in the midline against the left lobe of the liver between segments III and IV, to the left of the falciform ligament (Pictures 1 and 2). The fundus was somewhat intrahepatic. The cystic duct was narrow and followed its course to the common hepatic duct, and the cystic artery was found anterior to the cystic duct.

As a result of the findings during the procedure, some modification was required to perform it safely and successfully. It was difficult to use the epigastric port to access the gallbladder due to obstruction by the falciform; thus, an additional port was placed in the left upper quadrant at Palmer’s point (Picture 3) for ease of access and dissection. The gallbladder was retracted towards the left shoulder underneath the falciform instead of the right shoulder tip to expose the Calot’s triangle and to avoid tears to the liver. No other anatomical abnormalities were noted intraoperatively and the remainder of the operative procedure was performed as routine, devoid of any complication. The patient’s postoperative recovery was uneventful and she was successfully discharged home.

Some weeks after surgical intervention an MRCP was performed with patients consent and did not reveal no other abnormality of the biliary tree.

nor any other have completely explain the findings of the left sided gallbladder and other anomalies that are associated with it. The exact developmental pathway for a LSG still remains unknown.

Clinically, the visceral pain fibres do not transpose with the gallbladder and therefore these patients will still present with RUQ pain and positive Murphy's sign in cholecystitis [13]. The diagnosis of LSG is one that is often made intraoperatively. The finding of abnormal intrahepatic portal venous branching and/or radiological absence of segment IV should raise the suspicion of a left sided gallbladder and the potential for other anatomical abnormalities.

There are a number of anatomical variations understood to be associated with left sided gallbladder including those of the hepatobiliary system and portal vein. Duplication of the CBD [14], hypoplastic CBD [15], infraportal bile duct [16] and abnormal pancreato-biliary junction have all been described [13]. Variations in the anatomy of the bile duct may provide significant operative challenges and increase the risk of complications during cholecystectomy.

Abnormalities of the portovenous system are of less importance during laparoscopic cholecystectomy. However, inability to recognise altered anatomy may lead to dire consequences, especially in liver resection, split liver transplantation or living donor hepatectomy. Common complications that may arise are hepatic failure and bile leak. If there is any doubt regarding normal biliary anatomy, pre-operative CT angiography and or MRCP should be performed to plan for safe resection.

#### 4. Conclusion

The finding of left sided gallbladder is a rare anatomical variation which is often not identified during medical imaging and is often found incidentally during laparoscopic cholecystectomy. Given its rarity, intraoperative findings may stun a novice surgeon, and an inability to anticipate potential anatomical variations may well increase morbidity from the procedure. Ability to recognise a LSG allows one to safely anticipate varying confluence of cystic duct into the common bile duct, and therefore its safe dissection and ligation. As highlighted in our case, changes to the standard port placement may well be required for improved access to the Calot's triangle. The use of intraoperative cholangiography may help clarify any anatomical uncertainties that may arise during the operation. For those with left sided gallbladder undergoing surgery of the liver and the pancreas, more detailed pre-operative planning will be required.

#### Conflict of interest

None.

#### Sources of funding

Nil.

#### Ethical approval

Nil required.

#### Consent

Written consent has been obtained from the patient.

#### Author contribution

Sathyan Nagendram: Assisting surgeon, Author, obtaining consent.

Kate Lyles: Surgeon for the procedure.

Ayman Hamade: Lead surgeon, Author, approval of final version.

#### Guarantor

Sathyan Nagendram.

#### Patient consent

Obtained.

#### References

- [1] H.M. Kaafarani, T.S. Smith, L. Neumayer, D.H. Berger, R.G. Depalma, K.M. Itani, Trends, outcomes, and predictors of open and conversion to open cholecystectomy in Veterans Health Administration hospitals, *Am. J. Surg.* 200 (1) (2010) 32–40.
- [2] C. Gholipour, M.B.A. Fakhree, R.A. Shalchi, M. Abbasi, Prediction of conversion of laparoscopic cholecystectomy to open surgery with artificial neural networks, *BMC Surg.* 9 (1) (2009).
- [3] B. Tang, A. Cuschieri, Conversions during laparoscopic cholecystectomy: risk factors and effects on patient outcome, *J. Gastrointest. Surg.* 10 (7) (2006) 1081–1091.
- [4] R.A. Agha, A.J. Fowler, A. Saetta, I. Barai, S. Rajmohan, D.P. Orgill, for the SCARE Group, The SCARE Statement: Consensus-based surgical case report guidelines, *Int. J. Surg.* (2016).
- [5] Shakerford's Surgery of Alimentary Tract, ed. 7. 2013.
- [6] C. Gary, Schoenwolf, et al., Larsen's human embryology (Thoroughly rev. and updated), in: *Development of the Gastrointestinal Tract*, 4th ed., Churchill Livingstone/Elsevier, Philadelphia, 2009.
- [7] R.E. Gross, Congenital anomalies of the gallbladder, *Arch. Surg.* 32 (1936) 131–162.
- [8] J.F. Newcombe, M. Chir FRCS, F.A. Henley MB, BS, FRCS., Left-sided gallbladder. A review of the literature and a report of a case associated with hepatic duct carcinoma, *Arch. Surg.* 88 (3) (1964) 494–497, <http://dx.doi.org/10.1001/archsurg.1964.01310210168027>.
- [9] M. Nagai, K. Kubota, S. Kawasaki, T. Takayama, Y. Bandai, M. Makuuchi, Are left sided gallbladders really located on the left side? *Ann. Surg.* 225 (1997) 274–280.
- [10] S. Alharthi, M. Bernon, J.E.J. Krige, Beware the left-sided gallbladder, *South Afr. J. Surg.* 50 (3) (2012) 88–89, <http://dx.doi.org/10.7196/SAJS.1301>.
- [11] Y. Maetani, K. Itoh, N. Kojima, T. Tabuchi, T. Shibata, K. Asonuma, K. Tanaka, J. Konishi, Portal vein anomaly associated with deviation of the ligamentum teres to the right and malposition of the gallbladder, *Radiology* 207 (1998) 723–728.
- [12] R. Gross, Congenital anomalies of the gallbladder. A review of 148 cases, with report of double gallbladder, *Arch. Surg.* 32 (1936) 131–162.
- [13] Sagar Sadhu, Tarshid A. Jahangir, Manas K. Roy, Left-sided gallbladder discovered during laparoscopic cholecystectomy in a patient with dextrocardia, *Indian. J. Surg.* 74 (April (2)) (2012) 186–188.
- [14] Elizabeth A. Bender, Sara Springhetti, Kamal Shemisa, Wittenauer Justine, Left-sided gallbladder (Sinistroposition) with duplication of the common bile duct, *JSLs* 11 (January–March (1)) (2007) 148–150.
- [15] R. Colovic, N. Colovic, G. Barisic, H.D.E. Atkinson, Z. Krivokapic, Left-sided gallbladder associated with congenital liver cyst, *HPB (Oxford)* 8 (April (2)) (2006) 157–158.
- [16] Ishii Hiromichi, Noguchi Akinori, Onishi Mie, Takao Koji, Maruyama Takahiro, Taiyoh Hiroaki, Araki Yasunobu, Shimizu Takeshi, Izumi Hiroyuki, Tani Naoki, Yamaguchi Masahide, Tetsuro Yamane, True left-sided gallbladder with variations of bile duct and cholecystic vein, *World J. Gastroenterol.* 21 (June (21)) (2015) 6754–6758.

#### Open Access

This article is published Open Access at [sciedirect.com](http://sciedirect.com). It is distributed under the [IJSCR Supplemental terms and conditions](#), which permits unrestricted non commercial use, distribution, and reproduction in any medium, provided the original authors and source are credited.