



No pouch, no problem: successful endoscopic division of a symptomatic cricopharyngeal bar using a modified peroral endoscopic myotomy technique for Zenker's diverticulum

Sarah S. Al Ghamdi, MD, Jad Farha, MD, Thomas M. Runge, MD, MPH, Yervant Ichkhanian, MD, Mouen A. Khashab, MD

Cricopharyngeal bars (CPBs) are fibrous thickenings of the cricopharyngeus (CP) muscle that can rarely lead to dysphagia. Established treatment modalities include esophageal dilation, endoscopic botulinum toxin injection, and surgical cricopharyngeal myotomy. There has been no reported experience with peroral endoscopic myotomy (POEM) for symptomatic CPBs.

CASE PRESENTATION

A 78-year-old man with a history of congestive heart failure, hypertension, coronary artery disease, asthma, and hypothyroidism presented to an Otolaryngologist with a 3-month history of intermittent dysphagia to solids and liquids. Dysphagia was associated with coughing episodes and aspiration pneumonia. Modified barium swallow study revealed mild oropharyngeal dysphagia with a prominent CPB (Fig. 1A). The patient later underwent direct laryngoscopy with cricopharyngeal botulinum toxin injection, with no improvement of symptoms. Barium swallow was repeated several weeks later, with similar

findings. He was then referred to the gastroenterology department for definitive therapy.

VIDEO DESCRIPTION

A diagnostic EGD was performed, during which significant resistance was detected when traversing a prominent CPB, and a small Zenker's diverticulum was noted (Fig. 1B). Submucosal injection was performed slightly upstream of the CP muscle (Fig. 1C). A premixture of saline solution, 1% indigo carmine, and diluted epinephrine was injected to create a mucosal bleb. A 1.5-cm mucosal incision was then performed using a triangular-tip (TT) knife (Olympus America, Center Valley, Penn, USA) using EndoCut Q (ERBE USA, Marietta, GA, USA) current (Fig. 1D). Submucosal tunneling was then performed (Fig. 1E) with clear identification of the fibers of the thickened CP muscle. This was done with the TT knife, spray coagulation current, and injection of saline solution with indigo carmine solution via a pump. During dissection, mild fibrosis was noted, due to prior botulinum toxin injection. CP muscle fibers were

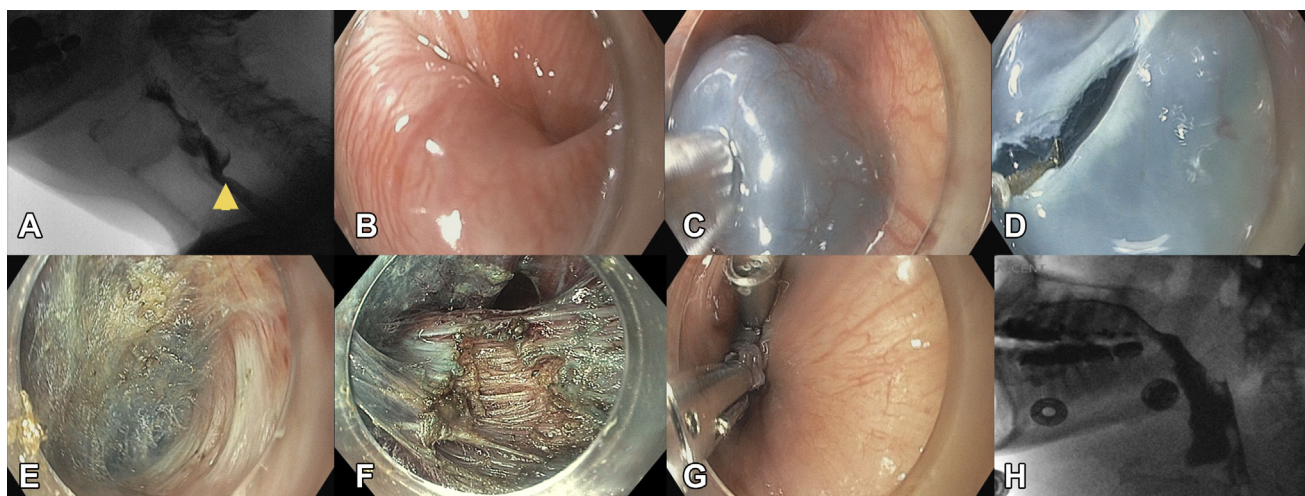


Figure 1. A, Modified barium swallow study showing a prominent cricopharyngeal bar. B, Endoscopic view of cricopharyngeal bar. C, Submucosal injection. D, Mucosal incision. E, Submucosal tunneling. F, Beginning of myotomy. G, Endoscopic closure. H, Barium swallow study after peroral endoscopic myotomy showing no leakage and resolution of cricopharyngeal bar.

identified, and complete myotomy was performed using an insulated tip knife (Olympus America, Center Valley, Penn, USA) (Fig. 1F). Complete septotomy was not performed, distinguishing this from a standard peroral endoscopic myotomy technique for Zenker's diverticulum (Z-POEM). After myotomy, the endoscope passed easily across the upper esophageal sphincter. Closure of the mucosal entry site was performed using 5 endoclips (Fig. 1G). The procedure time was 44 minutes, with no adverse events (Video 1, available online at www.VideoGIE.org).

OUTCOMES

The patient was admitted overnight. Day 1 barium swallow showed no leak or subcutaneous emphysema (Fig. 1H). The patient tolerated clear fluids with no pain and was discharged on oral antibiotics. At 1-month follow-up, the patient was feeling well and tolerating solid foods, with complete resolution of dysphagia. This case demonstrates the use of a modified Z-POEM technique as safe and effective management of symptomatic CPBs. We have previously reported 1 prior case of successful single-session cricopharyngeal myotomy and Z-POEM.¹ In symptomatic patients with a CPB, a submucosal tunneling technique still allows for excellent exposure of the muscle and complete myotomy in a manner similar to that

performed during Z-POEM. This technique can be considered as an alternative management option for symptomatic patients with a prominent CPB.

DISCLOSURE

M.A. Khasbab is a consultant for Boston Scientific, Olympus, and Medtronic. All other authors disclosed no financial relationships.

Abbreviations: CPB, cricopharyngeal bar; CP, cricopharyngeus; POEM, per-oral endoscopic myotomy; TT, triangular-tip; Z-POEM, Zenker per-oral endoscopic myotomy.

REFERENCE

1. Brewer Gutierrez OI, Moran R, Yang J, Sanaei O, et al. Successful single-session cricopharyngeal and Zenker's diverticulum per-oral endoscopic myotomy. *Endoscopy* 2018;50:E220-1.

Division of Gastroenterology and Hepatology, Johns Hopkins Medical Institutions, Baltimore, MD.

Copyright © 2020 American Society for Gastrointestinal Endoscopy. Published by Elsevier Inc. This is an open access article under the CC BY-NC-ND license (<http://creativecommons.org/licenses/by-nc-nd/4.0/>).

<https://doi.org/10.1016/j.vgie.2020.03.006>

Read Articles in Press Online Today! Visit www.videogie.org

VideoGIE posts in-press articles online in advance of their appearance in a monthly edition of the journal. These articles are available on the *VideoGIE* website by clicking on the "Articles in Press" tab. Articles in Press represent the final edited text of articles that are accepted for publication but not yet scheduled to appear in a specific issue. They are considered officially published as of the date of Web publication, which means readers can access the information and authors can cite the research months prior to its availability in an issue. To cite Articles in Press, include the journal title, year, and the article's Digital Object Identifier (DOI), located in the article footnote. Visit the website today to stay current on the latest research in the field of gastrointestinal endoscopy.