

Management of recurrent rhegmatogenous retinal detachment

Manish Nagpal, Pranita Chaudhary, Shachi Wachasundar, Ahmed Eltayib, Aparajita Raihan

Rhegmatogenous retinal detachment (RRD) repair is one of the most common vitreoretinal surgeries a surgeon performs. In an ideal scenario, RRD can be repaired with a single surgical intervention; however, despite excellent skill, flawless technique, and the introduction of high-end technology, up to 10% of cases require additional interventions to ultimately repair recurrent detachments. It is thus important to study the outcomes of multiple interventions to understand whether performing repeat vitrectomy on patients with a history of failed surgeries is worthwhile. Thus, recurrent retinal detachment (re-RD) remains a significant challenge for vitreoretinal surgeons as well as the patients considering the economic and the emotional burden of undergoing multiple interventions. The advent of microincision vitrectomy system, perfluorocarbon liquids, and effective intraocular tamponades has opened new doors for managing re-RDs. In this article, we have reviewed and summarized the various causes and approaches for management for optimal anatomical and functional outcomes.

Key words: Perfluorocarbon liquid, proliferative vitreoretinopathy, recurrent retinal detachment, resurgery, scleral buckle, silicone oil, vitrectomy

Rhegmatogenous retinal detachment (RRD) is the most common form of retinal detachment (RD). In an ideal scenario, RRD can be repaired with a single surgical intervention; however, despite excellent skill, flawless technique, and the introduction of high-end technology, up to 10% of cases require additional interventions to ultimately repair recurrent detachments.^[1] In addition, the increasing number of patients has nevertheless brought with it a greater number of recurrences. Although the overall functional outcome prognosis is unfavorable in recurrent retinal detachments (re-RDs), a small share of patients benefit highly by restoring a good vision even after multiple interventions.^[2]

Causes of re-RD and severity of proliferative vitreoretinopathy (PVR) may be determined by the timing of detachment occurring after primary surgery. Thus, if the retina fails to attach at the time of surgery, it is termed as primary failure.^[3] Secondary failure constitutes when retina subsequently detached after a period of attachment.^[3] Early re-RD is defined as detachments occurring within the first 6 weeks postoperatively, whereas late re-RD is defined as detachments occurring 6 or more weeks postoperatively.^[4] According to the existing literature, more than 80% of the cases of re-RD occurred within the first 6 weeks of the primary surgery; thus, the risk is greatly reduced with increased interval after surgery.^[5]

The published results in various studies report a variety of treatment options depending on the cause, interval from the primary surgery, primary surgery, and severity of the recurrence with no clear definitive guidelines. Therefore, we have reviewed and summarized the various causes and approaches for management for optimal anatomical and

functional outcomes. This may be useful for doctors to decide the treatments and provide precautions for patients with higher risks.

Methods

We conducted a comprehensive search in PubMed for studies published in the last 15 years undertaken by four independent researchers. The keywords used for the search were "rhegmatogenous RD," "recurrent/persistent RD," "scleral buckling," "silicone oil," "per fluorocarbon liquids," "retinectomy," "PVR," "high myopic RD," "failure," "re surgery," and "re-detachment." Inclusion criteria comprised human studies published in English, which discussed incidence of retinal redetachments following scleral buckling or vitrectomy, risk factors for redetachments, incidence/risk of RD after silicone oil removal (SOR), management of retinal redetachment, outcomes, and success of various tamponading agents used in RD surgery. Review articles, prospective randomized and nonrandomized clinical studies, retrospective clinical studies, short case series, and pilot studies were included. A manual search of related articles was also performed through references reported in each article.

Risk Factors Relating to Redetachment

Recognition of the causes and risk factors, which lead to redetachment after a surgery, are very important for every surgeon. Awareness of risk factors not only allows the surgeon

This is an open access journal, and articles are distributed under the terms of the Creative Commons Attribution-NonCommercial-ShareAlike 4.0 License, which allows others to remix, tweak, and build upon the work non-commercially, as long as appropriate credit is given and the new creations are licensed under the identical terms.

For reprints contact: reprints@medknow.com

Cite this article as: Nagpal M, Chaudhary P, Wachasundar S, Eltayib A, Raihan A. Management of recurrent rhegmatogenous retinal detachment. Indian J Ophthalmol 2018;66:1763-71.

Access this article online

Website:
www.ijo.in

DOI:
10.4103/ijo.IJO_1212_18

Quick Response Code:



Department of Retina and Vitreous, Retina Foundation, Ahmedabad, Gujarat, India

Correspondence to: Dr. Manish Nagpal, Retina Foundation, Shahibagh Under Bridge, Ahmedabad - 380 004, Gujarat, India. E-mail: drmanishnagpal@yahoo.com

Manuscript received: 17.07.18; Revision accepted: 23.08.18

Table 1: Summary of risk factors relating to recurrent retinal detachment enlisted in various studies

Previous surgeries/ Retinal condition	Study	Study design	Patients included	re-RD %	Risk factors
Failure after PR	Rootman <i>et al.</i> ^[6]	Prospective interventional case series	113 patients with new-onset primary RRD treated with PR	31.4	2, 9, 10, 11
	Anaya <i>et al.</i> ^[7]	Retrospective, case series	73 out of total 423 patients that failed primary PR	25	9, 7, 10
re-RD post-SB	Goezinne <i>et al.</i> ^[8]	Retrospective	436 eyes undergoing primary SB	24	8, 9, 10, 12, 16
re-RD after SB/ vitrectomy undergoing PR	Petrushkin <i>et al.</i> ^[9]	Retrospective	42 cases who underwent secondary PR after either scleral buckling or vitrectomy	5	10
re-RD under silicone oil	Sigler <i>et al.</i> ^[10]	Prospective, interventional case series	39 patients presenting with recurrent RD or ERM under SO	13.9	9
	Ambiya <i>et al.</i> ^[11]	Retrospective	133 cases of recurrent RD	25.8	9, 21
	Solaiman and Dabour ^[6]	Prospective	23 silicone filled eyes undergoing supplemental buckle or re-vitrectomy	16.7	9, 17, 18
	Sharma <i>et al.</i> ^[12]	Retrospective	118 SO-filled eyes with recurrent RD were managed with revision of vitrectomy with membrane surgery with or without SOR, only SB or both	37.3	8, 9, 27
re-RD after complicated RD/ PVR	Üney <i>et al.</i> ^[13]	Retrospective	120 patients who underwent PPV with silicone oil tamponade	25	9, 10, 11
	Wickham <i>et al.</i> ^[14]	Prospective, randomized control trial	615 patients in trial investigating the use of 5-fluorouracil and low-molecular-weight heparin	15.6	1, 3, 4, 9, 10, 24
	Adelman <i>et al.</i> ^[15]	Retrospective	7678 cases of RRD	33	6, 9, 10
	Kapran <i>et al.</i> ^[16]	Retrospective	61 patients with complicated RD, silicone oil in 40, and perfluoropropane (C3F8) in 18 patients	29	9, 10, 13, 19
	Goezinne <i>et al.</i> ^[17]	Retrospective	30 eyes operated with vitrectomy for RD with GRT	30	11
re-RD after SOR	Nagpal <i>et al.</i> ^[18]	Retrospective	412 eyes (with attached retina after vitrectomy with silicone oil for RRD) undergoing SOR	12.7	3, 20, 25
	Teke <i>et al.</i> ^[19]	Retrospective	894 patients undergoing SOR after vitrectomy for complicated RD	13.2	3, 16, 26, 28
	Jonas <i>et al.</i> ^[20]	Retrospective	225 patients undergoing SOR	25.3	3, 9, 20
Late re-RD	Foster and Meyers ^[21]	Retrospective	10 eyes with late recurrent RRD after 1 or more years of reattachment out of a total of 453 patients	2.2	9, 10, 11, 15
	Zhioua <i>et al.</i> ^[22]	Retrospective	445 operated for RRD, 9 eyes had a late RRD. 6 eyes had SB, and 3 eyes had vitrectomy with SO injection then SOR	2.02	10, 13, 14

1: Duration of symptoms, 2: Pseudophakic status in detachment, 3: High myopic, posterior staphylomatous eyes, 4: Extent of RD, 5: Involvement of inferior quadrants, 6: Choroidal detachment and significant hypotony, 7: Persistent detachment, 8: Persistent and/or progressive reaccumulation of subretinal fluid, 9: PVR, 10: Undetected breaks formation of new breaks, 11: Ineffective closure of preexisting breaks, insufficient chorioretinal adhesion, 12: Large breaks, 13: Opening old break, 14: Reopened macular hole, 15: Progressive vitreoretinal traction, 16: Vitreous base traction, incomplete removal of the vitreous base and shaving, 17: Inadequate retinal tamponade, 18: Strict continuous posturing is not adhered, 19: Perisilicone proliferation, 20: Surgeon factor, 21: Multiple surgeries, 22: Retinectomies and relaxing retinotomies, 23: Absence of silicone oil emulsification at time of SOR, 24: Improper positioning of the buckle under the primary break, elevating the break off the buckle, 25: Inadequate buckle height, 26: Vitreous hemorrhage, 27: Postslippage of GRT, 28: Absence of encircling buckle. RRD: Rhegmatogenous retinal detachment; re-RD: Recurrent retinal detachment; SO: Silicone oil; PVR: Proliferative vitreoretinopathy; SB: Scleral buckle; PR: Pneumatic retinopathy; SOR: Silicone oil removal; GRT: Giant retinal tear; ERM: Epiretinal membrane

to be better prepared for the surgery ahead but also to prepare the patient for the possibility of a suboptimal outcome [Table 1].

Overall, development of PVR was found to be a potent predictor of failure in almost all studies, seen in 5–11% of patients.^[23] The mechanisms of PVR are incompletely understood. Earlier, it was believed that retinal pigment epithelium cells liberated through retinal breaks tend to proliferate along with glial cells resulting in epiretinal

membrane (ERM) formation.^[24] Recently, contraction and atrophy of intrinsic retinal elements causing retinal shortening and membrane contraction are considered more important leading to anteroposterior, perpendicular, or circumferential traction on the retina, or a combination of all, most notably around the vitreous base.^[25]

Majority of the studies quote PVR \geq Grade C, anterior and inferior PVR to be associated with a higher risk re-RD.^[6-17,19-22,26]

It was previously reported that 86% of eyes with re-RD after vitrectomy have a component of anterior PVR^[27] and eyes with anterior PVR have poorer surgical prognosis than those with posterior PVR.^[28]

The second most common cause of redetachment was related to retinal breaks. Large breaks more than three disk diameters,^[6,8] formation of new breaks or missed breaks^[6-9,13-15,19,21,22] or ineffective closure of preexisting breaks either by improper positioning of the scleral buckle (SB) or by inadequate chorioretinal adhesion,^[12,13,21,26] reopening of an old break^[19] and reopened macular hole^[22] lead to redetachment.

Risk factors for redetachment related to the characteristics of primary RD were longer duration of symptoms, involvement of inferior and all four quadrants,^[14,15] progressive vitreoretinal traction with or without PVR,^[21] vitreous base traction,^[8] persistent detachment,^[7] choroidal detachment, significant hypotony,^[15] and pseudophakic status in detachment.^[6] However, contrary to this, in a study comparing anatomical and functional results following primary PPV for RRD with superior versus inferior breaks, acceptable rates were achieved using PPV alone to treat uncomplicated RRD irrespective of the location of the breaks.^[29] Some of the causes mentioned above result in inflammation and hence can potentially trigger PVR.

Other causes related to SB were persistent and / or progressive reaccumulation of subretinal fluid (SRF), or progressive "leakage of SRF at the peripheral edge of the buckle caused by lack of indentation. In a study by Smiddy *et al.*, the authors have mentioned following causes of re-RD following SB surgery in the absence of advanced PVR (grade C-2 or greater): improper positioning of the buckle under the primary break, inadequate buckle height, progressive vitreous traction elevating the break off the buckle, formation of new breaks, insufficient chorioretinal adhesion.^[30]

In a retrospective study of 36 patient by Han *et al.*, the incidence of re-RD was 12% after SB removal for buckle related complications.^[31]

Concerning redetachment under silicone oil (SO), inadequate or unidirectional (superiorly directed) retinal tamponade with SO, especially when a strict continuous posturing is not adhered to in the first few postoperative days,^[26] and perisilicone proliferation^[16] were associated with redetachment.

High myopic and posterior staphylomatous eyes are at a high risk for recurrences of detachment due to various intraoperative and inherent anatomic variation. Intraoperative induction of complete posterior vitreous detachment is rarely possible in highly myopic eyes because of the stronger vitreoretinal adhesion and posterior shifting of the vitreous base.^[14,19] Despite meticulous shaving, vitreous collagen fibers intertwining with the outer retina represent a scaffold for proliferation, a prerequisite for retinal stiffening and PVR.^[32]

Surgical causes include multiple surgeries,^[2,11,18,20] incomplete removal of the vitreous base and shaving,^[19,20] retinectomies, and relaxing retinotomies.^[33]

In retrospective study of 133 cases of re-RD conducted at L. V. Prasad Eye Institute, PVR \geq Grade C and multiple resurgeries are associated with higher incidence of anatomical failure in re-RD surgery. Multiple breaks are associated with a poorer

visual outcome, whereas a better baseline visual acuity and delayed recurrence of RD after primary repair were associated with a better visual outcome.^[11]

Silicone oil removal

SO is usually removed after 3 months if the retina is attached. One of the major complication of SOR is redetachment, the rate of which varies across literature from 5% to up to one-third of all eyes undergoing SOR, because of different confounding factors including ethnic, socioeconomic, and access to health care.^[20,34] Teke *et al.* found that after SOR in 776 patients (86.8%), 118 patients (13.2%) developed redetachment.^[19] Choudhary *et al.*^[5] reported a redetachment rate of 3.46% after SOR with 173 cases and stated that aggressive vitreous base shaving, performing retinotomy, filling the eye with SO for full tamponade, and performing argon laser would reduce the complication rate. Scholda *et al.* has reported PVR, ERM or anterior PVR, preceding surgeries, myopia, cataract surgeries, and duration of tamponade as significant risk factors for re-RD post-SOR.^[34]

Factors decreasing the incidence of re-RD after SOR are 360° endolaser barrage prior to SOR, presence of encircling buckle, and SO emulsification prior to SOR.^[18] Although complete vitrectomy and vitreous replacement along with a 360° encircling SB remains a fundamental requirement for most eyes with established PVR. That is because the vitreous base, particularly inferiorly, becomes fibrocellular in PVR and continues to contract even after a complete vitrectomy, as it is virtually impossible to remove the whole vitreous base.^[35]

In a study by Nagpal *et al.*, the re-RD rates were found to be lower when SOR was performed in the presence of emulsified SO (6.17%) compared with when there was no emulsification (17.78%), as in this state of emulsification, SO does not serve the purpose of internal tamponade.^[18]

Management of Recurrent Retinal Detachment

Redetachment after scleral buckle

The primary anatomical success rate for SB surgery is found to be between 70% and 92%.^[36] PVR is most commonly reported to be the cause of failed surgery.^[37] Most of the primary failed buckling surgeries undergo PPV to achieve anatomical and functional success.

Even as the preference for SB is gradually decreasing, an alternative approach uses vitrectomy-based chandelier visualization systems. As surgeons are more comfortable with the vitrectomy-based systems, this approach is a middle path as well as an educational tool to help in reviving the dying art of buckling.^[38]

A study by Fleur Goezinne *et al.* evaluated the data of 436 eyes that underwent SB surgery and found that after more than 6 and 12 months of follow-up, redetachment occurred in 32 eyes (7%) and 20 eyes (5%), respectively. Multivariate regression analysis pointed out that recurrent redetachment and visual field loss more than 7 days were poor prognostic factors for postoperative visual outcome at 12 months.^[8]

Kreissig *et al.* reported 10% incidence of re-RD after SB procedures. They observed that early redetachment (up to

6 months after SB surgery) was caused mainly by PVR, while in nearly half of the cases, a late redetachment was caused by new breaks. Although PVR is also observed in patients with late recurrent RRDs, vitreous base traction is probably the main culprit in these cases and that the associated PVR might as well be a secondary phenomenon.^[39]

Surgical techniques useful for reattaching the retina with revision of buckle^[30] in these cases include:

1. Augmenting the original buckle by adding SB material
2. Modifying the existing buckle without adding new material
3. Replacing the original buckle with other material
4. Re-treating inadequately closed breaks
5. Combinations of the above four techniques

Thus, vitrectomy can be avoided in many cases by treating the rhegmatogenous component of the re-RD by revision of buckle, especially in eyes with only mild PVR changes.

Rescue pneumatic retinopexy

Pneumatic retinopexy (PR) use as a “rescue” procedure for re-RD following SB was first reported by Edwin Boldrey, and the results of its use were seconded by several authors.^[40,41]

In a study by Petrushkin *et al.* on 44 eyes who underwent a PR as a secondary rescue surgery in patients who had vitrectomy and gas tamponade or SB for as a primary surgery for RD. They noted that 90% of vitrectomized eyes and 100% of eyes with a SB achieved anatomical success at 3 months after rescue PR. This success of the procedure can be attributed to elimination of the vitreous as a potential source of traction in vitrectomized eyes and the presence of a scleral indentation that counteracts traction by inducing redundancy in the cortical and core vitreous fibrils. The authors concluded that PR is a valid rescue procedure in selected cases of missed or unsupported breaks for re-RD following vitrectomy and SB for patient. The most common complication noted was that procedure was cataract, more frequently observed in those who had vitrectomy as a primary procedure.^[9]

Pars plana vitrectomy for recurrent retinal detachment

The surgical management of re-RD involves an accurate assessment of the cause of failure. The important causes of failure include PVR, open retinal break (s) without PVR, or intrinsic retinal contraction.

Management of proliferative vitreoretinopathy

Surgery is the standard treatment for PVR to reattach the retina by identifying all the breaks and relieving all significant vitreoretinal traction. The advent of microincision vitrectomy system (MIVS), perfluorocarbon liquids (PFCL), and effective intraocular tamponades has opened new doors for managing PVR effectively.

Encircling scleral buckle

If a SB was not placed during the previous surgery, the surgeon should have a low threshold for placing an encircling SB at the time of reoperation if an extensive relaxing retinectomy is not planned to address the risk of subsequent tractional redetachment.^[42]

Core vitrectomy and removal of the vitreous base

Any remaining central gel is removed completely and then peripheral vitreous is removed meticulously after indentation

and as completely as possible, particularly inferiorly where pigment and inflammatory cells tend to gravitate and a common cause of recurrence of RD especially under SO.^[35]

A bimanual technique with an illuminated probe or pic held in the second hand can also be helpful in protecting the retina. A chandelier lighting system may be used for the same purpose.

In comparison to 20 ga, the MIVS cutter port is smaller and closer to the tip. A smaller port and a proximity closer to the tip maybe advantageous when performing complex maneuvers, such as shaving of the vitreous base and working near detached mobile retina. Higher cutting rates extending up to 5000–8000 cpm reduce the likelihood of uncut vitreous fibers going through the cutter port, thereby reducing dynamic vitreoretinal traction with less chance of iatrogenic retinal tears and damage to the retinal surface.^[43,44]

Formed vitreous attached to the peripheral retina is also very difficult to remove if the retina is detached and mobile, in which case it can be stabilized at this stage by partly filling the vitreous compartment with PFCL. This has the dual effect of flattening the retina by displacing SRF anteriorly and breaking down invisible microscopic retinal bridges of scar tissue.^[35]

Turbulence needs to be minimized by lowering the intraocular pressure (IOP) and using valved trocars, to stabilize PFCL and ensure stability of the retina, thus minimizing risk of retained PFCL droplets.^[42]

An attached posterior hyaloid in re-RD may be found multiple times, especially in children and myopes. In such cases where vitreous remains attached to the retinal surface posteriorly as well as at the vitreous base, the process of removal may be facilitated by visualization with intravitreal triamcinolone acetonide (IVTA). IVTA (0.1–0.3 mL, 40 mg/mL [4%] concentration) improves identification of tissue through the deposition of crystals,^[45] which helps the surgeon achieve complete detachment and removal of the posterior hyaloid. IVTA may prevent fibrin reaction and PVR postoperatively.^[46]

Removal of membranes

After a meticulous vitrectomy, any retinal folds due to ERM must be dealt with. Membranes are peeled from the retinal surface from the posterior pole outward with a forceps, illuminated pick, or a blunt vitreous spatula.^[47] The membranes may easily peel off in a single sheet or in piecemeal depending on the adherence. The complete maturation of ERMs may take about 6–12 weeks.^[48] Thus, it may be prudent to delay resurgery to facilitate the removal of these membranes in case the macula is attached. While peeling, care must be taken to avoid creating iatrogenic retinal breaks.

Trypan blue ophthalmic solution 0.15% (MembraneBlue, DORC) is commonly used to help visualize the ERM, internal limiting membrane (ILM), and staining of PVR membranes in eyes with complex RD. It is the only retinal dye solution approved by the FDA. It is easier to rinse out and there is no risk of xenon light-induced damage.^[49]

Another option is a dual-combination solution (MembraneBlue-Dual, DORC) containing Trypan blue 0.15%, Brilliant blue G (BBG) 0.025%, and 4% polyethylene glycol (PEG). It was commercially developed to provide a dual

dye solution in a single injection that is suitable for ILM, ERM, and PVR membrane staining.^[50,51] Due to a new integrated carrier 4% PEG solution, it can be injected in a BSS-filled eye and sinks immediately as a cohesive ball without diffusion throughout the whole globe.^[46]

Any subretinal bands causing obvious retinal traction should be removed via an extramacular retinotomy.

ILM peeling may be carried out at the posterior pole after staining with vital dyes to remove the scaffold for reproliferation. Indocyanine green (ICG)^[52] and BBG are used for staining and visualizing the ILM. Adverse effects reported with the use of ICG are visual field defects, reduced visual acuity due to a dose-dependent toxic effect on the retina, and persistent staining.^[46] Hence, BBG is now the preferred dye.^[53]

In a retrospective case series of 14 patients, Minarcik and von Fricken^[54] noted high anatomic success rate (79%) in PVR-related re-RDs using ICG-assisted ILM peeling in conjunction with vitrectomy and peeling of peripheral membranes. They considered the technique as a tissue-sparing alternative to the more extensive traditional retinectomy in select cases.

Testing adequacy of relief of traction and relaxing retinotomy

Machemer *et al.*^[55] identified three main indications for relaxing retinotomy: contraction of the edges of a large retinal tear, taut subretinal strands preventing retinal reattachment, and retinal incarceration in a wound.

After a complete fluid–air exchange and drainage of SRF, retina may fail to flatten if there is any residual traction or contracted retina due to intraretinal gliosis. It may require a limited peripheral relaxing retinotomy or even a circumferential or radial retinotomy^[56] or local retinectomy. PFCL helps to judge the mobility of retina and deciding the extent of retinotomy and retinectomy. A retinectomy should be made as anterior as possible after stabilizing the posterior pole with PFCL. Hemorrhage is avoided by meticulous endocautery to posterior edge. The posterior edges of the retinectomy are then thoroughly sealed with 2 or 3 concentric rows of endolaser photocoagulation. The retina anterior to the retinotomy should be completely removed to prevent neovascularization due to ischemic stimuli.^[57]

Failure to relieve all traction is the most frequent cause of a poor anatomic result. On the other hand, a relaxing retinotomy should not be undertaken lightly. After a large circumferential retinotomy, the posterior free edge may trigger PVR aggressively, contract under SO almost back to the disk and macula, and compromise the visual outcome.^[35] Another complication of retinectomy is hypotony. In the SO study, hypotony was more prevalent in eyes that had undergone retinectomy than those that did not. In addition, in the eyes that underwent retinectomy, hypotony was less frequent in oil-filled eyes than gas filled in the first 6 months follow-up.^[58] However, other studies contradict the association between retinectomy size and postoperative hypotony.^[59,60]

Tsui and Schubert^[61] reported an anatomical success rate of 90% in 41 patients with re-RD caused by anterior intraretinal and subretinal PVR, which required greater than 180° retinotomy and SO tamponade.

Quiram^[62] *et al.* found similar success rates of more than 90% complete retinal attachment after lensectomy, radical anterior base dissection, and inferior retinectomy in 56 patients with PVR-induced re-RD. After retinal reattachment, BCVA was improved or stabilized in 70% patients. SOR was performed in 58% before the last follow-up visit, with a 4% redetachment rate.

Tan *et al.* retrospectively reviewed 123 patients undergoing retinectomy without SB for anterior PVR. Ninety-six patients (77.2%) required no additional surgeries, 21 patients (17.1%) required 1 additional operation, and 4 patients (3.8%) required 2 additional operations. Visual acuity improved in a statistically significant fashion, from 2.10 to 1.44 logMAR units in all patients.^[63]

Mancino *et al.* found a success rate of 90% with 180° inferior retinectomy, SO tamponade, combined with phacoemulsification and intraocular lens implantation for recurrent inferior RD with Grade C PVR in phakic eyes that had undergone primary vitrectomy.^[64]

In a retrospective analysis of 51 eyes undergoing retinectomy of 180° or more, visual improvement or stabilization was achieved in 76.2% patients.^[59]

Narala *et al.* evaluated the outcomes of repeat vitrectomy for PVR after previous failed vitrectomy. Authors found that eyes with a history of preoperative retinectomy were significantly more common in the unsuccessful group, as they likely had more severe PVR to begin with, therefore increasing risk of persistent retinal contraction after surgery.^[65]

Tamponade in proliferative vitreoretinopathy cases

A tamponade agent because of its surface tension reduces the rate of fluid flow through open retinal tears, which would cause re-RD until the applied retinopexy (photocoagulation or cryopexy) creates a permanent seal. Since the USFDA approved SO in 1996 for the purpose of intraocular tamponade, it has been routinely used as an adjunct in vitreoretinal surgery. A controlled trial suggested that short-term tamponade for 2 weeks with sulfur hexafluoride (SF6) was inadequate but that longer acting gas tamponade with octafluorocyclobutane (C3F8) for up to 4 weeks was adequate for many eyes. Results were comparable in long-term outlook to those in which SO was inserted.^[66,67] The SO study concluded that SO was superior to sulfur hexafluoride and roughly equivalent to fluoropropane in cases with RD with severe PVR.^[67]

In practice, however, most surgeons prefer SO. This is because the majority of these eyes have already had one or more previous surgeries and SO tends to quieten the eye down much quicker and ensure control of a very difficult clinical situation.

Most vitreoretinal surgeons prefer the 1000–1300 cSt oil because of its relative ease of removal. The final aim is to achieve a complete fill of the vitreous cavity with SO but an IOP between 10 and 15 mmHg.^[35]

Heavy silicone oil

An additional choice for retinal tamponade is that of heavier than water, fluorinated silicone liquid. Heavy silicone oil (HSO) tamponades the inferior retina when the patient is upright. It has been used in combination with light SO but more often as an alternative, particularly after inferior relaxing

retinotomy. Third-generation HSO tamponades are reported to have a complication profile similar to light SO with better tamponade of the inferior retina and posterior pole. The toxic effects of long-term retention in the eye are not yet known, and emulsification is frequent. Therefore, HSO is usually currently removed after 3 months.^[68-73]

Perfluoro-*n*-octane

In a series of 44 patients with recurrent inferior RD complicated by PVR treated with PPV, postoperative PFO was used as a medium term postoperative tamponade. Mean follow-up time was 30.71 ± 12.92 months. Successful reattachment was achieved in 86% of eyes. Additional complications observed were cataract progression requiring surgery (42%), persistent IOP elevation (36%), and transient inflammation (32%).

Thus, medium-term PFO was found to be an efficacious technique for operative management of recurrent inferior RDs complicated by Grade C PVR.^[74]

Management of re retinal detachment under silicone oil

The rate of recurrence of RD in SO filled eyes varies from 21.4% to 77%.^[12,66,75] The important causes of failure in SO filled eyes include PVR, leaking untamponaded peripheral inferior retinal break without PVR, or intrinsic retinal contraction.

The options available for surgery under SO include:

1. Membrane surgery with SO *in situ*
2. SOR followed by removal of membranes and internal tamponade with SO or gas
3. Supplementing with SB without repeat vitrectomy

Recurrence of RD under SO provides management challenge. Unfortunately, guidelines for the diagnosis and management of these complicated cases are not defined clearly.

Revision vitrectomy with silicone oil in situ

Revision vitrectomy with SO *in situ* includes several steps that are quite similar to conventional vitrectomy. Yet, it requires meticulous planning and surgical skills. The infusion line is connected to an automated SO injector or air to maintain IOP, depending on the surgeon preference. To improve intraoperative visualization, any emulsified SO from the anterior chamber is removed. Membranes are peeled with vitreous forceps off the macula. A secondary retinal tear, if present, requires complete relief of traction and further laser. Retinal shortening usually needs a high SB and/or peripheral retinectomy. Any residual subretinal and preretinal fluid is drained by active suction, and SO is topped up as required.^[35]

Membranes under the SO may vary in thickness and adherence to the underlying detached retina. Sometimes they are so thin, pigmented, and strongly adherent to the retina that it is difficult to get at an edge and lift. More often, these membranes in SO-filled eyes can be held and removed with intraocular forceps with great ease.^[12] As the retina remains attached under oil, membrane removal is easier. Surgery under oil has an advantage in reducing the operation time.^[76]

However, it may be difficult to control bleeding under oil. If bleeding occurs, injection of additional SO to increase the IOP temporarily is the best method to stop the bleeding.^[77] Adequate diathermy to the edges of the retinotomy and to the bleeding vessels can avoid this complication.

In a study of 50 SO-filled eyes by Darwish, an unsupported lower break with no PVR was managed by face down positioning followed by laser barrage, and in cases where this technique failed, SO fluid exchange was done. Forty-four cases with retinal contraction, posterior PVR, and/or anterior PVR were operated with SO *in situ*. They reported a success rate of 85.2% in cases of re-RD posterior PVR to 57.1% in cases of combined anterior and posterior PVR.^[77]

Revision vitrectomy with silicone oil removal

Revision of vitrectomy with SOR is recommended in the following instances:

1. Phakic SO-filled eyes
2. If extensive membrane dissection is anticipated in both posterior and peripheral regions
3. When subretinal SO or a large amount of subretinal emulsified oil is present
4. When extensive subretinal proliferation is responsible for redetachment
5. When large relaxing retinotomies along with large retinotomies are desired to attain intraoperative flattening of the retina^[23]

Supplemental scleral buckle in silicone oil-filled eyes

Another surgical approach is SB, which can increase the tamponade effect of SO on the inferior retina, as it creates an area of contact by bringing the peripheral retina closer to the SO bubble, while relieving the traction on the retina circumferentially and supporting the retinal breaks. Acar *et al.*^[78] and Solaiman and Dabour^[26] reported that inferior RD in SO-filled eyes treated with SB surgery had satisfactory functional and anatomic outcomes in selected re-RD cases.

The surgical technique includes localization of the open retinal breaks and retinopexy with cryotherapy and/or laser photocoagulation, then placement of scleral sutures, external drainage of any significant SRF, and placement of an explant. If required, pars plana aspiration of SO can be done in cases of raised IOP or shallow SRF.

Solaiman and Dabour^[26] evaluated the efficiency of treating selected cases of inferior RD in SO-filled eyes using a supplemental SB with external drainage of SRF versus re-vitrectomy. They found shorter operating time in SB group with similar results after SOR. They concluded that SB could offer a faster, less invasive, and better economic alternative to repeated vitreoretinal surgery for treatment of such cases.

In a case series of seven patients with recurrent inferior RD under oil, Acar *et al.* reported anatomic success rate of 85.7% after SOR. Pars plana aspiration of SO was done in three cases.^[78]

Wei *et al.* compared the effectiveness of supplemental SB versus re-vitrectomy depending on the timing of detachment from primary surgery. The study concluded that for eyes with recurrent inferior RD in the early period (≤ 1 month) after primary vitrectomy, SB surgery may be a better choice since it causes less complication, while in the late period (1–6 months) after primary PPV, re-vitrectomy may be recommended, especially for the eyes with severe anterior PVR and retinal foreshortening.^[79]

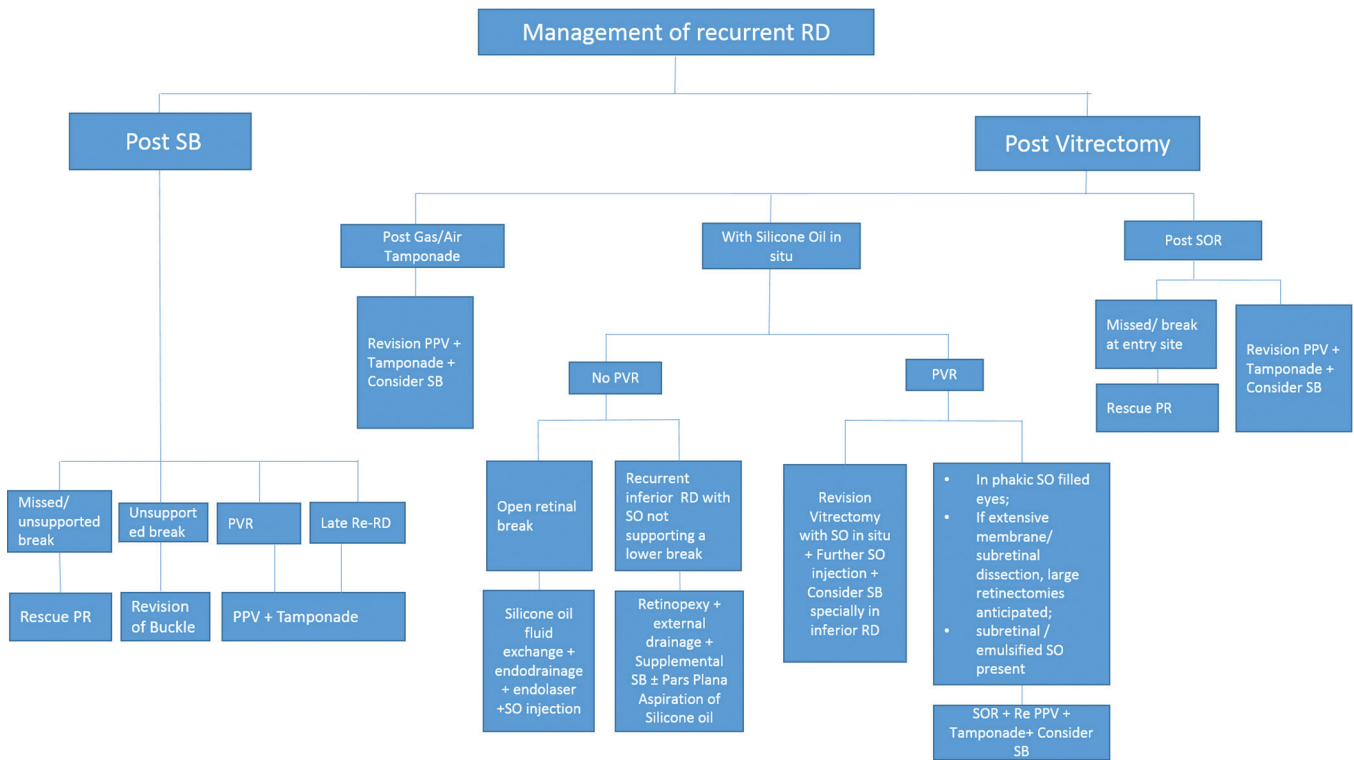


Figure 1: Flow chart for management of recurrent retinal detachment. RRD: Rhegmatogenous retinal detachment; re-RD: recurrent retinal detachment; SO: silicone oil; PVR: proliferative vitreoretinopathy; SB: scleral buckle; PR: pneumatic retinopexy; SOR: silicone oil removal

Recurrent retinal detachment in highly myopic eyes

re-RD occurring in highly myopic eyes frequently entails a guarded prognosis and its treatment usually consists of extensive inferior retinotomy^[79] or tamponade with HSO, in addition to being technically challenging and functionally disappointing. In a study by Guido Ripandelli *et al.*,^[32] they retrospectively evaluated data from 255 eyes of 237 highly myopic patients having re-RD after primary SB (40%), primary PPV (40%), and multiple surgeries (20%). Results of their study gave a high reattachment rate of 90% in the post-SB group, 90% in the post-PPV group, and 85% in the post-multiple surgery group. Although the visual acuity gain was disappointing in the SB group (mean 20/60) and 20/200 in both post-PPV and post-multiple surgery groups, they concluded that encircling SB with extensive inferior indentation can be an indispensable adjunct to PPV, ILM peeling, and SO tamponade in the treatment of re-RD in highly myopic eyes.^[80]

The algorithm for management of recurrent RRD has been summarized in Fig. 1.

Conclusion

As SB is on a decreasing trend and primary vitrectomy is often the preferred choice for most of the surgeons, this coupled with the advances in technology has led to pars plana vitrectomy becoming the cornerstone for the management of re-RDs. It is thus important to study the outcomes of multiple interventions to understand whether performing repeat vitrectomy on patients with a history of failed surgeries is worthwhile.

Enders *et al.* found that patients with first redetachment are exposed to a risk of approximately 21–26% for recurring RD after every additional surgical procedure aiming for RD repair. Predictability of functional outcome remained poor because of the wide range of interindividual postoperative visual acuity.^[2]

In addition, Pournaras *et al.* were able to show that repeated operations in cases of refractory RD can result in a high percentage of anatomical success (80%) with a considerable percentage of eyes retaining a good visual acuity (29%). PVR was found to affect both the anatomical and functional outcome.

In another retrospective case series including 51 eyes undergoing repeat surgery after failed previous vitrectomy for PVR, 17 (33.3%) eyes deemed successful and 34 (66.7%) eyes unsuccessful. Authors stressed on the fact that success after repeat surgery for PVR should include ambulatory vision, retinal reattachment, and SOR.^[65]

Thus, re-RD remains a significant challenge for vitreoretinal surgeons as well as the patients considering the economic and the emotional burden of undergoing multiple interventions. However, even if some patients retain ambulatory vision, it may be rewarding to operate such cases.

Financial support and sponsorship

Nil.

Conflicts of interest

There are no conflicts of interest.

References

- Adelman RA, Parnes AJ, Ducournau D; European Vitreo-Retinal Society (EVRs) Retinal Detachment Study Group. Strategy for the management of uncomplicated retinal detachments: The European Vitreo-Retinal Society Retinal Detachment study report 1. *Ophthalmology* 2013;120:1804-8.
- Enders P, Schick T, Schaub F, Kemper C, Fauser S. Risk of multiple recurring retinal detachment after primary rhegmatogenous retinal detachment repair. *Retina* 2017;37:930-5.
- McPherson A, Moura R. Full-thickness scleral buckling with cryoapplication and silicone sponge in retinal detachment surgery: A review of 447 cases. In: Pruett RC, Regan CD, editors. *Retina Congress*. New York: Appleton-Century-Crofts; 1972. p. 325-53.
- Benson WE. *Retinal Detachment. Diagnosis and Management*. 2nd ed. Philadelphia: J. B. Lippincott; 1988.
- Choudhary MM, Choudhary MM, Saeed MU, Ali A. Removal of silicone oil: Prognostic factors and incidence of retinal redetachment. *Retina* 2012;32:2034-8.
- Rootman DB, Luu S, M Conti S, Mandell M, Devenyi R, Lam WC, *et al*. Predictors of treatment failure for pneumatic retinopexy. *Can J Ophthalmol* 2013;48:549-52.
- Anaya JA, Shah CP, Heier JS, Morley MG. Outcomes after failed pneumatic retinopexy for retinal detachment. *Ophthalmology* 2016;123:1137-42.
- Goezinne F, La Heij EC, Berendschot TT, Kessels AG, Liem AT, Diederich RM, *et al*. Incidence of redetachment 6 months after scleral buckling surgery. *Acta Ophthalmol* 2010;88:199-206.
- Petrushkin HJ, Elgohary MA, Sullivan PM. Rescue pneumatic retinopexy in patients with failed primary retinal detachment surgery. *Retina* 2015;35:1851-9.
- Sigler EJ, Randolph JC, Calzada JJ, Charles S. Anatomical and visual outcomes after two-port pars plana vitrectomy reoperation under silicone oil for epimacular membrane or recurrent retinal detachment. *Retina* 2014;34:1939-44.
- Ambiya V, Rani PK, Narayanan R, Balakrishnan D, Chhablani J, Jalali S, *et al*. Outcomes of recurrent retinal detachment surgery following pars plana vitrectomy for rhegmatogenous retinal detachment. *Semin Ophthalmol* 2018;33:657-63.
- Sharma T, Gopal L, Shanmugam MP, Bhende PS, Agrawal R, Badrinath SS, *et al*. Management of recurrent retinal detachment in silicone oil-filled eyes. *Retina* 2002;22:153-7.
- Üney GÖ, Acar MA, Ünlü N, Hazirolan D, Yalniz-Akkaya Z, Örnek F, *et al*. Pars plana vitrectomy with silicone oil tamponade in failed scleral buckle surgery. *Can J Ophthalmol* 2016;51:331-5.
- Wickham L, Ho-Yen GO, Bunce C, Wong D, Charteris DG. Surgical failure following primary retinal detachment surgery by vitrectomy: Risk factors and functional outcomes. *Br J Ophthalmol* 2011;95:1234-8.
- Adelman RA, Parnes AJ, Michalewska Z, Ducournau D; European Vitreo-Retinal Society (EVRs) Retinal Detachment Study Group. Clinical variables associated with failure of retinal detachment repair: The European Vitreo-Retinal Society Retinal Detachment Study Report number 4. *Ophthalmology* 2014;121:1715-9.
- Kapran Z, Uyar OM, Kaya V, Eltutar K. Recurrences of retinal detachment after vitreoretinal surgery, and surgical approach. *Eur J Ophthalmol* 2001;11:166-70.
- Goezinne F, Heij EC, Berendschot TT, Gast ST, Liem AT, Lundqvist IL, *et al*. Low redetachment rate due to encircling scleral buckle in giant retinal tears treated with vitrectomy and silicone oil. *Retina* 2008;28:485-92.
- Nagpal MP, Videkar RP, Nagpal KM. Factors having implications on re-retinal detachments after silicone oil removal. *Indian J Ophthalmol* 2013;61:534.
- Teke MY, Balikoglu-Yilmaz M, Yuksekkaya P, Citirik M, Elgin U, Kose T, *et al*. Surgical outcomes and incidence of retinal redetachment in cases with complicated retinal detachment after silicone oil removal: Univariate and multiple risk factors analysis. *Retina* 2014;34:1926-38.
- Jonas JB, Knorr HL, Rank RM, Budde WM. Retinal redetachment after removal of intraocular silicone oil tamponade. *Br J Ophthalmol* 2001;85:1203-7.
- Foster RE, Meyers SM. Recurrent retinal detachment more than 1 year after reattachment. *Ophthalmology* 2002;109:1821-7.
- Zhioua R, Ammous I, Errais K, Zbiba W, Ben Younes N, Lahdhiri I, *et al*. Frequency, characteristics, and risk factors of late recurrence of retinal detachment. *Eur J Ophthalmol* 2008;18:960-4.
- Speicher MA, Fu AD, Martin JP, von Fricken MA. Primary vitrectomy alone for repair of retinal detachments following cataract surgery. *Retina* 2000;20:459-64.
- Kon CH, Occleston NL, Charteris D, Daniels J, Aylward GW, Khaw PT, *et al*. A prospective study of matrix metalloproteinases in proliferative vitreoretinopathy. *Invest Ophthalmol Vis Sci* 1998;39:1524-9.
- Glaser BM, Cardin A, Biscoe B. Proliferative vitreoretinopathy. The mechanism of development of vitreoretinal traction. *Ophthalmology* 1987;94:327-32.
- Solaiman KA, Dabour SA. Supplemental scleral buckling for inferior retinal detachment in silicone oil-filled eyes. *Retina* 2014;34:1076-82.
- Aaberg TM. Management of anterior and posterior proliferative vitreoretinopathy. XLV. Edward Jackson memorial lecture. *Am J Ophthalmol* 1988;106:519-32.
- Diddie KR, Azen SP, Freeman HM, Boone DC, Aaberg TM, Lewis H, *et al*. Anterior proliferative vitreoretinopathy in the silicone study. Silicone study report number 10. *Ophthalmology* 1996;103:1092-9.
- Stavarakas P, Tranos P, Androu A, Xanthopoulos P, Tsoukanas D, Stamatou P, *et al*. Anatomical and functional results following 23-gauge primary pars plana vitrectomy for rhegmatogenous retinal detachment: Superior versus inferior breaks. *J Ophthalmol* 2017;2017:2565249.
- Smiddy WE, Glaser BM, Michels RG, de Bustros S. Scleral buckle revision to treat recurrent rhegmatogenous retinal detachment. *Ophthalmic Surg* 1990;21:716-20.
- Han DP, Covert DJ, Wirostko WJ, Hammersley JA, Lindgren KE. Scleral buckle removal in the vitrectomy era: A 20-year clinical experience. *Retina* 2013;33:387-91.
- Ripandelli G, Rossi T, Scarinci F, Stirpe M. Encircling scleral buckling with inferior indentation for recurrent retinal detachment in highly myopic eyes. *Retina* 2015;35:416-22.
- Kolomeyer AM, Grigorian RA, Mostafavi D, Bhagat N, Zarbin MA. 360° retinectomy for the treatment of complex retinal detachment. *Retina* 2011;31:266-74.
- Scholda C, Egger S, Lakits A, Walch K, von Eckardstein E, Biowski R. Retinal detachment after silicone oil removal. *Acta Ophthalmol Scand* 2000;78:182-6.
- Constable I, Nagpal M. Proliferative vitreoretinopathy. Vol. 111. *Ryan's Retina*. 6th ed. Cleveland: Elsevier; 2018. p. 2031-51.
- Brazitikos PD, Androudi S, Christen WG, Stangos NT. Primary pars plana vitrectomy versus scleral buckle surgery for the treatment of pseudophakic retinal detachment: A randomized clinical trial. *Retina* 2005;25:957-64.
- Mendrinou E, Dang-Burgener NP, Stangos AN, Sommerhalder J, Pournaras CJ. Primary vitrectomy without scleral buckling for pseudophakic rhegmatogenous retinal detachment. *Am J Ophthalmol* 2008;145:1063-70.
- Nagpal M, Bhardwaj S, Mehrotra N. Scleral buckling for rhegmatogenous retinal detachment using vitrectomy-based visualization systems and chandelier illumination. *Asia Pac J Ophthalmol (Phila)* 2013;2:165-8.

39. Kreissig I, Rose D, Jost B. Minimized surgery for retinal detachments with segmental buckling and nondrainage. An 11-year follow-up. *Retina* 1992;12:224-31.
40. Friberg TR, Eller AW. Laser pneumatic retinopexy for repair of recurrent retinal detachment after failed scleral buckle – ten years experience. *Ophthalmic Surg Lasers* 2001;32:13-8.
41. Levkovitch-Verbin H, Treister G, Moisseiev J. Pneumatic retinopexy as supplemental therapy for persistent retinal detachment after scleral buckling operation. *Acta Ophthalmol Scand* 1998;76:353-5.
42. Wykoff C. Treating recurrent retinal detachment due to PVR. *Retina Today* 2017:32-3.
43. Bhende PS, Lobo A. Micro incision vitrectomy surgery (MIVS): An overview. *Sci J Med Vis Res Found* 2015;33:57-60.
44. Nagpal M, Verma A, Goswami S. Micro-incision vitrectomy Surgery – Past, present and future. *Eur Ophthalmic Rev* 2015;9:64-8.
45. Rodrigues EB, Maia M, Meyer CH, Penha FM, Dib E, Farah ME, *et al.* Vital dyes for chromovitrectomy. *Curr Opin Ophthalmol* 2007;18:179-87.
46. Kumar A, Thirumalesh MB. Use of dyes in ophthalmology. *J Clin Ophthalmol Res* 2013;1:55-8.
47. Constable I, Nagpal M. Proliferative vitreoretinopathy. *Retina*. 5th ed., Vol. 107. Cleveland: Elsevier; 2013. p. 1806-25.
48. Coffee RE, Jiang L, Rahman SA. Proliferative vitreoretinopathy: Advances in surgical management. *Int Ophthalmol Clin* 2014;54:91-109.
49. Jackson TL, Hillenkamp J, Knight BC, Zhang JJ, Thomas D, Stanford MR, *et al.* Safety testing of Indocyanine green and Trypan blue using retinal pigment epithelium and glial cell cultures. *Invest Ophthalmol Vis Sci* 2004;45:2778-85.
50. Veckeneer M, Mohr A, Alharthi E, Azad R, Bashshur ZF, Bertelli E, *et al.* Novel 'heavy' dyes for retinal membrane staining during macular surgery: Multicenter clinical assessment. *Acta Ophthalmol* 2014;92:339-44.
51. Mohr A, Bruinsma M, Oellerich S, Frank H, Gabel D, Melles GR, *et al.* Dyes for eyes™: Hydrodynamics, biocompatibility and efficacy of 'heavy' (dual) dyes for chromovitrectomy. *Ophthalmologica* 2013;230 Suppl 2:51-8.
52. Rodrigues EB, Meyer CH, Farah ME, Kroll P. Intravitreal staining of the internal limiting membrane using Indocyanine green in the treatment of macular holes. *Ophthalmologica* 2005;219:251-62.
53. Kumar A, Gogia V, Shah VM, Nag TC. Comparative evaluation of anatomical and functional outcomes using Brilliant blue G versus triamcinolone assisted ILM peeling in macular hole surgery in Indian population. *Graefes Arch Clin Exp Ophthalmol* 2011;249:987-95.
54. Minarcik JR, von Fricken MA. Virtual retinectomy: Indocyanine green-assisted internal limiting membrane peeling as a surgical adjunct in repair of recurrent rhegmatogenous retinal detachment due to PVR. *Clin Ophthalmol* 2012;6:631-6.
55. Machemer R, McCuen BW 2nd, de Juan E Jr. Relaxing retinotomies and retinectomies. *Am J Ophthalmol* 1986;102:7-12.
56. Lim AK, Alexander SM, Lim KS. Combined large radial retinotomy and circumferential retinectomy in the management of advanced proliferative vitreoretinopathy. *Retina* 2009;29:112-6.
57. Bourke RD, Cooling RJ. Vascular consequences of retinectomy. *Arch Ophthalmol* 1996;114:155-60.
58. Blumenkranz MS, Azen SP, Aaberg T, Boone DC, Lewis H, Radtke N, *et al.* Relaxing retinotomy with silicone oil or long-acting gas in eyes with severe proliferative vitreoretinopathy. Silicone study report 5. The silicone study group. *Am J Ophthalmol* 1993;116:557-64.
59. Nagpal M, Jain P, Nagpal K, Patil A. Outcomes of retinectomy of 180 degree or more in retinal detachment with advanced proliferative vitreoretinopathy. *World J Retina Vitreous* 2011;1:63-8.
60. Morse LS, McCuen BW 2nd, Machemer R. Relaxing retinotomies. Analysis of anatomic and visual results. *Ophthalmology* 1990;97:642-7.
61. Tsui I, Schubert HD. Retinotomy and silicone oil for detachments complicated by anterior inferior proliferative vitreoretinopathy. *Br J Ophthalmol* 2009;93:1228-33.
62. Quiram PA, Gonzales CR, Hu W, Gupta A, Yoshizumi MO, Kreiger AE, *et al.* Outcomes of vitrectomy with inferior retinectomy in patients with recurrent rhegmatogenous retinal detachments and proliferative vitreoretinopathy. *Ophthalmology* 2006;113:2041-7.
63. Tan HS, Mura M, Oberstein SY, de Smet MD. Primary retinectomy in proliferative vitreoretinopathy. *Am J Ophthalmol* 2010;149:447-52.
64. Mancino R, Aiello F, Ciuffoletti E, Di Carlo E, Cerulli A, Nucci C, *et al.* Inferior retinotomy and silicone oil tamponade for recurrent inferior retinal detachment and grade C PVR in eyes previously treated with pars plana vitrectomy or scleral buckle. *BMC Ophthalmol* 2015;15:173.
65. Narala R, Nassiri N, Kim C, Mehregan C, Padidam S, Abrams GW, *et al.* Outcomes of repeat pars plana vitrectomy after failed surgery for proliferative vitreoretinopathy. *Retina* 2018;38 Suppl 1:S49-59.
66. Vitrectomy with silicone oil or sulfur hexafluoride gas in eyes with severe proliferative vitreoretinopathy: Results of a randomized clinical trial. Silicone study report 1. *Arch Ophthalmol* 1992;110:770-9.
67. Schwartz SG, Flynn HW, Lee W-H, Ssemamanda E, Ervin A-M. Tamponade in surgery for retinal detachment associated with proliferative vitreoretinopathy. *Cochrane Database Syst Rev* 2009;(4):CD006126.
68. Berker N, Batman C, Ozdamar Y, Eraniel S, Aslan O, Zilelioglu O, *et al.* Long-term outcomes of heavy silicone oil tamponade for complicated retinal detachment. *Eur J Ophthalmol* 2007;17:797-803.
69. Auriol S, Pagot-Mathis V, Mahieu L, Lemoine C, Mathis A. Efficacy and safety of heavy silicone oil Densiron 68 in the treatment of complicated retinal detachment with large inferior retinectomy. *Graefes Arch Clin Exp Ophthalmol* 2008;246:1383-9.
70. Duan A, She H, Qi Y. Complications after heavy silicone oil tamponade in complicated retinal detachment. *Retina* 2011;31:547-52.
71. Li W, Zheng J, Zheng Q, Wu R, Wang X, Xu M, *et al.* Clinical complications of Densiron 68 intraocular tamponade for complicated retinal detachment. *Eye (Lond)* 2010;24:21-8.
72. Morescalchi F, Costagliola C, Duse S, Gambicorti E, Parolini B, Arcidiacono B, *et al.* Heavy silicone oil and intraocular inflammation. *Biomed Res Int* 2014;2014:574825.
73. Jousen AM, Rizzo S, Kirchhof B, Schrage N, Li X, Lente C, *et al.* Heavy silicone oil versus standard silicone oil in as vitreous tamponade in inferior PVR (HSO study): Interim analysis. *Acta Ophthalmol* 2011;89:e483-9.
74. Sigler EJ, Randolph JC, Calzada JI, Charles S. Pars plana vitrectomy with medium-term postoperative perfluoro-N-octane for recurrent inferior retinal detachment complicated by advanced proliferative vitreoretinopathy. *Retina* 2013;33:791-7.
75. McCuen BW 2nd, Landers MB 3rd, Machemer R. The use of silicone oil following failed vitrectomy for retinal detachment with advanced proliferative vitreoretinopathy. *Ophthalmology* 1985;92:1029-34.
76. Yang CM, Hsieh YT, Yang CH, Liu KR. Irrigation-free vitreoretinal surgery for recurrent retinal detachment in silicone oil-filled eyes. *Eye (Lond)* 2006;20:1379-82.
77. Darwish AAI. Management of recurrent retinal detachment in silicone oil filled eyes. Keys to diagnosis of pathogenesis and management. *Adv Ophthalmol Vis Syst* 2014;1:00003.
78. Acar MA, Ünlü N, Hazirolan D, Demir MN, Üney GÖ, Örnek F, *et al.* Conventional surgery for complicated retinal detachment in silicone oil-filled eyes. *Eur J Ophthalmol* 2011;21:290-5.
79. Wei Y, Wu G, Xu K, Wang J, Zu Z, Wang R, *et al.* The outcomes of scleral buckling versus re-vitrectomy for the treatment of recurrent inferior retinal detachment in silicone oil tamponade eyes. *Acta Ophthalmol* 2016;94:e624-8.
80. Pournaras C, Tsika C, Brozou C, Tsilimbaris MK. Surgical and visual outcome for recurrent retinal detachment surgery. *J Ophthalmol* 2014;2014:810609.