

Available online at [www.sciencedirect.com](http://www.sciencedirect.com)

ScienceDirect

journal homepage: <http://Elsevier.com/locate/radcr>

## Case Report

# Uterine artery embolization for cervical ectopic pregnancy

Qiao Zhou MD<sup>a,\*</sup>, Daniel Young MS<sup>b</sup>, Harlan Vingan MD<sup>b</sup>

<sup>a</sup> Department of Radiology, 270 West York St, Norfolk, VA, 23510, USA

<sup>b</sup> Department of Radiology, Eastern Virginia Medical School, 800 Gresham Dr, Norfolk, VA, USA

## ARTICLE INFO

## Article history:

Received 11 July 2015

Accepted 23 August 2015

Available online 9 October 2015

## ABSTRACT

A 36-year-old woman with 3 prior C-sections is diagnosed with a caesarean scar ectopic pregnancy. Despite receiving intramuscular and transvaginal methotrexate injection 2 months before presentation, the beta human chorionic gonadotropin was recorded to be 73 mIU/mL at the time of encounter. The patient complained of vaginal bleeding with a significant drop in hematocrit from 40% to 33%. Transvaginal ultrasound confirmed retroplacental hemorrhage and because of the patient's desire to retain fertility, interventional radiology was consulted to perform an uterine artery embolization. The uterine artery embolization was successful in achieving hemostasis and resulted in a decrease of betaHCG to 46 on postprocedure day 1 to <1 mIU/mL by postoperative week 3.

Copyright © 2015, the Authors. Published by Elsevier Inc. under copyright license from the University of Washington. This is an open access article under the CC BY-NC-ND license (<http://creativecommons.org/licenses/by-nc-nd/4.0/>).

## Case report

A 36-year-old female G4P3003 with 3 prior cesarean deliveries and recently diagnosed cesarean scar ectopic pregnancy presents with a 1-week history of vaginal bleeding, passage of clots, and lower abdominal cramping. She had already received intramuscular methotrexate and ultrasound-guided transvaginal methotrexate injection 2 months before presentation. The patient's beta human chorionic gonadotropin (beta-HCG) had decreased from 47,832 mIU/mL to 73 mIU/mL after administration of methotrexate. At presentation, the patient's hematocrit was 33.9%, which had dropped from 40.2% within 5 days. The patient was hemodynamically stable, and her physical examination was unremarkable, however, transvaginal ultrasound suggested a retroplacental hemorrhage. The patient

was admitted to the Gynecology service and further declined any surgical interventions, namely hysterectomy, with the intention of preserving future fertility. Interventional Radiology was consulted to evaluate the patient for uterine artery embolization to achieve hemostasis.

A right femoral Seldinger approach was used to gain access to the right femoral artery, and subsequently, an anterior posterior pelvic angiography was performed at the infrarenal abdominal aorta (Fig. 1). The bilateral uterine arteries were patent with mildly hypertrophied terminal branches. There was a focal area of dense contrast extravasation in the region of the lower uterine segment originating from the terminal branches of the right uterine artery. Conversely, there was no evidence of extravasation from the left uterine artery. The right uterine artery was embolized with gelfoam with

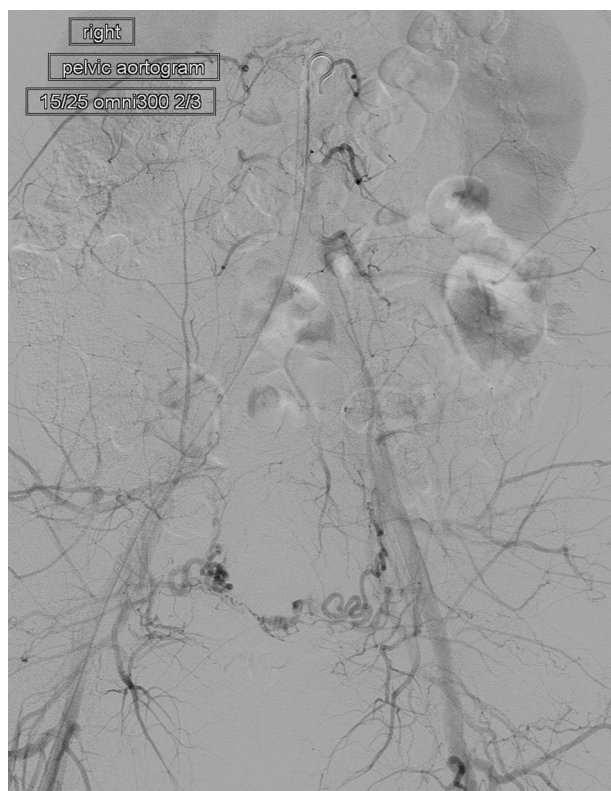
The authors Q.Z., D.Y., and H.V. declare that this case has never been presented; no financial conflicts of interest; and this study is institutional review board exempt.

Competing Interests: The authors have declared that no competing interests exist.

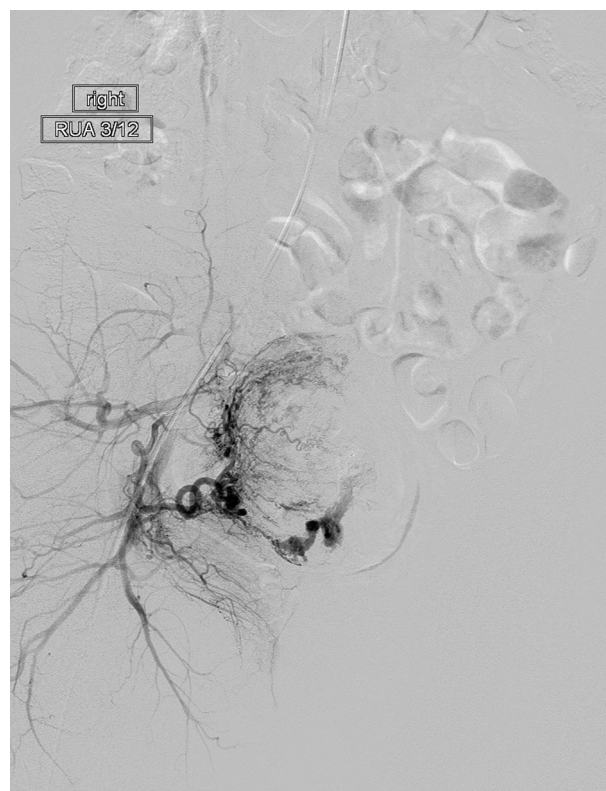
\* Corresponding author.

E-mail address: [Qzhou1984@gmail.com](mailto:Qzhou1984@gmail.com) (Q. Zhou).  
<http://dx.doi.org/10.1016/j.radcr.2015.08.004>

1930-0433/Copyright © 2015, the Authors. Published by Elsevier Inc. under copyright license from the University of Washington. This is an open access article under the CC BY-NC-ND license (<http://creativecommons.org/licenses/by-nc-nd/4.0/>).



**Fig. 1 – Digitally subtracted angiographic image of the infrarenal abdominal aorta demonstrates visualization of the bilateral uterine arteries.**



**Fig. 2 – Digitally subtracted image of the right uterine artery demonstrating mildly hypertrophied terminal branches and focal, dense contrast extravasation in the distal terminal branches.**

demonstrable, marked decrease in uterine artery perfusion and diminished contrast extravasation (Figs. 2, 3). The left uterine artery was embolized with Gelfoam slurry until successful contrast stagnation was obtained (Fig. 4). Upon closer scrutiny, there was a small area of extravasation suspected to arise from a small branch of the left anterior division of the hypogastric artery (Fig. 5). This terminal branch was targeted with  $3 \times 5 \text{ mm}^2$  figure 8 microcoils (Fig. 6). The patient tolerated the procedure well. Hemostasis was noted at the end of the procedure with minimal intraoperative blood loss.

The patient did well postoperatively, and only complaint was nausea associated with her patient controlled anesthesia pump that resolved when switched to oral pain medication. The patient had good urine output, tolerating bland diet, and ambulating without difficulty. The patient's beta-HCG had continued to diminish from 73 uIU/mL to 46 mIU/mL on postprocedure day 1. The patient was discharged on postprocedure day 1 with pain medication, stool softeners, instructions for pelvic rest, and outpatient follow-up with Gynecology in 2 weeks.

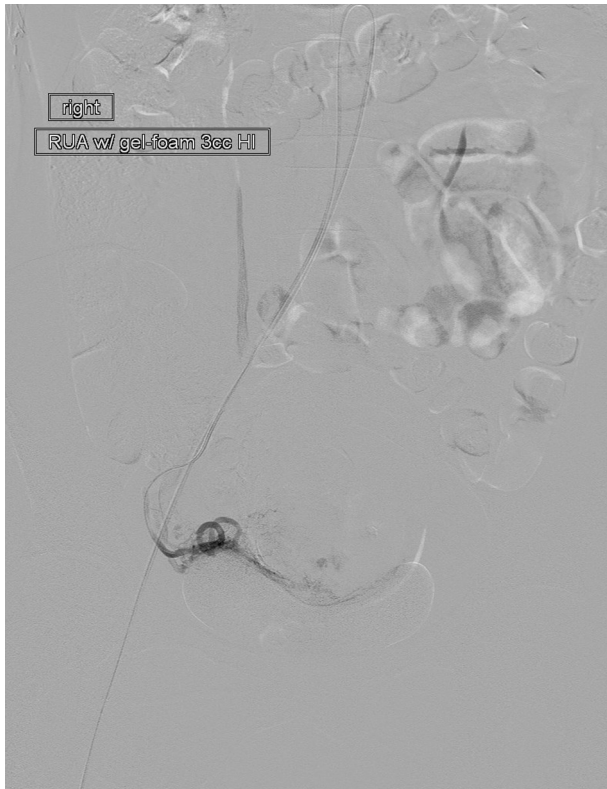
At postprocedure week 3, the patient's serum beta-HCG level had decreased to <1 mIU/mL.

## Discussion

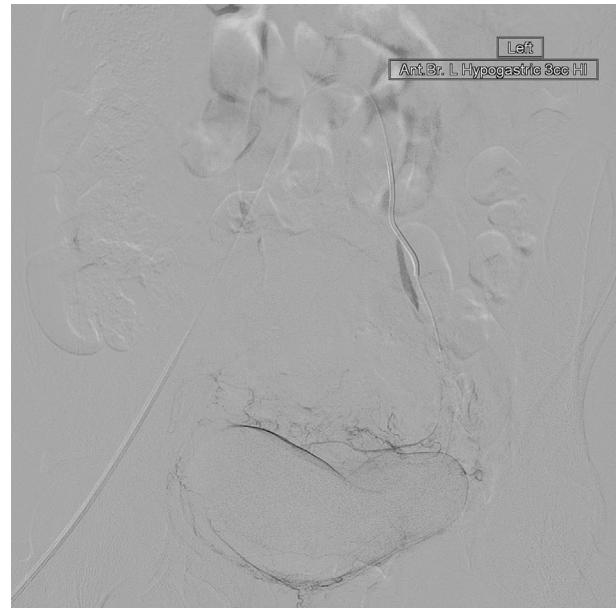
The prevalence of cervical ectopic pregnancy is estimated to be around 1 in 2500 to 18,000 deliveries. Predisposing factors

include any traction point that allows a gestation sac to be ensconced in, including cesarean section scars, scarring from previous dilation and curettages, Asherman's syndrome, and cervical conization [1]. In this patient, it was postulated that the lack of response to intramuscular methotrexate was because of the relative avascularity within the Cesarean section scar. Additional reports of decreased efficacy of methotrexate can be due to late gestational age at which the fetal heartbeat is present, betaHCG level of 10,000 mL and crown rump length of greater than 10 mm [2].

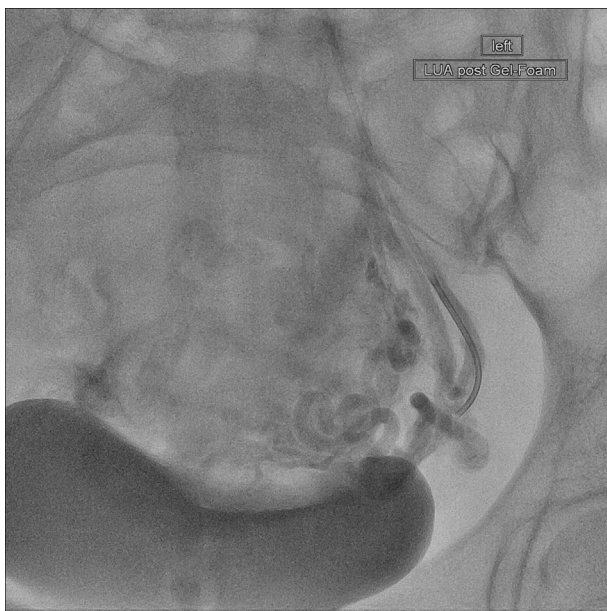
With the intention to preserve fertility, uterine artery embolization has shown efficacy in addressing cervical ectopic pregnancies [3]. Moreover, a synergistic 2-pronged approach of uterine artery embolization in conjunction with systemic methotrexate administration has demonstrated high therapeutic efficacy and is poised to become the first-line therapy used for cervical ectopic pregnancy treatment [4]. Sole use of uterine artery embolization has been proven effective if there is contraindication to methotrexate therapy such as coexisting hepatic disease [5]. Notably, concurrent therapy with methotrexate along with uterine artery embolization has been proven more effective than uterine artery embolization alone. From a post-treatment standpoint, adjunctive therapy with embolization has significantly reduced the duration of hospital stay than with methotrexate alone. Ideally, methotrexate should be administered before carrying out embolization to aid in preemptively diminishing the vascular flow to



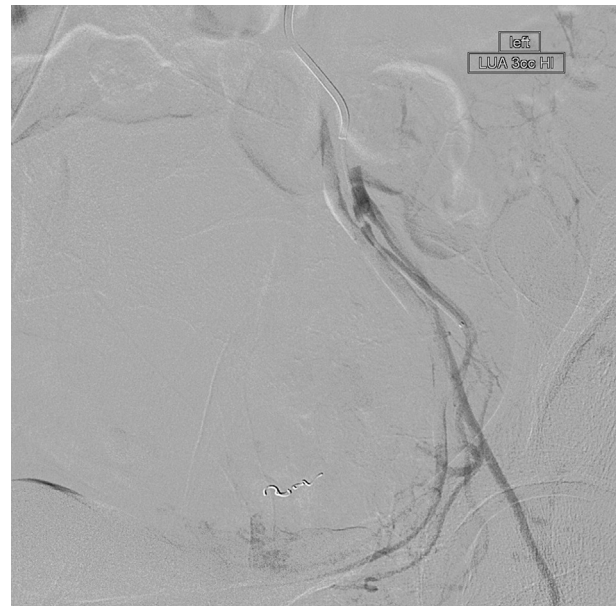**Fig. 3 – Digitally subtracted image of the right uterine artery status after gelfoam embolization resulting in decreased and nearly resolved contrast extravasation from the terminal branches.**



**Fig. 5 – Digitally subtracted image of the left hypogastric artery with identification of a small area of contrast extravasation arising from a small anterior division segmental branch.**



**Fig. 4 – Digital subtracted image of the left uterine artery status after gelfoam resulting in successful contrast stagnation.**



**Fig. 6 – Digitally subtracted image of the left hypogastric artery status after coiling of the small site of extravasation from the small segmental branch arising from the anterior division of the left hypogastric artery.**

the uterine tissue thereby augmenting the therapeutic effectiveness of embolization itself [6]. Intra-arterial infusion of methotrexate into a subselected uterine artery during the embolization has also shown great therapeutic impact in decreasing the cervical mass [7].

Potential complications of uterine artery embolization for ectopic pregnancy include uterine ischemia, necrosis, and subsequent amenorrhea from endometrial ischemia [8]. There is resumption of normal menstruation as soon as 1 month after procedure [9].

Aside from methotrexate, other treatment modalities that complement uterine artery embolization can also be used. Curettage alone for cervical ectopic pregnancy is not a viable option because of a high predisposition for uncontrollable bleeding [10]. Once embolization is performed to stem the bleeding risk, curettage can be safely carried out [11]. Because curettage can be performed concomitantly with embolization, even if there is a significant bleeding event, the interventional radiologist can immediately identify the source on angiogram [12]. One of the main advantages that has been postulated with after embolization curettage is that it circumvents the possibility that there will be delayed bleeding from reestablishment of collateral vessels [13,14]. Introduction of intra-amniotic KCl along with embolization and methotrexate can be considered when faced with a cervical ectopic pregnancy with documented heart rate.

The choice of embolization medium should also be considered. Gelfoam will considerably reduce circulation in the catheterized region for 24 hours, and there will be recanalization of the vessels in 2–6 weeks [15]. There have been mixed responses with delivering polyvinyl alcohol and/or gelfoam particles. Retreatment was not warranted in most cases whereas others have reported suboptimal response with gelfoam necessitating retreatment [6,16].

## REFERENCES

- [1] Parente JT, Ou CS, Levy J, et al. Cervical pregnancy analysis: a review and report of five cases. *Obstet Gynecol* 1983;62:79–82.
- [2] Hung TH, Chau WY, Hsieh TT, et al. Prognostic factors for an unsatisfactory primary methotrexate treatment of cervical pregnancy: a quantitative review. *Hum Reprod* 1998;13(9):2636–42.
- [3] Gun M, Mavrogiorgis M. Cervical ectopic pregnancy: a case report and literature review. *Ultrasound Obstet Gynecol* 2002;19:297–301.
- [4] Cosin JA, Bean M, Grow D, et al. The use of methotrexate and arterial embolization to avoid surgery in a case of cervical pregnancy. *Fertil Steril* 1997;67:1169–71.
- [5] Takano M, Hasegawa Y, Matsuda H, Kikuchi Y. Successful management of cervical pregnancy by selective uterine artery embolization: a case report. *J Reprod Med* 2004;49(12):986–8.
- [6] Zakaria M, Abdallah ME, Shavell VI, et al. *Fertil Steril* 2011 Mar 1;95(3):872–6.
- [7] Xiaolin Z, Ling L, Chengxin Y, Yiqing T, et al. Transcatheter intraarterial methotrexate infusion combined with selective uterine artery embolization as a treatment option for cervical pregnancy. *J Vasc Interv Radiol* 2010;21(6):836–41.
- [8] Godfrey CD, Zbella EA. Uterine necrosis after uterine artery embolization for leiomyoma. *Obstet Gynecol* 2001;98:950–2.
- [9] Martinelli P, Maruotti GM, Oppedisano R, et al. Is uterine artery embolization for cervical ectopic pregnancy always safe? *J Minim Invasive Gynecol* 2007;14(6):758–63.
- [10] Wang YK, Bing X, Dai SZ. An efficient conservative treatment modality for cervical pregnancy: angiographic uterine artery embolization followed by immediate curettage. *Am J Obstet Gynecol* 2011;204(1):31.e1–7.
- [11] Yu B, Douglas NC, Guarnaccia MM. Sauer Uterine artery embolization as an adjunctive measure to decrease blood loss prior to evacuating a cervical pregnancy. *Arch Gynecol Obstet* 2009;279:721–4.
- [12] Xu B, Wang YK, Zhang YH. Angiographic uterine artery embolization followed by immediate curettage: an efficient treatment for controlling heavy bleeding and avoiding recurrent bleeding in cervical pregnancy. *J Obstet Gynaecol Res* 2007;33:190–4.
- [13] Trambert JJ, Einstein MH, Banks E, et al. Uterine artery embolization in the management of vaginal bleeding from cervical pregnancy: a case series. *J Reprod Med* 2005;50(11):844–50.
- [14] Eblen AC, Pridham DD, Tatum Jr CM. Conservative management of an 11-week cervical pregnancy. A case report. *J Reprod Med* 1999;44(1):61–4.
- [15] Chaudhary V, Sachdeva P, Kumar D, et al. Conservative management of cervical pregnancy: a report of two cases. *J Reprod Med* 2013 Sep-Oct;58(9-10):451–7.
- [16] Hiraoka M, Tajima T, Yoshimitsu K, et al. Uterine artery embolization along with the administration of methotrexate for cervical ectopic pregnancy: technical and clinical outcomes. *AJR Am J Roentgenol* 2009;192(6):1601–7.