


Contents lists available at [ScienceDirect](https://www.elsevier.com/locate/aott)

Acta Orthopaedica et Traumatologica Turcica

journal homepage: <https://www.elsevier.com/locate/aott>

Single-incision Eden-Lange procedure in trapezius muscle paralysis: A report of 11 cases[☆]

Morteza Nakhaei Amroodi, Mostafa Salariyeh^{*}

Orthopedic Surgery, Shafa Orthopedic Hospital, Iran University of Medical Sciences, Tehran, Iran

ARTICLE INFO

Article history:

Received 4 July 2016

Received in revised form

29 October 2017

Accepted 3 December 2017

Available online 14 February 2018

Keywords:

Trapezius muscle

Paralysis

Eden-Lange procedure

Spinal accessory nerve

ABSTRACT

Objective: The aim of this study was to evaluate the outcome of single-incision Eden-Lange procedure in trapezius muscle paralysis.

Methods: The medical records of 11 patients (3 females and 8 males); mean age: 41 (25–59) years with trapezius muscle paralysis who underwent Eden-Lange procedure in our Center, between February 2009 and April 2013, were retrospectively analyzed. The clinical outcomes were evaluated with the American Shoulder and Elbow Surgeons Shoulder (ASES) score and visual analogue scale (VAS).

Results: The mean duration of symptoms before surgery was 10.18 months. The average duration of follow-up was 33.5 (24–48) months. The mean VAS score improved from 7.8 to 1.6 points ($p < 0.05$). The total ASES improved from 32.8 to 82.1 points ($p < 0.05$). The mean range of motion in forward elevation and abduction increased significantly from 121.80 to 154.40 ($p < 0.05$) and 80.00 to 148.18° ($p < 0.05$), respectively.

Conclusion: Single incision Eden-Lange procedure appears to be a safe and effective treatment option for the patients with trapezius muscle paralysis.

Level of evidence: Level IV, therapeutic study.

© 2018 Turkish Association of Orthopaedics and Traumatology. Publishing services by Elsevier B.V. This is an open access article under the CC BY-NC-ND license (<http://creativecommons.org/licenses/by-nc-nd/4.0/>).

Introduction

Scapular winging is a well-known condition and a rare cause of shoulder girdle muscle weakness.¹ Paralysis of the serratus anterior and trapezius muscles due to long thoracic and spinal accessory nerve injury, respectively are the most common cause of this condition.² In terms of prevalence, trapezius muscle paralysis, as the cause of scapular winging, is rare and as such, its diagnosis is difficult.³ The awareness about accessory nerve injury during cervical surgery and newer surgery technique have lowered the incidence of scapular winging.^{3,4} The most common symptoms of the trapezius muscle paralysis are pain, weakness, inability to perform abduction, and eventual restrictions on all overhead activities.

Electromyography (EMG) is the definitive study for the evaluation of scapular winging that originates from muscular or neurologic abnormalities.^{5,6} There may also be cases of scapular winging, in which the EMG finding shows normal; therefore, clinical suspicion should remain high regardless of the test result.⁷ Efficient improvement of trapezius muscle caused by spinal accessory nerve injury does not always derive a benefit from conservative management.⁸ Conservative treatments known to have failed include transcutaneous nerve stimulation, NSAIDs, scapular brace, physical therapy, stretching and strengthening exercise.⁹ These treatments in patients have poor prognosis and as such, most surgeons usually suggest surgical treatment. Neurolysis, nerve graft, or repair may be attempted to the spinal accessory nerve if performed within 6–12 months.¹¹ It has been reported that the choice of surgical procedure in patients with trapezius muscle paralysis is Eden-Lange,¹⁰ in which the surgeon transfers the tendon of the levator scapulae to the scapular spine and then, reattached the tendon of rhomboid minor and major to the scapular body.^{10,11} The Eden-Lange surgery mainly results in good to excellent outcomes, with adequate relief of pain and functional overhead movements.^{4,10} Therefore, this study aimed to review the causes and symptoms of scapular winging, and report the good experience in this field.

[☆] Location of research: Shafa Orthopedic Hospital.

^{*} Corresponding author. Bone and Joint Reconstruction Research Center, Shafa Orthopedic Hospital, Iran University of Medical Sciences, Tehran, IR Iran. Fax: +98 2133542020.

E-mail addresses: drmna@yahoo.com (M.N. Amroodi), mostafa.salariyeh@gmail.com (M. Salariyeh).

Peer review under responsibility of Turkish Association of Orthopaedics and Traumatology.

Materials and methods

In this study, 11 consecutive patients, who were referred to our center and operated for scapular winging due to spinal accessory nerve injury between February 2009 and April 2013, were reported. Accessory nerve injury, based on examination and electromyography, was documented within the records of all cases. All patients had been under physiotherapy before the surgery, for at least 6 months to strengthen the muscles around the shoulder. The senior author performed all the surgeries using the Eden-Lange technique. The inclusion criteria included accessory nerve injury with failed nonoperative treatment for more than 6 months, and obvious atrophy of trapezius muscle without any improvement in shoulder symptoms during the last 2 months (Fig. 1a–d). Exclusion criteria included the presence of previous shoulder pain or disease, report of malignancy of the cervical lymph node biopsy and patients above 60 years of age.

Pre-operative evaluation

All the relevant data were obtained from the patients' hospital records including demographic information, age, sex, dominant hand and involved limb. The patient's shoulder function was assessed using shoulder pain VAS and ASES score. The active ROM in forward elevation and abduction was measured using a goniometer.

Surgical technique

After general anesthesia, on prone positioning of the patient, prep and drape was done from the base of the neck and medial border of the opposite scapula to the entire affected upper limb. The hand was placed on the lumbar region to make a “chicken wing” position for the scapula to prevent any possible damage to the chest. The body of the scapula was marked and a longitudinal incision, 3 cm superior to the spine of the scapula toward its inferior angle, was done. Thereafter, trapezius was dissected from its attachment to the scapula. The supraspinatus and the infraspinatus muscles were identified and the scapula was peeled off 7 cm laterally. A longitudinal osteotomy was performed in order to detach the levator scapulae and rhomboid muscles from the superomedial angle medial border of the scapula, respectively with a shell of bone (Fig. 2a). Multiple drill-holes were created in the infraspinatus fossa and on the scapular spine, all were approximately 5 cm lateral from the medial border of the scapula (Fig. 2b).

The levator scapula muscle advanced laterally and attached to the scapular spine with two Krackow suture using heavy non-absorbable sutures. Similarly, both rhomboid muscles were attached to the infraspinatus fossa (Fig. 2c). Caution was made to keep bone-to-bone contact between the fragment and the scapular bone for better healing. The wound was closed in layers and dressed.

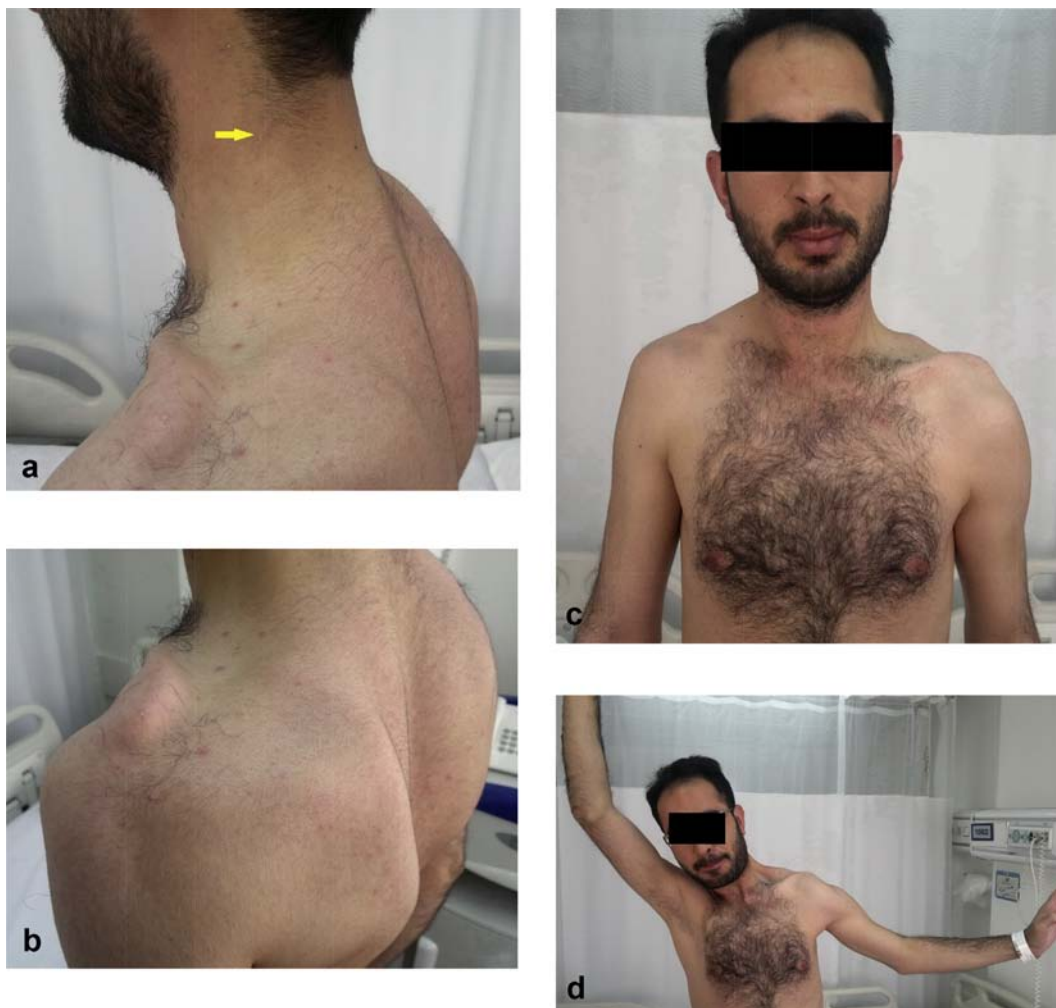

Fig. 1. (a) Photograph shows previous site of biopsy from cervical lymph node, (b, c) atrophy of trapezius muscle, (d) Limited range of motion in abduction.

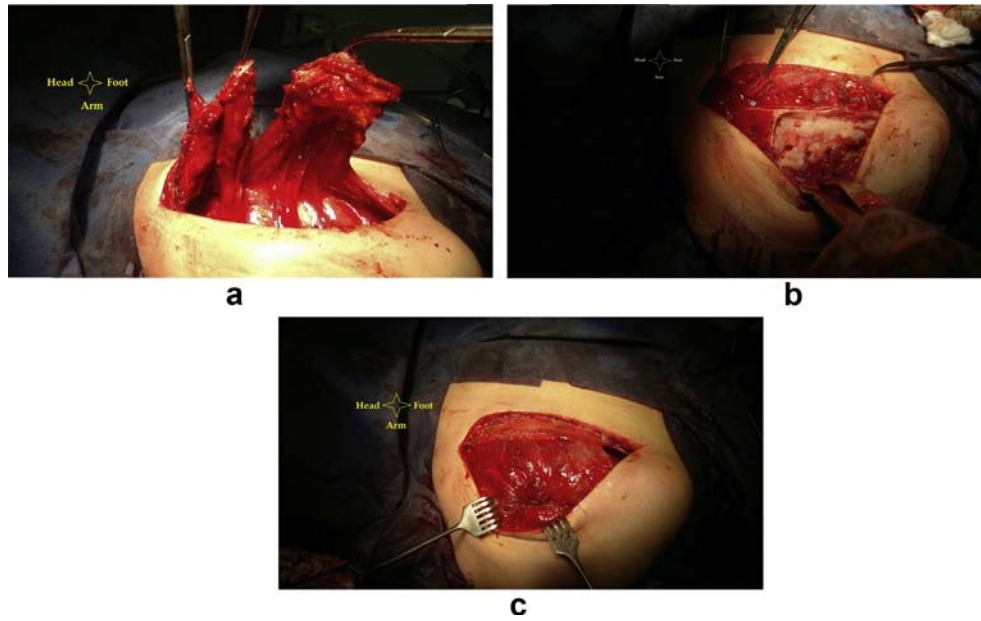


Fig. 2. (a) Levator scapulae, rhomboid minor and major muscles (from left to right respectively) were detached of the scapula with a small fragment of bones, (b) Drill holes in scapula for reattaching rhomboid muscles, (c) reattached all three muscles.

Rehabilitation

Postoperatively, the limb was immobilized in a sling for two weeks. Then pendulum movement occurred intermittently. After 7 weeks, the sling was removed completely. Thereafter, in addition to prescribing physiotherapy, the patients were asked to perform all active and passive range of motions with home exercises three times in a day, each time for at least 1 h. This rehabilitation program

was continued in order to get to the plateau state in shoulder symptoms, ROM and forces.

Assessments and statistical analysis

All patients were followed up post-operatively at the 2nd and 7th weeks, 3rd, 6th and 12th months, and then annually for an unlimited time. An antero-posterior view x-ray of the scapula was

Table 1
Patient's demographics data.

Case no	Sex	Age (years)	Dominant hand	Involved limb	mechanism	Follow-up period (months)
1	Female	52	Right	Left	Biopsy	40
2	Male	37	Right	Left	Biopsy	28
3	Male	26	Right	Right	Stab wound	26
4	Male	36	Left	Right	Blunt trauma	36
5	Female	45	Right	Left	Biopsy	48
6	Male	25	Right	Right	Biopsy	30
7	Male	33	Right	Left	Biopsy	24
8	Female	57	Right	Left	Biopsy	34
9	Male	51	Right	Right	Biopsy	42
10	Male	30	Right	Left	Biopsy	31
11	Male	59	Right	Right	Biopsy	27

Table 2
Shoulder scores and range of motions.

Case no	Pre-op ASES	Post-op ASES	Pre-op VAS score	Post-op VAS score	Pre-op active FE	Post-op active FE	Pre-op active Abd	Post-op active Abd
1	30.80	75.00	8	3	120	150	40	140
2	30.60	83.20	9	2	110	160	80	160
3	34.00	81.60	8	2	130	160	90	150
4	37.4	93.20	7	0	140	160	80	150
5	30.80	85.00	8	1	130	150	80	140
6	16.20	72.00	9	2	120	160	90	160
7	37.20	78.40	8	2	110	150	90	160
8	24.40	85.00	8	1	120	150	80	140
9	37.40	86.80	7	0	130	160	60	150
10	47.20	81.60	6	2	120	160	100	140
11	35.60	81.40	8	3	110	140	90	140
Mean	32.87	82.10	7.8	1.6	121.80	154.40	80.00	148.18
SD	7.98	5.74	0.87	1.02	9.8	6.8	16.73	8.73

ASES = American Shoulder and Elbow Surgeons Shoulder; VAS = visual analogue scale; op = operative; FE = Forward Elevation; ER = External Rotation; Abd = Abduction.

obtained at the 2nd and 7th weeks and then at 3rd months post-operatively, in order to determine any muscle detachment with its bone fragment. After 3 months post-operatively, throughout all follow-ups, the patient's shoulder function was assessed using shoulder pain VAS and ASES score and active ROM in forward elevation and abduction was measured. Finally, the data were analyzed using SPSS software, V.19.

Results

In this study, 11 patients (3 females and 8 males) were operated following diagnosis with an injury of the spinal accessory nerve. The dominant limb was found in 4 (36%) patients. The most

common mechanism (9 of 11) of spinal accessory nerve injury among these patients was biopsy of the lymph node of the neck. The mean age of the patients was 41 years (range: 25 to 59). The mean follow-up period was 33.5 months (range: 24–48 months) (Table 1). The mean interval between the nerve injury and surgery was 10.18 months (range: 7–18 months). The mean pre-operative VAS score was 7, while it was 1.6 after surgery (p -value < 0.05). The baseline pre-operative mean ASES score was 32.8, which improved to mean ASES score of 82.1 at the final visit (p -value < 0.05). The mean preoperative range of motion in forward elevation and abduction were 121.80 and 80.00° and increased significantly to 154.40 and 148.18°, respectively (p -value < 0.05) (Table 2) (Fig. 3a–c).

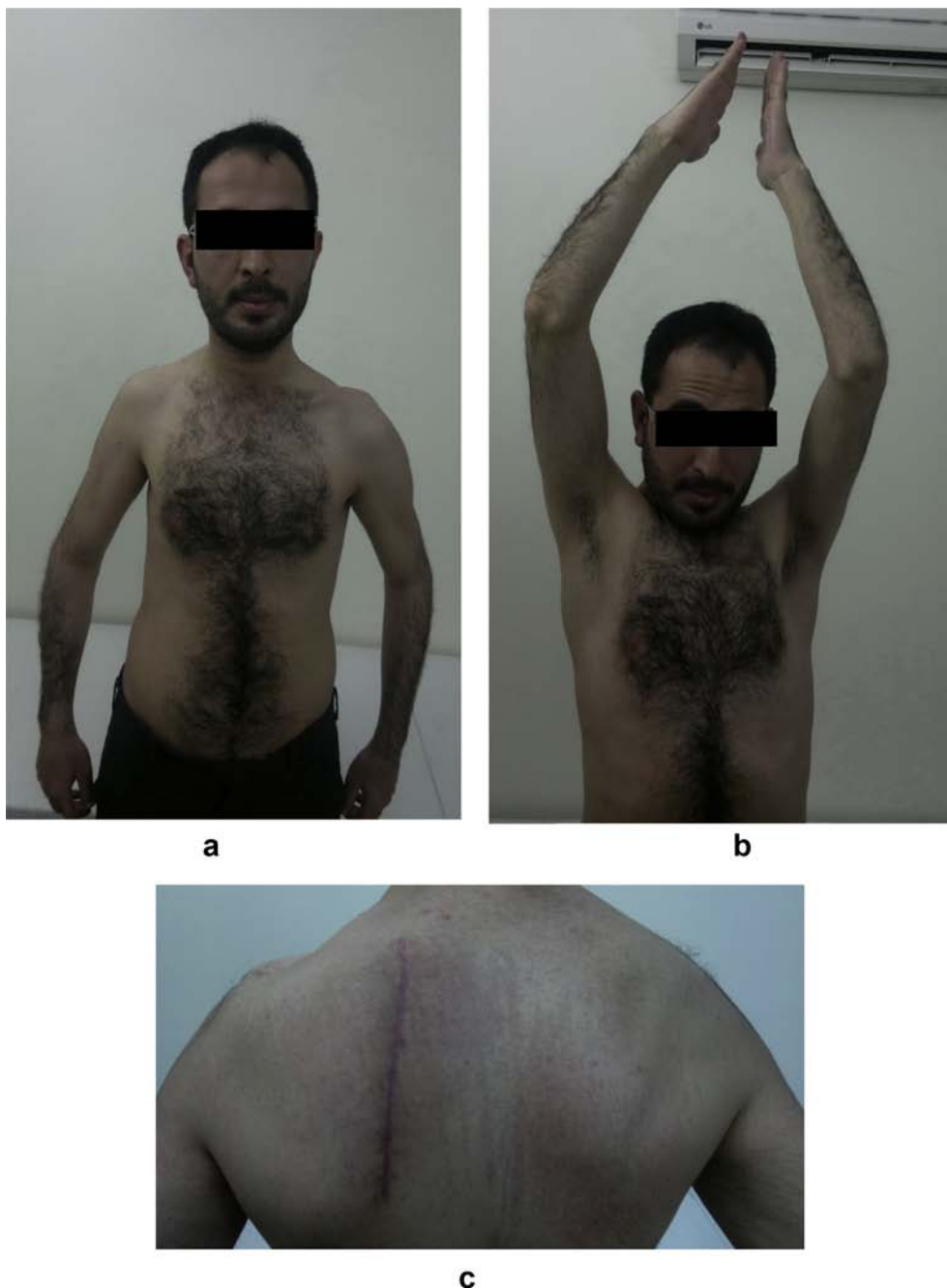

Fig. 3. (a) Improvement of neck- shoulder appearance, (b) shoulder ROM in abduction, (c) surgical scar 6 months after surgery in the patient presented in figure 1.

Discussion

By definition, scapular winging is a condition in which the medial border of the scapula is prominent.¹² Among the most common causes, paralysis of the serratus anterior and trapezius muscles are more important. According to clinical examination, in serratus anterior muscle paralysis, pain is more felt on the shoulder region and, scapular winging decreases in the resting position and increases in the forward elevation. However, in trapezius muscle paralysis, usually pain is in the posterior area of the sternocleidomastoid and scapular wingings increases during abduction.¹³ As reported by previous studies, spinal accessory nerve injury usually is seen due to neck surgery such as biopsy of the lymph node.^{14,15} In the present study, 80% of the spinal accessory nerve injury was caused by biopsy of the cervical lymph nodes. The Eden-Lange procedure, which is used for the treatment of trapezius muscle palsy, was first described in 1951 by Lange, and has been shown to be accompanied with good outcomes.^{16,17}

In a study by Romero et al (2003), 12 patients were operated due to paralysis of the trapezius muscle. In their study, the most common cause of spinal accessory nerve injury was biopsy of the cervical lymph nodes. Overall, 9 patients were satisfied with the surgery, and all patients returned to work. The mean constant score of the affected limb as compared with healthy limb was 73–83, postoperatively and had no significant difference.¹⁰

In a study by Galano et al,¹⁸ 6 patients were treated as a result of trapezius muscle paralysis using the modified Eden-Lange procedure. The mean ASES score was improved from 33.3 to 64.6, forward elevation from 141.7 to 151 and VAS score from 7 to 2.3. The mean follow-up period was 47 months, while in the present study it was 33.5 months. In 2004, Teboul et al published the results of their study on spinal accessory nerve injury. 20 patients were treated by nerve repair and 7 patients using the Lange method. The results were satisfactory in both groups. Finally, the nerve repair method was recommended for cases of nerve damage of less than 20 months.¹⁹

As reported by Elhassan et al, 22 patients were treated as a result of persistent trapezius paralysis due to spinal accessory nerve injury using an Eden-Lange variant procedure. After a mean follow-up of 35 months, all patients had significant improvement of pain ($p < 0.01$) and range of motion such as active shoulder abduction which improved from an average of 71° preoperatively to 118° postoperatively, and shoulder flexion from an average of 102°–150°. In addition, significant improvements occurred in aggregate Constant Shoulder Score, and Disabilities of the Arm, Shoulder and Hand score.²⁰ Ozalp T et al showed good result using the modified Eden-Lange procedure for paralysis of the trapezius muscle.²¹

In this study, after a mean follow-up period of 33.5 months, the mean range of motion in forward elevation and abduction improved significantly from 121.80 to 154.40 and from 80.00 to 148.18°, respectively. The mean VAS and total ASES scores improved significantly from 7.8 to 1.6 and from 32.8 to 82.1 points, respectively. The results of this study are similar to those of Elhassan et al except that the final ROM in active abduction in the present study is better (148.18° as compared with 118°).

Conclusion

The results of the Eden-Lange procedure with one incision in the treatment of the trapezius muscle palsy after 6 months of injury are acceptable. Therefore, appropriate technique and good post-operative care may play important roles in the treatment of the mentioned condition.

Financial support

None.

Conflicts of interest

No conflict of interest.

References

- Chan PK, Hems TE. Clinical signs of accessory nerve palsy. *J Trauma*. 2006;60(5):1142–1144.
- Lee S, Savin DD, Shah NR, Bronsnick D, Goldberg B. Scapular winging: evaluation and treatment: AAOS exhibit selection. *J Bone Jt Surg Am*. 2015;97(20):1708–1716.
- Meininger AK, Figuerres BF, Goldberg BA. Scapular winging: an update. *J Am Acad Orthop Surg*. 2011;19(8):453–462.
- Bigliani LU, Perez-Sanz JR, Wolfe IN. Treatment of trapezius paralysis. *J Bone Jt Surg Am*. 1985;67(6):871–877.
- Zeier FG. The treatment of winged-scapula. *Clin Orthop Relat Res*. 1973;91(1):128–133.
- Kaplan PE. Electrodiagnostic confirmation of long thoracic nerve palsy. *J Neurol Neurosurg Psychiatry*. 1980;43(1):50–52.
- Sanitate S, Jurist KA. Medial scapular winging in a patient with normal electromyograms. *Orthopedics*. 1995;18(3):292–293.
- Wiater JM, Bigliani LU. Spinal accessory nerve injury. *Clin Orthop Relat Res*. 1999;368(1):5–16.
- Kuhn JE, Plancher KD, Hawkins RJ. Scapular winging. *J Am Acad Orthop Surg*. 1995;3(6):319–325.
- Romero J, Gerber C. Levator scapulae and rhomboid transfer for paralysis of trapezius. *Bone Jt J*. 2003;85(8):1141–1145.
- Fiddian NJ, King RJ. The winged scapula. *Clin Orthop Relat Res*. 1984;185(1):228–236.
- Duralde XA. Evaluation and treatment of the winged scapula. *J South Orthop Assoc*. 1994;4(1):38–52.
- Olarte MA, Adams DA. Accessory nerve palsy. *J Neurol Neurosurg Psychiatry*. 1977;40(11):1113–1116.
- Norden A. Peripheral injuries to the spinal accessory nerve. *Acta Chir Scand*. 1946;94(6):515.
- Woodhall B. Trapezius paralysis following minor surgical procedures in the posterior cervical triangle. Results following cranial nerve suture. *Ann Surg*. 1952;136(3):375.
- Eden R. Zur Behandlung der Trapeziuslähmung mittelst Muskelplastik. *Deutsche Zeitschr Chir*. 1924;184(1):387–397.
- Lange M. Die Behandlung der irreparablen Trapeziuslähmung. *Langenbecks Arch Klin Chir*. 1951;270:437–439.
- Galano GJ, Bigliani LU, Ahmad CS, Levine WN. Surgical treatment of winged scapula. *Clin Orthop Relat Res*. 2008;466(3):652–660.
- Teboul F, Bizot P, Kakkar R, Sedel L. Surgical management of trapezius palsy. *J Bone Jt Surg Am*. 2004;86(9):1884–1890.
- Elhassan BT, Wagner ER. Outcome of triple-tendon transfer, an Eden-Lange variant, to reconstruct trapezius paralysis. *J Shoulder Elb Surg*. 2015;24(8):1307–1313.
- Ozalp T, Yercan H, Okcu G, Erkan S. The modified Eden-Lange procedure for paralysis of the trapezius muscle. *Acta Orthop Traumatol Turc*. 2004 Jul 23;41(2):159–162.