

Available online at [www.sciencedirect.com](http://www.sciencedirect.com)

ScienceDirect

journal homepage: [www.elsevier.com/locate/radcr](http://www.elsevier.com/locate/radcr)

## Case Report

# Supratentorial hemangioblastoma: A rare case report and literature review <sup>☆</sup>

Kai-Chieh Chang, MD<sup>a</sup>, Cheng-Ta Hsieh, MD, PhD<sup>a,b</sup>, Jing-Shan Huang, MD<sup>a,\*</sup>

<sup>a</sup> Division of Neurosurgery, Department of Surgery, Cathay General Hospital, Taipei City 106, Taiwan

<sup>b</sup> Department of Medicine, School of Medicine, Fu Jen Catholic University, New Taipei City 24205, Taiwan

## ARTICLE INFO

## Article history:

Received 30 March 2022

Revised 30 June 2022

Accepted 3 July 2022

## Keywords:

Hemangioblastoma

Supratentorial hemangioblastoma

Sporadic

## ABSTRACT

Hemangioblastomas are rare and benign tumors of the central nervous system. They account for 1.5%–2.5% of all intracranial tumors and have an incidence of 3.2%. The resemblance of hemangioblastomas to other tumors renders preoperative diagnosis and management challenging. Herein, we report a case of a supratentorial hemangioblastoma accompanied by extensive reactive gliosis and diagnosed through magnetic resonance imaging. In addition, we review the relevant literature.

© 2022 The Authors. Published by Elsevier Inc. on behalf of University of Washington.

This is an open access article under the CC BY-NC-ND license

(<http://creativecommons.org/licenses/by-nc-nd/4.0/>)

## Introduction

Hemangioblastomas (HBLs), which comprise blood vessels and neoplastic stromal cells, are rare and benign tumors of the central nervous system. These tumors are usually infratentorial and are seldom located in the supratentorial region of the brain. Hemangioblastomas were first described by von Hippel in 1895 and Bielschowsky in 1902 [1]. Their resemblance to other tumors impedes preoperative diagnosis and management. Herein, we report a rare case of a supratentorial hemangioblastoma accompanied by extensive reactive gliosis and diagnosed through magnetic resonance imaging (MRI). Further, we provide a review of the relevant literature.

## Case report

A 58-year-old woman presented with generalized seizures. The seizures were characterized by right-leg cramping episodes and the patient collapsing while conscious for 1–2 minutes and gazing upward. She denied experiencing vertigo, extremity numbness, weakness, nausea, and vomiting. She had no medical history of hypertension or renal disease and no family history of von Hippel-Lindau (VHL) syndrome. A neurological examination on admission revealed full consciousness without extremity weakness. No vision loss, visual defects, tinnitus, hematuria, or excessive sweating were noted. Laboratory examinations revealed a red blood

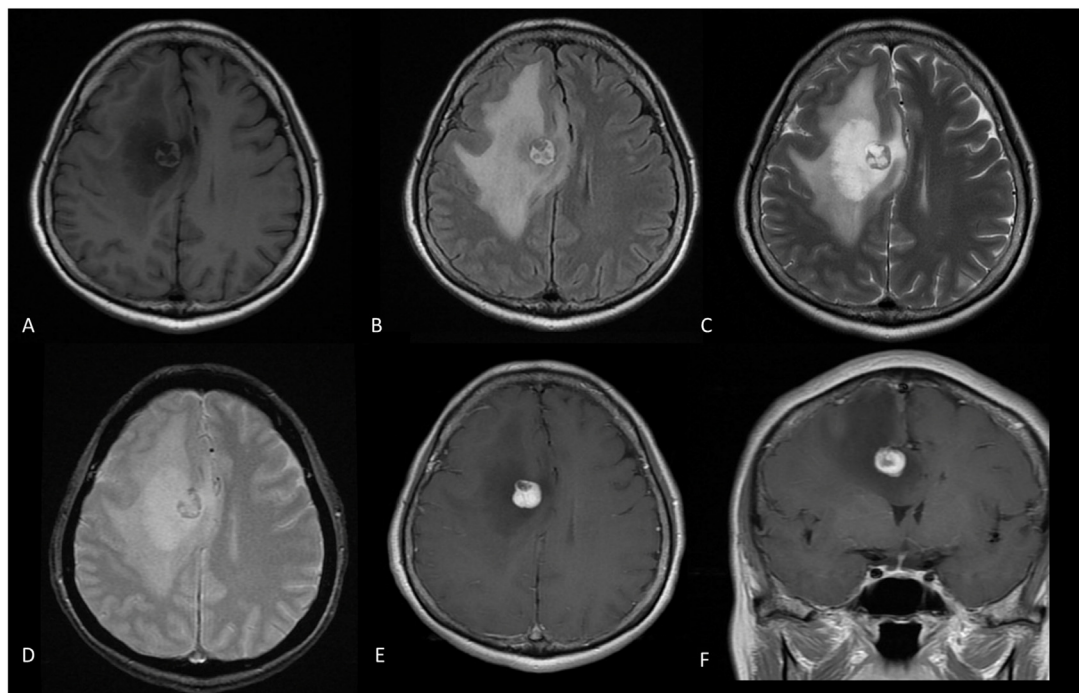
<sup>☆</sup> Competing Interests: All authors declare no conflict of interest.

\* Corresponding author.

E-mail address: [submission0318@gmail.com](mailto:submission0318@gmail.com) (J.-S. Huang).

<https://doi.org/10.1016/j.radcr.2022.07.014>

1930-0433/© 2022 The Authors. Published by Elsevier Inc. on behalf of University of Washington. This is an open access article under the CC BY-NC-ND license (<http://creativecommons.org/licenses/by-nc-nd/4.0/>)



**Fig. 1 – Preoperative MRI. (A) Axial T1-weighted, (B) (C) T2-weighted, and T2-weighted FLAIR (D) images; T2-weighted image after injection of gadolinium-based contrast medium shows slight hyperintensity near the heterogeneous nodule and peritumoral edema (E). (F) Axial and coronal T1-weighted images after the injection of the gadolinium-based contrast medium showing heterogeneous enhancement with prominent serpentine flow voids.**

cell count of  $4.31 \times 10^6/\mu\text{L}$ , hemoglobin level of 13.3 g/dL, and hematocrit level of 38.7%. Thus, the major criteria for polycythemia were not met.

Brain computed tomography (CT) revealed an enhanced nodule with a diameter of 1.4 cm in the right frontal lobe, along with perifocal edema. Brain FLAIR MRI revealed a mass with a slightly hyperintense mural component along with marked perifocal edematous change and a leftward midline shift. After the administration of gadolinium-based contrast medium, the nodule became hyperintense and heterogeneous on T1-weighted images, and the cystic area was hyperintense on T2-weighted images (Fig. 1). The corresponding enhancement was intense and suggestive of a highly vascularized lesion.

Digital subtraction angiography (DSA) revealed tightly packed and wide vessels fed by branches of the right-anterior cerebral artery and a dilated draining vein (Fig. 2). The preoperative differential diagnoses included HBL with an advanced astroglial response, angioglioma (highly vascular anomaly, arteriovenous malformation [AVM], and glioma), brain metastasis, lymphoma, and glioblastoma multiforme.

She underwent craniotomy with the bicoronal approach for the removal of the target mass. During the operation, the mass appeared pink and had soft contents. Hypervascularity was also observed. The mass was removed en bloc through microscopic techniques. A pathological examination revealed a highly vascular lesion with prominent capillary channels and stromal cells. CD34 staining highlighted the vascular network. Furthermore, reticulin and inhibin stains circumscribed

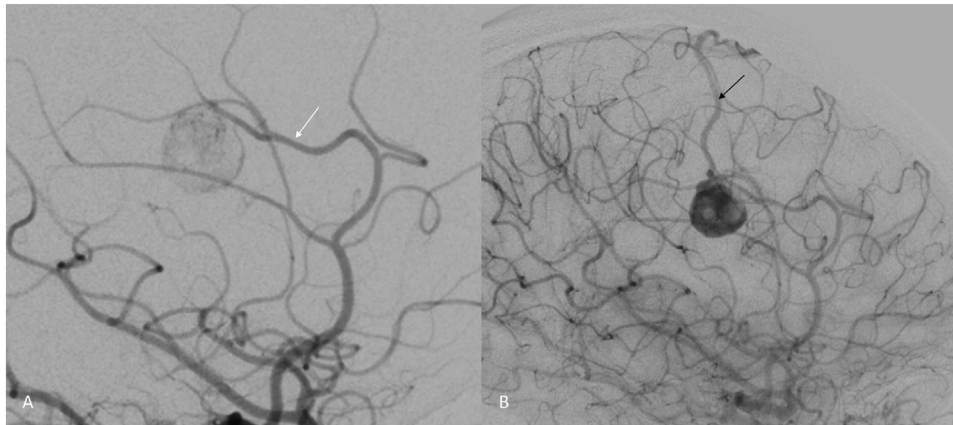
the stromal cells, and the tumor was negative for cytokeratin AE1/AE3 and glial fibrillary acidic protein (GFAP). Thus, the tumor was finally diagnosed as a reticular HBL variant (Fig. 3).

The postoperative course was uneventful. The patient had full muscle power, and no seizure episodes were noted. Postoperative MRI at 6 and 12 months (Fig. 4) showed no tumor recurrence.

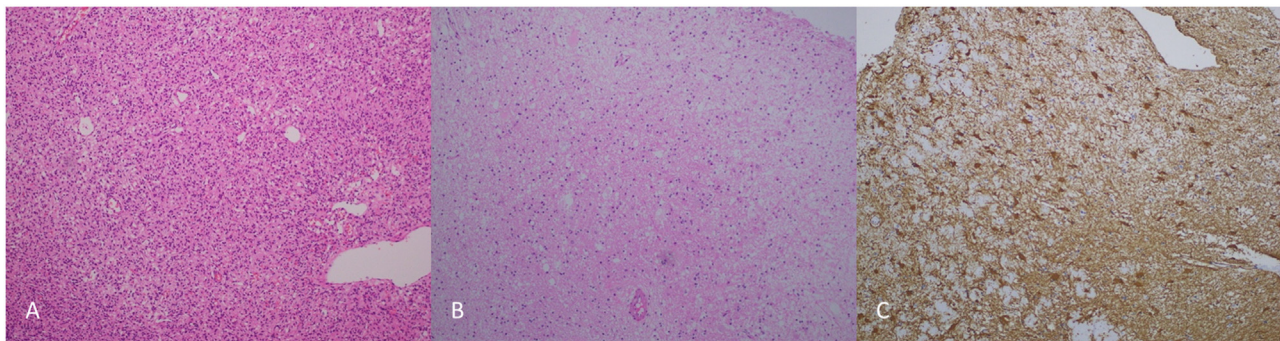
## Discussion

HBLs account for 1.5%-2.5% of all intracranial tumors and 7%-12% of all posterior fossa tumors [2]. In addition, HBLs are usually infratentorial, with most occurring in the cerebellum (76%). The incidence of supratentorial and spinal cord HBL is 3.2% and 13%-44%, respectively. Sporadic and nonfamilial cases account for approximately two-thirds of all HBL cases but only 40% of all supratentorial HBL cases [2]. The average age of patients with supratentorial HBL is approximately 36 years, men account for the majority of cases (at a ratio of 1.3:1) [2,3]. Supratentorial HBLs are most commonly located in the frontal lobe, followed by the parietal and temporal lobes [2,3].

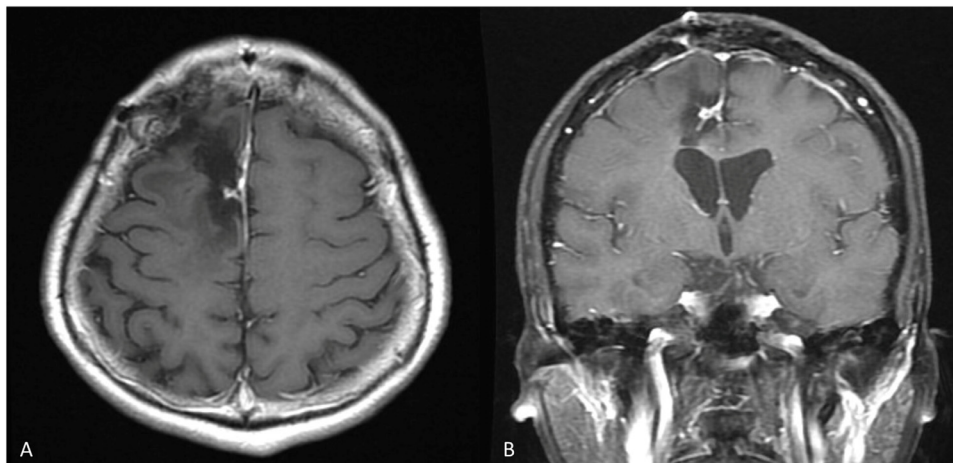
The clinical symptoms of supratentorial HBLs are related to the location and growth pattern of the lesions. HBLs are benign; consequently, symptoms may appear late. The mass effect (tumor growth), cyst formation, and peritumoral edema on the surrounding structures contribute to the symptoms. HBLs manifest suddenly with the onset of neurological symp-



**Fig. 2 – DSA showing tightly packed wide vessels fed by branches of the right-anterior cerebral artery (white arrow) and a dilated draining vein (black arrow).**



**Fig. 3 – Pathological hematoxylin and eosin staining. Highly vascular lesion with prominent thin-walled vessels and stromal cells. Absence of glioma. Mild-to-moderate gliosis.**



**Fig. 4 – Postoperative MRI showing no tumor recurrence at 6 months.**

toms and demand neurosurgical intervention [4]. Clinical symptoms include seizures, intracranial hypertension, neurological deficit, and, in rare cases, hemorrhage [1].

Histologically, HBLs are highly vascular and benign and comprise stromal cells and vessels. The vascular component

consists of small capillaries with a single layer of plump and uniform endothelial cells. The cellular component is characterized by large and vacuolated stromal cells [5]. On the basis of the relative abundance of the stromal cells, HBLs can be subdivided into 2 variants: the cellular variant, in which stro-

mal cells predominate, and the reticular variant, in which the vascular component predominates. The cellular HBL variant is associated with a high likelihood of GFAP positivity (80% vs 7%), a high Ki67 (MIB-1) proliferation index (4% vs <1%), and a high probability of recurrence (25% vs 8%) [6]. Because of the resemblance of HBLs to gliomas, Roussy and Oberling proposed the concept of angioglioma [6]. In addition, the GFAP immunoreactivity common with the cellular variant may lead to misdiagnosis as glioma.

CT or gadolinium-enhanced MRI can be used for impression, and a definitive diagnosis can be achieved through histopathological examination [4]. MRI is often used to distinguish brain tumors from non-neoplastic lesions and to divide them into low-grade and high-grade tumors. Advanced MRI can provide independent and complementary prognostic information, which can affect surgical decisions and other crucial aspects of patient care. In radiographs, HBLs are spherical and well defined, and the cystic component is usually hypodense on CT scans. On contrast-enhanced T1-weighted MRI, the most common finding is a considerably enhanced mural nodule with an adjacent unenhanced smooth cyst. Such cysts appear hyperintense on T2-weighted images [7]. However, less cyst formation occurs in the supratentorial region than in the posterior fossa, and small tumors in the region have larger areas of edema because the cerebrum provides more volume for edema diffusion than the cerebellum provides [8]. Edema is considered to be the result of the diffusion of plasma ultrafiltrate from the tumor interstitial space to the surrounding brain tissue, whose absorptive capacity is exceeded [8]. The difference in the prevalence of cystic lesions between VHL and sporadic cases is not significant. HBLs are highly vascular tumors located in avascular cysts, and they are directly supplied by the vessels that originate from the dural arteries. Flow voids are visible on T2-weighted images in 60%-70% of cases [7]. Angiography of HBLs usually shows enlarged feeding arteries and often reveals dilated draining veins along with a dense tumor blush in the center [9]. The characteristic tightly packed wide vessels possess a nodule resembling a “cherry attached to its stalk” in the early arterial phase [7]. An HBL without a cyst can be easily misdiagnosed as an AVM. When both MRI and angiography are available, a certain diagnosis can usually be made before surgery.

VHL syndrome is a multisystem familial cancer syndrome involving the variation and deletion of the VHL gene, which is located on chromosome 3p25. It is autosomal dominant, with a penetrance rate of approximately 90% by the age of 60 years [10]. It is related to retinal HBLs, pheochromocytoma, renal cell and pancreatic carcinoma, and other unusual tumors, including abdominal organ cysts [1].

We know of 162 reported cases of supratentorial HBL, only 68 of which were supratentorial HBLs without VHL syndrome, including cases with multiple lesions. Specifically, Pandey et al. described 59 cases of supratentorial HBL without VHL syndrome. Nine additional cases of sporadic HBL were discovered in a search of PubMed, Google Scholar, and Cochrane Library for English-language articles published after 2017 [1,11–13].

Reviewing the relevant literature shows that supratentorial HBL unaccompanied by gliosis on MRI is rare. In our case, the slight regional T2 hyperintensity near the heterogeneous

nodule was unlikely to indicate vasogenic edema, and gliotic change was suspected. Because of the flow voids on the T1-weighted images, the initial impression was a highly vascular lesion such as an HBL or angioglioma [14]; therefore, DSA was performed to aid in differential diagnosis. Colon or ovarian cancer with brain metastasis and tumor hemorrhage as well as central nervous system (CNS) lymphoma could not be ruled out.

Primary CNS tumors may cause reactive gliosis and multicellular responses. Burda et al. described 3 overlapping phases of CNS responses to focal damage [15]. The interaction of tumor cells with glia and infiltrating inflammatory cells is complicated and depends strongly on tumor cell type. Noninvasive tumors are accompanied by reactive gliosis in their surroundings and encapsulating scars similar to those observed around traumatic tissue injuries. Matyja et al. [14] reported 28 cases of HBL, out of which the cyst wall or surrounding brain tissue of 15 tumors was available. Furthermore, pathological staining of neighboring brain tissue usually shows diffuse and massive gliosis.

---

## Surgical intervention

For symptomatic cases, surgical resection is the first-line treatment. Through surgical resection, tumors with peritumoral edema can be removed to thereby resolve symptoms immediately [13]. The surgical technique for treating HBLs is similar to that for treating AVM. Complete removal of the tumor is crucial; therefore, extremely dilated veins must be drained at the latest possible moment. The operation involves distinguishing the blood-supply arteries first and ligating the draining veins last. The blood supply to the tumor should be interrupted before resection, and complete resection should be performed after dissection of the peripheral tumor tissue (avoiding intratumoral resection). Finally, the draining veins should be ligated. Because internal decompression may cause uncontrollable bleeding, en bloc resection is performed, even in the case of large tumors. At the end of the operation, any bleeding is stopped through careful coagulation [13,16]. Mill et al. reported that gross total resection provided superior progression-free survival to that provided by subtotal resection (100% vs 53%, respectively) [4]. Avoiding bleeding during the procedure is challenging; therefore, endovascular embolization before surgery can facilitate the removal of tumor lesions. Preoperative embolization after consideration of the size, location, and vascularization of HBLs is a safe, effective, and reliable adjuvant treatment for the complete surgical resection of tumors [17,18].

Radiotherapy is limited to cases involving multiple lesions, deep tumors, subtotal resection, recurrence, or postoperative hemorrhage. The reported tumor-control rates range from 26% to 80% [1]. Furthermore, the 5-year progression-free survival rate for fractionated radiotherapy for all CNS HBLs (combined primary treatment modality and adjuvant therapy) ranges from 33% to 90.5% [4]. Gamma Knife radiosurgery is an alternative modality. The overall local control rates following stereotactic radiosurgery are 94% and 80% at 5 and 10 years, respectively [19].

The most frequently reported recurrence rate after surgical resection is approximately 25% [1]. Suzanne and Horowitz reported that young age (<30 y) at first diagnosis, VHL syndrome, and multicentric tumors with a solid gross histological structure and no stromal cells are correlated with symptomatic tumor regrowth. Sporadic lesions are more likely to be cured after initial total resection [2,20]. Studies have recommended high clinical suspicion and postoperative MRI follow-up for long-term surveillance. Asymptomatic tumors must undergo serial imaging at regular intervals (6–12 months), depending on the tumor size, presence of associated cysts, and volume and number of related HBLs in the same anatomical region [21].

## Conclusion

Supratentorial HBLs are rare. They are usually located in the frontal lobe and discovered to be sporadic when isolated. We present a case of unique supratentorial HBL surrounded by gliosis with a superficial resemblance to glioma. Massive reactive gliosis on pathological stains is rare in reticular HBL. This case reflects the importance of preoperative diagnostics with both MRI and angiography for this pathology. Our review of the literature can enable superior therapeutic planning to facilitate treatment and improve patient outcomes.

## Patient consent

The patient has consented to the publication of the case report.

## REFERENCES

- [1] Rocha L, Noronha C, Taipa R, Reis J, Gomes M, Carvalho E. Supratentorial hemangioblastomas in von Hippel-Lindau wild-type patients—case series and literature review. *Int J Neurosci* 2018;128(3):295–303.
- [2] Pandey S, Sharma V, Pandey D, Kumar V, Kumar M. Supratentorial haemangioblastoma without von Hippel-Lindau syndrome in an adult: a rare tumor with review of literature. *Asian J Neurosurg* 2016;11(1):8–14.
- [3] Yang B, Luan S, Cao X, Bao W. Supratentorial hemangioblastoma. *Neurosciences (Riyadh)* 2011;16(2):150–2.
- [4] Mills SA, Oh MC, Rutkowski MJ, Sughrue ME, Barani IJ, Parsa AT. Supratentorial hemangioblastoma: clinical features, prognosis, and predictive value of location for von Hippel-Lindau disease. *Neurol Oncol* 2012;14(8):1097–104.
- [5] Murali R, Jones WI, Ma Wyatt J. A 57-year-old man with a dural-based parietal lobe tumor. *Brain Pathol* 2007;17(4):460–3 474.
- [6] Hasselblatt M, Jeibmann A, Gerss J, Behrens C, Rama B, Wassmann H, et al. Cellular and reticular variants of haemangioblastoma revisited: a clinicopathologic study of 88 cases. *Neuropathol Appl Neurobiol* 2005;31(6):618–22.
- [7] Rumboldt Z, Castillo M, Huang B, Rossi A. *Brain imaging with MRI and CT: an image pattern approach*. Cambridge University Press; 2012.
- [8] Peyre M, David P, Van Effenterre R, François P, Thys M, Emery E, et al. Natural history of supratentorial hemangioblastomas in von Hippel-Lindau disease. *Neurosurgery* 2010;67(3):577–87 discussion 587.
- [9] Ho VB, Smirniotopoulos JG, Murphy FM, Rushing EJ. Radiologic-pathologic correlation: hemangioblastoma. *AJNR Am J Neuroradiol* 1992;13:1343–52.
- [10] Maher ER, Iselius L, Yates JR, Littler M, Benjamin C, Harris R, et al. Von Hippel-Lindau disease: a genetic study. *J Med Genet* 1991;28(7):443–7.
- [11] Junior JCR, da Silva VEB, Vital RB, Kumar V, Kumar M. Supratentorial hemangioblastomas without von-Hippel Lindau disease—case report and review. *Int J Neurosurg* 2021;5(1):1.
- [12] Qu L, Lv C, Ji T, Wang Y, Yu J. Cerebral hemangioblastoma without von Hippel-Lindau syndrome: a report of 6 cases. *Int J Surg Pathol* 2021;29(2):129–34.
- [13] Klingler JH, Glasker S, Bausch B, Urbach H, Krauss T, Jilg CA, et al. Hemangioblastoma and von Hippel-Lindau disease: genetic background, spectrum of disease, and neurosurgical treatment. *Childs Nerv Syst* 2020;36(10):2537–52.
- [14] Matyja E, Grajkowska W, Taraszewska A, Marchel A, Bojarski P, Nauman P. Advanced reactive astroglia associated with hemangioblastoma versus astroglial-vascular neoplasm ("angioglioma"). *Folia Neuropathol* 2007;45(3):120–5.
- [15] Burda JE, Sofroniew MV. Reactive gliosis and the multicellular response to CNS damage and disease. *Neuron* 2014;81(2):229–48.
- [16] Cui H, Zou J, Bao YH, Wang MS, Wang Y. Surgical treatment of solid hemangioblastomas of the posterior fossa: a report of 28 cases. *Oncol Lett* 2017;13(3):1125–30.
- [17] Takeuchi S, Tanaka R, Fujii Y, Abe H, Ito Y. Surgical treatment of hemangioblastomas with presurgical endovascular embolization. *Neurol Med Chir (Tokyo)* 2001;41(5):246–51 discussion 251–242.
- [18] Liu X, Zhang Y, Hui X, You C, Yuan F, Chen W, et al. Surgical management of medulla oblongata hemangioblastomas in one institution: an analysis of 62 cases. *Int J Clin Exp Med* 2015;8(4):5576–90.
- [19] Hanakita S, Koga T, Shin M, Takayanagi S, Mukasa A, Tago M, et al. The long-term outcomes of radiosurgery for intracranial hemangioblastomas. *Neurol Oncol* 2014;16(3):429–33.
- [20] de la Monte SM, Horowitz SA. Hemangioblastomas: clinical and histopathological factors correlated with recurrence. *Neurosurgery* 1989;25(5):695–8.
- [21] Ammerman JM, Lonser RR, Dambrosia J, Butman JA, Oldfield EH. Long-term natural history of hemangioblastomas in patients with von Hippel-Lindau disease: implications for treatment. *J Neurosurg* 2006;105(2):248–55.