

# Arterial embolization of metal-on-metal hip arthroplasty-related pseudotumor material causing acute limb ischemia

Eleanor Atkins, BMedSci, BMBS, MRCS,<sup>a</sup> Rob Wallace, MBBS, MRCS, FRACS,<sup>b</sup>

Luke Johnson, BMBS, BSc, FRACS, FAOrthA,<sup>a</sup> and Phillip Puckridge, MBBS, FRACS,<sup>a</sup> Adelaide, South Australia, Australia

## ABSTRACT

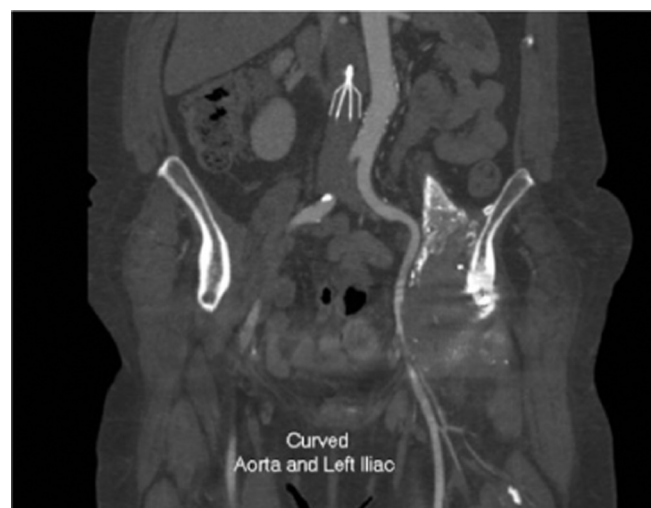We have described a complication of a pseudotumor secondary to metal-on-metal hip arthroplasty. The patient experienced acute limb ischemia after pseudotumor material had invaded and stenosed the external iliac artery and embolized distally. Multiple vascular surgery procedures were performed to revascularize the limb. The present report highlights the importance of involving vascular surgeons early in a limb-threatening presentation of a pseudotumor to achieve limb salvage. (*J Vasc Surg Cases and Innovative Techniques* 2021;7:399-402.)

**Keywords:** Acute limb ischemia; Arterial embolus; Limb salvage; Metal-on-metal joint prosthesis; Vascular surgical procedures

Metal-on-metal hip arthroplasty was introduced in the 1990s. Adverse reactions to metal debris, commonly known as pseudotumors, have been reported in the literature with various associated complications. We have presented a case of acute limb ischemia after formation of a pseudotumor secondary to metal-on-metal hip arthroplasty eroding into the external iliac artery and embolizing into the distal vessels and described the vascular surgical management. The patient provided written informed consent for the report of her case and imaging studies.

## CASE REPORT

A 62-year-old woman had presented to our unit in January 2020 with a 24-hour history of left calf pain. She had a background of asthma, hysterectomy (2006), gastroesophageal reflux disease, active smoking, and a left-sided metal-on-metal hip replacement using the Magnum modular system (Biomet Orthopaedics, Warsaw, Ind) in 2007. The hip replacement had been revised in 2008 after she had presented with a collection in the left iliac fossa. A firm, lobulated periarticular mass was found at operation. A further revision was performed in 2015 for recurrent dislocation and another in 2018 for acetabular



**Fig 1.** Attenuation of contrast in the left external iliac artery next to the calcified periarticular mass.

loosening to a custom three-dimensionally printed triflanged prosthesis (Ossis Ltd, Christchurch, New Zealand).

At all three revisions, tissue from the mass was sent for histologic examination, and chronic nonspecific inflammation was seen, with metallosis pigment found on a review of the samples. She had developed left-sided postoperative deep vein thrombosis in 2008 and also in 2016 after a skin graft to her left leg for a dog bite. She was taking rivaroxaban as a consequence of this. Her leg was chronically swollen, and left external iliac vein compression had been identified as secondary to the pseudotumor in the past. This had been managed conservatively.

At her initial presentation, her chronic left hip pain and left lower limb swelling was unchanged. No deep vein thrombosis was seen on the bedside ultrasound examination. The inflammatory markers were normal, and creatine kinase was elevated at 1407 U/L. Her left foot was colder than her right foot, with no

From the Department of Vascular Surgery, Flinders Medical Centre<sup>a</sup>; and the Department of Orthopaedic Surgery, Sportsmed South Australia.<sup>b</sup>

Author conflict of interest: none.

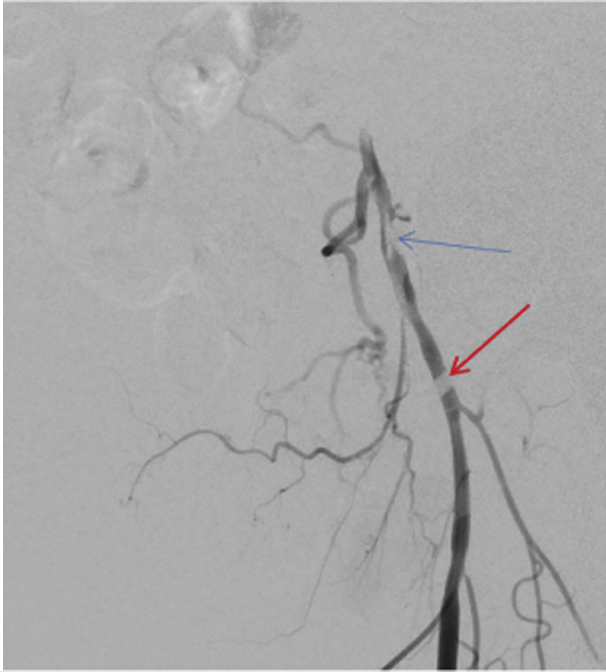Correspondence: Eleanor Atkins, BMedSci, BMBS, MRCS, Department of Vascular Surgery, Flinders Medical Centre, Adelaide, SA 5042 5000, Australia (e-mail: [eleanor.atkins@nhs.net](mailto:eleanor.atkins@nhs.net)).

The editors and reviewers of this article have no relevant financial relationships to disclose per the Journal policy that requires reviewers to decline review of any manuscript for which they may have a conflict of interest.

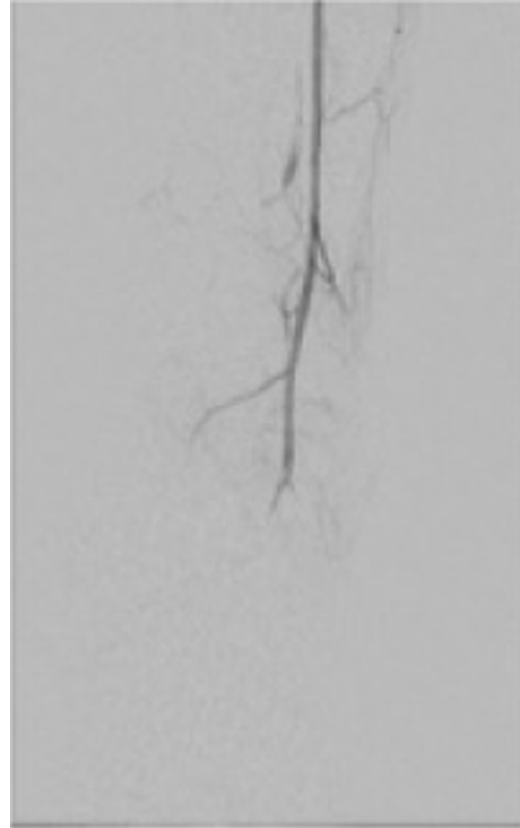
2468-4287

© 2021 The Authors. Published by Elsevier Inc. on behalf of Society for Vascular Surgery. This is an open access article under the CC BY-NC-ND license (<http://creativecommons.org/licenses/by-nc-nd/4.0/>).

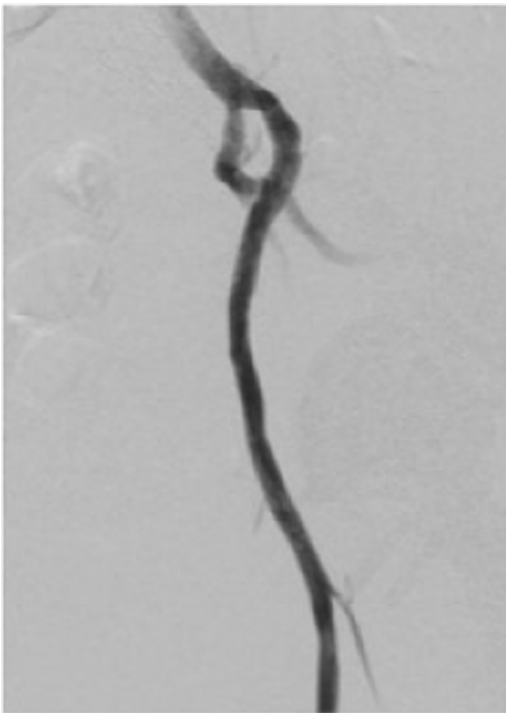
<https://doi.org/10.1016/j.jvscit.2021.04.009>



**Fig 2.** Left external iliac artery stenosis secondary to compression and invasion of pseudotumor (*blue arrow*) with thrombotic material inside the artery and artifact (*red arrow*) representing an acetabular screw.



**Fig 4.** Filling defects in the left dorsalis pedis artery with minimal flow into the foot.

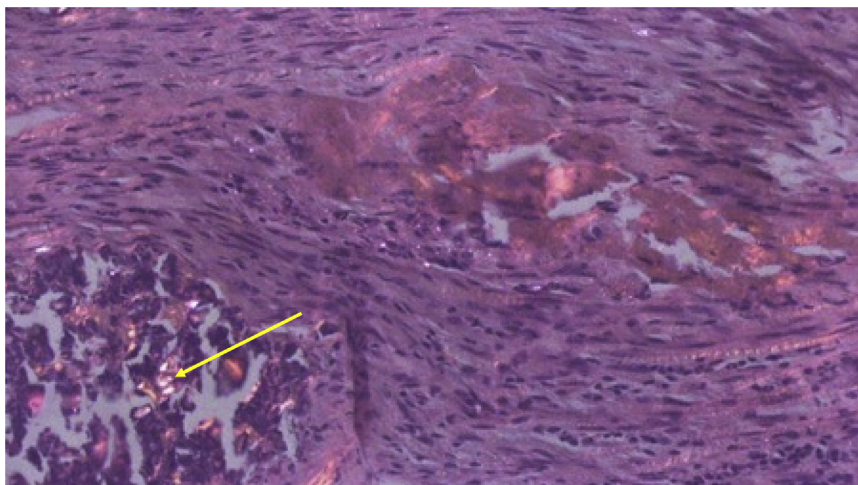


**Fig 3.** Good post-stenting appearance of the left external iliac artery.

angiography was performed, which demonstrated a calcific periarticular mass around the left hip. Attenuation of contrast in the left external iliac artery in its course over the hip joint was seen (Fig 1), giving the impression of progressive external compression of the artery compared with previous imaging findings. Single-vessel arterial runoff to the ankle was confirmed via the anterior tibial artery, but poor filling was noted in the dorsalis pedis artery. She was diagnosed with acute limb ischemia (Rutherford class IIb) and taken to the angiographic suite emergently. Ultrasound guidance was used to secure retrograde access to the left common femoral artery.

Her left external iliac artery stenosis (Fig 2) was crossed and stented with a  $7 \times 100$ -mm Viabahn stent (W.L. Gore and Associates, Inc, Flagstaff, Ariz) to treat the compression and trap thrombotic material along the EIA with a covered stent. A  $6.5 \times 100$ -mm Supera stent (Abbott Vascular, Inc, Santa Clara, Calif) was deployed within the covered stent to assist with crush resistance (Fig 3). Good flow to ankle was seen after stenting; however, filling defects representing distal embolus were seen in the dorsalis pedis artery (Fig 4). Similar findings from the preoperative computed tomography angiography suggested that the embolization to the dorsalis pedis artery had occurred before the intervention. Intra-arterial glyceryl trinitrate and urokinase were given but with minimal effects. Retrograde access was obtained to the right common femoral artery, and suction embolectomy was attempted via the up-and-over route without success.

palpable left-sided foot pulses. Tenderness was present in the anterior compartment of the lower limb. She was referred to the vascular surgery team and computed tomography



**Fig 5.** Intra-articular foreign material viewed using polarized light. Organizing granulation tissue containing blood vessels, fibroblasts, and metallic particles shown as bright specks (yellow arrow).

After the procedure, reperfusion compartment syndrome was clinically evident, and she was transferred to a main operating room for four compartment fasciotomy. She was taken to the intensive treatment unit after the procedure with a palpable anterior tibial pulse and intravenous iloprost and heparin were started.

The next day, the left forefoot remained poorly perfused, with dusky toes and sluggish capillary refill. Also, the patient was in significant pain. We decided to return the patient to the operating room for anterior tibial thrombectomy via a dorsalis pedis cutdown. Intra-arterial foreign material was retrieved and sent for analysis. Histologic examination demonstrated a cord of loose fibrous connective tissue containing numerous particles of polarizable foreign material, which was identified as metallic in nature (Fig 5).

Her foot improved rapidly, and she continued to recover well until her discharge 17 days after admission. She completed 5 days of iloprost, and rivaroxaban was restarted. Her fasciotomy wounds were treated with negative pressure dressings and grafted using the CelluTome Epidermal Harvesting System (KCI, San Antonio, Tex). However, she continued to smoke. On review in the clinic at 2 weeks after discharge, her wounds were healing nicely and the foot was well perfused with a palpable dorsalis pedis pulse.

The patient had undergone surveillance ultrasound scans at 6 weeks, 3 months, and 6 months. At 6 months, a high-grade stenosis was identified within the external iliac artery stent. The patient was not symptomatic. On multiplanar angiographic imaging, it appeared that a flange of the acetabular component of the hip prosthesis was externally compressing the stent. Further angioplasty of the stent was performed with a good postprocedure appearance. Ultrasound surveillance 6 weeks after angioplasty showed a patent arterial stent with no restenosis.

## DISCUSSION

Metal-on-metal hip arthroplasty was introduced in the 1990s. It was mainly used in younger patients with the

understanding that the wear would be less with a hard-on-hard bearing, the large head would reduce dislocations, and, in the case of resurfacing arthroplasty, more bone in the femoral neck would be retained for any subsequent revision surgery.<sup>1,2</sup> Subsequently, a high incidence of periarticular, noninfective, cystic or solid masses was described in these patients, with the masses collectively referred to as “pseudotumors” by Pandit et al.<sup>3</sup> A prospective cohort study identified a prevalence of pseudotumor of 39% on follow-up computed tomography scans at a mean of 3.6 years,<sup>4</sup> much higher than previously thought. The cause of the mass is an immunologically delayed hypersensitivity reaction to metal particles. A lymphocyte-dominated histologic pattern will usually be seen, and the term “aseptic lymphocytic vasculitis-associated lesion” has been used to describe the histologic findings.<sup>5</sup> Metal-on-metal hip arthroplasties are consequently seldom used in the modern era.

The complications associated with pseudotumors related to metal-on-metal hip arthroplasty in the literature include pain, venous compression leading to deep vein thrombosis,<sup>6</sup> ureteric obstruction,<sup>7</sup> and femoral nerve palsy.<sup>8</sup> To the best of our knowledge, the present case report is the first to describe a pseudotumor invading an arterial structure and leading to distal embolization.

Pseudotumors can become symptomatic up to 15 years after metal-on-metal hip arthroplasty.<sup>9</sup> Both vascular and orthopedic surgeons should be aware of the potential complications, including intra-arterial embolus and acute limb ischemia. Vascular surgeons should be aware of any orthopedic procedures on the affected leg when assessing patients and should be especially aware of the female preponderance for complications from metal-on-metal arthroplasty.<sup>10</sup> Sending any embolized material for histologic examination should be routine. Multidisciplinary teams should be standard in patients’

ongoing care. We would suggest a low threshold for open surgical thrombectomy rather than thrombolysis for these cases.

## CONCLUSIONS

The present case report has described a complication of a pseudotumor secondary to metal-on-metal hip arthroplasty. We have highlighted the importance of involving vascular surgeons early in a limb-threatening presentation of pseudotumor to achieve limb salvage.

## REFERENCES

1. Girard J, Bocquet D, Autissier G, Foulleron N, Fron D, Migaud H. Metal-on-metal hip arthroplasty in patients thirty years of age or younger. *J Bone Joint Surg Am* 2010;92:2419-26.
2. Isaac GH, Thompson J, Williams S, Fisher J. Metal-on-metal bearings surfaces: materials, manufacture, design, optimization, and alternatives. *Proc Inst Mech Eng H* 2006;220:119-33.
3. Pandit H, Glyn-Jones S, McLardy-Smith P, Gundle R, Whitwell D, Gibbons CLM, et al. Pseudotumours associated with metal-on-metal hip resurfacings. *J Bone Joint Surg Br* 2008;90:847.
4. Bosker BH, Ettema HB, Boomsma MF, Kollen BJ, Maas M, Verheyen CCPM. High incidence of pseudotumour formation after large-diameter metal-on-metal total hip replacement: a prospective cohort study. *J Bone Joint Surg Br* 2012;94:55-61.
5. Langton DJ, Joyce TJ, Jameson SS, Lord J, Van Orsouw M, Holland JP, et al. Adverse reaction to metal debris following hip resurfacing: the influence of component type, orientation and volumetric wear. *J Bone Joint Surg Br* 2011;93:164-71.
6. Parfitt DJ, Wood SN, Chick CM, Lewis P, Rashid MH, Evans AR. Common femoral vein thrombosis caused by a metal-on-metal hip arthroplasty-related pseudotumor. *J Arthroplasty* 2012;27:1581.e9-11.
7. Hananouchi T, Saito M, Nakamura N, Yamamoto T, Yonenobu K. Huge pelvic mass secondary to wear debris causing ureteral obstruction. *J Arthroplasty* 2005;20:946-9.
8. Clayton RA, Beggs I, Salter DM, Grant MH, Patton JT, Porter DE. Inflammatory pseudotumor associated with femoral nerve palsy following metal-on-metal resurfacing of the hip: a case report. *J Bone Joint Surg Am* 2008;90:1988-93.
9. Griffiths HJ, Burke J, Bonfiglio TA. Granulomatous pseudotumors in total joint replacement. *Skeletal Radiol* 1987;16:146-52.
10. Latteier MJ, Berend KR, Lombardi AV Jr, Ajluni AF, Seng BE, Adams JB. Gender is a significant factor for failure of metal-on-metal total hip arthroplasty. *J Arthroplasty* 2011;26(Suppl):19-23.

Submitted Nov 21, 2020; accepted Apr 19, 2021.