



Cardiac Arrest during Temporary Clipping for Ruptured Internal Carotid Artery Aneurysm: A Case Report

Toshihiko Shimizu¹ Hiroshi Kosaka¹ Yuji Yamamoto¹

¹ Department of Neurosurgery, Matsuyama Shimin Hospital, Matsuyama-city, Ehime, Japan

Asian J Neurosurg 2024;19:787–790.

Address for correspondence Toshihiko Shimizu, MD, PhD, Department of Neurosurgery, Matsuyama Shimin Hospital, 2-6-5 Otemachi, Matsuyama-city, Ehime 790-0067, Japan (e-mail: toshihiko.ss2001@gmail.com).

Abstract

Mechanical stimulation of the trigeminal nerve during craniofacial, skull base, or dental surgeries may cause bradycardia, hypotension, or cardiac arrest. This phenomenon is called trigeminal cardiac reflex (TCR). We encountered a rare case of a patient who experienced sinus arrest due to temporary clipping of the intracranial carotid artery during the clipping of a ruptured aneurysm. We discuss possible reasons for the occurrence of TCR in this case. A man in his 30s with no medical history presented with a sudden-onset headache. Computed tomography revealed a subarachnoid hemorrhage in the basal cistern and left Sylvian fissure. Angiography revealed a saccular aneurysm of the left internal carotid-anterior choroidal artery. A left frontotemporal craniotomy and dural incision were performed, followed by a trans-Sylvian approach. Cardiac arrest occurred twice during the temporary clipping of the intracranial carotid artery. After surgery, we performed a cardiac ultrasound echo and a 1-week Holter electrocardiogram. Neither showed abnormalities. No arrhythmia or cardiac events were observed over a one and half-year follow-up period. The cardiac arrest might have been triggered by the stimulation of the trigeminal nerve in the internal carotid artery. The repeated and anatomical features of this case suggest that TCR triggered cardiac arrest. The high probability that cardiac arrest was induced by trigeminal nerve stimulation should be considered during the temporary clipping of the internal carotid artery. However, the predisposing factors and exact underlying mechanisms for these arrhythmias remain unknown and require further investigation.

Keywords

- ▶ trigeminal cardiac reflex
- ▶ subarachnoid hemorrhage
- ▶ temporary clipping
- ▶ aneurysmal clipping
- ▶ sinus arrest

Case Report

A man in his 30s with no medical history presented with a sudden-onset headache. Computed tomography revealed a subarachnoid hemorrhage (SAH) in the basal cistern and left Sylvian fissure. The patient was then referred to our hospital.

Angiography revealed a saccular aneurysm of the left internal carotid-anterior choroidal artery. The aneurysm neck and dome sizes were 2 and 6 mm, respectively (▶ **Fig. 1A**). He had no medical history of heart disease and was not prescribed any medication. On the day after onset, we performed aneurysmal clipping. Anesthesia was induced using a

article published online
August 5, 2024

DOI <https://doi.org/10.1055/s-0044-1788974>.
ISSN 2248-9614.

© 2024. Asian Congress of Neurological Surgeons. All rights reserved.

This is an open access article published by Thieme under the terms of the Creative Commons Attribution-NonDerivative-NonCommercial-License, permitting copying and reproduction so long as the original work is given appropriate credit. Contents may not be used for commercial purposes, or adapted, remixed, transformed or built upon. (<https://creativecommons.org/licenses/by-nc-nd/4.0/>)

Thieme Medical and Scientific Publishers Pvt. Ltd., A-12, 2nd Floor, Sector 2, Noida-201301 UP, India

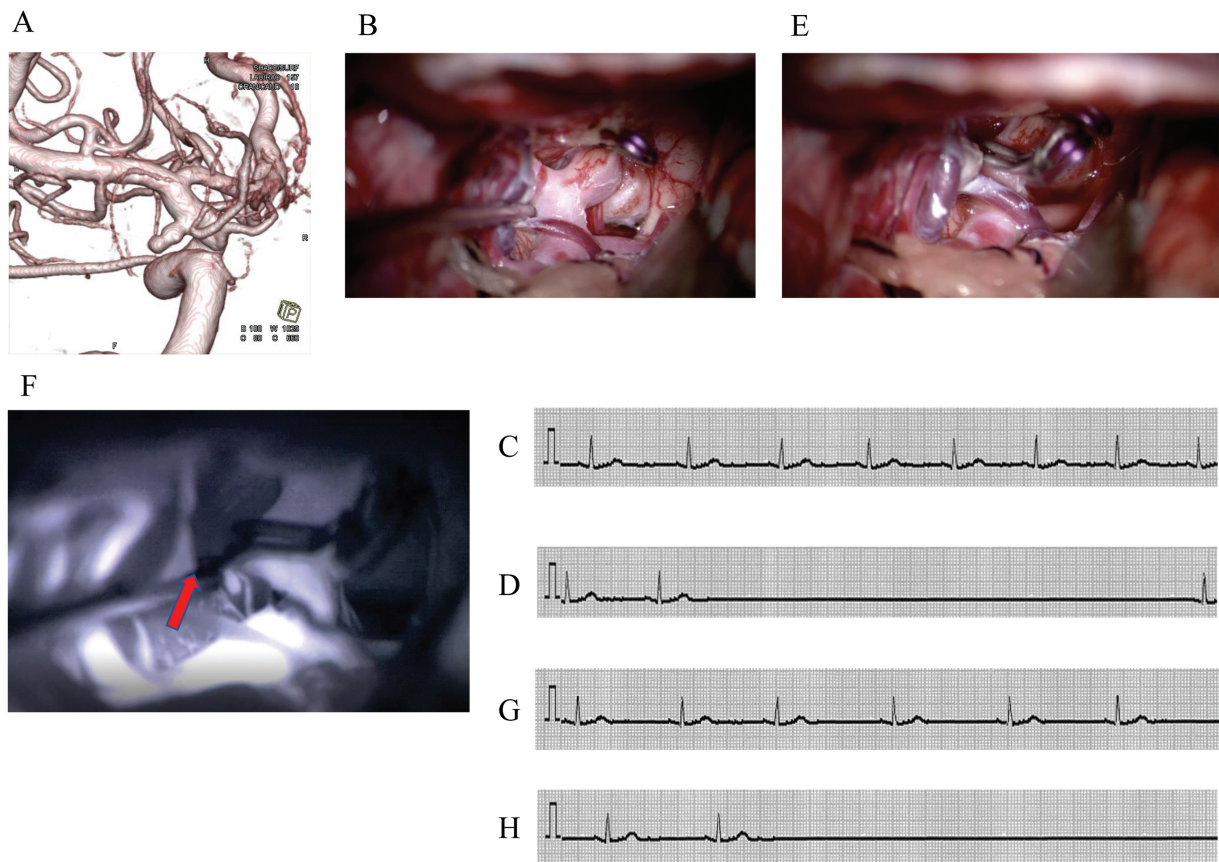


Fig. 1 (A) Three-dimensional (3D) rotational angiography showed the saccular aneurysm of the left internal carotid-anterior choroidal artery aneurysm. (B) Temporary clip was applied proximally to the internal carotid artery. (C) Clipping of the aneurysm was performed. (D) Intraoperative indocyanine green fluorescence video angiography showed a slight influx of the fluorescent dye into the dome of the aneurysm (red arrow). (E) Prior to the first temporary clipping, the electrocardiogram (ECG) showed sinus rhythm. (F) Upon the first temporary clipping, sinus arrest occurred for ~5 seconds. (G) Before the second temporary clipping, the ECG showed sinus rhythm. (H) When the second temporary clip was applied, sinus arrest occurred for 7 seconds.

combination of propofol, remifentanyl, fentanyl, and rocuronium. Propofol and remifentanyl were used to maintain the anesthesia. A left frontotemporal craniotomy and dural incision were performed, followed by a trans-Sylvian approach. The arachnoid around the internal carotid artery was carefully dissected and a temporary clip was inserted proximally to the internal carotid artery to dissect and expose the aneurysm (►Fig. 1B). During temporary clipping, sinus arrest occurred for approximately 5 seconds (►Fig. 1C, D), and the normal sinus rhythm spontaneously resumed. Clipping of the aneurysm was performed (►Fig. 1E) and the temporary clip was removed. Intraoperative indocyanine green (ICG) fluorescence video angiography showed a slight influx of fluorescent dye into the dome of the aneurysm (►Fig. 1F). Therefore, we decided to reclip the aneurysm. When the temporary clip was reinserted, sinus arrest occurred for approximately 7 seconds (►Fig. 1C, H). Following subsequent removal of the temporary clip, the aneurysmal clip was reapplied, and neck clipping was confirmed via ICG. Sinus arrest was not observed. Postoperative magnetic resonance imaging showed no ischemic lesions. Additionally, postoperative cerebral three-dimensional rotational angiography confirmed that the anterior choroid plexus artery was

preserved and the aneurysm was completely closed off. After surgery, we performed a cardiac ultrasound echo and a 1-week Holter electrocardiogram. Neither showed abnormalities. He was discharged on postoperative day 25 with a modified Rankin Scale score of 0. No arrhythmia or cardiac events were observed over a one and half-year follow-up period.

Discussion

Trigeminal cardiac reflex (TCR) is defined as parasympathetic and sympathetic arrhythmia, hypotension, apnea, and gastrointestinal hyperactivity that suddenly occurs during stimulation of the trigeminal branch, resulting in a 20% drop in mean arterial blood pressure and bradycardia below 60 beats per minute.¹ TCR involves the sensory afferent pathway of the trigeminal nerve that enters the spinal trigeminal tract and nucleus via the Gasserian ganglion and then centrifugally via the rostral ventrolateral medulla and the intermediate lateral nucleus of the spinal cord, causing a vagal reflex that results in cardiovascular depression.²

In the existing literature, we found three cases in which patients developed TCR during aneurysm clipping.³⁻⁶

Shibata et al reported that cardiac arrest due to the trigeminal vagal reflex occurred in 2 (2.3%) of 86 aneurysmal clipping surgeries.⁶ There is no case of a patient who developed cardiac arrest during the temporary clipping of an SAH aneurysm, possibly due to TCR. In the present case, cardiac arrest occurred on both occasions of temporary clipping. The repeated and anatomical features of this case suggest that TCR triggered cardiac arrest. TCR is usually resolved within tens of seconds by interrupting the intraoperative procedure.⁷ Therefore, the first step is to terminate the intraoperative procedure causing the reflex.

The majority of intracranial blood vessels and dura are innervated by the ophthalmic division of the trigeminal nerve.⁸ The nasociliary nerve, which originates from the ophthalmic branch of the trigeminal nerve, innervates the middle cerebral artery to induce major vasodilation.⁹ Experimental studies have identified trigeminal nerve endings throughout the extravascular membrane, often in close proximity to the tunica media but never in contact with smooth muscle cells.¹⁰ Therefore, TCR should be considered in cranial craniotomy, not only during dural manipulation of the skull base, but also when directly manipulating intracranial blood vessels, and it is important to cooperate with anesthesiologists by deepening the depth of anesthesia.¹¹ However, the predisposing factors and exact underlying mechanisms for these arrhythmias remain unknown and require further investigation.

Triggers that predispose patients to TCR during general anesthesia include hypoxia, hypercarbia, preoperative β -blockers, calcium blockers, shallow general anesthesia, and pediatric cases.¹²

In the present case, the anesthetics consisted of propofol, remifentanyl, fentanyl, and rocuronium. Remifentanyl is an ultrashort-acting opioid-receptor agonist that is continuously administered intravenously for analgesia and sedation. Remifentanyl has been reported to cause bradycardia and cardiac arrest¹¹ and lower the threshold for vagal excitation.¹³ The incidence of TCR in the surgery for the cerebellopontine angle was shown to increase upon changing the anesthetics from fentanyl and nitrous oxide gas to remifentanyl.¹⁴ In the present case, no intraoperative hypoxemia or hypercarbia was observed. Additionally, preoperative β -blockers or calcium blockers were not administered. Hence, the anesthetic remifentanyl, most likely, may have triggered the reflex. When the temporary clip was applied, the depth of anesthesia used, remifentanyl, was possibly not enough to avoid TCR.

Few studies have shown that anticholinergic agonists are effective in preventing cardiovascular depression caused by TCR.^{15–17} However, some reports have also indicated that anticholinergic agonists can induce serious arrhythmias¹⁸; hence, the agents should be administered cautiously. TCR is usually resolved within tens of seconds by interrupting the intraoperative procedure; therefore, the immediate first

step is to stop the intraoperative procedure that causes the reflex.

In conclusion, we encountered a case of cardiac arrest during temporary clipping of the internal carotid artery. The cardiac arrest might have been triggered by the stimulation of the trigeminal nerve in the internal carotid artery. The high probability that cardiac arrest was induced by trigeminal nerve stimulation should be considered during the temporary clipping of the internal carotid artery.

Conflict of Interest

None declared.

References

- Schaller B, Probst R, Strebel S, Gratzl O. Trigemino-cardiac reflex during surgery in the cerebellopontine angle. *J Neurosurg* 1999; 90(02):215–220
- Prabhakar H, Rath GP, Arora R. Sudden cardiac standstill during skin flap elevation in a patient undergoing craniotomy. *J Neurosurg Anesthesiol* 2007;19:203–204
- Ganjoo P, Navkar DV, Tandon MS. Complete heart block complicating intracranial aneurysm surgery in a pregnant patient. *Neurol India* 2010;58:146
- Murakawa T, Jin T, Matsuki A. A case of ventricular fibrillation during emergency clipping operation for cerebral aneurysm [in Japanese]. *Masui* 2002;51(02):203–205
- Takenaka I, Aoyama K, Iwagaki T, Ishimura H, Kadoya T. Development of torsade de pointes caused by exacerbation of QT prolongation during clipping of cerebral artery aneurysm in a patient with subarachnoid haemorrhage. *Br J Anaesth* 2006;97(04):533–535
- Shibata T, Sakai N, Tani S. Transient asystole during surgery for intracranial unruptured aneurysms caused by excitation of the trigemino-vagal reflex: two case reports. *Jpn J Neurosurg (Tokyo)* 2014;23:673–677
- Chowdhury T, Mendelowith D, Golanov E, et al; Trigemino-Cardiac Reflex Examination Group. Trigemino-cardiac reflex: the current clinical and physiological knowledge. *J Neurosurg Anesthesiol* 2015;27(02):136–147
- White TG, Powell K, Shah KA, Woo HH, Narayan RK, Li C. Trigeminal nerve control of cerebral blood flow: a brief review. *Front Neurosci* 2021;15:649910
- Hosaka F, Yamamoto M, Cho KH, Jang HS, Murakami G, Abe S. Human nasociliary nerve with special reference to its unique parasympathetic cutaneous innervation. *Anat Cell Biol* 2016;49(02):132–137
- Simons T, Ruskell GL. Distribution and termination of trigeminal nerves to the cerebral arteries in monkeys. *J Anat* 1988; 159:57–71
- DeSouza G, Lewis MC, TerRiet MF. Severe bradycardia after remifentanyl. *Anesthesiology* 1997;87(04):1019–1020
- Arasho B, Sandu N, Spiriev T, Prabhakar H, Schaller B. Management of the trigemino-cardiac reflex: facts and own experience. *Neurol India* 2009;57(04):375–380
- Unlüğenç H, İtegin M, Ocal I, Ozalevli M, Güler T, Isik G. Remifentanyl produces vasorelaxation in isolated rat thoracic aorta strips. *Acta Anaesthesiol Scand* 2003;47(01):65–69
- Usami K, Kamada K, Kunii N, Tsujihara H, Yamada Y, Saito N. Transient asystole during surgery for posterior fossa meningioma caused by activation of the trigemino-cardiac reflex: three case reports. *Neurol Med Chir (Tokyo)* 2010;50(04):339–342

- 15 Mirakhur RK, Jones CJ, Dundee JW, Archer DB. I.m. or i.v. atropine or glycopyrrolate for the prevention of oculocardiac reflex in children undergoing squint surgery. *Br J Anaesth* 1982;54(10): 1059–1063
- 16 Hunsley JE, Bush GH, Jones CJ. A study of glycopyrrolate and atropine in the suppression of the oculocardiac reflex during strabismus surgery in children. *Br J Anaesth* 1982;54(04):459–464
- 17 Blanc VF. Trigemino-cardiac reflexes. *Can J Anaesth* 1991;38(06): 696–699
- 18 Branco G, Takahashi A, Ezura M, Yoshida M, Yoshimoto T. Dural arteriovenous shunt involving the superior petrosal sinus: presentation and treatment by transvenous embolisation via the occipital and transverse sinuses. *Neuroradiology* 1997;39(01): 67–70