

Superior Cerebellar Arteries Originating from the Posterior Cerebral Arteries but Normal Course of the Oculomotor Nerves

Dominic Dalip¹, Joe Iwanaga¹, Marios Loukas², Rod J. Oskouian³, R. Shane Tubbs⁴

1. Seattle Science Foundation, Seattle, USA 2. Department of Anatomical Sciences, St. George's University, School of Medicine, St. George's, GRD 3. Neurosurgery, Swedish Neuroscience Institute, Seattle, USA 4. Neurosurgery, Seattle Science Foundation, Seattle, USA

✉ **Corresponding author:** Joe Iwanaga, joei@seattlesciencefoundation.org

Disclosures can be found in Additional Information at the end of the article

Abstract

The posterior cerebral artery (PCA) is a branch of the terminal part of the basilar artery and perfuses the temporal lobes, midbrain, thalamus, and the posterior inferior portion of the parietal lobes. It is divided into P1-P4 segments. Variations in the P1 segment of the PCA are important to neurosurgeons when performing surgery, for example, on basilar tip aneurysms. We report bilateral superior cerebellar artery (SCA) arising from the P1 segment of the PCA. Such a configuration appears to be uncommon but should be kept in mind by neurosurgeons, neurointerventionalists, and neuroradiologists.

Categories: Pathology, Radiology, Neurosurgery

Keywords: posterior cerebral artery, superior cerebellar artery, basilar artery, variations, anatomy

Introduction

The temporal lobes, midbrain, thalamus, and the posterior inferior portion of the parietal lobes are supplied by the posterior cerebral artery (PCA) which is a branch of the terminal part of the basilar artery [1]. The superior cerebellar artery (SCA) usually originates from the basilar artery [2]. The superior vermis, the tectum, and superior surface of the cerebellar hemispheres are supplied by the SCA. Variations in the P1 segment of the PCA are important to neurosurgeons, neurologists and neuroradiologists alike [2,3]. Herein, we report an uncommon case of the left and right SCA arising from the P1 segments of the PCA in a cadaver.

Case Presentation

During routine dissection of the skull base of a male cadaver, an unusual origin of the left and right SCA was observed. The cadaver was 89-years-old at death. Following removal of the bony parts of the skull base, the dura mater was opened. From an inferior view (Figure 1) it was noted that the left and right SCA originated from the P1 segments of the left and right PCA. In normal fashion, the oculomotor nerve passed between the PCA and SCA on both sides (Figure 1). The SCA on both sides left the PCA and traveled over the crus cerebri at their junction with the pons to extend to the cerebellum, under the free edge of the tentorium cerebelli, in a typical fashion. No other intracranial anatomical variations or intracranial pathology was observed.

Received 06/27/2018

Review began 06/28/2018

Review ended 07/01/2018

Published 07/05/2018

© Copyright 2018

Dalip et al. This is an open access article distributed under the terms of the Creative Commons Attribution License CC-BY 3.0., which permits unrestricted use, distribution, and reproduction in any medium, provided the original author and source are credited.

How to cite this article

Dalip D, Iwanaga J, Loukas M, et al. (July 05, 2018) Superior Cerebellar Arteries Originating from the Posterior Cerebral Arteries but Normal Course of the Oculomotor Nerves. Cureus 10(7): e2932. DOI 10.7759/cureus.2932

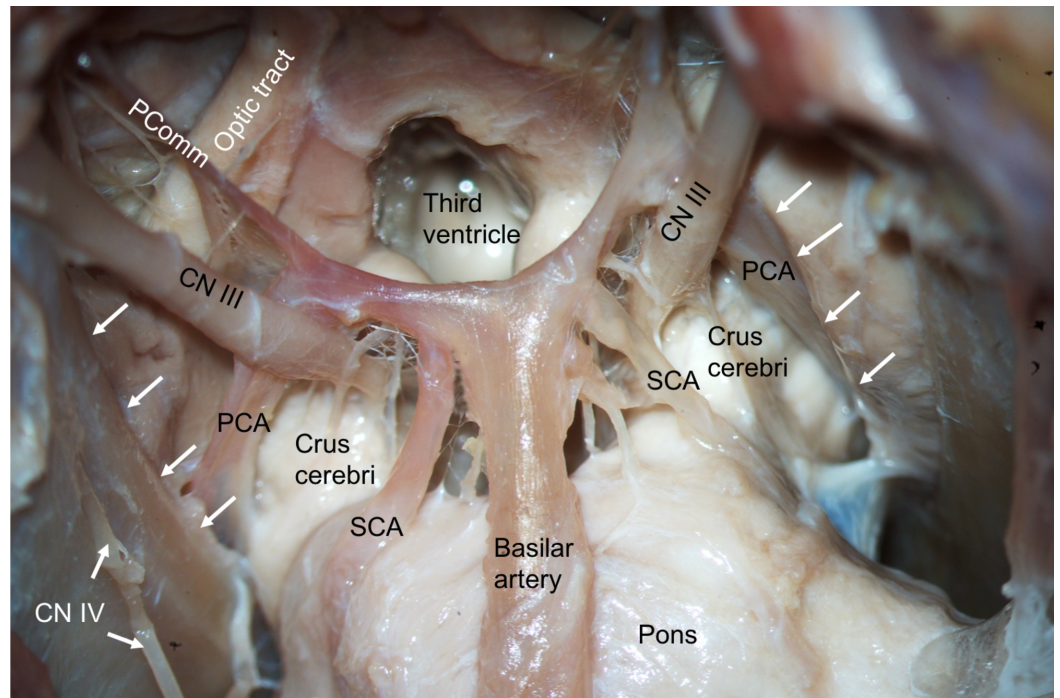


FIGURE 1: Inferior view of the basal brain and associated neurovascular structures.

Note the posterior cerebral arteries (PCA), superior cerebellar arteries (SCA), oculomotor (CN III) and trochlear nerves (CN IV) and posterior communicating artery (PComm). Note that the left and right SCAs arise from the P1 segments of the PCA.

Discussion

Our case demonstrates an unusual origin of the left and right SCA from the P1 segments of the PCA. The PCA is a branch of the terminal part of the basilar artery that perfuses the temporal lobes, midbrain, thalamus, and the posterior inferior portion of the parietal lobes [1]. The PCA is divided into four segments (P1, P2, P3, and P4) and branches into the posterior communicating artery, choroidal branches from P2 segment, perforating branches, and temporal lobe branches [1]. The P1 segment is the part of the PCA that extends from the basilar artery to the posterior communicating artery. The oculomotor nerve usually passes between the P1 segment of the PCA and the SCA. The portion of PCA from the posterior communicating artery to the posterior edge of the midbrain is termed the P2 segment. The P3 segment continues from the P2 segment to the calcarine fissure. The anterior calcarine sulcus marks the beginning of the P4 segment and continues to the cortical surface where this segment terminates [3,4]. Caruso et al. [3] reported that the variations in the P1 segment are rare and occur in only 3% of cases [3]. One case of P1 segment duplication was established in this study and two other cases were described in the literature [3, 5-6]. There were two left-sided P1 segments of the PCA. The P1 segment originated as a single vessel, then separated 4 mm after its branching from the basilar artery. The P1 segment of the PCA and the SCA formed a common trunk bilaterally in a single case [3].

The SCA can be divided into three main portions: interpeduncular-crus, ambient and quadrigeminal. The first portion of the SCA is the interpeduncular-crus portion, which angles laterally from the basilar artery to meet the anterolateral brain stem. At this point, the artery is inferior to the oculomotor nerve [7]. The ambient portion is the second part of the SCA that passes posteriorly into the ambient cisterns [2]. The marginal branch arises from this portion

and is the first large branch of the SCA. Distally, two or three small hemispheric branches arise. The final portion of the SCA is the quadrigeminal part and this artery forms an anastomosis with the superior cerebellar arteries to perfuse the tectum. This portion gives rise to the terminal branch of the SCA to the superior vermis. There are a variety of variations of the SCA. Twenty-eight out of 100 patients displayed duplication of the SCA with 8% being bilateral. Furthermore, unilateral triplication was reported in two patients [2]. Hardy et al. [7] described seven cases where the SCA arose from a duplicated trunk. In 20% of cases, the SCA was found to be duplicated [7,8]. Absence of the SCA is rare, but can be observed [9]. Hardy et al. [7] found 2/50 (4%) SCAs arising from the proximal PCA. However, in both cases, the arteries crossed over the oculomotor nerve. In our case (Figure 1), the oculomotor nerve passed between the PCA and SCA in typical fashion [10].

Conclusions

The SCA was found to branch from the P1 segment of the PCA during dissection of a cadaver. Such a configuration appears to be uncommon but should be kept in mind by neurosurgeons, neurointerventionalists, and neuroradiologists.

Additional Information

Disclosures

Human subjects: Consent was obtained by all participants in this study. **Conflicts of interest:** In compliance with the ICMJE uniform disclosure form, all authors declare the following:

Payment/services info: All authors have declared that no financial support was received from any organization for the submitted work. **Financial relationships:** All authors have declared that they have no financial relationships at present or within the previous three years with any organizations that might have an interest in the submitted work. **Other relationships:** All authors have declared that there are no other relationships or activities that could appear to have influenced the submitted work.

References

1. Caplan LR: Syndromes related to large artery thromboembolism in the posterior circulation. Stroke Syndromes. Caplan LR, Van Gijn J (ed): Cambridge University Press, Cambridge; 2012. 574-592. [10.1017/CBO9781139093286.052](https://doi.org/10.1017/CBO9781139093286.052)
2. Mani RL, Newton TH, Glickman MG: The superior cerebellar artery: an anatomic-roentgenographic correlation. Radiology. 1968, 91:1102-1108. [10.1148/91.6.1102](https://doi.org/10.1148/91.6.1102)
3. Caruso G, Vincentelli F, Guidicelli G, et al.: Anomalies of the P1 segment of the posterior cerebral artery: early bifurcation or duplication, fenestration, common trunk with the superior cerebellar artery. Acta Neurochirurgica. 1991, 109:66-71. [10.1007/bf01405701](https://doi.org/10.1007/bf01405701)
4. Kaya AH, Dacinar A, Ulu MO, et al.: The perforating branches of the P1 segment of the posterior cerebral artery. J Clin Neurosci. 2010, 17:80-84. [10.1016/j.jocn.2009.03.046](https://doi.org/10.1016/j.jocn.2009.03.046)
5. Bisaria KK: Anomalies of the posterior communicating artery and their potential clinical significance. J Neurosurg. 1984, 60:572-576. [10.3171/jns.1984.60.3.0572](https://doi.org/10.3171/jns.1984.60.3.0572)
6. Watanabe T, Togo M: Accessory middle cerebral artery. Report of four cases. J Neurosurg. 1974, 41:248-251. [10.3171/jns.1974.41.2.0248](https://doi.org/10.3171/jns.1974.41.2.0248)
7. Hardy DG, Peace DA, Rhoton AL: Microsurgical anatomy of the superior cerebellar artery. Neurosurg. 1980, 6:10-28. [10.1227/00006123-198001000-00002](https://doi.org/10.1227/00006123-198001000-00002)
8. Salamon G, Huang YP: Radiologic Anatomy of the Brain. Springer, New York; 1976.
9. Tubbs RS, Shoja MM, Loukas M: Bergman's Comprehensive Encyclopedia of Human Anatomic Variation. John Wiley & Sons, New Jersey; 2016. [10.1002/9781118430309](https://doi.org/10.1002/9781118430309)
10. Park HK, Rha HK, Lee KJ, Chough CK, Joo W: Microsurgical anatomy of the oculomotor nerve. Clin Anat. 2017, 30:21-31. [10.1002/ca.22811](https://doi.org/10.1002/ca.22811)