

Contents lists available at [ScienceDirect](https://www.sciencedirect.com)

International Journal of Surgery Case Reports

journal homepage: www.casereports.com

Opioid drugs and stercoral perforation of the colon: Case report and review of literature

Renée Poitras^{a,*}, Daun'Lee Warren^a, Sylvanus Oyogoa^b^a Avalon University School of Medicine, Youngstown, OH, United States^b Department of General Surgery, Raleigh General Hospital, Beckley, WV, United States

ARTICLE INFO

Article history:

Received 26 June 2017

Received in revised form

28 November 2017

Accepted 28 November 2017

Available online 7 December 2017

Keywords:

Stercoral perforation

Constipation

Suboxone

Opioids

Buprenorphine

ABSTRACT

INTRODUCTION: Stercoral perforation of the colon is a rare pathology, which is believed to be caused by an increased intraluminal pressure created by a fecaloma. Opioid induced constipation is a rare and often unsuspected cause of colonic perforation.

PRESENTATION OF CASE: We report the case of a 58-year-old woman, who presented to the emergency department (ED) with severe hypotension, abdominal pain and gastrointestinal bleeding. She was found to have a diffusely tender and distended abdomen. Her history was positive for long-term suboxone use and chronic constipation. Abdominopelvic computed tomography (CT) scan revealed a bowel perforation, ascites and fecal impaction. Emergency laparotomy revealed extensive stool in the peritoneal cavity as well as hemoperitoneum. There was a fecal bolus with perforation located in the sigmoid colon. On postoperative day (POD) six, a second abdominopelvic CT scan was performed and results revealed the necessity of a second exploratory laparotomy. She had multiple loculated abscesses within the small bowel and other areas, which were opened and washed out.

DISCUSSION: Due to the inflating use of drugs in the opioid class, the recognition of this pathology has become increasingly important. The action of the drug on the mu-opioid receptors, any patients taking opioid medications are at risk for constipation progressing to stercoral perforation and should be monitored closely.

CONCLUSION: Patients presenting with chronic constipation, fecal impaction on imaging and clinical signs of peritonitis or sepsis, should consider stercoral perforation in their differential diagnosis since early detection is key to reduce mortality rates in these cases.

© 2017 The Authors. Published by Elsevier Ltd on behalf of IJS Publishing Group Ltd. This is an open access article under the CC BY-NC-ND license (<http://creativecommons.org/licenses/by-nc-nd/4.0/>).

1. Introduction

Stercoral perforation was first described by Berry to the Pathological Society of London in 1894 [1]. Colon perforation caused by stercoral ulcer is extremely rare, with fewer than 150 cases reported in the English language to date [2]. The pathogenesis is thought to be caused by an increased intraluminal pressure by the stercoraceous mass, causing localized ischemic pressure necrosis of the bowel. Ulceration, bowel wall thinning and subsequent bacterial invasion progresses to perforation [3]. There are many causes of stercoral perforation, such as chronic constipation, Chagas disease, Hirschsprung's disease, toxic colitis and megacolon. We will

focus on stercoral perforation caused by opioid induced chronic constipation, as was the case with our patient.

This case report has been reported in line with the SCARE criteria [4].

2. Presentation of case

A 58-year-old female was admitted to the department of surgery through the ED with a chief complaint of severe abdominal pain and discomfort as well as a syncopal episode thought to be related to patient's hypotensive state. She had a history of chronic pain syndrome treated with long-term sublingual 8 mg–2 mg Suboxone film therapy, current infection of hepatitis C, chronic untreated constipation, reported history of irregular heartbeat and possible history of coronary artery disease treated as outpatient with Plavix. The patient was unable to provide any family history. She currently lives with her husband and is unemployed. She stated that her only positive drug history was the suboxone. Her past surgical history

Abbreviations: CT, computed tomography; ED, emergency department; POD, postoperative day.

* Corresponding author at: Avalon University School of Medicine, P.O. BOX 480, Girard, OH 44420, United States.

E-mail address: renealexiepoitras@gmail.com (R. Poitras).

<https://doi.org/10.1016/j.ijscr.2017.11.060>

2210-2612/© 2017 The Authors. Published by Elsevier Ltd on behalf of IJS Publishing Group Ltd. This is an open access article under the CC BY-NC-ND license (<http://creativecommons.org/licenses/by-nc-nd/4.0/>).

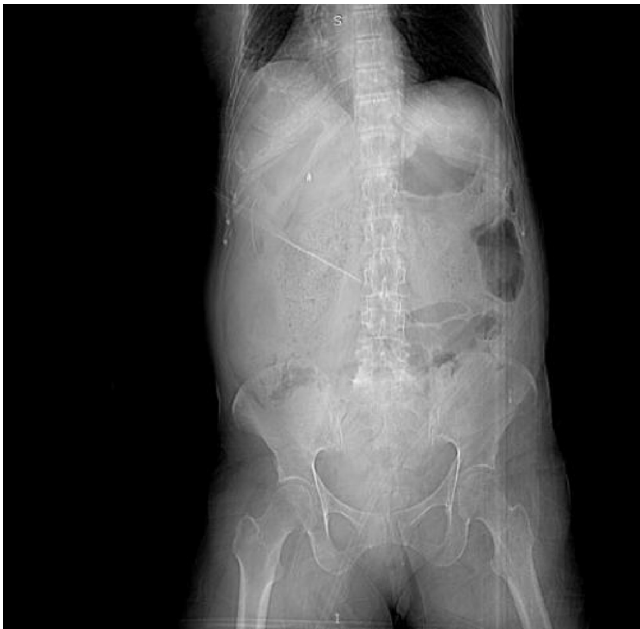

Fig. 1. Preoperative CT Abdomen/Pelvis showing significant amount of fecal matter within the pelvis.

revealed a partial hysterectomy, a cholecystectomy as well as an appendectomy.

On initial physical exam, the patient was found to have a diffusely tender and distended abdomen and hematochezia. She was afebrile and hypotensive with a systolic blood pressure in the 80s–90s. Her white blood count on admission was $6.5 \times 10^9/L$. Abdominopelvic CT scan revealed a bowel perforation most likely in the distal colon, ascites and fecal impaction of the large bowel (Fig. 1 and 2). The initial diagnosis was perforated ischemic bowel. Emergency surgery was performed by Dr. Sylvanus Oyogoa. Intraoperatively, she was found to have extensive stool in the peritoneal cavity as well as hemoperitoneum. There was a large fecal mass located in the sigmoid colon causing pressure necrosis on surrounding tissues that had progressed to bowel perforation. Fecal material was protruding through the perforation site into the peritoneal cavity. Hartmann's procedure was used to resect the affected bowel. A splenic rupture was also noted and a splenectomy was performed (Fig. 3). The colostomy was created in the full quadrant bisecting with simple fashion and a wound VAC was placed following closure. The patient was given antibiotics initially and was given Zosyn, Flagyl and Vancomycin. Post-op diagnosis was perforated bowel, fecal peritonitis, hemoperitoneum and splenic rupture. Postoperatively, she continued to show signs of sepsis as well as continual complaints of worsening abdominal pain. On POD six, a second abdominopelvic CT scan was performed and revealed increased free fluid within the abdominal cavity, increased attenuation more dependently, extraluminal oral contrast is seen in the fluid within the abdominal cavity consistent with bile leak. High-density fluid present in the left upper quadrant was suggestive of a contrast leak at the location of splenectomy (Fig. 4). This raised concern for possible venous leak and a second exploratory laparotomy with washout was performed on POD seven. Preoperative diagnosis was perforated gut with fecal peritonitis, intraabdominal abscess, and sepsis. Upon exploration of the cavity, the patient had lots of murky dusky looking fluid in the abdomen. There was no evidence of compromised bowel, she had multiple loculated abscesses within the small bowel and other areas, which were opened and washed out very gently with antibiotic solution and sterile solution. The patient tolerated the procedure well and was brought to the recovery room in

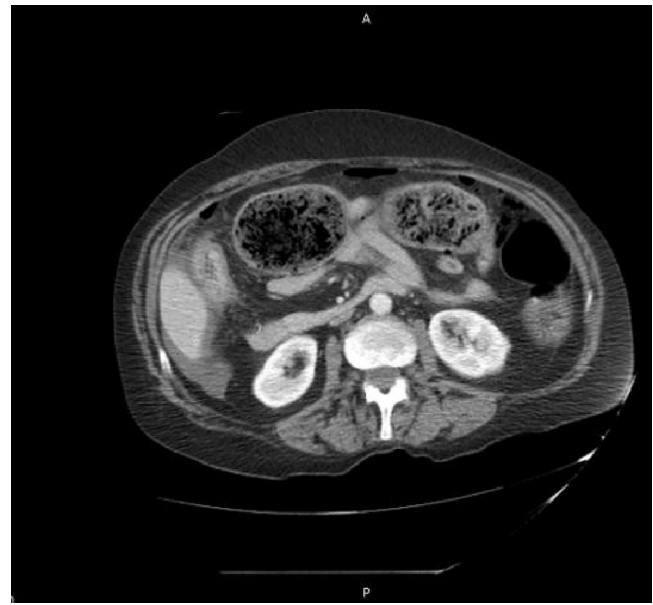

Fig. 2. Preoperative axial CT Abdomen showing small pockets of free gas at the anterior abdominal wall, colonic perforation and fecal impaction of the large bowel.

stable condition. Post-op diagnosis was intraabdominal abscesses and sepsis. After re-operation, she showed steady recovery with conservative treatment.

3. Discussion

Stercoral perforation or “perforation of the large bowel due to pressure necrosis from a fecal mass” [5] is a rare, yet dangerous condition that carries a mortality rate ranging from 32 to 57% [6]. It is thought to be the cause of 3.2% of all colonic perforations and 2.2% of randomly selected autopsy examinations [7]. The mean patient age in cases of stercoral perforation is 59 years and the age range is 22–85 years of age [8]. Mauer et al., proposed four diagnostic criteria for classification as stercoral perforation: 1) A round and ovoid antimesenteric colonic perforation larger than 1 cm in diameter 2). The colon full of stool that protrudes through the perforation site 3) Microscopic evidence of multiple pressure ulcer and acute inflammatory reaction surrounding the perforation 4) Absence of external injury, diverticulitis or obstruction due to neoplasm or adhesions [9]. The four diagnostic criteria were met in our case.

This patient suffered from chronic drug-induced constipation, which is one of the well-documented risk factors of stercoral perforation. Many drugs currently prescribed carry a high incidence of constipation as a side effect including, amongst others, opioids, anti-cholinergics, antispasmodics, tricyclic antidepressants and calcium channel blockers. Our patient was treated with sublingual 8 mg–2 mg Suboxone film therapy for chronic pain syndrome, causing her decreased gastrointestinal (GI) motility. Constipation is a common side effect of Suboxone use, experienced in 5–12.1% of all Suboxone users [10]. Buprenorphine, the major constituent of Suboxone, is a partial agonist of the mu and delta opioid receptor as well as an antagonist of the kappa-opioid receptor. Mu-opioid receptor agonists inhibit gastric emptying, increase pyloric muscle tone, induce pyloric and duodenojejunal phasic pressure activity, disturb the migrating myoelectric complex, delay transit through the small and large intestine, and elevate the resting anal sphincter pressure [11]. The decreased velocity of stool through the GI systems increases fecal contact time with the GI mucosa and promotes excessive absorption of water and electrolytes causing bulkier, firm stools. Due to their action on mu-opioid receptors, any patient tak-

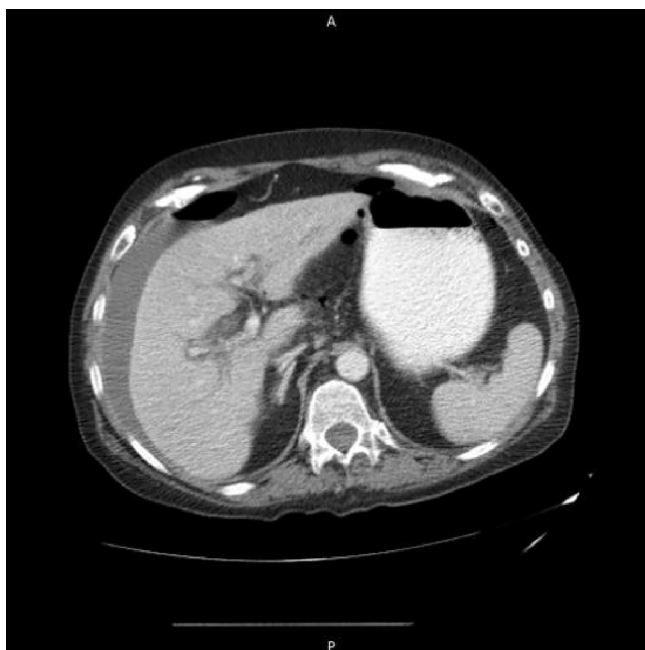

Fig. 3. Preoperative axial CT Abdomen showing spleen that was found to be ruptured during laparotomy.

ing opioid medications are at risk for this condition and should be monitored closely. Treating the constipation before a fecaloma can develop would eliminate the development of pressure necrosis caused by increased intraluminal pressure thus halting the incidence of stercoral perforation.

4. Conclusion

This case report has identified and presented a 58-year-old female patient with stercoral perforation. In our case, the patient had chronic pain treated with long-term sublingual 8 mg–2 mg Suboxone film therapy causing her chronic constipation. Due to its high mortality rate, early identification of patients at risk for stercoral perforation is important. Only 10% of patients with this condition are correctly diagnosed before surgery [12]. Some patients with a fecaloma may experience episodes of bowel incontinence as a result of encopresis and get wrongfully treated with antidiarrheal medication thus causing further progression of the pathology. Stercoral perforation of the colon is an often-overlooked complication of opioid use. Due to the widespread use of this class of drugs, early identification of this complication is crucial. Any patient presenting with chronic constipation, fecal impaction on x-ray or CT scan and clinical signs of peritonitis or sepsis, should have stercoral perforation included in their differential diagnosis.

Conflicts of interest

There are no conflicts of interest.

Funding

This research did not receive any specific grant from funding agencies in the public, commercial, or not-for-profit sectors.

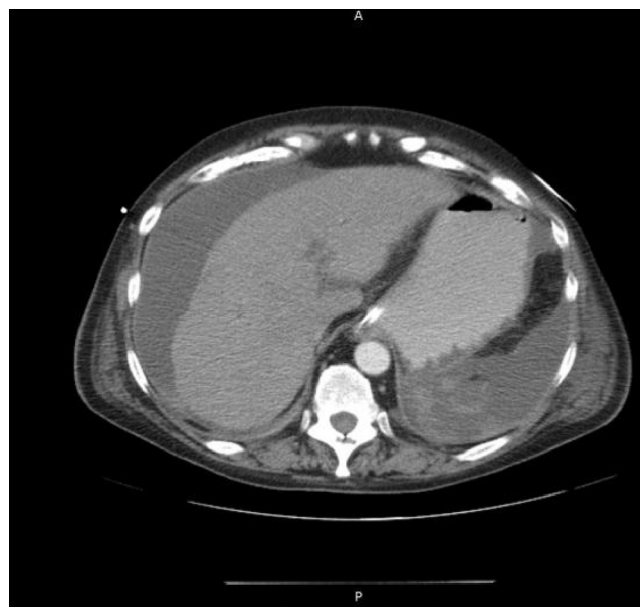


Fig. 4. POD6 axial CT Abdomen with hyperdense area in LUQ.

Ethical approval

Ethical approval has been exempted by Raleigh General Hospital's Ethical and Compliance committee, no reference number was given for their judgement.

Consent

Written informed consent was obtained from the patient for publication of this case report and accompanying images. A copy of the written consent is available for review by the Editor-in-Chief of this journal on request.

Author contribution

Renee Poitras: Responsible for research, organization, and composition of this case report.

Daun'Lee Warren: Responsible for critical review and corrections of this case report.

Sylvanus Oyogoa, MD: Responsible for the interview, exam, and surgical management of the patient.

Registration of research studies

This is inapplicable to our case report.

Guarantor

Renée Poitras.

References

- [1] Wen-Shih Huang, Chia-Siu Wang, Ching-Chuan Hsieh, Paul Y. Lin, Chih-Chien Chin, Jeng-Yi Wang, Management of patients with stercoral perforation of the sigmoid colon: report of five cases, *World J. Gastroenterol.* 12 (3) (2006) 500.
- [2] Jeonghyun Kang, Chung Min, A stercoral perforation of the descending colon, *J. Korean Surg. Soc.* 82 (2) (2012) 125.
- [3] J. Alexander-Williams, J. Hollingworth, Stercoral perforation of the colon, *Br. J. Surg.* 68 (6) (1991) 763.
- [4] R.A. Agha, A.J. Fowler, A. Saetta, I. Barai, S. Rajmohan, D.P. Orgill, for the SCARE Group, The SCARE statement: consensus-based surgical case report guidelines, *Int. J. Surg.* 34 (2016) 180–186.
- [5] Jeonghyun Kang, Chung Min, A stercoral perforation of the descending colon, *J. Korean Surg. Soc.* 82 (2012) 125–127.

- [6] Bunkar Shiv Kumar, Stercoral perforation of the sigmoid colon in a schizophrenic patient, *JCDR* 9 (1) (2015) PD07–PD08.
- [7] R. Bhatt Vijaya, et al., Perforation in a patient with stercoral colitis and diverticulosis: who did it? *J. Commun. Hosp. Intern. Med. Perspect.* 4 (1) (2014), <http://dx.doi.org/10.3402/jchimp.v4.22898>.
- [8] C.A. Maurer, P. Renzulli, L. Mazzucchelli, B. Egger, C.A. Seiler, M.W. Büchler, Use of accurate diagnostic criteria may increase incidence of stercoral perforation of the colon, *Dis. Colon Rectum* 43 (2000) 991–998.
- [9] Andrew Davies, et al., Stercoral perforation of the colon a potentially fatal complication of opioid-induced constipation, *J. Pain Symptom Manage.* 50 (2) (2015) 260–262.
- [10] Buprenorphine/naloxone (Rx), Suboxone, Zubsolv (buprenorphine/naloxone) Dosing, Indications, Interactions, Adverse Effects, and More, Medscape, 2017, Web. 20 May 2017. 02 May.
- [11] Peter Holzer, Opioid receptors in the gastrointestinal tract, *Regul. Pept.* 155 (1–3) (2009) 11–17.
- [12] Bo Yang, Huai-Kun Ni, Diagnosis and treatment of spontaneous colonic perforation: analysis of 10 cases, *World J. Gastroenterol.* 14 (28) (2008) 4569–4572, PMC. Web. 2 2017.

Open Access

This article is published Open Access at [sciedirect.com](https://www.sciedirect.com). It is distributed under the [IJSCR Supplemental terms and conditions](#), which permits unrestricted non commercial use, distribution, and reproduction in any medium, provided the original authors and source are credited.