

# Length of hospital stay and complications of mini-facelift versus modified Blair incision for parotid abscess drainage

## Purpose

To compare the length of hospital stay (LHS) and complications between mini-facelift (MFL) and modified Blair incisions (MBI) for adult patients undergoing parotid abscess drainage (PAD).

## Materials and Methods

A retrospective cohort study design was utilized comprising 2 groups of healthy adult patients (American Society of Anesthesiology [ASA] status I-II) who underwent PAD during a 7-year interval. The primary predictor variable was incision type (MFL vs. MBI). The primary outcomes were LHS and adverse complications resulting from the incision type. Other study variables were grouped into demographic, clinical, microbiological, and therapeutic categories. Difference in the cohort characteristics were analyzed using appropriate descriptive and uni- and bivariate statistics. Multivariate logistic regression was used to measure the effect of the incision type had on the LHS and adverse complication rates.

## Results

The sample included 120 subjects (50% females) with a mean age of  $41.7 \pm 18.3$  years. Patients in the MFL group were hospitalized for  $8.2 \pm 7.7$  days, and the other group stayed in the hospital for  $10.2 \pm 8$  days (adjusted odd ratio [OR] 1.19, 95% confidence interval [95% CI] 0.52 to 2.7;  $p=0.8$ ). In comparison with MBI, MFL did not significantly increase complication risks in term of facial paralysis (adjusted OR 0.93, 95% CI 0.06 to 15.29;  $p=1.0$ ) and necessity of re-operation (adjusted OR 0.61, 95% CI 0.1 to 3.8;  $p=0.7$ ).

## Conclusion

Given no different LHS and complication risks, MFL can replace MBI for ASA I-II adult patients undergoing PAD.

**Keywords:** Parotid abscess, incision, hospital stay, complication, head and neck infection

## Introduction

The *International Classification of Diseases*, 10<sup>th</sup> Revision, Clinical Modification (ICD-10-CM) separates parotid abscess (PA) (K11.3) from acute suppurative parotitis (APP) (K11.21) despite the fact that the former is generally accepted as a disease spectrum end of the latter (“*continuum concept*”). PA emerges from *ca.* one fifth of APP cases and links to ductal stricture or kinks, primary parenchymal involvement, or infection of peri-/intraparotid lymph nodes, especially with poor oral hygiene. Surgical intervention is indicated in patients with (1) no clinical improvement after 24-48 hours of conservative treatment: hydration, gland massage/stimulation and broad-spectrum antibiotics, (2) facial paralysis, (3) deep fascial space infections, (4) intraglandular parenchymal suppuration, or (5) risk of severe infections, e.g. osteomyelitis, necrotizing fasciitis, or sepsis. Superficial parotidectomy is often necessary for recurrent or chronic PA (1-8).

Poramate Pitak-Arnnop<sup>1</sup> ,  
Nattapong Sirintawat<sup>2</sup> ,  
Keskanya Subbalekha<sup>3</sup> ,  
Jean-Paul Meningaud<sup>4</sup> ,  
Prim Auychai<sup>5</sup> ,  
Chatpong Tangmanee<sup>6</sup> ,  
Andreas Neff<sup>1</sup> 

ORCID IDs of the authors: P.P. 0000-0002-7427-3461; N.S. 0000-0002-6441-5243; K.S. 0000-0002-1570-2289; J.P.M. 0000-0001-9227-9026; P.A. 0000-0002-6505-3424; C.T. 0000-0001-6805-2921; A.N. 0000-0001-5865-0020

<sup>1</sup>Department of Oral and Maxillofacial Surgery, University Hospital of Giessen and Marburg, UKGM GmbH, Campus Marburg, Faculty of Medicine, Philipps-University of Marburg, Marburg, Germany

<sup>2</sup>Department of Oral and Maxillofacial Surgery, Faculty of Dentistry, Mahidol University, Bangkok, Thailand

<sup>3</sup>Department of Oral and Maxillofacial Surgery, Faculty of Dentistry, Chulalongkorn University, Bangkok, Thailand

<sup>4</sup>Department of Plastic, Reconstructive, Aesthetic and Maxillofacial Surgery, Henri Mondor University Hospital, AP-HP, Faculty of Medicine, University Paris-Est Créteil Val de Marne (Paris XII), Créteil, France

<sup>5</sup>Department of Paediatric Dentistry, Faculty of Dentistry, Chulalongkorn University, Bangkok, Thailand

<sup>6</sup>Department of Statistics, Chulalongkorn Business School, Bangkok, Thailand

Corresponding Author: Poramate Pitak-Arnnop

E-mail: poramate.pitakarannop@gmail.com

Received: 2 September 2021

Revised: 3 December 2021

Accepted: 27 December 2021

DOI: 10.26650/eor.2022989445

With time, surgeries with minimal/short incisions have gained popularity not only for aesthetic but also for oncologic and traumatological purposes. Mini-facelift (MFL) has gradually superseded conventional facelift and modified Blair incisions (MBI) for parotidectomy. Over the past two decades, authors of several standard textbooks have recommended MFL for parotid abscess drainage (PAD), and MBI should be performed only in case of caudally extending/locating PA (1,4,8-10). Minimally invasive surgical techniques result in gratifying outcomes, low complications rates, and rapid return to daily activities (11-14). However, our literature search unveiled a truth that the recommendation on surgical approach to PA relied on Level of Evidence IV and V after the Oxford Centre of Evidence-Based Medicine (CEBM). Existing studies included small sample sizes and non-systematic research designs, making them difficult to ascertain conclusions concerning risks of prolonged hospitalization (> 7 days) and complications.

The purpose of the present study was to analyze length of hospital stay (LHS) and complications resulting from (extended) deep plane MFL vs. traditional MBI for relatively healthy adult patients undergoing parotid abscess drainage (PAD). We also sought to determine whether any difference in LHS and complication risks existed between both incisions. The investigators hypothesized that no significant difference would be found in prolonged LHS and adverse risks when using MFL vs. MBI. Our specific aims were to perform a retrospective outcome research (CEBM's Level of Evidence 2c), to document type and frequency of surgical incisions for PAD, to calculate the prolonged LHS and complication rates, and to prove the differences in outcomes of each PA incision.

## Material and Methods

### Study design and samples

We completed a retrospective cohort study recruiting 2 groups of patients undergoing PAD performed by a single surgeon (P.P.) during a 7-year interval. Subjects eligible for study inclusion were female or male, older than 18 years of age, who had undergone PAD via any incision types in an inpatient setting with postoperative antibiotics. The diagnosis was established based on clinical presentations, routine blood test, and radiographic confirmation with computed tomography (CT): low attenuated, single cyst-like or multiple loculated lesions with contrast enhancement of the abscess wall (5,7). The surgical technique was together decided by provider and patient factors. In the MFL group, the patients were informed about the chance of intraoperative converting the incision into the conventional MBI, depending on surgical difficulty. All subjects received routine use of general anaesthetics and continuous intraoperative neuro-monitoring (cIONM) of the facial nerve, as described by other authors (15-17). Subjects were excluded from the study if they did not satisfy the inclusion criteria, had poor general health (American Society of Anesthesiology [ASA] status III-IV), or if infection became disseminating to other tissues/organs or arose from a tumor ("tumor necrosis"). Treatment outcomes in pediatric/adolescent patients may be difficult to evaluate, and ASA III-IV patients often suffer from poor/delayed healing (3,18). Both of these patient groups were therefore excluded from the study.

### Ethical statement

This retrospective cohort study with chart review was approved by the institutional review board, and the ethical guidelines of the World Medical Association's Declaration of Helsinki and the STROCSS criteria were followed throughout the study. Every patient gave consent for participation and prospective consent for their anonymous data in future researches.

### Study variables

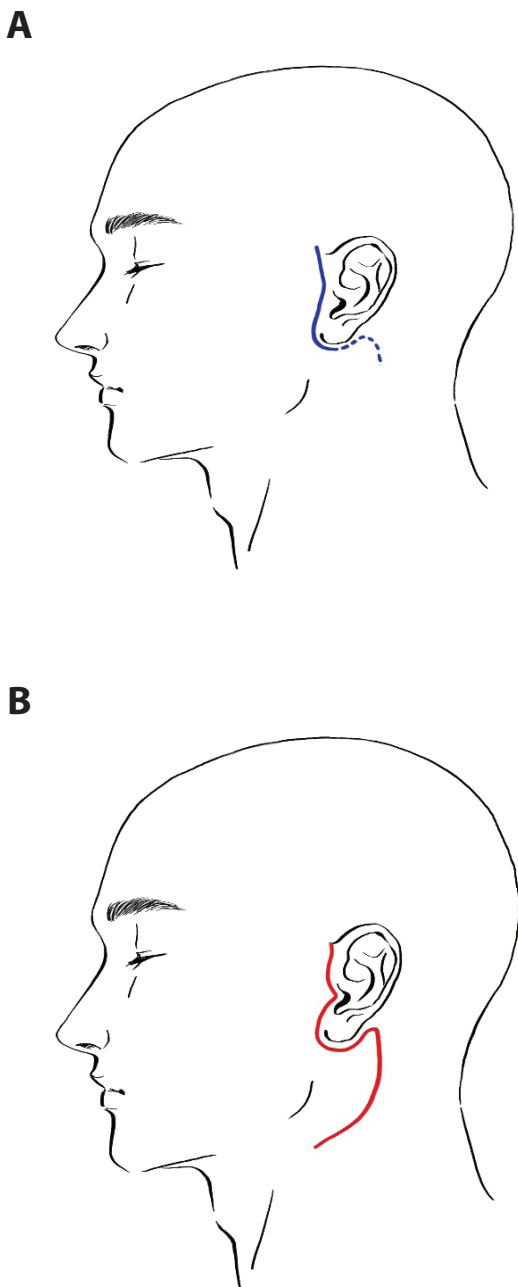
The primary predictor variable was incision types: MFL vs. MBI. The surgical technique was recorded as documented in operative notes. MFL began with the preauricular incision extending into its natural crease superior to the tragus, and then curved posterior to the tragus and inferior to the inferior ear lobule with/without small postauricular extension. The incision included neither temporal hair nor trichophytic incision nor extension beyond the mastoid skin (Figure 1A). In the MBI group, we used the conventional Blair "Lazy-S" incision with extension into the upper neck (Figure 1B). Details of both surgical methods were extensively described by other authors (4,11-14,19,20). The parotid fascia was exposed and incised parallel to the facial nerve. An incision biopsy was also performed to rule out tumor diseases. After microbiological swab, abscess evacuation and aggressive antiseptic lavage (mostly, 7.5% povidone-iodine: Braunol® Haut-, Schleimhaut- und Wundantiseptikum, B. Braun Melsungen AG, Melsungen, Germany), one or two penrose drains (size 8 or 10 or 12 mm; Easy-Flow-Drainage®, Dispomedica GmbH, Hamburg, Germany) for postoperative irrigation were left *in situ* until a day before patient discharge.

The primary outcomes were length of hospital stay (days) and incidence of adverse complications related to the surgical incision. Complications included delayed wound healing/dehiscence/fistula, recurrence of the infection, trismus, facial paralysis, Frey's syndrome, sensory disturbance, and hypertrophic scar/keloid. The patients were discharged when clinical symptoms resolved and blood chemical test results were unremarkable.

The other study variables were categorized into 4 categories: (1) demographic: age, gender, relevant risk factors (metabolic diseases, dehydration, irradiation, Sjögren's syndrome, HIV infection, placement of a Sengstaken-Blakemore tube, previous endoscopic retrograde cholangiopancreatography [ERCP], continuous positive airway pressure therapy, and use of total parenteral nutrition) (8), (2) clinical: limited mouth opening (defined as an inability to vertically align 3 fingers between upper and lower central incisors up to the first distal interphalangeal folds) (21), dysphagia/odynophagia, reduced/poor general condition including severe pyrexia and malaise (defined as Eastern Co-operative Oncology Group [ECOG]/WHO Performance Score Grade 3-5) (22), (3) microbiological: identified pathogen, and (4) therapeutic: used antibiotic.

### Statistical analysis

Statistical analyses were performed using SPSS V27 (Statistical Package for Social Sciences, IBM Corporation, NY, USA) for all analyses. For all categorical comparisons, we used the  $\chi^2$  test or Fisher's Exact Test, as appropriate. For comparisons



**Figure 1.** Drawings showing (A) mini-facelift incision and (B) modified Blair incision.

of continuous variables, we used independent samples *t* test. Multivariable logistic regression analysis was then applied to measure the effect of the incision technique on prolonged LHS and adverse complication rates. The multivariate model was adjusted into binary before calculation. We reported 95% confidence intervals (CIs) and calculated *P* values. All statistical tests were 2-sided using a standard alpha of 0.05.

## Results

A total of 120 PA patients treated by the first author (P.P.) were identified during the 7-year study period. Patient demographics, outcomes, and data analyses are summarized in Table 1. The only risk factor in this cohort was found, i.e. metabolic diseases in 11 (or 9.2%) patients. Advanced age

and usual symptoms of odontogenic infections (i.e. limited mouth opening, swallow difficulty, reduced general condition) were not common. However, gram-positive oral bacteria were the main pathogen of the infection, and intravenous ampicillin/sulbactam remained the gold standard of empiric antibiotic therapy. Only 10 (or 8.3%) patients had a Staphylococcal infection.

Neither incision conversion (MFL to MBI) nor surgical airways nor secondary parotidectomy was warranted. All patients were successfully intubated via the orotracheal route with/without a flexible fiberoptic bronchoscope. There were no postoperative complications other than 2 (or 1.7%) transient facial paralyses (House-Brackmann scoring Grade II and III) and 5 (or 4.2%) re-operations. Of those, 4 re-operated patients were Asian/Eurasian immigrants and had an infection of *Burkholderia pseudomallei*, making the association between this pathogen and re-operation events statistically significant ( $P = 0.0001$ ).

On multivariate logistic regression analysis, there was no significantly increased risk of LHS > 7 days (adjusted odd ratio [OR] 1.19, 95% confidence interval [95% CI] 0.52 to 2.7;  $P = 0.8$ ) and adverse complication (facial paralysis: adjusted OR 0.93, 95% CI 0.06 to 15.29,  $P = 1.0$ ; necessity of re-operation (adjusted OR 0.61, 95% CI 0.1 to 3.8,  $P = 0.7$ ).

## Discussion

Given a proliferation of facial plastic surgical techniques, there exists a need to assess the efficacy between different surgical approaches to determine which offers the optimal results. To address this deficit, we compared two surgical techniques for PAD. Our findings point to specific factors that could support a decision regarding the incision for PAD in ASA I-II patients. MBI provides a wide surgical approach to visualize the facial nerve, abscess, hematoma and necrotic tissue, but it causes aesthetic concerns and probably fistulation. In this regard, MFL seems to be more advantageous because the MBI's disadvantages are overcome (23,24).

For aesthetic purposes, MBI and MFL yield comparable short-time outcomes. MBI offers a superior long-term result in the neck only (12). However, correction of cervical laxity and/or bulky neck is not the main aim of PAD. In this study, the investigators could not demonstrate the significant difference of LHS and complication rates between both sample groups. These results correspond with those recently reported by other investigators (23,24). MBI should therefore be used in case of caudally extending/locating PA – an alternative for this situation is extending the short retroauricular incision to allow a better vision with a completely hidden scar behind the ear lobe instead of a visible occipital prehairline scar (11). One huge drawback of the MFL incision is that the direction of the drainage is often not parallel to the gravity. However, the effect of this unfavorable vector is unlikely to hinder treatment outcomes in this series.

*Staphylococcus aureus* and *Streptococcus viridians* are common pathogenic causes of PA. Gram-negative bacilli and strict anaerobes, e.g. *Klebsiella spp*, *Bacteroides spp*, *Fusobacterium nucleatum*, and *Peptostreptococcus anaerobius* have been identified in patients with poor oral hygiene. Rare PA arises from methicillin-resistant *S. aureus*, *Mycobacterium spp*, *Salmonella spp*, *Neisseria meningitides*, *Treponema pall-*

**Table 1:** Cohort characteristics grouped by incision type. Continuous data are listed as mean  $\pm$  SD. Categorical data are presented as number (percentage). Statistically significant P-values are indicated in bold typeface.

Characteristics	Overall	Mini-Facelift	Modified Blair incision	P value (adjusted odd ratio; 95% confidence interval)
<b>Demographic</b>				
Sample size	120	62	58	N/A
Age at diagnosis	41.7 $\pm$ 18.3	43.1 $\pm$ 17.3	40.1 $\pm$ 19.4	0.4
Age at diagnose > 60 years	29 (24.2)	14 (48.3)	15 (51.7)	0.8 (0.84; 0.36-1.93)
Female gender	60 (50)	29 (48.3)	31 (51.7)	0.6 (0.77; 0.37-1.57)
Metabolic diseases	11 (9.2)	7 (63.6)	4 (36.4)	0.5 (1.72; 0.48-6.21)
<b>Clinical</b>				
Limited mouth opening	23 (19.2)	9 (39.1)	14 (60.9)	0.2 (0.53; 0.21-1.35)
Dysphagia/odynophagia	5 (4.2)	3 (60)	2 (40)	1.0 (1.42; 0.23-8.84)
Reduced/poor general condition	4 (3.3)	2 (50)	2 (50)	1.0 (0.93; 0.13-6.85)
<b>Microbiological</b>				
Gram-positive cocci	68 (56.7)	33 (48.5)	35 (51.5)	0.5 (0.75; 0.36-1.54)
Gram-negative cocci	9 (7.5)	5 (55.6)	4 (44.4)	1.0 (1.18; 0.3-4.64)
Anaerobes	11 (9.2)	5 (45.5)	6 (54.5)	0.8 (0.76; 0.22-2.64)
<i>Burkholderia pseudomallei</i>	4 (3.3)	2 (50)	2 (50)	1.0 (0.9; 0.13-6.85)
<i>Candida albicans</i>	5 (4.2)	2 (40)	3 (60)	0.7 (0.61; 0.1-3.8)
<b>Therapeutic</b>				
Ampicillin/sulbactam	95 (79.2)	50 (52.6)	45 (47.4)	0.8 (1.2; 0.5-2.91)
Clindamycin	12 (10)	5 (41.7)	7 (58.3)	0.6 (0.64; 0.19-2.14)
Others after antibiogram	13 (10.8)	7 (53.8)	6 (46.2)	1.0 (1.1; 0.35-3.5)
Length of hospital stay	9.2 $\pm$ 7.9	8.2 $\pm$ 7.7	10.2 $\pm$ 8	0.2
Length of hospital stay > 7 days	31 (25.8)	17 (27.4)	14 (25.5)	0.8 (1.19; 0.52-2.7)
<b>Postoperative</b>				
Facial paralysis	2 (1.7)	1 (50)	1 (50)	1.0 (0.93; 0.06-15.29)
Re-operation	5 (4.2)	2 (40)	3 (60)	0.7 (0.61; 0.1-3.8)
Complications with evidence of <i>Burkholderia pseudomallei</i>	4 (3.3)	2 (50)	2 (50)	1.0 (0.9; 0.13-6.85)

*idum*, *Bartonella henselae*, *Eikenella corrodens*, *Fusobacterium necrophorum* (Lemierre's disease) and *B. pseudomallei* (melioidosis) (6,8,25). Retrograde infection of the parotid secretory system results from ductal erosion with subsequent bacterial penetration, exudate formation within the parenchyma, and glandular destruction (3,23). Notwithstanding our findings that oral bacteria were commonly found, oral health indices, such as caries prevalence DMFT/DMFS, Community Periodontal Index (CPI), in PA patients are beyond this study's scope.

Similar to results of other studies, diabetes mellitus (DM) was an important risk factors in PA patients (3,7,24,25). It appears clear that DM increases susceptibility to infection and worsens outcomes of infectious diseases. For example, DM patients have a 12-fold increased risk of melioidosis, and over half of the melioidosis cases have diabetes. Main mechanisms are impairment of phagocyte function and adaptive T-cell immunity, chronic hyperactivation of the innate immune response (i.e. polyclonal B-cell stimulation and enhanced antibody production to stimuli), altered skin flora (including increased colonization of *S. aureus*), and antimicrobial resistance (18). It has been believed that pro-

longed usage of broad-spectrum antibiotics in DM patient precipitates selective colonization of the upper respiratory tract with Gram-negative bacteria, e.g. *Klebsiella*, *Pseudomonas*, because the commensals are shed out (3). On the other hand, acute infection leads to hyperglycemia as a consequence of the stress-response activation of the hypothalamic-pituitary-adrenal axis to increase secretion of cortisol and other hormones, which promote peripheral insulin resistance and alter insulin-receptor signaling by pro-inflammatory cytokines (18). Altogether, appropriate blood sugar management is an essential part of successful treatments for PA patients with DM.

Melioidosis has often been reported in farmers, transporters, machine workers and recreation activists in Southeast Asia and Northern Australia, and presents as pneumonia (ca. 15%) and/or multiple soft-tissue abscesses (ca. 20%), especially in DM patients. Bacteremia and septic shock (ca. 20%) are the strong predictors of death with the mortality rates of 33%-65%. Radiological appearances of the melioidosis abscesses vary from large abscesses with the "honeycomb" or "Swiss cheese" appearance to dispersing microabscesses (26.) All of our melioidosis patients were apt to re-operations.

This finding may indicate high virulence of *B. Pseudomallei*, as also described by other authors (23,24,26.) PA arising from this bacterium should therefore be treated cautiously.

If the patient's general health does not suit an invasive treatment, ultrasound-guided emergency needle aspiration of the pus may be able to prevent dissemination of the infection (23,27). Our cohort enrolled only ASA I-II patients; therefore, needle aspiration was not attempted. In another German series (n = 31), all but 4 healed uneventfully after PAD with cIONM. The other four patients underwent superficial parotidectomy because of multiple recurrences of PA (2). To the best of our knowledge, ultrasound-guide PAD appears to be relatively unpopular in this country.

Facial paralysis in PA patients has been sporadically reported in the literature and may occur due to the severity of infection, perineuritis, or nerve compression (6,7). A Taiwanese series demonstrated one of 14 (or 7.1%) patients with temporary facial paralysis (5), and 13% (2/15) in another Malaysian series (3). We found no facial paralysis before the surgery. A possible explanation is that all patients presented to us within a few days after the infection began and the PA sizes were less than 5 cm in preoperative CT. Contrast to postoperative/iatrogenic facial paralysis, facial paralysis due to PA *per se* often resolves spontaneously within a few months after the disease cure. Facial paralysis resistant to therapy is very highly suggestive of parotid malignancy and mandates further workups (6,10).

Dissection, transaction, laceration, clamp compression, retraction, electrocautery, ligature entrapment, suction trauma, or even compressive ischemia can cause iatrogenic facial nerve injury (17). cIONM during parotid surgery allows early nerve identification, forewarns surgeons of unexpected facial nerve stimulation, maps the nerve course, reduces mechanical nerve damage, and helps to evaluate and prognosticate the nerve function at the end of the procedure (15,16.) This real-time monitoring of the facial nerve undoubtedly decreases operation time and increases patient satisfaction (17). Although an elevated nerve response (0.5 mA) could predict postoperative facial nerve paresis at the end of procedure, an absence of an electrically evoked response does not exclude the facial nerve injury (15, 17). The incidence of temporary postoperative facial weakness in our cohort is much lower than that in the recent meta-analysis (1.7% vs. 23.4%, adjusted OR 0.06, 95% CI 0.01 to 0.23,  $P = 0.0001$ ) (16). Possible explanations are that most data in that meta-analysis were based on studies with 2-channel systems during parotidectomy, while we used passive 4 channel-monitoring (electrode placement in the frontal, orbicularis oculi and oris, and mentalis muscles). Our patients with postoperative facial paralysis were conservatively treated with physiotherapy and returned to normal nerve functions within a year.

In Taiwanese, Thai and Malaysian series, trismus was found in 43% (or 6/14), 50% (or 31/62) and 60% (or 9/15) of PA patients, respectively (3,5,25). However, limited mouth opening, swallowing problem and reduced general condition (ECOG/WHO Performance Score Grade 3 or more) in our patients were uncommon. The most likely cause of the discrepancies is that the patients in the abovementioned Asian series came to the treatment later than ours ( $6.3 \pm 6.3$  [Taiwan] vs.  $1.8 \pm 0.6$  [Germany] days; 95% CI 3.28 to 5.61,  $P = 0.0001$ ; Malaysian means: 15.2 days), and had more percentages

of patients with underlying metabolic diseases (40% [Malaysia] vs. 42.9% (Taiwan) vs. 9.2% [Germany]; adjusted OR 0.13, 95% CI 0.04 to 0.46,  $P = 0.0028$ ), probably because we included ASA I-II patients only. This could explain why our patients tended to have shorter hospitalization ( $14 \pm 39.3$  [Taiwan] vs.  $9.2 \pm 7.9$  [Germany] days; 95% CI -3.26 to 12.86,  $P = 0.24$ ; Malaysian means: 14.2 days), albeit not statistically significant. Moreover, our patients did not require advanced airways management. In other words, the German health-care system seems to support a quick referral of problematic patients to specialists.

Our study was limited in several ways, most notably by the retrospective observational study design. Inaccurate charting and missing data cannot be excluded as a possibility in some reviewed cases. Besides, chart reviewing was not blinded. Despite no surgeon variation, we did not analyze the whole patient population in the catchment areas of the studied facilities. The demographic data may be unrepresentative, e.g. how many APP patients developed PA remains unknown, and our results might not be generalized to other patient groups, e.g. those with ASA III-IV and/or advanced infections. Patient satisfaction after PAD is our next research project.

## Conclusion

The results of our study allow us to give strong recommendations in favor of the use of MFL in ASA I-II adult patients undergoing PAD. Both MFL and MBI techniques are low-risk with regard to LHS and postoperative complications. However, it should be borne in mind that the faster the treatment begins, the less chance the patients have of getting complications. DM and melioidosis seem to be important risk factors and require particular attention. Postoperative facial nerve dysfunction after PAD is temporary and diminished after conservative physiotherapy.

**Türkçe özet:** Parotis apsesi drenajı için mini yüz germe tekniği ya da modifiye Blair insizyonu kullanılan hastalarda meydana gelen komplikasyonların ve hastanede kalış süresinin değerlendirilmesi. Amaç: Parotis apse drenajı (PAD) uygulanan yetişkin hastalarda mini yüz germe (MFL) ve modifiye Blair insizyonları (MBI) arasındaki hastanede kalış süresini (LHS) ve komplikasyonları karşılaştırmaktır. Gereç ve yöntem: 7 yıllık bir aralıkta PAH uygulanan 2 sağlıklı yetişkin hasta grubunu (Amerikan Anesteziyoloji Derneği [ASA] durum I-II) içeren retrospektif bir kohort çalışma tasarımı kullanıldı. Birincil öngörücü değişken, insizyon tipi (MFL'ye karşı MBI). Birincil sonuçlar, LHS ve insizyon tipinden kaynaklanan olumsuz komplikasyonlardı. Diğer çalışma değişkenleri demografik, klinik, mikrobiyolojik ve terapötik kategorilere ayrılmıştır. Kohort özelliklerindeki fark, uygun tanımlayıcı tek ve iki değişkenli istatistikler kullanılarak analiz edildi. İnsizyon tipinin LHS üzerindeki etkisini ve olumsuz komplikasyon oranlarını ölçmek için çok değişkenli lojistik regresyon kullanıldı. Bulgular: Örneklem, ortalama yaşı  $41.7 \pm 18.3$  olan 120 deneği (%50 kadın) içermiştir. MFL grubundaki hastalar  $8,2 \pm 7,7$  gün hastanede yatırıldı ve diğer grup  $10,2 \pm 8$  gün hastanede kaldı (düzeltilmiş olasılık oranı [OR] 1.19, %95 güven aralığı [%95 GA] 0.52 ila 2.7;  $P = 0.8$ ). MBI ile karşılaştırıldığında MFL, fasyal paralizi (düzeltilmiş OR 0.93, %95 GA 0.06 ila 15.29;  $P = 1.0$ ) ve yeniden ameliyat gerekliliği (düzeltilmiş OR 0.61, %95 CI 0.1 ila 3.8) açısından komplikasyon risklerini önemli ölçüde artırmadı. ;  $P = 0.7$ ). Sonuç: Hastanede kalış süresi ve komplikasyon riski göz önüne alındığında, MFL, PAH uygulanan ASA I-II yetişkin hastalarda MBI'nin yerini alabilir. Anahtar kelimeler: parotis apsesi; kesi; hastanede kalış; komplikasyon; baş ve boyun enfeksiyonu

**Ethics Committee Approval:** This retrospective cohort study with chart review was approved by the institutional review board, and

the ethical guidelines of the World Medical Association's Declaration of Helsinki and the STROCSS criteria were followed throughout the study.

**Informed Consent:** Participants provided informed consent.

**Peer-review:** Externally peer-reviewed.

**Author contributions:** PPA, NS, KS, JPM, PA, CT, AN participated in designing the study. PPA, NS, KS, JPM, CT, AN participated in generating the data for the study. PPA, NS, KS, PA, CT, AN participated in gathering the data for the study. PPA, NS, KS, JPM, PA, CT, AN participated in the analysis of the data. PPA, AN wrote the majority of the original draft of the paper. PPA, NS, KS, JPM, PA, CT, AN participated in writing the paper. PPA, NS, KS, JPM, PA, CT, AN have had access to all of the raw data of the study. PPA, NS, KS, JPM, PA, CT, AN have reviewed the pertinent raw data on which the results and conclusions of this study are based. PPA, NS, KS, JPM, PA, CT, AN have approved the final version of this paper. PPA, NS, KS, JPM, PA, CT, AN guarantee that all individuals who meet the Journal's authorship criteria are included as authors of this paper.

**Conflict of Interest:** The authors declared that they have no conflict of interest.

**Financial Disclosure:** The authors declared that they have received no financial support.

## References

1. Ord RA. Acute suppurative parotitis. In: Fonseca RJ, Williams TP, Stewart J-CB, editors. *Oral and Maxillofacial Surgery. Volume 5: Surgical Pathology*. 1<sup>st</sup> Ed. Philadelphia: WB Saunders Co., 2000, p. 275-6.
2. Thiede O, Stoll W, Schmal F. Klinische Aspekte der abszedierenden Parotitis. *HNO* 2002;50:332-8. [v](#)
3. Tan VE, Goh BS. Parotid abscess: A five-year review—clinical presentation, diagnosis and management. *J Laryngol Otol* 2007;121:872-9. [\[CrossRef\]](#)
4. Sajjadian A, Magge KT. Salivary gland disorders. In: Guyuron B, Eriksson E, Persing J, Chung KC, Disa JJ, Gosain AK, et al, editors. *Plastic Surgery. Indications and Practice*. 1<sup>st</sup> Ed. Philadelphia: Saunders, 2009, p. 778-86. [\[CrossRef\]](#)
5. Chi TH, Yuan CH, Chen HS. Parotid abscess: A retrospective study of 14 cases at a regional hospital in Taiwan. *B-ENT* 2014;10:315-8. Available at <http://www.b-ent.be/en/parotid-abscess-a-retrospective-study-of-14-cases-at-a-regional-hospital-in-taiwan-16315> (accessed 14 October 2021).
6. Alam M, Hasan SA, Hashmi SF, Singh PK. Facial palsy due to parotid abscess: An unusual complication. *Turk Arch Otorhinolaryngol* 2016;54:168-71. doi: 10.5152/tao.2016.1671. [\[CrossRef\]](#)
7. Kim YY, Lee DH, Yoon TM, Lee JK, Lim SC. Parotid abscess at a single institute in Korea. *Medicine (Baltimore)* 2018;97:e11700. [\[CrossRef\]](#)
8. Porter SR, Fedele S, Mercadante V. Acute suppurative sialadenitis (suppurative parotitis; bacterial sialadenitis; bacterial parotitis). In: Watkinson JC, Clarke EW, Jones TM, Paleri VP, White N, Woolford T, editors. *Scott-Brown's Otorhinolaryngology, Head and Neck Surgery. Volume 3: Head and Neck Surgery, Plastic Surgery*. 8<sup>th</sup> Ed. London: CRC Press, 2019, p. 712-4.
9. Theissing J. Eingriffe beim Parotisabszess. In: Theissing J, Rettinger G, Werner JA, editors. *HNO-Operationslehre*. 4<sup>th</sup> Ed. Stuttgart: Georg Thieme Verlage, 2006, p. 309. [\[CrossRef\]](#)
10. Mydlarz WK, Ha PK, Eisele DW. Bacterial sialadenitis. In: Sataloff RT, Gullane PJ, Goldstein DP, editors. *Sataloff's Comprehensive Textbook of Otolaryngology, Head and Neck Surgery, Vol. 5: Head and Neck Surgery*. New Delhi: Jaypee Brothers Medical Publishers (P) Ltd, 2016, p. 395-6.
11. Atiyeh BS, Dibo S, Papazian N, Zgheib E. Overcoming limitations of short scar minimal access cranial suspension facelift for enhanced rejuvenation. *J Craniofac Surg* 2015;26:800-6. [\[CrossRef\]](#)
12. Antell DE, May JM, Bonnano MJ, Lee NY. A comparison of the full and short-scar face-lift incision techniques in multiple sets of identical twins. *Plast Reconstr Surg* 2016;137:1707-14. [\[CrossRef\]](#)
13. Borges J, Loureiro F. Minilifting technique for treatments of the lower third of the face and anterior cervical neck with tumescent anesthesia. *J Cosmet Dermatol* 2020;19:1208-10. [\[CrossRef\]](#)
14. Van Pham T, Truong KHTN. Short or minimum incision deep plane/extended deep plane facelift/rhytidectomy. *Facial Surg* 2020;36:376-85. [\[CrossRef\]](#)
15. Guntinas-Lichius O, Eisele DW. Facial Nerve Monitoring. *Adv Otorhinolaryngol* 2016;78:46-52. [\[CrossRef\]](#)
16. Stankovic P, Wittlinger J, Georgiew R, Dominas N, Hoch S, Wilhelm T. Kontinuierliches intraoperatives Neuromonitoring (cIONM) in der Kopf-Hals-Chirurgie – eine Übersicht. *HNO* 2020;68:801-9. [\[CrossRef\]](#)
17. Chiesa-Estomba CM, Larruscain-Sarasola E, Lechien JR, et al. Facial nerve monitoring during parotid gland surgery: A systematic review and meta-analysis. *Eur Arch Otorhinolaryngol* 2021;278:933-43. [\[CrossRef\]](#)
18. Dunachie S, Chamnan P. The double burden of diabetes and global infection in low and middle-income countries. *Trans R Soc Trop Med Hyg* 2019;113:56-64. [\[CrossRef\]](#)
19. Wormald R, Donnelly M, Timon C. "Minor" morbidity after parotid surgery via the modified Blair incision. *J Plast Reconstr Aesthet Surg* 2009;62:1008-11. [\[CrossRef\]](#)
20. Riyadh S, Abdulrazaq SS. Assessment of the extracapsular dissection of the benign parotid tumors, extending the literature. *J Oral Maxillofac Surg Med Pathol* 2018;30:86-90. [\[CrossRef\]](#)
21. Agrawal J, Shenai PK, Chatra L, Kumar PY. Evaluation of normal range of mouth opening using three finger index: South India perspective study. *Indian J Dent Res* 2015;26:361-5. [\[CrossRef\]](#)
22. Sok M, Zavrl M, Greif B, Srpcić M. Objective assessment of WHO/ECOG performance status. *Support Care Cancer* 2019;27:3793-8. [\[CrossRef\]](#)
23. Ganesh R, Leese T. Parotid abscess in Singapore. *Singapore Med J* 2005;46:553-6. Available at <https://www.sma.org.sg/smj/4610/4610a5.pdf> (accessed on 14 October 2021).
24. Buaberg S. Comparative study of incision and drainage parotid abscess using long incision and short incision in Yasothon Hospital. *Thai J Otolaryngol Head Neck Surg* 2019;20:46-56. Available at <http://www.rcot.org/2016/assets/pdf/journal-rcot-20-1-2562.pdf> (accessed on 14 October 2021).
25. Wadwongtham W, Cutchavaree A. Parotid abscesses: A ten-year review in King Chulalongkorn Memorial Hospital. *Chula Med J* 1988;42:1069-77. Available at [http://www.clmjournal.org/\\_fileupload/journal/300-2-2.pdf](http://www.clmjournal.org/_fileupload/journal/300-2-2.pdf) (accessed on 14 October 2021).
26. Kingsley PV, Leader M, Nagodawithana NS, Tipre M, Sathiakumar N. Melioidosis in Malaysia: A review of case reports. *PLoS Negl Trop Dis* 2016;10:e0005182. [\[CrossRef\]](#)
27. Scattergood S, Moore S, Prior A, Yusuf GT, Sidhu PS. Percutaneous drainage of a parotid gland abscess under contrast-enhanced ultrasound guidance: A case report. *Ultrasound* 2018;26:182-6. [\[CrossRef\]](#)