

# Vesicobullous disorders of female genitalia

Taru Garg, Saurabh Mittal

Department of Dermatology and STD, Lady Hardinge Medical College and Associated Hospitals, Shaheed Bhagat Singh Marg, New Delhi, India

## Address for correspondence:

Dr. Taru Garg, Department of Dermatology and STD, Lady Hardinge Medical College and Associated Hospitals, Shaheed Bhagat Singh Marg, New Delhi - 110 001, India. E-mail: drtarugarg@rediffmail.com

## Abstract

Blistering over the vulval region can be due to multiple causes, each having nearly a similar presentation. Thus, a thorough understanding of the various etiologies is necessary to make a correct diagnosis. Clinically, there always remains some ambiguity as to the precise diagnosis, thus investigations, such as biopsy, play a very essential role in clinching the correct diagnosis. Most of these disorders are amenable to treatment and thus an early intervention is a must to prevent morbidity associated with these diseases.

**Key words:** Female, genitalia, vesicobullous

## INTRODUCTION

Disorders of female genitalia can present with varying manifestations, being present either as an isolated disorder or as part of a systemic disease. Disorders of female genitalia have always proved confusing to the clinicians as majority of the problems are dermatological, but patients tend to present to other specialties, especially gynecologists, who have had little or no training in dermatology. Almost all types of cutaneous diseases can affect the vulval region.

Vesicobullous diseases are a group of disorders in which a patient presents with fluid-filled lesions.

These can be classified into following types depending upon the etiology:

1. *Autoimmune bullous disorders*: Pemphigus vulgaris (PV), pemphigus vegetans, paraneoplastic pemphigus, bullous pemphigoid (BP), mucous

membrane pemphigoid, linear IgA disease, and epidermolysis bullosa acquisita (EBA).

2. *Genetic bullous disorders*: Epidermolysis bullosa (EB) and Hailey-Hailey disease (HHD).
3. *Inflammatory disorders*: Contact dermatitis (CD).
4. *Drug induced*: Acute disseminated epidermal necrolysis (ADEN) and bullous fixed drug eruption (FDE).
5. *Infectious*: Herpes simplex and herpes zoster.
6. *Miscellaneous*: Lymphangiectasia, lymphangioma, mucinous cysts, erythema multiforme (EM), and lichen sclerosus (LS).

## Autoimmune bullous diseases

These diseases are characterized by pathogenic autoantibodies directed against antigens which are important adhesion molecules in the skin. These are primarily classified into intraepidermal and subepidermal depending upon the level of split.

## *Pemphigus vulgaris*

These disorders are characterized by intraepidermal flaccid blisters and a positive Nikolsky's sign. PV is the most common immunobullous disorder and is primarily a disease of middle age. Its incidence is 0.1-3.2 cases per 100,000 individuals per year.<sup>[1]</sup> Antibodies are directed primarily against the desmoglein 3 antigen,<sup>[2]</sup> but antibodies to

### Access this article online

#### Quick Response Code:



#### Website:

www.ijstd.org

#### DOI:

10.4103/0253-7184.93786

### How to cite this article:

Garg T, Mittal S. Vesicobullous disorders of female genitalia. Indian J Sex Transm Dis 2012;33:1-8.

desmoglein 1 are also found. Blisters in PV are confined to the suprabasal level. All patients have mucosal lesions. Although oral mucosa is most commonly involved (50%-70%), involvement of vulva<sup>[3]</sup> [Figure 1] and cervix<sup>[4]</sup> is also seen in some cases. Localized vulvar pemphigus has been reported due to topical tacrolimus therapy.<sup>[5]</sup> In a study done on 77 females with PV, genital lesions were observed in 39 (51%) patients. Of these, the labia minora were involved in 36 patients (92%), the labia majora in 11 (28%), the vagina in 14 (36%), and the cervix in 6 (15%) patients.<sup>[6]</sup> PV clinically presents as flaccid blisters filled with clear fluid over a normal or an erythematous base which soon rupture to produce painful erosions [Figure 1]. Unusual presentations of genital PV such as desquamative inflammatory vaginitis<sup>[7]</sup> and chronic vaginal discharge have also been described.<sup>[8]</sup> Such cases usually pose a diagnostic dilemma as even histopathology may be inconclusive. Direct immunofluorescence (DIF) plays an essential role in diagnosing such cases. The lesions heal without scarring. Corticosteroids, both topical and systemic, are the mainstay of treatment. A case of squamous cell carcinoma (SCC) arising from vulvar pemphigus has been reported in the literature. The patient also had associated systemic lupus erythematosus, an association described only in five cases till date.<sup>[1]</sup>

Pemphigus vegetans is a variant of pemphigus vulgaris that is characterized by primarily a flexural involvement. Oral mucosa is involved in majority and few cases may have genital involvement as well. Pemphigus vegetans has also been reported as a cause of localized vulvar acantholytic dermatoses. This girl presented with warty lesions over the labium majus whose histopathology and DIF showed typical features of pemphigus.<sup>[9]</sup>

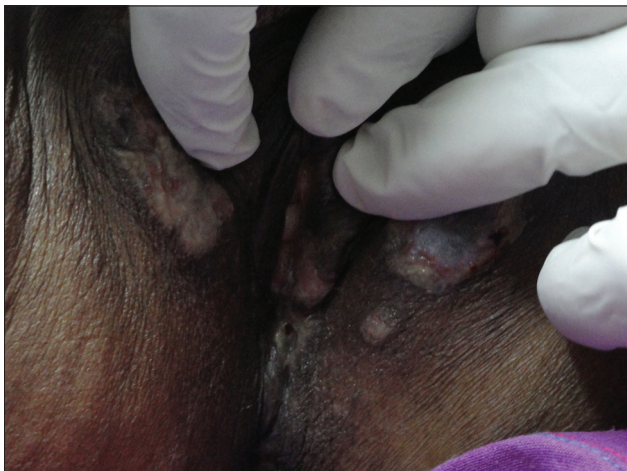

Figure 1: Vulvar involvement in pemphigus vulgaris

### **Pemphigoid**

It is clinically characterized by presence of tense bullae. Mucous membrane involvement is less common than PV; however, intact blisters are also seen rather than only erosions, as in case of PV.

Localized vulvar pemphigoid is a variant of bullous pemphigoid and is a rarely reported entity. It is characterized by recurrent blistering confined to the vulva of young girls and does not result in scarring.<sup>[10,11]</sup>

Mucous membrane pemphigoid, also known as “*cicatricial pemphigoid*” or “*benign mucosal pemphigoid*,” causes recurrent blistering of the mucous membrane or of the skin near one of the orifices along with a tendency to form scars.<sup>[12]</sup> Genitalia are involved in half of the female patients.<sup>[3]</sup> Mucous membrane pemphigoid of the genitalia is manifested by nonspecific erosions, skin fragility, and sometimes intact blisters over clinically hair-bearing skin.<sup>[7]</sup> Complications that ensue are labial fusion, introital shrinkage, and scarring, indistinguishable from LS.<sup>[13]</sup> These can further lead to sexual and urinary problems. Initial therapy is with oral corticosteroids. Lesions may respond to potent topical steroids or to the combination of topical steroids and tetracycline. Adhesions may require surgical division. Success has also been reported with sulfapyridine, minocycline, mycophenolate mofetil, and intravenous immunoglobulin (IVIg).<sup>[14]</sup> Linear IgA mucous membrane pemphigoid is an entity in which patients have typical clinical signs of mucous membrane pemphigoid along with linear IgA on direct immunofluorescence.<sup>[15]</sup> The disease has been described in both children and adults.<sup>[16]</sup>

### **Linear IgA disease of adults**

It commonly occurs after the age of 60 years and is characterized by IgA basement membrane antibodies.<sup>[17]</sup> There is a strong association between linear IgA disease and the extended autoimmune haplotype HLA-B8, -CW7, and -DR3. The major antigen in linear IgA disease is BP180/collagen XVII. Symptoms may vary from mild to severe pruritus and burning. The trunk is almost always affected. Mucosal lesions are common<sup>[17]</sup> and involvement of the genitalia can also occur. Spontaneous remission occurs in the majority after an average of 3-6 years, the TNF genotype of the patient affects disease duration.<sup>[18]</sup> The disease responds favorably to dapsone.

### **Genetic bullous diseases**

These are characterized by genetically determined structural abnormalities in the dermoepidermal junction.

### *Epidermolysis bullosa*

EB comprises a group of genetically determined skin fragility disorders characterized by blistering of skin and mucosae following mild mechanical trauma, thus they are also known as “*mechanobullous diseases*.” Involvement of the genitourinary tract has been described in many types of EB.<sup>[19]</sup> Depending upon the ultrastructural level of tissue cleavage, they are grouped into three types: EB simplex (split through basal layer), junctional EB (split through lamina lucida), and dystrophic EB (split through sublamina-densa).

EB simplex, inherited in an autosomal dominant manner, usually does not involve the mucosae except for the Dowling-Meara type which is the most severe form of EB simplex. Early involvement of mucous membranes is there, which heal with scarring and milia formation.

Mucosal involvement is seen in both types of junctional EB, i.e., Herlitz and non-Herlitz variety, an autosomal recessive disorder.

Dystrophic EB is the most severe variety in which there's a mutation in the anchoring fibril protein, type VII collagen. It is characterized by skin fragility, blistering, scarring, nail changes, and milia formation. In the severe generalized recessive dystrophic EB (Hallopeau-Siemens type), blistering, erosions, and painful fissures may develop which later lead to stenosis due to scarring. An important sequel of this form is the development of SCC; these are aggressive and often metastasize.<sup>[20,21]</sup> In the non-Hallopeau-Siemens dystrophic EB, findings are similar but milder.

Although skin biopsy may clinch the diagnosis in a few cases but electron microscopy (EM) is diagnostic. No specific treatment is as yet available but gene therapy might prove to be helpful in the near future.<sup>[22-25]</sup> Till then, the most important approach to such children is prevention of trauma.

### *Hailey-Hailey disease*

Also known as familial benign chronic pemphigus, it is an autosomal dominant intraepidermal blistering disease characterized by recurrent vesicles and erosions affecting the neck, axillae, and groins.<sup>[26]</sup> The disease is caused by mutations in the ATP2C1 gene. The disease usually presents in the 3<sup>rd</sup> or 4<sup>th</sup> decade with flaccid vesicopustules, crusted erosions, or expanding circinate plaques in areas exposed to friction.<sup>[27,28]</sup> Mucosal involvement is rare but vaginal involvement has been described.<sup>[28]</sup> Lesions presenting exclusively in the vulval region have also been described.<sup>[29]</sup> HHD at times may also present

atypically as leukoplakia<sup>[30]</sup> or candidiasis.<sup>[31]</sup> Rarely SCC arising both in the skin<sup>[32]</sup> as well as vulvar lesions<sup>[33]</sup> of HHD has been reported. A report of SCC following topical tacrolimus therapy has also been described.<sup>[30]</sup>

### **Inflammatory diseases**

#### *Contact dermatitis*

Contact dermatitis of the vulva is common, with irritant CD occurring more frequently than allergic CD.<sup>[34]</sup> CD usually occurs when there is an impairment of the barrier function.<sup>[35,36]</sup> This may occur because of dampness and maceration secondary to a heavy vaginal discharge, or increased contact with urine in an incontinent patient. Agents usually responsible for irritant dermatitis are cleansing agents, bubble baths, disinfectants, lubricants, perfumed products, deodorants, and medicaments. Mostly, it presents as an eczematous eruption but in severe cases, vesicobullous lesions may be seen.

### **Drug induced**

#### *Acute disseminated epidermal necrolysis*

The term ADEN was first proposed by Ruiz-Maldonado<sup>[37]</sup> to encompass two life-threatening mucocutaneous reactions: Steven-Johnsons syndrome (SJS) and toxic epidermal necrolysis (TEN). SJS involves <10% of body surface area (BSA), whereas TEN involves >30% BSA. ADEN clinically begins within 8 weeks of drug exposure (usually 4-30 days). Nonspecific constitutional symptoms may precede the mucocutaneous lesions by 1-3 days. Mucosal involvement is seen in nearly 90% of cases.<sup>[38]</sup> Genital lesions are frequent leading to dysuria; retention of urine may occur, as may involvement of the bladder. Renal damage may occur as a complication of genital lesions, and can prove fatal if not recognized in time. Systemic steroids are the most commonly employed agents for treatment. IVIg is the most specific treatment, but is expensive. Immunosuppression by these agents may minimize severity if instituted in the first 24-48 hours.<sup>[39]</sup>

#### *Bullous-fixed drug eruption*

FDE occurs more commonly over the penis than vulva. The most common medications responsible include acetaminophen, barbiturates, nonsteroidal anti-inflammatory drugs including salicylates, oral contraceptives, penicillins, tetracyclines, phenolphthalein, and sulfonamides.<sup>[40,41]</sup> One or a few blisters or erosions ranging from 1 to 3 cm appear within 1-2 days following ingestion of the offending medication. Subsequent exposure to the medication produces recurrence of lesions precisely at the same location and occasionally at additional areas



as well. FDE of the genitalia preferentially affects non-hair-bearing skin of the vulva. Postinflammatory hyperpigmentation generally does not occur on these areas.

## Infectious disease

### *Vulval herpes*

It is caused by herpes simplex virus type I and II, latter being more commonly found. 95% infections are acquired sexually. Typical lesions are closely aggregated vesicles, filled with clear fluid, which later rupture to form erosions or ulcers [Figure 2]. Lesions are symptomatic most of the times in the form of pain, burning, or itching. Urinary retention may occur either due to affection of the nerve segments S2-4 or due to pain and edema. A case report of atypical genital herpes simulating PV has been published, where DIF and indirect immunofluorescence studies were consistent with diagnosis of pemphigus.<sup>[42]</sup>

Definitive diagnosis is possible only by a viral culture. Treatment involves prescribing acyclovir 400 mg three times a day or acyclovir 200 mg five times a day, for 5-7 days. Recalcitrant and recurrent cases may require prolonged doses of antivirals.

### *Herpes Zoster*

It is caused by reactivation of the Varicella-Zoster virus leading to eruption of vesicobullous lesions in a dermatomal fashion. Involvement of the vulva may occur if the 3<sup>rd</sup> sacral dermatome is involved and may also be accompanied by bladder and bowel dysfunction.<sup>[43]</sup>

## Miscellaneous

### *Lymphangioma*

Lymphangiomas are malformations of the lymphatic system giving rise to vesicles filled with clear

fluid. Vulval lymphangiomas are of two types: Lymphangioma circumscriptum and cavernous lymphangioma. The former appear as localized thin-walled vesicles which are aggregated together and the latter one arises in childhood and presents as a soft compressible mass. It may even involve the whole vulva.<sup>[44]</sup> Vulval lymphangiomas are rare. Thirteen cases of the congenital and 24 cases of acquired form of lymphangiomas have been reported in the literature presently.<sup>[45]</sup> Surgical resection is an effective and well-tolerated therapy for vulval lymphangioma circumscriptum in most women. Lesion recurrence is frequent but resection can be repeated several times with no adverse effects.<sup>[46]</sup>

### *Lymphangiectasia*

It is an acquired dilatation of the cutaneous lymphatics secondary to obstruction of the lymphatic vessels. It may occur secondary to treatment of cervical carcinoma with surgery and/or radiotherapy,<sup>[47-49]</sup> Crohn's disease and in pregnant females. A case report of lymphangiectasia as a sequel of primary chylous reflux has also been published.<sup>[50]</sup> Repeated episodes of cellulitis may also occur in lymphangiectasia; however, there may be an underlying abnormality of the lymphatics that predisposes to cellulitis.

### *Mucinous cysts*

Vulval mucinous cysts are not uncommon. They are usually found on the vestibule where they develop secondary to obstruction of the duct of one of the many minor vestibular mucus-secreting glands. They are of urogenital sinus origin.<sup>[51,52]</sup>

### *Erythema multiforme*

It is an acute self-limited, usually mild, and often recurrent mucocutaneous disease. There are four subtypes:<sup>[53]</sup>

- EM minor: Only cutaneous lesions.
- EM major: Cutaneous lesions with mucosal involvement.
- Herpes associated EM.
- Mucosal EM (Fuchs syndrome): Only mucosal involvement.

Most common cause of EM is infection, most commonly herpes simplex. *M. pneumoniae* is the most common cause in children.<sup>[54,55]</sup> Cutaneous lesions present typically as "target or iris" lesions. Mucosal lesions occur in 70% of cases, most commonly limited to the oral mucosa. Genitalia are rarely involved in EM. "Ectodermosis pluriorificialis" or "Fuchs syndrome" is characterized by severe

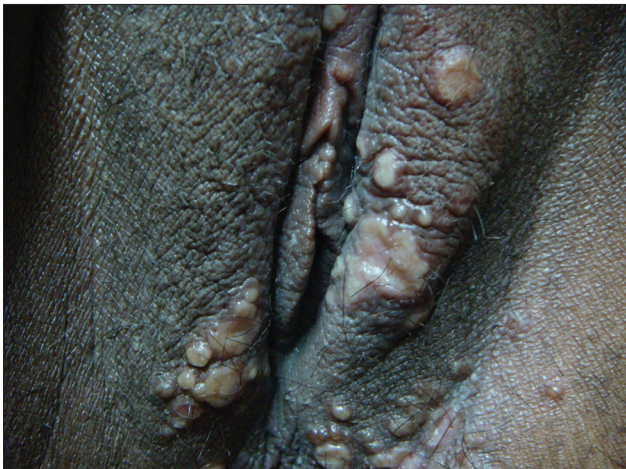

Figure 2: Vesicles and erosions in herpes genitalis

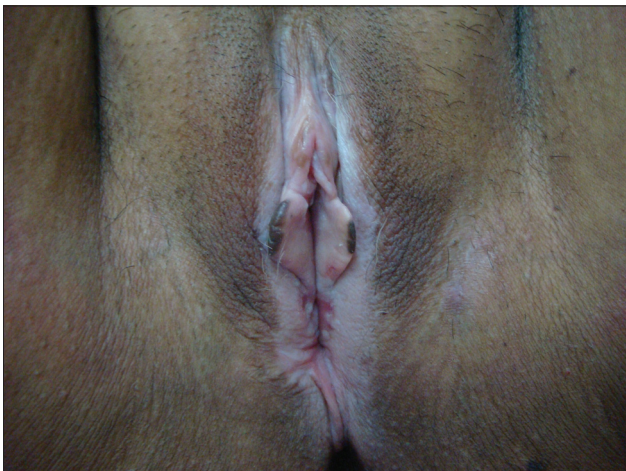
involvement of two or three mucosal sites in the absence of skin lesions.

### *Lichen sclerosus*

The condition was initially described as a variant of lichen planus and was earlier known by varied names such as “*leukoplakia*,” “*leukoplakic vulvitis*,” and “*kraurosis vulvae*.”<sup>[56]</sup> These terms have now been abandoned to avoid any confusion. Exact etiology of the condition is not known, but it is believed to be an autoimmune disorder which is genetically determined.<sup>[57]</sup> The disease can affect females of any age but majority are either prepubertal or postmenopausal. Presenting symptom is usually severe itching, but few cases might be asymptomatic. The disease usually presents with atrophic whitened epithelium [Figure 3], but rarely bullae may occur. These later ulcerate and heal with scarring. Complications thereby ensue such as disfigurement and introital narrowing. Vulval LS is also associated with malignancy such as SCC.<sup>[58]</sup> Topical steroids are the mainstay of treatment.

### *Pyodermatitis-pyostomatitis vegetans*

The disorder is also known as “*blastomycosis-like pyoderma*.”<sup>[59]</sup> It most commonly presents as a verrucous plaque studded with pustules, thus mimicking pyoderma gangrenosum, especially of the vegetans type. When the lesions are localized to the oral mucosa, it is known as “*pyostomatitis vegetans*.” Such cases mostly occur in association with IBD. Besides oral mucosa, involvement of vulval mucosa has also been described. It may be the presenting symptom or may get involved later during the course of the disease.<sup>[60]</sup> Histology shows eosinophilic spongiosis with eosinophilic microabscesses and pseudoepitheliomatous hyperplasia. Direct immunofluorescence is negative.



**Figure 3: Atrophic whitish plaque of lichen sclerosus**

A predominant neutrophilic infiltrate may also be seen.

Vesicobullous disorders of the female genitalia can include a multitude of dermatological entities with nearly similar presentation. Thus, a careful and watchful approach toward such patients is necessary in order to arrive at the correct diagnosis. Besides clinical examination, histopathology and DIF also plays an important role in making a diagnosis.

## REFERENCES

1. Bifulco G, Mandato VD, Piccoli R, Giampaolino P, Mignogna C, Mignogna MD, *et al*. Early invasive vulvar squamous cell carcinoma arising in a woman with vulvar pemphigus vulgaris and systemic lupus erythematosus. *BMC Cancer* 2010;10:324.
2. Amagai M, Klaus-Kovtun V, Stanley JR. Autoantibodies against a novel epithelial cadherin in pemphigus vulgaris, a disease of cell adhesion. *Cell* 1991;67:869-77.
3. Marren P, Wojnarowska F, Venning V, Wilson C, Nayar M. Vulvar involvement in auto-immune bullous diseases. *J Reprod Med* 1993;38:101-7.
4. Sagher F, Bercovici B, Romen R. Nikolsky sign on cervix uteri in pemphigus. *Br J Dermatol* 1974;90:407-11.
5. Campagne G, Roca M, Martínez A. Successful treatment of a high-grade intraepithelial neoplasia with imiquimod, with vulvar pemphigus as a side effect. *Eur J Obstet Gynecol Reprod Biol* 2003;109:224-7.
6. Akhyani M, Chams-Davatchi C, Naraghi Z, Daneshpazhooh M, Toosi S, Asgari M, *et al*. Cervicovaginal involvement in pemphigus vulgaris: A clinical study of 77 cases. *Br J Dermatol* 2008;158:478-82.
7. Murphy R. Desquamative inflammatory vaginitis. *Dermatol Ther* 2004;17:47-9.
8. Batta K, Munday PE, Tamall FM. Pemphigus vulgaris localized to the vagina presenting as chronic vaginal discharge. *Br J Dermatol* 1999;140:945-7.
9. Wong KT, Wong KK. A case of acantholytic dermatosis of the vulva with features of pemphigus vegetans. *J Cutan Pathol* 1994;21:453-6.
10. Kirtschig G, Wojnarowska F, Marsden RA, Edwards S, Bhogal B, Black MM. Acquired bullous diseases of childhood: Re-evaluation of diagnosis by indirect immunofluorescence examination on 1 M NaCl split skin and immunoblotting. *Br J Dermatol* 1994;130:610-6.
11. Farrell AM, Kirtschig G, Dalziel KL, Allen J, Dootson G, Edwards S, *et al*. Childhood vulval pemphigoid: A clinical and immunopathological study of five patients. *Br J Dermatol* 1999;140:308-12.
12. Hardy KM, Perry HO, Pingree GC, Kirby TJ Jr. Benign mucous membrane pemphigoid. *Arch Dermatol* 1971;104:467-75.
13. Marren P, Walkden V, Mallon E, Wojnarowska F. Vulval cicatricial pemphigoid may mimic lichen sclerosus. *Br J Dermatol* 1996;134:522-4.
14. Kirtschig G, Murrell D, Wojnarowska F, Khumalo N. Interventions for mucous membrane pemphigoid/cicatricial pemphigoid and epidermolysis bullosa acquisita: A systematic literature review. *Arch Dermatol* 2002;138:380-4.
15. Chan LS, Ahmed AR, Anhalt GJ, Bernauer W, Cooper KD, Elder MJ, *et al*. The first international consensus on mucous membrane pemphigoid: Definition, diagnostic criteria, pathogenic factors, medical treatment, and prognostic indicators. *Arch Dermatol* 2002;138:370-9.
16. Wojnarowska F, Marsden RA, Bhogal B, Black MM. Childhood cicatricial pemphigoid with linear IgA deposits. *Clin Exp Dermatol* 1984;9:407-15.

17. Wojnarowska F, Marsden RA, Bhogal B, Black MM. Chronic bullous disease of childhood, childhood cicatricial pemphigoid and linear IgA disease of adults, a comparative study demonstrating clinical and immunopathological overlap. *J Am Acad Dermatol* 1988;19:792-805.
18. Collier PM, Wojnarowska F, Welsh K, McGuire W, Black MM. Adult linear IgA disease and chronic bullous disease of childhood: The association with human leucocyte antigens, Cw7, B8, HLA DR3, and tumour necrosis factor influences disease expression. *Br J Dermatol* 1999;141:867-75.
19. Almaani N, Mellerio JE. Genitourinary tract involvement in epidermolysis bullosa. *Dermatol Clin* 2010;28:343-6.
20. Fine JD, Johnson LB, Suchindran C. Cancer and inherited EB: The NEBR experience. In: Fine JD, Baurer EA, McGuire J, Moshell A. *Epidermolysis Bullosa: Clinical, Epidemiologic, and Laboratory Advances, and the findings of the National Epidermolysis Bullosa Registry*. Baltimore: John Hopkins University Press; 1999. p. 175-92.
21. Fine JD, Johnson LB, Suchindram C. Premature death and inherited EB: Contingency table and life table analysis of the NEBR study population. In: Fine JD, Baurer EA, McGuire J, Moshell A, editors. *Epidermolysis Bullosa: Clinical, Epidemiologic, and Laboratory Advances, and the findings of the National Epidermolysis Bullosa Registry*. Baltimore: John Hopkins University Press; 1999. p. 206-24.
22. Chen M, Kasahara N, Keene DR, Chan L, Hoeffler WK, Finlay D, *et al*. Restoration of type VII collagen expression and function in dystrophic epidermolysis bullosa. *Nat Genet* 2002;32:670-5.
23. Ortiz-Urda S, Lin Q, Green CL, Keene DR, Marinkovich MP, Khavari PA. Injection of genetically engineered fibroblasts corrects regenerated human epidermolysis bullosa skin tissue. *J Clin Invest* 2003;111:251-5.
24. Ortiz-Urda S, Thyagarajan B, Keene DR, Lin Q, Fang M, Calos MP, *et al*. Stable non-viral genetic correction of inherited human skin disease. *Nat Med* 2002;8:1166-70.
25. Dellambra E, Pellegrini G, Guerra L, Ferrari G, Zambruno G, Mavilio F, *et al*. Toward epidermal stem cell-mediated *ex vivo* gene therapy of junctional epidermolysis bullosa. *Hum Gene Ther* 2000;11:2283-7.
26. Hailey, Hailey H. Familial benign chronic pemphigus. *Arch Dermatol Syphilol* 1939;39:679-85.
27. Palmer D, Perry H. Benign familial chronic pemphigus. *Arch Dermatol* 1962;86:493-502.
28. Burge SM. Hailey-Hailey disease: The clinical features, response to treatment and prognosis. *Br J Dermatol* 1992;126:275-82.
29. von Felbert V, Hampl M, Talhari C, Engers R, Megahed M. Squamous cell carcinoma arising from a localized vulvar lesion of Hailey-Hailey disease after tacrolimus therapy. *Am J Obstet Gynecol* 2010;203:e5-7.
30. Evron S, Leviatan A, Okon E. Familial benign chronic pemphigus appearing as leukoplakia of the vulva. *Int J Dermatol* 1984;23:556-7.
31. Misra R, Ramon M, Singh N, Agarwal N. Hailey-Hailey disease masquerading as candidiasis. *Int J Gynaecol Obstet* 1993;42:51-2.
32. Holst VA, Fair KP, Wilson BB, Patterson JW. Squamous cell carcinoma arising in Hailey-Hailey disease. *J Am Acad Dermatol* 2000;43(2 Pt 2):368-71.
33. Cockayne SE, Rassl DM, Thomas SE. Squamous cell carcinoma arising in Hailey-Hailey disease of the vulva. *Br J Dermatol* 2000;142:540-2.
34. Schlosser BJ. Contact dermatitis of the vulva. *Dermatol Clin* 2010;28:697-706.
35. Britz MB, Maibach HI. Human cutaneous vulvar reactivity too irritants. *Contact Dermatitis* 1979;5:375-7.
36. Elsner P, Wilhelm D, Maibach HI. Multiple parameter assessment of vulvar irritant contact dermatitis. *Contact Dermatitis* 1990;23:20-6.
37. Ruiz-Maldonado R. Acute disseminated epidermal necrosis types 1, 2, and 3: Study of sixty cases. *J Am Acad Dermatol* 1985;13:623-35.
38. Ashby DW, Lazar T. Erythema multiforme exudativum major (Stevens-Johnson syndrome). *Lancet* 1951;1:1091-5.
39. Chave TA, Mortimer NJ, Sladden MJ, Hall AP, Hutchinson PE. Toxic epidermal necrolysis: Current evidence, practical management and future directions. *Br J Dermatol* 2005;153:241-53.
40. Sehgal VN, Gangwani OP. Genital fixed drug eruption. *Genitourin Med* 1986;62:56-8.
41. Ozkaya-Bayazit E. Specific site involvement in fixed drug eruption. *J Am Acad Dermatol* 2003;49:1003-7.
42. Kalajian AH, Callen JP. Atypical herpes simplex infection masquerading as recalcitrant pemphigus vulgaris. *Australas J Dermatol* 2007;48:242-7.
43. Fugelso PD, Newman SB, Beamer JE. Herpes zoster of the anogenital area affecting urination and defecation. *Br J Dermatol* 1973;89:285-8.
44. Brown JV, Stenchever MA. Caverosus lymphangioma of the vulva. *Obstet Gynecol* 1989;73:877-9.
45. Ghaemmaghami F, Karimi Zarchi M, Mousavi A. Major labiaectomy as surgical management of vulvar lymphangioma circumscriptum: Three cases and a review of the literature. *Arch Gynecol Obstet* 2008;278:57-60.
46. Vignes S, Arrault M, Trévidic P. Surgical resection of vulva lymphoedema circumscriptum. *J Plast Reconstr Aesthet Surg* 2010;63:1883-5.
47. LaPolla J, Foucar E, Leshin B, Whitaker D, Anderson B. Vulvar lymphangioma circumscriptum: A rare complication of therapy for squamous cell carcinoma of the cervix. *Gynecol Oncol* 1985;22:363-6.
48. Handfield-Jones SE, Prendeville WL, Norman S. Vulval lymphangiectasia. *Genitourin Med* 1989;65:335-7.
49. Fisher I, Orkin M. Acquired lymphangioma (lymphangiectasis) Report of a case. *Arch Dermatol* 1970;101:230-4.
50. Huang HY, Chiu WT. Primary chylous reflex presenting with vulvar vesicles. *Arch Dermatol* 2010;146:683-4.
51. Robboy SJ, Ross JS, Prat J, Keh PC, Welch WR. Urogenital sinus origin of mucinous and ciliated cysts of the vulva. *Obstet Gynecol* 1978;51:347-51.
52. Oi RH, Munn R. Mucous cysts of the vulvar vestibule. *Hum Pathol* 1982;13:584-6.
53. Roujeau JC. Erythema Multiforme. In: Wolff K, Goldsmith LA, Katz SI, Gilchrist BA, Paller AS, Leffell DJ. *Fitzpatrick's Dermatology in General Medicine* 7<sup>th</sup> edn. USA: McGraw-Hill Companies; 2008. 343-9.
54. Forman R, Koren G, Shear NH. Erythema multiforme, Stevens-Johnson syndrome and toxic epidermal necrolysis in children: A review of 10 years' experience. *Drug Saf* 2002;25:965-72.
55. Lam NS, Yang YH, Wang LC, Lin YT, Chiang BL. Clinical characteristics of childhood erythema multiforme, Stevens-Johnson syndrome and toxic epidermal necrolysis in Taiwanese children. *J Microbiol Immunol Infect* 2004;37:366-70.
56. Tremaine RD, Miller RA. Lichen sclerosus et atrophicus. *Int J Dermatol* 1989;28:10-6.
57. Friedrich EG Jr, MacLaren NK. Genetic aspects of vulvar lichen sclerosus. *Am J Obstet Gynecol* 1984;150:161-6.
58. Zaki I, Dalziel KL, Solomonsz FA, Stevens A. The under-reporting of skin disease in association with squamous cell carcinoma of the vulva. *Clin Exp Dermatol* 1996;21:334-7.
59. Su WP, Duncan SC, Perry HO. Blastomycosis-like pyoderma. *Arch Dermatol* 1979;115:170-3.
60. Nigen S, Poulin Y, Rochette L, Lévesque MH, Gagné E. Pyodermatitis-pyostomatitis vegetans: Two cases and a review of the literature. *J Cutan Med Surg* 2003;7:250-5.

**Source of Support:** Nil. **Conflict of Interest:** None declared.



## Multiple Choice Questions

- Q1. Urinary retention in cases of genital herpes may occur following involvement of which nerves?
- S1-3
  - S2-4
  - S3-5
  - S4-6
- Q2. All of the following can present as vesicular lesions in the vulvar region except
- Lichen sclerosus
  - Psoriasis
  - Fixed drug eruption
  - Contact dermatitis
- Q3. A 27-year-old pregnant female presented with multiple asymptomatic vesicles over her labia majora, for the past 1 month. The probable diagnosis in this patient is
- Lymphangiectasia
  - Contact dermatitis
  - Folliculitis
  - Pemphigus vulgaris
- Q4. A 50-year-old female presented with severely pruritic vesicular eruption on the 2<sup>nd</sup> postoperative day after a vaginal hysterectomy. The most likely cause is
- Pemphigus vulgaris
  - Scabies
  - Contact dermatitis
  - Lichen planus
- Q5. Which of the following vesicobullous disorder of vulva is genetically determined?
- Pemphigus vulgaris
  - Hailey-Hailey disease
  - Pyodermatitis-pyostomatitis vegetans
  - Fuchs syndrome
- Q6. All of the following vesicular conditions of the vulva have been reported to develop secondary malignancy except
- Lichen sclerosus
  - Hailey-Hailey disease
  - Pemphigus vulgaris
  - Erythema multiforme
- Q7. Steroids, oral or topical, are the preferred modality of treatment in all of the following except
- Linear IgA disease of adults
  - Mucous membrane pemphigoid
  - Lichen sclerosus
  - Contact dermatitis
- Q8. DIF (direct immunofluorescence) is a useful investigation in diagnosis of following vesicobullous disorders involving genitalia
- Pemphigus vulgaris
  - Bullous pemphigoid
  - Linear IgA disease
  - Dystrophic epidermolysis bullosa

Q9. Which statement isn't true for vulvar mucinous cysts?

- a. Usually found on vestibule
- b. Develop secondary to obstruction of minor mucus secreting gland
- c. Originate from the urogenital sinus
- d. None of these

Q10. Dapsone is the preferred treatment for which of the following vesicobullous disease?

- a. Linear IgA disease
- b. Pemphigus vulgaris
- c. Bullous pemphigoid
- d. Hailey-Hailey disease

Answers:  
1. (b)  
2. (b)  
3. (a)  
4. (c)  
5. (b)  
6. (d)  
7. (a)  
8. (a)  
9. (d)  
10. (a)