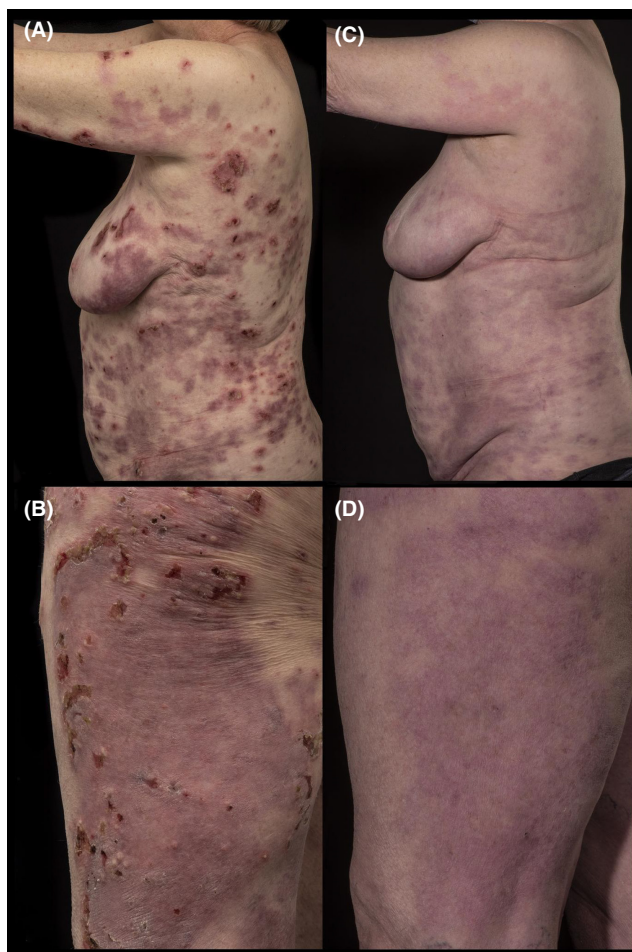


**CORRIGENDUM**

In the article entitled “Linear IgA/IgG bullous dermatosis successfully treated with omalizumab: A case report”<sup>1</sup> which was previously published in Volume 10 Issue 3 of Clinical Case Reports, the part figures 2b and 2c were wrongly swapped in the published version. The correct images are presented below:



In addition, the following sentence in the Discussion section was wrong: “Consequently, we did try other antibiotics to achieve disease control.”

It should read as follows: “Consequently, we did not try other antibiotics to achieve disease control.”

**REFERENCE**

1. Haulrig MB, Nielsen SL, Elberling J, Skov L. Linear IgA/IgG bullous dermatosis successfully treated with omalizumab: a case report. *Clin Case Rep.* 2022;10:e05368. doi:[10.1002/ccr3.5368](https://doi.org/10.1002/ccr3.5368)

This is an open access article under the terms of the Creative Commons Attribution-NonCommercial-NoDerivs License, which permits use and distribution in any medium, provided the original work is properly cited, the use is non-commercial and no modifications or adaptations are made.

© 2022 The Authors. *Clinical Case Reports* published by John Wiley & Sons Ltd.