

CASE REPORT

# Obscure gastrointestinal bleeding with negative abdominal computed tomography study: The importance of enteroscopy for early diagnosis of small bowel malignancy

Meng-Yu Ko,\* Chi-En Yen\* and Hsu-Heng Yen† 

\*Department of Internal Medicine and †Division of Gastroenterology and Hepatology, Changhua Christian Hospital, Changhua, Taiwan

## Key words

capsule endoscopy, enteroscopy, obscure gastrointestinal bleeding, small bowel cancer.

Accepted for publication 18 January 2019.

## Correspondence

Hsu-Heng Yen, Department of Gastroenterology and Hepatology, Changhua Christian Hospital, No 135 Nanhsiao Street, Changhua, Taiwan.  
Email: 91646@cch.org.tw

**Author contribution:** Dr. Meng-Yu Ko and Dr Chi-En Yen contributed equally to the manuscript. Meng-Yu Ko contributed in drafting, writing, and final approval of the manuscript.

**Declaration of conflict of interest:** The authors have no conflicts of interest to disclose.

**Funding support:** Changhua Christian Hospital105-IRP-CCH-009 and 106-CCHIRP-030

## Abstract

Small bowel tumors are rare among all gastrointestinal (GI) cancers. The most common histological subtype is adenocarcinoma. Adenocarcinoma of the small bowel is difficult to diagnose, often presents at a late stage, and has a poor prognosis. We describe a case of a patient with adenocarcinoma of the small intestine who presented to the hospital with nonspecific GI symptoms and obscure GI bleeding. An initial examination using abdominal computed tomography revealed negative findings. The patient underwent subsequent enteroscopy with capsule endoscopy and double-balloon endoscopy, and an early-stage jejunal adenocarcinoma was finally diagnosed.

## Introduction

Small bowel cancer is a rare malignancy that constitutes <5% of all gastrointestinal (GI) malignancies. Small bowel cancers exhibit the following four common histological types: adenocarcinomas, carcinoids, sarcomas, and lymphomas. Adenocarcinoma represents the most common type, accounting for almost 50% of malignancies detected in this part of the GI tract.<sup>1,2</sup> It is generally located in the duodenum (57%), while 29% of cases are located in the jejunum and 10% in the ileum.<sup>1,3</sup> Small bowel cancer is asymptomatic during its first stage. Because of its nonspecific symptoms, such as nausea, vomiting, weight loss, anemia, pain in the abdominal cavity, diarrhea, GI bleeding, and intestinal obstruction, its diagnosis is often delayed by months or even years. As a consequence of the rarity of this cancer, there are no good screening methods available for its detection. Here, we describe the case of a patient with obscure gastrointestinal bleeding (OGIB) caused by a small intestinal tumor. The latter was preoperatively diagnosed by video capsule endoscopy (VCE) and double-balloon endoscopy (DBE).

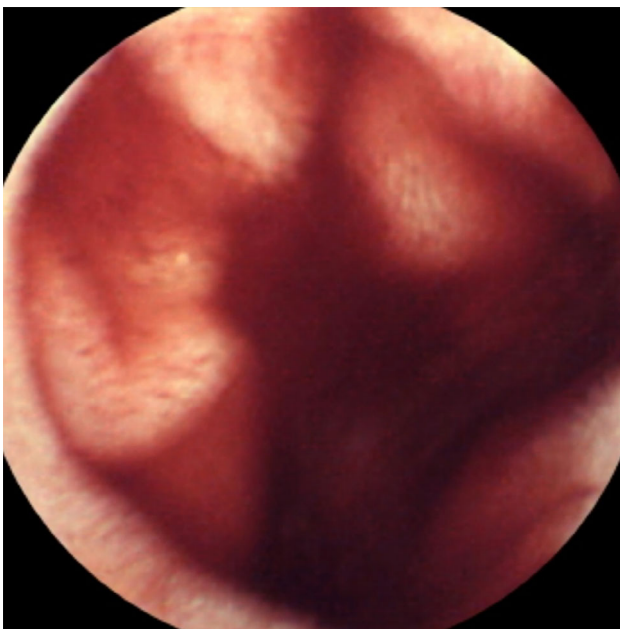## Case Presentation

A 58-year-old male presented to our emergency department complaining of black stools and anemia. His medical history was characterized by coronary artery disease, hypertension, and hyperlipidemia. The patient was being treated for coronary artery disease with antiplatelet therapy (aspirin 100 mg/day). He visited our emergency department because of chest tightness. The patient denied having cold sweating, radiating pain, back pain, dyspnea, and fever in the recent past. Electrocardiography demonstrated normal sinus rhythm and no ST-T-wave abnormalities. Physical examination demonstrated soft abdomen with no tenderness. In addition, abdomen palpation did not demonstrate the presence of a mass. Laboratory tests were indicative of normocytic anemia (hemoglobin 12.8 g/dL, normal 14.0–17.0 g/dL). The results of other laboratory tests were unremarkable. We could not identify the source of bleeding through esophagogastroduodenoscopy (EGD) and colonoscopy. The patient developed persistent black stools with fresh blood. In addition, his hemoglobin level decreased from 12.8 to 11.1 g/dL; therefore, he was admitted for further management. Contrast-enhanced abdominal computed

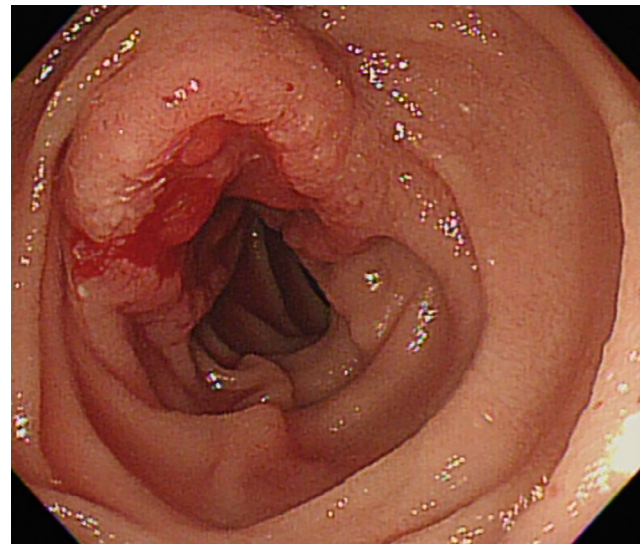
tomography (CT) scan demonstrated no evidence of active contrast medium extravasation, small bowel tumor, or hematoma formation. We detected the presence of a diverticulum in the second portion of the duodenum. Therefore, we performed VCE to assess his small intestine. The latter showed shallow gastric ulcers, gastric erosions, and bleeding in the proximal jejunum (Fig. 1). Subsequently, DBE performed via the oral route demonstrated a 2-cm bleeding ulcerative tumor over the proximal jejunum (Fig. 2). A biopsy was performed, and the patient was endoscopically treated with argon plasma coagulation for hemostasis. Clips were used to mark the lesion. Pathological examination of the ulcerative tumor demonstrated adenocarcinoma. The patient was discharged in a stable status. He subsequently visited another hospital for surgery. A stage 1 adenocarcinoma was finally diagnosed.

## Discussion

Small bowel carcinoma is rare compared with gastric and colorectal cancers. The small bowel constitutes 75% of the GI tract length and 90% of the mucosal surface area. However, only <2% of GI malignancies arise from the small intestine.<sup>4,5</sup> Small intestinal adenocarcinoma shows geographic variation. Specifically, it has low prevalence in Asia compared to North America, Northern Europe, or Oceania.<sup>6</sup> Males have a higher predisposition to these malignancies. Moreover, increasing age is associated with a higher incidence of such tumors.<sup>1,4,5,7</sup> The following are the most common histological types of small bowel cancers: adenocarcinomas (30–40%), carcinoid tumors (35–42%), lymphomas (15–20%), and sarcomas (10–15%).<sup>7</sup> Individuals with small bowel adenocarcinomas initially present nonspecific abdominal discomfort. As a consequence, the diagnosis is delayed and usually made in the context of an emergency involving an occlusion (40%) or bleeding (24%).<sup>5,7</sup> Additional nonspecific symptoms



**Figure 1** Video capsule endoscopy showing blush of blood in the proximal jejunum.



**Figure 2** Double-balloon endoscopy showing a 2-cm bleeding ulcerative tumor over the proximal jejunum.

include nausea, vomiting, weight loss, abdominal pain, and anemia. During physical examination, it is rare to identify a palpable abdominal mass or tender abdomen, possibly with peritoneal signs caused by obstruction or perforation.

CT scans have an overall accuracy rate of 47% for the diagnosis of small bowel adenocarcinomas.<sup>8</sup> However, the latter does not accurately evaluate the intestinal mucosa and potentially overlooks some small or flat lesions. CT scans can more accurately identify perforations or bowel obstructions. Furthermore, they can concomitantly help in directing interventional therapies. Among patients with complicated celiac disease, enteroscopy represents a powerful and efficient diagnostic tool for the detection of small bowel malignancies.<sup>9</sup> Capsule endoscopy helps identify the site of OGIB or malignancy. However, it poses the risk of capsule retention in case of an impending obstruction.<sup>10</sup> DBE overcomes this limitation. In addition, it has an advantage: the ability to obtain a biopsy or provide endoscopic therapy.<sup>11</sup>

Historically, the radiological diagnosis of acute overt GI bleeding has been performed using technetium-99 m-labeled (99 m Tc) RBC scintigraphy and conventional angiography. In order to detect the site of active bleeding in cases of acute overt bleeding, multiphase CT or CT angiography (CTA) is usually performed. It has been demonstrated that the bleeding rates detected by CTA can be as slow as 0.3 mL/min in comparison with 0.5–1.0 mL/min for conventional angiography and 0.2 mL/min for 99 m-Tc-tagged RBC scintigraphy. An earlier meta-analysis showed that CTA had a pooled sensitivity of 89% and specificity of 85% in diagnosing acute GI bleeding throughout the GI tract.<sup>12,13</sup> In an earlier study on patients with acute overt OGIB ( $n = 71$ ), the authors observed that enteroscopy or surgical exploration confirmed the CTA findings in 25 patients. Therefore, they were considered true positives. Among the 46 patients with negative CTA findings, 33 (71.7%) were regarded as false negatives, and 13 (28.3%) were regarded as true negatives. Of 25 patients with positive CTA findings, small bowel tumor was confirmed in 16 patients (64%). Of 46 patients

with negative CTA findings, small bowel tumor was confirmed in four patients (8.7%) ( $P < 0.001$ ).<sup>13</sup> In a retrospective analysis of patients with overt suspected small bowel bleeding ( $n = 31$ ), CT had a yield of 45% (86% tumor and 33% nontumor yield) versus 94% for DBE10. However, CTA has some limitations. In order to detect contrast extravasation, active bleeding must be present at the time of the scan. In case of a lack of identification of either active bleeding or its source at the time of CTA, additional workup may be necessary. Of note, such a scenario occurred in the present case because even a small bowel malignancy could be missed by CTA.

## Conclusion

Small bowel tumors represent a diagnostic challenge, frequently occurring with nonspecific clinical symptoms. In detecting acute overt and active bleeding, multiphasic CT or CTA has a high sensitivity and specificity. Small bowel tumors should be taken into consideration in patients with OGIB, even in the event of a negative CT scan finding. A negative CT scan should prompt additional investigations, such as VCE. VCE and DBE are of beneficial value in the diagnosis of OGIB.

## Acknowledgments

The authors received funding for this manuscript from Changhua Christian Hospital (105-IRP-CCH-009 and 106-CCHIRP-030). The authors thank Enago ([www.enago.tw](http://www.enago.tw)) for English language review.

## References

- Lewis BS, Kornbluth A, Wayne JD. Small bowel tumors: yield of enteroscopy. *Gut*. 1991; **32**: 763–5.
- Schottenfeld D, Beebe-Dimmer JL, Vigneau FD. The epidemiology and pathogenesis of neoplasia in the small intestine. *Ann. Epidemiol.* 2009; **19**: 58–69.
- Ugurlu MM, Asoglu O, Potter DD, Barnes SA, Harmsen WS, Donohue JH. Adenocarcinomas of the jejunum and ileum: a 25-year experience. *J. Gastrointest. Surg.* 2005; **9**: 1182–8.
- Neugut AI, Marvin MR, Rella VA, Chabot JA. An overview of adenocarcinoma of the small intestine. *Oncology*. 1997; **11**(4): 529–36 discussion 45, 49–50.
- Vagholkar K, Mathew T. Adenocarcinoma of the small bowel: a surgical dilemma. *Saudi J. Gastroenterol.* 2009; **15**: 264–7.
- Goodman MT, Matsuno RK, Shvetsov YB. Racial and ethnic variation in the incidence of small-bowel cancer subtypes in the United States, 1995–2008. *Dis. Colon Rectum.* 2013; **56**: 441–8.
- Dabaja BS, Suki D, Pro B, Bonnen M, Ajani J. Adenocarcinoma of the small bowel: presentation, prognostic factors, and outcome of 217 patients. *Cancer*. 2004; **101**: 518–26.
- Horton KM, Fishman EK. The current status of multidetector row CT and three-dimensional imaging of the small bowel. *Radiol. Clin. North Am.* 2003; **41**: 199–212.
- Elli L, Casazza G, Locatelli M *et al.* Use of enteroscopy for the detection of malignant and premalignant lesions of the small bowel in complicated celiac disease: a meta-analysis. *Gastrointest. Endosc.* 2017; **86**: 264–73e1.
- Srai R, Tullie L, Wadoodi A, Saunders M. Capsule endoscopy: a dangerous but diagnostic tool. *BMJ Case Rep.* 2013; **2013**: bcr2013009932. <http://doi.org/10.1136/bcr-2013-009932>
- Yang CW, Chen YY, Yen HH, Soon MS. Successful double balloon enteroscopy treatment for bleeding jejunal diverticulum: a case report and review of the literature. *J. Laparoendosc. Adv. Surg. Tech. A.* 2009; **19**: 637–40.
- Wu LM, Xu JR, Yin Y, Qu XH. Usefulness of CT angiography in diagnosing acute gastrointestinal bleeding: a meta-analysis. *World J. Gastroenterol.* 2010; **16**: 3957–63.
- Yen HH, Chen YY, Yang CW, Liu CK, Soon MS. Clinical impact of multidetector computed tomography before double-balloon enteroscopy for obscure gastrointestinal bleeding. *World J. Gastroenterol.* 2012; **18**: 692–7.