



Case report

Acute contact appendicitis due to a migrated pericardial drain: a case report

Daniel Paramythiotis¹, Theodosis S Papavramidis^{1*}, Vassilis N Papadopoulos¹,
Antonis Michalopoulos¹, Olia Vasilaki² and Nick Harlaftis¹

Addresses: ¹1st Propedeutic Surgical Clinic, A.H.E.P.A. University Hospital, Aristotle's University of Thessaloniki, Thessaloniki, Greece

²Department of Microbiology, A.H.E.P.A. University Hospital of Thessaloniki, Aristotle's University of Thessaloniki, Thessaloniki, Greece

Email: DP - danosprx@med.auth.gr; TSP* - papavramidis@hotmail.com; VNP - bnpap2003@yahoo.com; AM - amichal@med.auth.gr;
OV - oliavasil@yahoo.com; NH - papavramidou@hotmail.com

* Corresponding author

Received: 28 February 2009 Accepted: 4 July 2009 Published: 30 July 2009

Cases Journal 2009, 2:6250 doi: 10.4076/1757-1626-2-6250

This article is available from: <http://casesjournal.com/casesjournal/article/view/6250>

© 2009 Paramythiotis et al.; licensee Cases Network Ltd.

This is an Open Access article distributed under the terms of the Creative Commons Attribution License (<http://creativecommons.org/licenses/by/3.0>), which permits unrestricted use, distribution, and reproduction in any medium, provided the original work is properly cited.

Abstract

Introduction: The literature is replete with articles of foreign-body appendicitis and periappendicitis, but to our knowledge there are only two reports of extraintestinal foreign bodies causing contact appendicitis.

Case presentation: A 47-year old woman presented to the emergency department with a 24-hour history of right iliac fossa pain, nausea and vomiting, high fever and palpable right iliac fossa mass. The patient had an anamnestic of systemic lupus erythematosus, that caused acute pericarditis with effusion, that was treated with pericardiotomy and a pericardial drain. The laboratory tests showed leukocytosis. The plain abdomen film showed no radiologic signs corresponding to acute abdomen, while the computed tomography revealed a radio-opaque formation in the right iliac fossa, corresponding to the palpable mass. Exploratory laparotomy revealed a pericardial drain. The microbiologic analysis of the abscess revealed *Salmonella*. The postoperative course of the patient was uneventful.

Conclusion: Acute appendicitis due to a foreign body, without an anamnestic of either surgery or injury may cause a severe diagnostic dilemma. The computed tomography images may lead to logic riddles that have to be solved by an explorative laparotomy. Foreign bodies rarely cause acute abdomen, nevertheless the probability has to be considered when an interventional technique has been applied even if the location of the intervention is far from the abdominal cavity.

Introduction

The literature is replete with articles of foreign-body appendicitis and periappendicitis, including three comprehensive review articles on this topic [1-3]. These articles

have reported many types of ingested foreign bodies within the appendix. Klinger et al reported that ingested foreign bodies account for the 0.0005% of the aetiology of acute appendicitis [1]. Hard pointed objects such as

toothpicks, pins, needles, nails, and screws are prone to causing perforation, but other foreign bodies —some seemingly innocuous— such as thread, chewing gum, and hair have been reported as the likely causes of appendicitis resulting from obstruction, as have lodged bullets, ingested lead shot, and parasitic worms topic [1-3].

To our knowledge there are only two reports of extraintestinal foreign bodies causing appendicitis [4,5]. The present case is extremely interesting because the appendicitis is caused by an extraintestinal foreign body which originated from the thoracic cavity. Furthermore, this is the only case in the literature that a pericardial drain causes acute abdomen.

Case presentation

A 47-year old Greek woman presented to the emergencies with a 24 hour history of right iliac fossa pain, nausea and vomiting, high fever and palpable right iliac fossa mass. The patient had an anamnestic of systemic lupus erythematosus, that caused three years ago acute pericarditis with effusion, which was treated with pericardiotomy and placement of a pericardial drain.

Laboratory tests showed leukocytosis (15.100 WBC/ μ L with 86% polymorphs). The plain abdomen film showed no radiologic signs corresponding to acute abdomen, while the CT revealed a radio-opaque formation in the right iliac fossa, corresponding to the palpable mass (Figure 1).

Exploratory laparotomy revealed a foreign body (8 cm long) corresponding to the pericardial drain. The drain had migrated to the right iliac fossa causing the formation of a periappendiceal abscess. The microbiologic analysis of the abscess revealed Salmonella. The postoperative course of the patient was uneventful.

Discussion

Pericardial disorders occurring in connective tissue diseases are not uncommon and may present as acute or chronic pericarditis with or without an effusion. In many instances, a diagnosis of pericardial involvement is not found until autopsy [6]. Furthermore, pericarditis is the most common cardiac abnormality in systemic lupus erythematosus (SLE) patients [7]. Our patient presented, three years before the acute appendicitis, pericarditis due to SLE.

The drainage of pericardial effusion is an established practice concomitant to surgical pericardiotomy and pericardiectomy [8]. Our patient had a pericardial drain connecting the pericardial cavity to the abdominal cavity in order to evacuate the pericardial effusion.

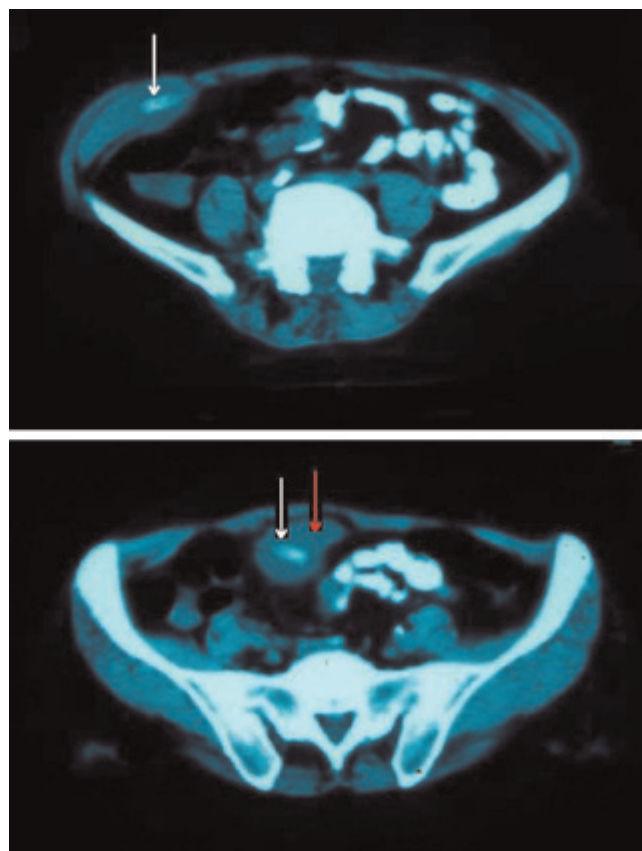


Figure 1. CT showing the localisation of the drain that migrated in the right iliac fossa. White arrow indicates the drain, while red arro indicates the abscess.

Salmonella was isolated from the periappendiceal abscess. The fact that this intestinal pathogen was involved in the acute abdomen formation has to let us consider the probability of its being the primary pathology. We have at least to acknowledge the fact that it is possible that the Salmonella infection led to intestinal perforation and that the drain was an incidental finding.

Conclusion

Acute appendicitis due to a foreign body, without an anamnestic of either surgery or injury may cause a severe diagnostic dilemma. The CT images may lead to logic riddles that have to be solved by an explorative laparotomy. Foreign bodies rarely cause acute abdomen, nevertheless the probability has to be considered when an interventional technique has been applied even if the location of the intervention is far from the abdominal cavity.

Abbreviations

CT, computed tomography; SLE, systemic lupus erythematosus; WBC, white blood cells.

Consent

Written informed consent was obtained from the patient for publication of this case report and any accompanying images. A copy of the written consent is available for review by the Editor-in-Chief of this journal.

Competing interests

The authors declare that they have no competing interests.

Authors' contributions

DP involved in revising the draft critically for important intellectual content. TSP received the patient to the emergency department Involved in drafting the manuscript and revising it critically for important intellectual content. VNP received the patient to the emergency department and consulted on the pharmaceutical treatment and he involved in drafting the manuscript. AM, the Auxiliary surgeon involved in revising the draft critically for important intellectual content. OV did microbiologic analysis and involved in revising the draft critically for important intellectual content. NH involved in strategic planning for the treatment of the patient and also involved in revising the draft critically for important intellectual content. All author have given final approval of the version to be published.

References

1. Klingler PJ, Seelig MH, DeVault KR, Wetscher GJ, Floch NR, Branton SA, Hinder RA: **Ingested foreign bodies within the appendix: a 100-year review of the literature.** *Dig Dis* 1998, **16**:308-314.
2. Green SG, Schmidt SP, Rothrock SG: **Delayed appendicitis from an ingested foreign body.** *Am J Emerg Med* 1994, **12**:53-56.
3. Balch CM, Silver D: **Foreign bodies in the appendix: review of eight cases and review of the literature.** *Arch Surg* 1971, **102**:14-20.
4. Mendez LE, Medina C: **Late Complication of Laparoscopic Salpingoophorectomy: Retained Foreign Body Presenting as an Acute Abdomen.** *JSLs* 1997, **1**:79-81.
5. Conti F, Gentilli S, Mauri A: **Foreign body decubitus: unusual cause of acute appendicitis.** *Minerva Chir* 1993, **48**:713-716.
6. Langley RL, Treadwell EL: **Cardiac tamponade and pericardial disorders in connective tissue diseases: case report and literature review.** *J Natl Med Assoc* 1994, **86**:149-153.
7. Doria A, Iaccarino L, Sarzi-Puttini P, Atzeni F, Turriel M, Petri M: **Cardiac involvement in systemic lupus erythematosus.** *Lupus* 2005, **14**:683-686.
8. Bellon RJ, Wright WH, Unger EC: **CT-guided pericardial drainage catheter placement with subsequent pericardial sclerosis.** *J Comput Assist Tomogr* 1995, **19**:672-673.

Do you have a case to share?

Submit your case report today

- Rapid peer review
- Fast publication
- PubMed indexing
- Inclusion in Cases Database

Any patient, any case, can teach us something



**CASES
NETWORK**

www.casesnetwork.com