

Successful management of multiple small bowel perforations due to polyarteritis nodosa

Seyed Hamzeh Mousavie¹, Rezvan Mirzaei², Bahar Mahjoubi², Rasoul Azizi²

¹Department of General Surgery, ²Associated Professor of Colorectal Surgery, Division of Colon and Rectal Surgery, Hazrat-e-Rasoul Hospital, Iran University of Medical Sciences, Tehran, Iran

Classic Polyarteritis nodosa (PAN)) is a medium-sized vessel vasculitis that usually occurs in middle-aged men. One of the dramatic manifestations of PAN that requires surgical intervention is multiple small bowel perforations. Many studies have reported a high rate of mortality in PAN due to acute abdominal complications. We report here the case of multiple small bowel perforations in a 22-year-old man, who presented with an acute abdomen, and eventually, PAN was diagnosed. In our case, PAN led to multiple small bowel perforations and diffuse patchy necrosis. All perforations were primarily repaired and corticosteroids were prescribed. Using corticosteroid in patients with abdominal sepsis is injurious; however, laparostomy is the method we suggest, to achieve the purpose, including prevention of a short bowel and infection control. Our patient was discharged, well, after 48 days of hospitalization and referred to a rheumatologist.

Key words: Laparostomy, multiple small bowel perforations, open abdomen, polyarteritis nodosa

How to cite this article: Mousavie SH, Mirzaei R, Mahjoubi B, Azizi R. Successful management of multiple small bowel perforations due to polyarteritis nodosa. *J Res Med Sci* 2014;19:276-8.

INTRODUCTION

The Chapel Hill Consensus Conference (CHCC) on the Nomenclature of Systemic Vasculitis defined PAN or alternatively 'classic' PAN as a condition characterized by the necrotizing inflammation of medium-sized or small arteries, without glomerulonephritis or vasculitis in the arterioles, capillaries, or venules.^[1]

In classic PAN, it being a medium-sized vessel vasculitis disease, symptoms result from ischemic damage to the affected organs, often the skin, heart, kidneys, and nervous system.

In one study that reviewed the medical records of 62 patients with systemic small and medium-sized vessel vasculitides and gastrointestinal tract involvement, who were followed between 1981 and 2002, gastrointestinal manifestations were present at or occurred within three months of diagnosis in 81% of the patients and were mainly abdominal pain in 97%, nausea or vomiting in 34%, diarrhea in 27%, hematochezia or melena in 16%, and hematemesis in 6%. Gastroduodenal ulcerations were detected endoscopically in 27% of the patients, esophageal in 11%, and colorectal in 10%, but histological signs of vasculitis were found in only three colon biopsies. Twenty-one (34%) patients had a surgical

abdomen; 18% developed peritonitis, 15% had bowel perforations, 16% bowel ischemia / infarction, 6% intestinal occlusion, 10% acute appendicitis, 8% cholecystitis, and 5% acute pancreatitis.^[2]

Gastrointestinal involvement usually presents in the form of nonspecific symptoms and signs such as abdominal pain, nausea, and vomiting. However, rare and more serious complications of PAN are bowel infarction and perforation.^[3,4]

Gastrointestinal tract manifestations are among the most serious expressions of PAN and in one-third of the cases manifest as an acute surgical abdomen.^[1,5]

Fagniez has coined the term 'laparostomy,' which implies leaving the abdomen open. Open management of the infected abdomen was instituted in the belief that the peritoneal cavity could be treated like an abscess cavity.^[6]

Laparostomy is a valuable technique in the management of severe, intractable intra-abdominal sepsis. The indications to embark on planned re-laparostomy remain poorly defined and empiric. The two postoperative complications that may require a re-look are generalized peritonitis or intra-abdominal abscess.^[6,7]

CASE REPORT

Address for correspondence: Dr. Rezvan Mirzaei, Hazrat-e-Rasoul Hospital, Iran University of Medical Sciences, Tehran, Iran.
E-mail: Rezvan_mirzaei@yahoo.com

Received: 02-03-2013; **Revised:** 26-05-2013; **Accepted:** 15-07-2013

A 22-year-old man, who was hospitalized from four days prior, consulted with the General Surgery Department in the Rasool-Akram Hospital at an address in Tehran, Iran, because of deterioration of his general condition and existence of abdominal pain and distention, in September 2012.

During this time, the patient was ill and complained of abdominal pain and distention. On physical examination, abdominal generalized tenderness and rebound tenderness were detected. The patient was icteric. On account of tachycardia, leukocytosis, and fever, the patient was suffering from the systemic inflammatory response syndrome (SIRS). The patient was diagnosed as an acute abdomen and immediately underwent a laparotomy.

As medical history, he was admitted initially with postprandial periumbilical abdominal pain, low-grade fever, diarrhea, loss of appetite, and weight loss, with two months duration. A positive laboratory test included: Hemoglobin = 12.6 (13.5 – 17.5), hematocrit = 38.5 (41 – 53), white blood cell count = 24200 (4,000 – 12,000 / mm³), Eosinophils = 33 (1 – 3%). Colonoscopic findings were aphthous, nodularity, and multiple ulcers with skip lesions, and upper endoscopic findings were multiple cratered large ulcers without bleeding in the stomach, one 5 mm superficial ulcer in the bulb of the duodenum, and three cratered large ulcers without bleeding in the second part of the duodenum. Therefore, he had been treated with corticosteroids, as it was a case of Crohn's disease.

After laparotomy for acute abdomen, the findings were multiple intestinal perforations that were approximately 2 × 1.5 cm in the largest size, four of which were in the jejunum and three in the ileum. These perforations were at a distance of 60 cm, 70 cm, 80 cm, 90 cm, 130cm, 150cm, and 170 cm from the ligament of Treitz, and there were necrotic lesions among them. Also one necrotic lesion in the liver, diffuse patchy intestinal necrosis, purulent discharge, and fibrin and adhesion bands were found [Figure 1].

On account of the increase in the risk of short bowel syndrome and the possibility of new perforations, and

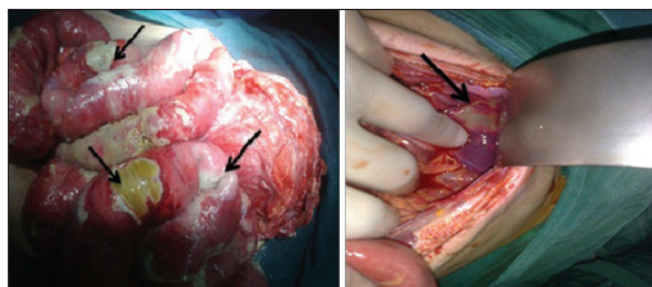


Figure 1: Multiple small bowel necrosis and liver patchy necrosis

also persistence of abdominal sepsis, we decided to repair the lesions after debridement and biopsy [Figure 2]. Thus, treatment had to be continued open abdomen. The perforations were primarily repaired with silk in seven locations of the perforations, but were not resected, and the biopsy specimens were taken from the perforated edges of the intestinal wall and the abdomen covered by a sterile bag. Owing to the strong clinical suspicion of vasculitis, corticosteroids were prescribed.

The abdomen was re-explored, after 24 hours. We evaluated the intestines and did not find new perforations, but there was still a risk of perforation (because of multiple discolored lesions). The patient's abdomen was not closed and managed in the same manner as previously, with frequent washing of the intestines. In re-evaluation of the intestines on the second day, we found two new perforations and leakage of one anastomosis, which were repaired. On account of bile discharge from the midline incision on the sixth day again — in the fourth time exploration — we found bile discharge in the left gutter, but all intestines walled off by themselves. Therefore, we drained the discharge by placing the abdominal drainage catheter without additional manipulations.

Management of this patient with open-abdomen treatment (laparostomy) was performed overall five times and during all these periods, corticosteroids were continued. After ensuring the intestinal condition, on the eighth day, the skin of the abdomen was closed and an abdominal drainage catheter remained in place. The catheter was removed because of low output discharge on the fifteenth day and we managed it as an enterocutaneous fistula and started total parenteral nutrition (TPN).

According to the pathology report, clinical signs and symptoms, and rheumatological consultation, PAN was a definite diagnosis and corticosteroid therapy (Methylprednisolone: 60 mg / day PO divided q 6 – 24

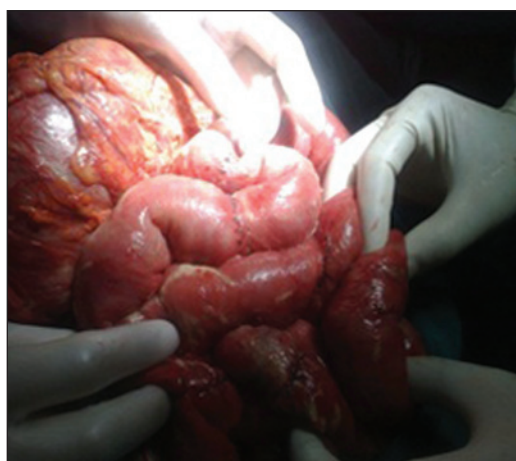

Figure 2: Multiple small bowel repairs

hours) was continued, and cyclosporine (Novartis, under the brand name Sandimmune once a day, for two weeks) started on the seventh day.

Finally, the patient was discharged after 48 days of hospitalization and referred to a rheumatologist [Figure 3].

DISCUSSION

Many studies reported a high rate of mortality in PAN, due to acute abdominal complications. Pagnoux and his colleagues showed a significant increase in the mortality rate in 62 patients with systemic small- and medium-sized vessel vasculitis that presented with peritonitis, bowel perforations, gastrointestinal ischemia or infarctions and intestinal occlusion.^[2] In another study by Zizic and his colleagues, five of the 16 patients with polyarteritis nodosa, who had acute abdomen and required operative intervention, died in contrast to only two of the 11 PAN patients without abdominal involvement.^[8]

In our case, PAN led to multiple small bowel perforations and diffuse patchy necrosis. Due to the risk of short bowel syndrome and due to a wide resection, primary repair of the perforations and frequent evaluation of the suspicious lesions were planned. Actually, we saved the patient's life by using the laparostomy technique.

In one study, Bourgarit and his colleagues described uncontrolled vasculitis and infection as being the major causes of early death in these patients. Despite

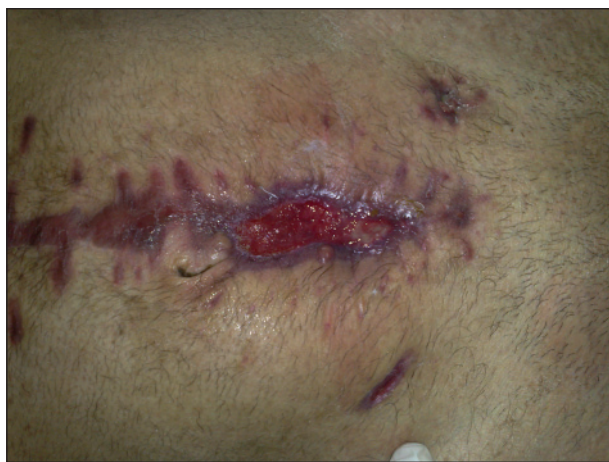

Figure 3: Patient's abdomen on forty-eighth day (discharge time)

iatrogenic complications due to Cyclophosphamide and corticosteroids, early deaths were more frequently the consequence of insufficient or inappropriate therapy.^[9]

On account of the presence of multiple risk factors including sepsis, multiple anastomosis, and malnutrition, treatment with corticosteroids for our patient was controversial. Hence, we managed the patient using the open-abdomen method (frequent washing of abdomen and repeated assessment of the intestines) and mandatory corticosteroid therapy was continued for vasculitis.

Finally, we recommend timely diagnosis and treatment of GI complications of PAN, so as to benefit the decrease in mortality and morbidity. Simultaneous treatment with surgical intervention and corticosteroid therapy enabled us to control the abdominal complication of PAN.

REFERENCES

1. Colmegna I, Maldonado-Cocco JA. Polyarteritis nodosa revisited. *Curr Rheumatol Rep* 2005;7:288-96.
2. Pagnoux C, Mahr A, Cohen P, Guillevin L. Presentation and outcome of gastrointestinal involvement in systemic necrotizing vasculitides: Analysis of 62 patients with polyarteritis nodosa, microscopic polyangiitis, Wegener granulomatosis, Churg-Strauss syndrome, or rheumatoid arthritis-associated vasculitis. *Medicine* 2005;84:115-28.
3. Trepo C, Guillevin L. Polyarteritis nodosa and extrahepatic manifestations of HBV infection: The case against autoimmune intervention in pathogenesis. *J Autoimmun* 2001;16:269-74.
4. Younger DS. Vasculitis of the nervous system. *Curr Opin Neurol* 2004;17:317-36.
5. de Carvalho Panzeri Carlotti AP, Ferriani VPL, Caldas CT, Cervi MC, Pileggi G, Carvalho C, *et al.* Polyarteritis nodosa with central nervous system involvement mimicking meningoencephalitis. *Pediatr Crit Care Med* 2004;5:286-8.
6. Schein M, Rogers P, Assalia A. Schein's common sense emergency abdominal surgery. Germany: Springer Verlag; 2010.
7. Mughal M, Bancewicz J, Irving M. 'Laparostomy': A technique for the management of intractable intra-abdominal sepsis. *Br J Surg* 1986;73:253-9.
8. Zizic TM, Classen JN, Stevens MB. Acute abdominal complications of systemic lupus erythematosus and polyarteritis nodosa. *Am J Med* 1982;73:525-31.
9. Bourgarit A, Le Toumelin P, Pagnoux C, Cohen P, Mahr A, Le Guern V, *et al.* Deaths occurring during the first year after treatment onset for polyarteritis nodosa, microscopic polyangiitis, and Churg-Strauss syndrome: A retrospective analysis of causes and factors predictive of mortality based on 595 patients. *Medicine (Baltimore)* 2005;84:323-30.

Source of Support: Nil, **Conflict of Interest:** None declared.