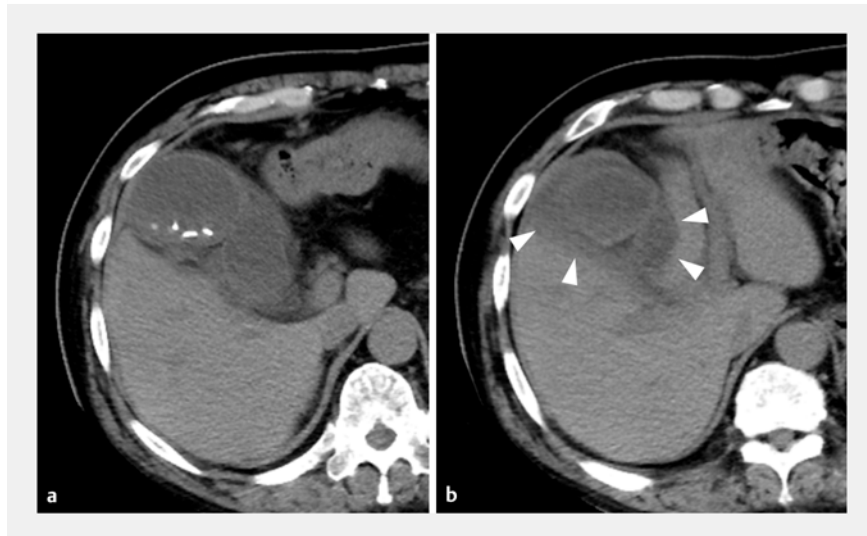


Efficacy of an easy loop-forming guidewire in endoscopic transpapillary gallbladder drainage with gallstones impacted in the cystic duct

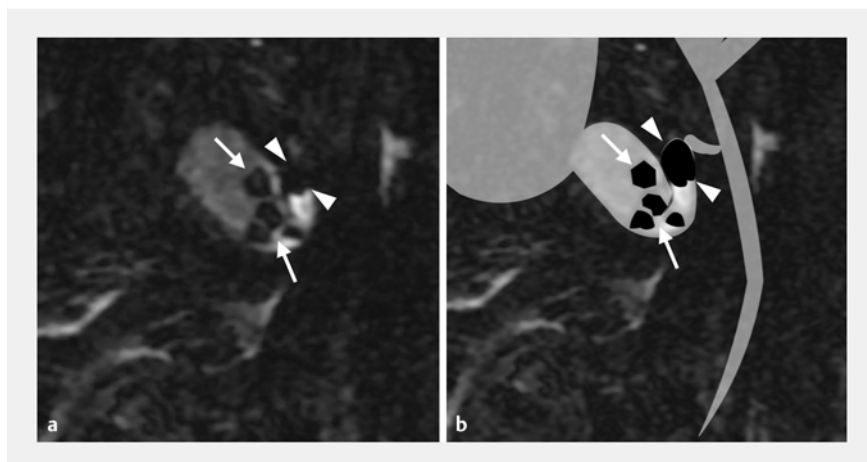


Endoscopic transpapillary gallbladder drainage (ETGBD) is a drainage method for acute cholecystitis; it is often used in patients who are on antithrombotic drugs or in those presenting with ascites [1–3]. However, the success rate of the procedure is lower than that of percutaneous transhepatic biliary drainage (PTGBD), and one of the reasons for this is the difficulty of inserting the guidewire into the gallbladder [4]. Especially in cases where a stone is impacted in the cystic duct, it becomes even more difficult to insert the guidewire into the gallbladder [5]. A 75-year-old man with acute cholecystitis had been referred because of septic shock. The patient was taking two antithrombotic drugs. Computed tomography revealed gallbladder wall thickening, gallstones, and fat-stranding around the enlarged gallbladder (▶ Fig. 1). Magnetic resonance cholangiopancreatography confirmed the presence of impacted gallstones in the cystic duct (▶ Fig. 2). Because of the antithrombotic drugs and the presence of ascites, ETGBD was selected as the drainage method.

After biliary cannulation, it was not possible to advance a 0.025-inch angled-shape guidewire through the gallstones impacted in the cystic duct and into the gallbladder. Therefore, manipulation using a guidewire that readily forms into a loop shape (J-Wire Prologue; J-MIT, Shiga, Japan) was attempted. This is a 0.025-inch guidewire with a soft section as long as 160 mm; the nitinol core is tapered toward the tip, so that it tends to form a loop shape (▶ Fig. 3). This characteristic allowed a loop shape to be easily created, moving the gallstones impacted in the cystic duct to create a gap, so that the guidewire could be passed into the gallbladder (▶ Fig. 4). Finally, an endoscopic nasobiliary drainage tube was successfully placed (▶ Fig. 5; ▶ Video 1), with the cholecystitis improving after drainage.



▶ Fig. 1 Computed tomography images showing gallbladder wall thickening, gallstones, and fat-stranding around the enlarged gallbladder (arrowhead).



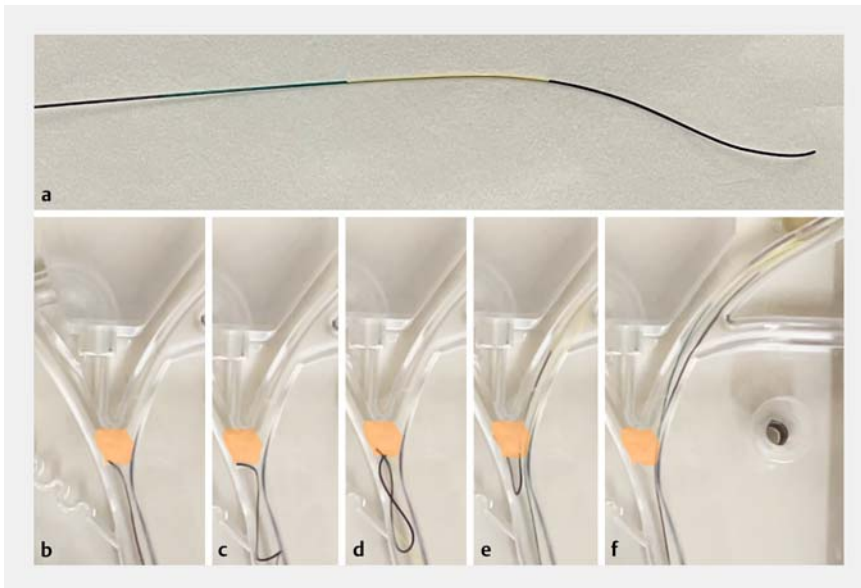
▶ Fig. 2 Magnetic resonance cholangiopancreatography images showing the presence of impacted gallstones in the cystic duct (arrowhead).

This loop-friendly characteristic is expected to be an effective option in ETGBD for acute cholecystitis with gallstones impacted in the cystic duct.

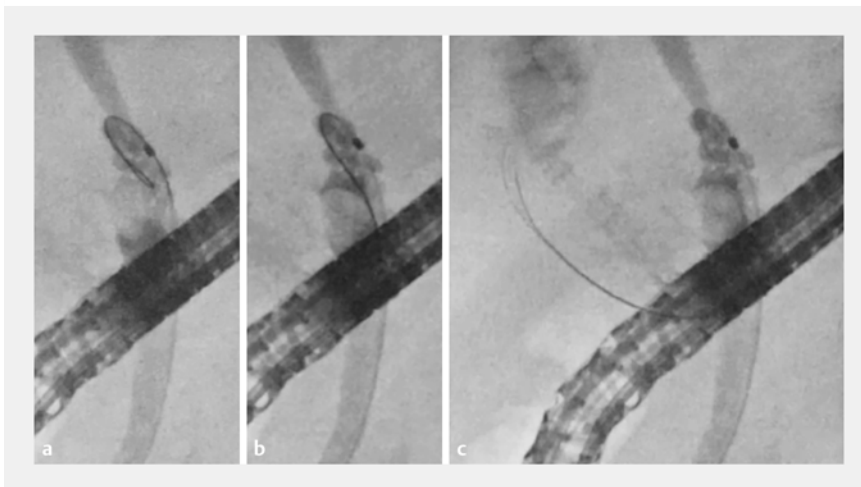
Endoscopy_UCTN_Code_TTT_1AR_2AH

Competing interests

The authors declare that they have no conflict of interest.



► **Fig. 3** Photographs showing: **a** the J-Wire Prologue, which is a 0.025-inch guidewire with a soft section of 160 mm containing a nitinol core that is tapered toward the tip; **b–f** a demonstration in a biliary model of how the guidewire tends to form a loop shape that allows it to pass a stricture (orange area).



► **Fig. 4** Radiographic images showing: **a** the guidewire creating a loop shape, with the cystic duct as the fulcrum; **b** the guidewire loop moving the stones in the impacted cystic duct to create a gap; **c** the guidewire being passed into the gallbladder.

The authors

Mamoru Takenaka  **Kae Fukunishi, Kota Takashima, Tomohiro Yamazaki, Masatoshi Kudo**

Department of Gastroenterology and Hepatology, Kindai University Faculty of Medicine, Osaka-Sayama, Japan

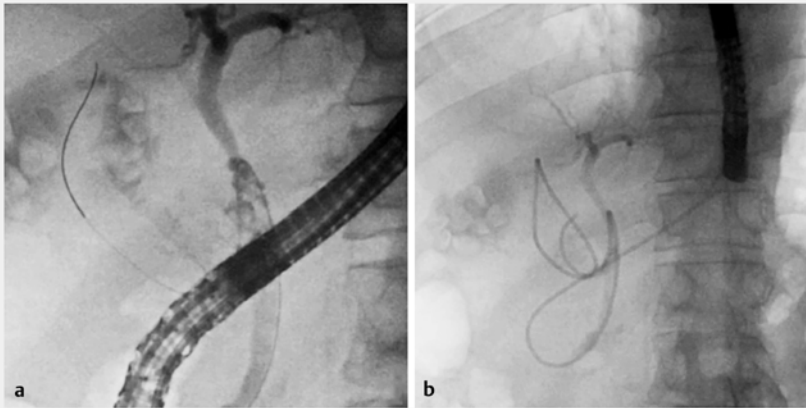
Corresponding author

Mamoru Takenaka, MD

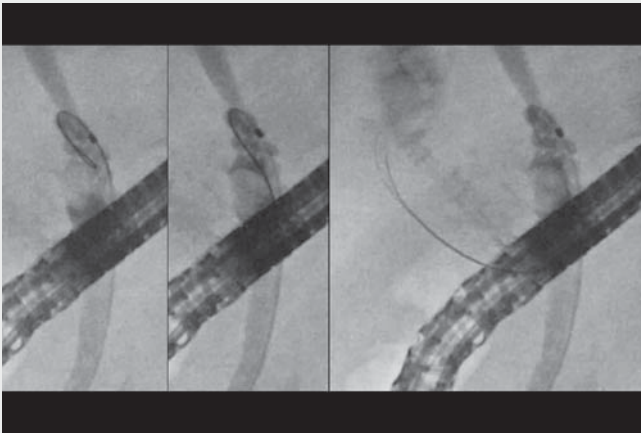
Department of Gastroenterology and Hepatology, Kindai University Faculty of Medicine, 377-2 Ohno-Higashi, Osaka-Sayama, 589-8511, Japan
mamoxyo45@gmail.com

References

- [1] Jandura DM, Puli SR. Efficacy and safety of endoscopic transpapillary gallbladder drainage in acute cholecystitis: An updated meta-analysis. *World J Gastrointest Endosc* 2021; 13: 345–355
- [2] Mandai K, Kawamura T, Uno K et al. Endoscopic transpapillary gallbladder stenting for acute cholecystitis using a novel integrated inside biliary stent and nasobiliary drainage catheter system. *Endoscopy* 2021. doi:10.1055/a-1512-8024
- [3] Park SW, Lee SS. Current status of endoscopic management of cholecystitis. *Dig Endosc* 2022; 34: 439–450
- [4] Mohan BP, Khan SR, Trakroo S et al. Endoscopic ultrasound-guided gallbladder drainage, transpapillary drainage, or percutaneous drainage in high risk acute cholecystitis patients: a systematic review and comparative meta-analysis. *Endoscopy* 2020; 52: 96–106
- [5] Nakahara K, Michikawa Y, Morita R et al. Endoscopic transpapillary gallbladder drainage using the balloon occlusion method to advance the guidewire into the cystic duct. *Endoscopy* 2020; 52: E339–E341



► **Fig. 5** Radiographic images showing the successful placement of an endoscopic nasobiliary drainage tube.



► **Video 1** A guidewire that easily forms a loop shape is used in endoscopic transpapillary gallbladder drainage for acute cholangitis due to gallstones impacted in the cystic duct.

Bibliography

Endoscopy 2022; 54: E1078–E1080

DOI 10.1055/a-1893-5590

ISSN 0013-726X

published online 1.9.2022

© 2022. The Author(s).

This is an open access article published by Thieme under the terms of the Creative Commons Attribution-NonDerivative-NonCommercial License, permitting copying and reproduction so long as the original work is given appropriate credit. Contents may not be used for commercial purposes, or adapted, remixed, transformed or built upon. (<https://creativecommons.org/licenses/by-nc-nd/4.0/>)

Georg Thieme Verlag KG, Rüdigerstraße 14,
70469 Stuttgart, Germany



ENDOSCOPY E-VIDEOS

<https://eref.thieme.de/e-videos>



Endoscopy E-Videos is an open access online section, reporting on interesting cases and new techniques in gastroenterological endoscopy. All papers include a high quality video and all contributions are freely accessible online. Processing charges apply (currently EUR 375), discounts and waivers acc. to HINARI are available.

This section has its own submission website at
<https://mc.manuscriptcentral.com/e-videos>