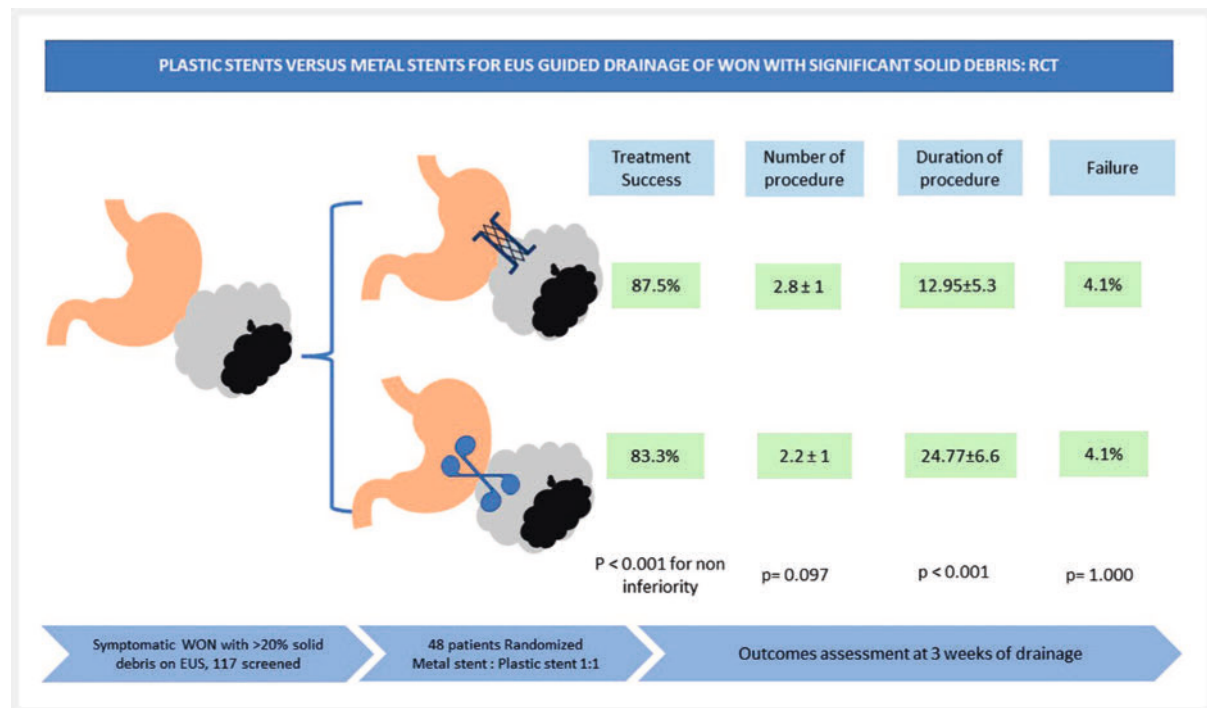


# Plastic versus metal stents for transmural drainage of walled-off necrosis with significant solid debris: a randomized controlled trial



## GRAPHICAL ABSTRACT



## Authors

Rinkal Kakadiya<sup>1†</sup>, Gaurav Muktesh<sup>1†</sup>, Jayanta Samanta<sup>1</sup>, Harshal S Mandavdhare<sup>1</sup>, Pankaj Gupta<sup>2</sup>, Jimil Shah<sup>1</sup>, Phulen Sarma<sup>3</sup>, Vikas Gupta<sup>4</sup>, Thakur Deen Yadav<sup>4</sup>, Anuraag Jena<sup>1</sup>, Vishal Sharma<sup>1</sup>, Rakesh Kochhar<sup>1</sup>

## Institutions

- 1 Gastroenterology, Post Graduate Institute of Medical Education and Research, Chandigarh, India
- 2 Radiodiagnosis, Post Graduate Institute of Medical Education and Research, Chandigarh, India
- 3 Pharmacology, Post Graduate Institute of Medical Education and Research, Chandigarh, India
- 4 General Surgery, Post Graduate Institute of Medical Education and Research, Chandigarh, India

## Key words

Endoscopic ultrasonography, Pancreas, Intervention EUS

received 5.7.2023

accepted after revision 25.9.2023

accepted manuscript online 6.10.2023

## Bibliography

Endosc Int Open 2023; : –

DOI 10.1055/a-2185-6318

ISSN 2364-3722

© 2023. The Author(s).


This is an open access article published by Thieme under the terms of the Creative Commons Attribution-NonDerivative-NonCommercial License, permitting copying and reproduction so long as the original work is given appropriate credit. Contents may not be used for commercial purposes, or adapted, remixed, transformed or built upon. (<https://creativecommons.org/licenses/by-nc-nd/4.0/>)

Georg Thieme Verlag KG, Rüdigerstraße 14,  
70469 Stuttgart, Germany

† These authors contributed equally.

**Corresponding author**

Gaurav Muktesh, Post Graduate Institute of Medical Education and Research, Gastroenterology, Chandigarh, India  
gauravmuktesh@gmail.com

 Additional material is available at  
<https://doi.org/10.1055/a-2185-6318>

**ABSTRACT**

**Background and study aims** Recently, larger-caliber metal stents have been increasingly used, resulting in higher efficacy in walled-off necrosis (WON) with more solid debris. However, none of the trials have included WON with significant solid debris. The aim of this study was to compare plastic stents and metal stents for drainage of symptomatic WON with significant solid debris ( $\geq 20\%$ ).

**Patients and methods** We conducted a single-center, open-label, noninferiority trial including 48 patients. The primary endpoint was treatment success. Secondary outcomes were technical success, total number of procedures,

adverse events (AEs), duration of procedure, and treatment failure. All the outcomes were assessed at 3 weeks after drainage. Patients were followed up for 3 months to assess recurrence.

**Results** Treatment succeeded in 21 of 24 patients (87.5%) and 20 of 24 patients (83.3%) in the metal and plastic stent groups, respectively with  $P = 1.05$  (95% confidence interval 0.81–1.39). Assuming 10% non-inferiority margin,  $P < 0.001$  for non-inferiority, suggesting that plastic stents are non-inferior to metal stents. The technical success rate was 100%. Procedure duration was significantly shorter in the metal stent group ( $12.95 \pm 5.3$  minutes versus  $29.77 \pm 6.6$  minutes,  $P < 0.001$ ). The number of total procedures was comparable ( $2.8 \pm 1$  vs  $2.2 \pm 1$ ,  $P = 0.097$ ). There were more minor AEs in plastic stent arm but no significant difference between the two groups. A single asymptomatic recurrence was observed in the metal stent arm.

**Conclusions** Plastic stents are not inferior to metal stents for WON drainage with significant solid debris. However, larger sample-size studies are needed to make definite conclusions.

## Introduction

Acute pancreatitis can result in various local complications, walled-off necrosis being one of them [1]. WON produces symptoms in approximately 50% of cases, presenting as abdominal pain, biliary obstruction, gastric outlet obstruction or infection [2]. Endoscopic ultrasound (EUS)-guided transmural drainage plays a crucial role in managing a collection with mature walls, such as pancreatic pseudocyst and WON, due to its capacity to withstand puncture, dilation, and necrosectomy. Both small-caliber double-pigtail plastic and large-caliber metal stents can be employed for drainage of WON. However, data comparing these two type of stents are limited, mainly consisting of retrospective studies with controversial outcomes [3, 4, 5, 6, 7, 8].

A randomized controlled trial (RCT) conducted by Lee et al comparing metal stents and plastic stents for EUS-guided drainage of pancreatic fluid collections demonstrated no significant difference in terms of safety, efficacy, and technical feasibility [9]. It is important to note that this study encompassed patients with both pseudocyst and WON, with the primary endpoint being procedure duration. Another RCT by Bang et al. that compared plastic stents with lumen-apposing metal stents (LAMS) for WON drainage found no significant difference in treatment success between the two types of stents. However, the primary outcome in this study was the number of procedures needed for resolution of WON, rather than treatment success, which is a major clinical endpoint [10]. Rana et al. showed that patients with  $< 10\%$  solid debris typically required only one endoscopic intervention, those with 10% to 40% solid debris needed multiple sessions of endoscopic drainage, and

patients with solid debris  $> 40\%$  required direct endoscopic necrosectomy (DEN) or minimally invasive surgical necrosectomy to achieve treatment success [11]. Therefore, it is well established that WON with a higher percentage of solid debris is difficult to treat and these patients warrant additional interventions. Recently, there has been a rapid increase in the use of metal stents for WON drainage. However, the superiority of metal stents, particularly in cases with a greater amount of solid debris ( $> 20\%$ ), has not been proven. Our hypothesis posits that plastic stents are not inferior to metal stents in terms of treatment success after EUS-guided drainage of WON with 20% or more solid debris. The goal of this study was to compare treatment success between metal stents and plastic stents in patients with symptomatic WON with significant solid debris.

## Patients and methods

### Trial design

This was a randomized comparative non-inferiority trial with allocation ratio of 1:1. It was conducted in the Department of Gastroenterology, Postgraduate Institute of Medical Education and Research, Chandigarh, India from August 2020 to July 2021.

### Participants

The inclusion criteria were: 1) informed consent for study participation; 2) symptomatic WON; 3) WON having  $> 20\%$  solid debris; and 4) amenable to EUS-guided drainage. The exclusion criteria were: 1) prior radiological/endoscopic or surgical intervention; 2) age  $< 18$  years; 3) Billroth II surgery, gastric bypass surgery; 4) thrombocytopenia or coagulopathy (platelets

<1,00,000 or international normalized ratio >1.5; 4) asymptomatic WON; and 5) WON not amenable to EUS-guided drainage.

### Intervention

The intervention was EUS-guided transmural drainage of WON performed using metal stent or plastic stent. Metal stents used in this study were biflanged fully-covered self-expanding metallic stents measuring 16 × 30mm (NAGI, Taewoong Medical, Gimpo, Korea) or LAMS measuring 15×10mm (Hot Axios, Boston Scientific, Marlborough, Massachusetts, United States). Double-pigtail plastic stents with a diameter of 7F or 10F and length of 3 or 5 cm were used in this study. A minimum of two double-pigtail plastic stents were deployed during index drainage procedure.

### Pre-procedure workup

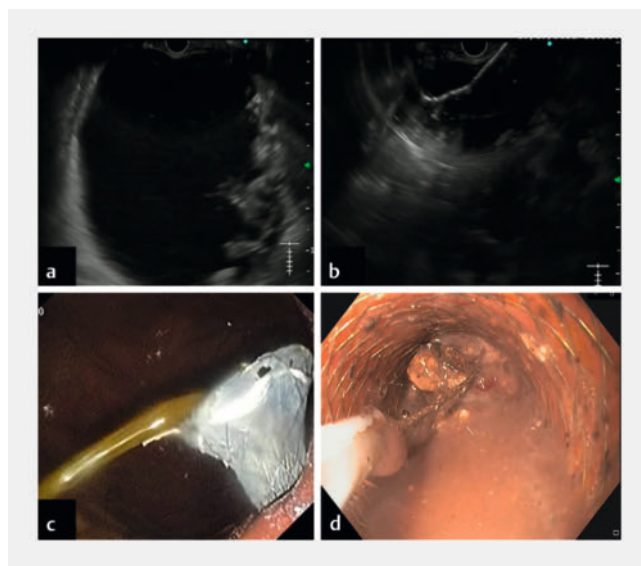
After enrollment, a detailed history, clinical, anthropometric and laboratory evaluation (routine investigation, C-reactive protein, procalcitonin, blood culture) was done. Therapeutic/prophylactic antibiotics were administered and cysto-gastrostomy was performed as described below. WON fluid was sent for analysis like culture and amylase levels.

### Description of cystogastrostomy procedure

All drainage procedures were done by one of the expert endoscopists (GM, JS, HSM) by using a linear array echoendoscope with CO<sub>2</sub> insufflation under mild sedation with midazolam. The cyst was punctured with a 19G EUS fine-needle aspiration needle (Echo tip Ultra; Cook Endoscopy, USA or Expect; Boston Scientific Corporation, USA) and 0.035-inch guidewire was inserted under EUS guidance. The tract was dilated with either an 8.5F cystotome (ENDO-FLEX GmbH EN, Germany) in case of metal stent or controlled radial expansion balloon dilator up to 15mm in the plastic stent group. A metal stent (NAGI stent) was deployed over guidewire through the scope channel under fluoroscopy or EUS vision. In case of Hot Axios stent, proximal flange was deployed under EUS vision and distal flange was deployed using intrachannel release technique. For plastic stents, along the previously placed guidewire, another guidewire was placed to deploy multiple plastic stent without losing access to the WON cavity.

### Steps in direct endoscopic necrosectomy

The WON cavity was entered through the metal stent. In case of a plastic stent, the tract was dilated with a controlled radial expansion balloon up to 15mm after stent removal and the cavity was entered with a therapeutic gastroscope. Debridement was done by rat tooth, snare or basket (► Fig. 1). Subsequently the cavity was irrigated with normal saline. A nasocystic drain (NCD) was placed at the discretion of the endoscopist.



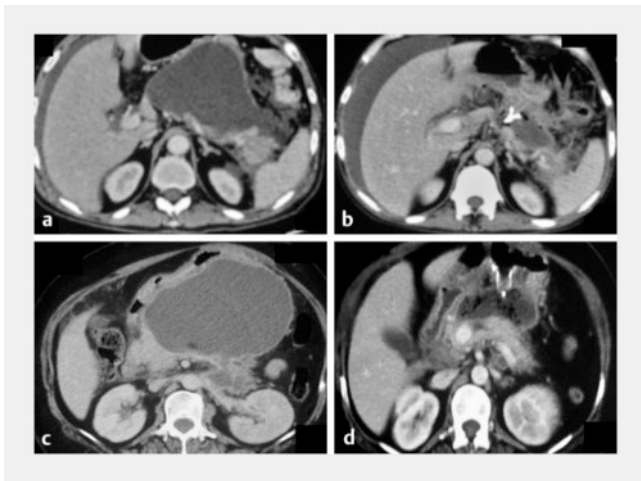
► **Fig. 1** **a** Endoscopic ultrasound image showing large collection showing significant solid debris. **b** Endoscopic ultrasound-guided biflanged fully-covered self-expanding metallic stent deployment. **c** Endoscopic image showing biflanged fully-covered self-expanding metallic stent in stomach with draining gush fluid. **d** Direct endoscopic necrosectomy being carried out with snare, large chunk of debris is grasped.

### Post-procedure workup/treatment/care

Patients were reassessed post-procedure at 72 hours for improvement in symptoms, Systemic inflammatory response syndrome (SIRS), organ failure, and biochemical parameters. Contrast-enhanced computed tomography (CECT) of the abdomen was performed to evaluate changes in WON size, extension in paracolic/perirenal space and stent position (► Fig. 2). If there was new onset/persistence of SIRS or organ failure after 72 hours with residual collection, the patient was considered for necrosectomy. Patients were regularly monitored for improvement in their symptoms and resolution of SIRS. The patients who improved were discharged from the hospital and were asked to follow up at 3 weeks.

### Follow-up

After 3 weeks of drainage, patients were evaluated clinically and radiologically (CECT abdomen/CE magnetic resonance imaging [CEMRI] abdomen) for resolution of WON. Endoscopic retrograde cholangiopancreatography/magnetic resonance cholangiopancreatography was done to assess pancreatic ductal anatomy. All metal stents were removed at 3 weeks [10]. If residual WON persisted or patients had a disconnected pancreatic duct syndrome (DPDS) in the metal stent arm, the transmural metal stent was replaced by a plastic stent. In the plastic stent group, transmural plastic stents were kept in situ. Patients were followed up clinically and with abdominal ultrasound abdomen at 3 months to evaluate for recurrence of WON.



► **Fig. 2** a CECT showing large walled-off necrosis in lesser sac with extension in pararenal space. b CECT of the same patient after 72 hours showing significant reduction in size. c CECT showing large walled-off necrosis in lesser sac, compressing stomach. d CECT of the same patient after 72 hours of drainage showing significant reduction in size after drainage with metal stent.

## Definitions

1. WON: Encapsulated acute necrotic collection with a well-formed inflammatory wall, which matured after four weeks of acute necrotizing pancreatitis [1].
2. Symptomatic WON: infected WON, abdominal pain requiring daily analgesics, gastric outlet obstruction or extrahepatic biliary obstruction.
3. Percentage of solid debris: Two endosonographers assessed WON on EUS for amount of solid debris individually and noted their interpretation on a paper, both of whom were unaware of the other's result. The patient was enrolled only if on independent assessment, the solid debris was assessed as more than 20% by both endosonographers. The average of their results was considered as the final amount of solid debris for the study. The subsequent procedure was performed by a single endosonographer [12, 13].
4. Technical success: Successful placement of stent across the digestive lumen into WON cavity [10].
5. Treatment success: Radiological resolution plus clinical resolution at 3 weeks [10].
6. Radiological resolution: WON resolution or <3 cm residual cavity on CECT/CEMRI abdomen after 3 weeks of drainage.
7. Symptom resolution/clinical success: Complete symptom resolution after 3 weeks of drainage.
8. Duration of procedure: From needle puncture of WON to withdrawal of echoendoscope after completing procedure [9].
9. Significant bleeding: Hb drop >2 gm%, needed blood transfusion, endoscopic hemostasis, radiological intervention or surgery [14].

10. Ascites or pneumoperitoneum: new onset after procedure, which prolonged hospital stay or needed radiological or surgical intervention [14].
11. Stent migration: Either in gastrointestinal lumen or WON cavity before radiological resolution of WON.
12. Treatment failure: Need for salvage surgery or death [10].

## Outcomes

The primary outcome was to compare the treatment success rate at 3 weeks of drainage between the metal stent and plastic stent groups. Secondary outcomes were to compare technical success, duration of procedure, total number of procedures required to achieve treatment success, adverse events (AEs), and failure.

## Sample size calculation

Sample size was calculated based on non-inferiority trial design in which plastic stents were compared with metal stents in EUS-guided transmural drainage of WON. An available study on EUS-guided transmural drainage of WON reported a success rate of 94% with metal stents and 74% with plastic stents [4]. Assuming a success rate of 94% for a metal stent and 74% for a plastic stent, a one-sided test with a non-inferiority margin of 10% in favor of a metal stent, at 80% power with alpha error of 5%, and 30% dropout rate, the sample size calculated was 24 in each arm as per Pharma School sample size calculator (Binary non-inferiority).

## Randomization and allocation concealment

Patients meeting the inclusion criteria were randomly assigned to either the plastic stent group or the metal stent group using computer-generated block randomizations (block size of 4), generated by random allocation software (freely available online).

The random sequence generation was followed by allocation concealment using sequentially numbered opaque envelopes (SNOOSE method). The envelope was opened after EUS assessment demonstrated a solid debris >20%, and drainage was performed during the same procedure. Blinding was not implemented due to the apparent nature of the treatment and its visibility in follow-up cross sectional imaging.

## Statistical analysis

All data were entered in Microsoft Excel 2019 and analyzed using SPSS software version 23 (IBM). The dataset was scrutinized for outliers, errors, and missing values. Quantitative or numerical variables were expressed as measures of central tendency, such as mean along with measures of dispersion including standard deviation and standard error. Median and interquartile range (IQR) were used for non-normally distributed quantitative variables. The non-inferiority analysis was conducted for the primary objective (treatment success rate) using a two proportion non-inferiority test. Student's T test was applied for duration of procedure and number of procedures. A Mann-Whitney U test was applied in case of number of direct endoscopic necrosectomies, and duration of hospital stay. A Chi-square test was applied when the expected count was

more than five in all the quadrants of a 2x2 table. In case the expected count was less than 5, Fisher's exact test was applied.  $P < 0.05$  was considered statistically significant. Non-inferiority hypothesis testing was based on relative risk using Gartnam score method. All the outcomes were analyzed as per intention to treat principle.

### Ethical conduct of the study

The study was initiated following approval from the institutional ethics committee, as indicated by ethical letter no - INT/IEC/2020/SPL-680. Prior to enrollment into the study, informed written consent was received from all participants. This study is registered on ClinicalTrials.gov. Our study adheres to the Consolidated Standards of Reporting Trials (CONSORT) guidelines and the protocol aligns with the ethical principles outlined in the Declaration of Helsinki and Indian Council of Medical Research guidelines of 2007. All authors were granted access to the study data, and they have thoroughly reviewed and approved the final manuscript.

## Results

### Participant enrollment details

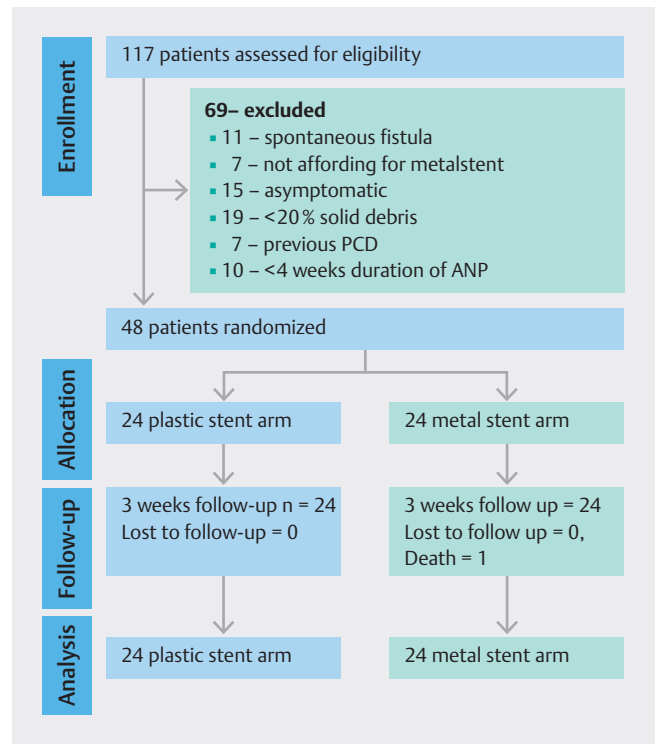
Between August 2020 and July 2021, a total of 117 patients with acute necrotizing pancreatitis (ANP) and WON as per Revised Atlanta Criteria [1] were assessed for inclusion. Among the 117 patients, 48 patients met the inclusion criteria. Ultimately, 24 patients were randomized in each study group. (► Fig. 3).

### Demographic characteristics

Both groups were comparable in terms of demographic profile, etiology of pancreatitis, comorbidity, presenting symptoms, and inflammatory markers (► Table 1). The characteristics of WON, including three-dimensional size, volume, location, extension of WON, percentage of solid debris, and distance from the stomach, were comparable in both groups (► Table 2).

### Primary outcome (treatment success)

Treatment success was achieved in 21 of 24 patients (proportion 1 i.e.,  $p_1 = 87.5\%$ ) and in 20 of 24 patients (proportion 2 i.e.,  $p_2 = 83.3\%$ ) in the metal stent and plastic stent groups, respectively, with  $P_1/p_2$  being 1.05 (95% confidence interval [CI], 0.81–1.39). Utilizing the Gartnam score method and assuming a non-inferiority margin of 10%, the  $P$  value for non-inferiority was  $< 0.001$ . In context of our non-inferiority trial, the null hypothesis posited that the plastic stent is inferior to the metal stent, while an alternate hypothesis suggested that a plastic stent is non-inferior to a metal stent. Given that the  $P$  value (for non-inferiority) falls below the predetermined threshold, we reject the null hypothesis, and conclude that the plastic stent is non-inferior to the metal stent. However, it is important to note that the lower limit of the CI also intersects the no-effect line (since the confidence interval encompasses 1), which indicates a lack of power to draw a definite conclusion.



► Fig. 3 CONSORT diagram [15].

### Secondary outcomes

#### Technical outcomes

Technical success was achieved in 100% of cases in both groups. In the metal stent group, five patients received LAMS and 19 patients received biflanged self-expanding metal stents. All patients in the plastic stent group were treated with two double-pigtail plastic stents. A transmural tract was consistently established via the stomach in the entire study cohort. The procedure duration, on average, was  $12.95 \pm 5.3$  minutes in the metal stent group and  $29.77 \pm 6.6$  minutes in the plastic stent group ( $P < 0.001$ ) (► Table 3).

#### Requirement for additional procedures

DEN was necessary in eight patients (33.3%) in the metal stent group and three patients (12.5%) in the plastic stent group ( $P = 0.086$ ). The median number of DEN procedures was one in the metal stent group and two in the plastic stents group. Additional percutaneous drainage was required for five patients in the metal stent group and one patient in the plastic stent group ( $P = 0.188$ ). The mean number of total procedures needed to achieve treatment success was 2.8 in the metal stent group and 2.2 in the plastic stent group ( $P = 0.097$ ) (► Table 3).

#### Adverse events and failure

The major AE was bleeding, which occurred in one patient from the metal stent and one patient from the plastic stent group ( $P = 0.945$ ). The patient in the plastic stent group experienced bleeding during the procedure after tract dilatation, with the likely source being a collateral within the wall of the WON.

► **Table 1** Patient demographic profiles, etiology of pancreatitis, presentation and preprocedural inflammatory markers.

Variable		Metal stent (n = 24)	Plastic stent (n = 24)
Sex	Male – n	18	20
	Female – n	6	4
Age (years)	Mean±SD	35.37±11.8	38.16±12.65
Height (cm)	Mean±SD	165.9±8.5	167.8±8.9
Weight (kg)	Mean±SD	61.39±6.9	62.39±8.1
BMI (kg/m <sup>2</sup> )	Mean±SD	22.2±2.4	22.3±2.4
Comorbidity	DM	2	2
	HCV	1	1
	CKD	0	1
Etiology	GSD	10	10
	Alcohol	9	10
	Unknown	5	3
	Trauma	0	1
Presentation	Pain-n	19	22
	GOO-n	11	8
	Infection-n	9	3
	EHBO-n	1	3
Onset of pancreatitis to drainage (weeks) Median, IQR (range)		8, 17.5 (4–60)	12, 10 (4–46)
Organ failure		1	1
CRP (mg/L), median, IQR (range)		51, 78 (3–283)	24, 81, (3–254)
Procalcitonin (ng/mL), Median, IQR (range)		0.06, 0.17 (0.02–0.84)	0.04, 0.1045 (0.017–0.5)
SIRS – n		10	4

BMI, body mass index; SD, standard deviation; DM, diabetes mellitus; HCV, hepatitis C virus; CKD, chronic kidney disease; GSD, gallstone disease; GOO, gastric outlet obstruction; EHBO, extrahepatic biliary tract obstruction; IQR, interquartile range; CRP, C-reactive protein; SIRS, systemic inflammatory response syndrome.

CECT angiography of the abdomen did not reveal a pseudoaneurysm. The patient was managed conservatively. This same patient had a second episode of bleeding 10 days after discharge, requiring surgical intervention. Following the surgery, the patient was doing fine and was followed up for 3 months. In the metal stent group, another patient experienced bleeding a week after drainage. The bleeding spontaneously ceased but necessitated a blood transfusion of 1 unit; CECT angiography did not reveal a pseudoaneurysm. Unfortunately, this patient later required one session of direct necrosectomy followed by surgical necrosectomy due to persistent uncontrolled sepsis. This patient was admitted with severe ANP during the first week and remained hospitalized for 50 days throughout the course of illness. Unfortunately, the patient developed septic shock and sadly, passed away after surgery.

In the metal stent arm, no patient had procedure-related pneumoperitoneum or new-onset ascites post-procedure. In the plastic stent group, two patients exhibited asymptomatic

pneumoperitoneum and one patient developed mild ascites post-procedure. However, none of these patients required any intervention. No stent migration was observed in the metal stent arm. Three patients in the plastic stent group reported passing the plastic stent in their stool after complete WON resolution. The study groups had comparable AE and treatment failure rates (► **Table 3**).

### Follow up

All patients were followed up for 3 months. In each study arm, 21 patients had DPDS. In the plastic stent group, stents were permanently left but in one patient, who required surgery. In the metal stent group, metal stents were replaced with plastic stents in 15 patients (62.5%). One patient underwent surgery, and seven patients had a completely collapsed cavity at the end of 3 weeks, precluding the possibility of replacement with a plastic stent. Only one patient experienced asymptomatic recurrence in the metal stent group at 3 months, observed on ab-

► **Table 2** WON characteristics.

Variable		Metal stent (n=24)	Plastic stent (n=24)	P value
Size (cm)	Transverse Mean±SD	13.704±3.5	11.417±3.04	<b>0.020</b>
	Anteroposterior Median, IQR (Range)	8.2, 4.2 (4.6–17.6)	7.5, 3.4 (3.4–12.7)	0.476
	Craniocaudal Median, IQR (Range)	7.95, 5.29 (3–26)	7.6, 4.28 (3.2–12.5)	0.509
Volume (mL) Median, IQR (range)		411, 710 (125–2148)	370, 328 (73–1230)	0.174
Location n (%)	Lesser sac	24 (100%)	22 (91.6%)	0.489
	Gastrosplenic	0	2 (8.3%)	
Extension of WON n	Peri renal space	8 (33.3%)	5 (20.8%)	0.454
	Paracolic space	1 (4.1%)	0	
	Perihepatic space	2 (8.3%)	2 (8.3%)	
% solid debris mean±SD		32.083±11.1	28.542±8.9	0.230

WON, walled-off necrosis; SD, standard deviation; IQR, interquartile range.

dominal US. Conversely, no recurrence was detected in the plastic stent group during the same period of follow up ( $P=1.000$ ) (► **Table 3**).

## Discussion

In the present study, the overall treatment success rate with EUS-guided drainage of WON was 85.41%. Treatment success was attained in 21 of 24 patients (proportion 1 i.e.,  $p_1=87.5\%$ ) in the metal stent group and 20 of 24 patients (proportion 2 i.e.,  $p_2=83.3\%$ ) in plastic stent group, resulting in  $P_1/p_2$  ratio of 1.05 (95% CI 0.81 to 1.39). Given that the  $P$  value (for non-inferiority) is below the predetermined threshold, we reject the null hypothesis, and conclude that the plastic stent is non-inferior to the metal stent. However, it is noteworthy that the lower limit of the CI crosses the no-effect line, indicating a lack of statistical power for a definite conclusion.

The findings from studies comparing metal and plastic stents for endoscopic drainage of WON are heterogenous. Similar to our study, retrospective studies have demonstrated no significant difference between metal or plastic stents. For instance, Mukai et al. reported no difference (97.7% versus 92.6%,  $P=0.31$ ), as did abuDayyeh et al. (94.8% versus 91.7%,  $P=0.55$ ), and Rana et al. (96.4% versus 98.5%,  $P=0.42$ ) [3, 5, 7]. Interestingly, even the RCTs by Lee et al. (87% versus 90.0%,  $P=-0.97$ ), Bang et al. (93.5% versus 96.6%,  $P=0.97$ ), and Karstensen JG et al. (94.7% versus 95.5%,  $P=1.0$ ) did not establish the superiority of metal stents over plastic stents for drainage of pancreatic fluid collections and WON, respectively [9, 10, 16]. A meta-analysis conducted by Bazerbach F et al. indicated that resolution with a single endoscopic procedure was similar between metal and plastic stents (47% vs 44%) [17]. However, lower treatment success rates with plastic stent have been observed in retrospective studies by Bapaye et al. (94.4%

vs. 73.7%,  $P<0.05$ ), Chen et al. (80.4% vs. 57.5%,  $P=0.001$ ), Siddiqui et al. (92.75% vs. 81%,  $P=0.0001$ ), and in our prior study (96.2% vs. 81.8%,  $P=0.04$ ) [4, 6, 8, 18]. In the present study, clinical success (symptom resolution 3 weeks after index procedure) was 90% and 95.5% in the metal and plastic stent groups, respectively ( $P=0.493$ ), indicating no significant difference between the two groups. Our data suggest that choice of stent (metal vs plastic) holds no implications for the eventual treatment and clinical success for WON with significant solid debris. This is likely because the larger diameter of the metal stent may not confer an actual advantage over multiple smaller-caliber plastic stents when the solid debris in the WON increases significantly.

In the metal stent group, a higher number of patients required direct necrosectomy or percutaneous catheter drainage compared with the plastic stent group; however, this difference did not reach statistical significance. Retrospective studies have hypothesized that a larger stent diameter could potentially contribute to more effective drainage, thus reducing the necessity for a DEN session [4]. We hypothesize that although larger stent diameter may contribute to early WON cavity collapsing by emptying the liquid contents, the choice of metal vs plastic stents makes no difference in terms of need for DEN in cases of WON with significant solid debris. One likely advantage of metal stents is feasibility of performing DEN through their lumen, often negating the requirement to remove and replace the stents after each DEN session, unlike plastic stents.

In the present study, the mean procedure duration was notably longer in the plastic stent group compared with the metal stent group (26.16±6.7 minutes vs. 12.60±5.13 minutes,  $P<0.001$ ). This outcome was anticipated, given the necessity for multiple exchange and tract dilatation when using a plastic stent. A similar finding was reported by Lee et al. (15.0 minutes vs. 29.5 minutes,  $P<0.01$ ) and Bang et al. (18±15.5 vs. 41.6

► **Table 3** Outcomes, adverse events and failure in metal stent and plastic stent groups.

Variable	Metal stent (n=24)	Plastic stent (n=24)	P value	
Technical success n (%)	24 (100%)	24 (100%)	1.00	
Duration of procedure				
Mean±SD (minute)	12.95±5.3	24.77±6.6	<0.001	
Median, IQR (Range)	13.05, 7 (3–22)	23.8, 6 (15–41)		
DEN required n (%)	8 (33.3%)	3 (12.5%)	0.086	
No. DEN Median, IQR (range)	1, 1.5 (1–4)	2, - (1–3)	1.000	
PCD placement	5 (20.8%)	1 (4.1%)	0.188	
No. of procedures (Mean ± SD)	2.8±1	2.2±1	0.097	
Duration of hospital stay Median, IQR (Range)	8.5, 11 (2–50)	5, 5 (1–31)	0.111	
Clinical success n (%)	22 (91.6%)	23 (95.8%)	1.000	
Radiological success n (%)	21 (87.5%)	20 (83.33%)	1.000	
Adverse events n (%)	Bleeding	1 (4.1%)	1 (4.1%)	1.000
	Pneumoperitoneum	0	2 (8.3%)	0.489
	New onset ascites	0	1 (4.1%)	1.000
	Stent migration	0	3 (12.5%)	0.113
Failure n (%)	Surgery	1 (4.1%)	1 (4.1%)	1.000
	Death	1 (4.1%)	0	
Indefinite plastic stent n (%)	15 (62.5%)	23 (95.8%)	0.024	
DPDS n (%)	21 (87.5%)	21 (87.5%)	1.000	
Recurrence n (%)	1 (4.1%)	0	1.000	

SD, standard deviation; IQR, interquartile range; DEN, direct endoscopic necrosectomy; PCD, percutaneous catheter drainage; DPDS, disconnected pancreatic duct syndrome.

±25.7 minutes,  $P < 0.001$ ) [9, 10]. The mean number of total procedures performed to achieve treatment success was comparable in the metal and plastic stent groups (2.8±1 vs. 2.2±1,  $P = 0.144$ ). The retrospective studies by Chen et al. (2.6±1.5 vs. 2.6±2.9,  $P = 0.09$ ) and Rana et al. (3.33 vs. 3.53,  $P = 0.28$ ) and the RCT by Bang et al. (2.8±1.2 vs. 3.2±1.5,  $P = 0.192$ ) also found no significant difference between metal and plastic stent groups in terms of number of total procedures to achieve treatment success [5, 8, 10].

Major AEs were a similar in the two groups. Bleeding emerged as the sole major AE, occurring in one patient in each group. None of the patients had stent-related bleed as reported in a recent RCT [10]. In the plastic stent group, three patients experienced spontaneous stent migration into the lumen after WON resolution, and none of them required intervention. The nature of plastic stents is to gravitate toward the lumen as the cavity collapses and eventual pass out spontaneously in stool. In addition, two patients in the plastic stent group developed pneumoperitoneum and one patient had new-onset ascites post-procedure - while no such complications were noted in the metal stent group. The increased risk of pneumoperito-

neum in the plastic stent group can be attributed to the need for significant tract dilatation. Nevertheless, all patients remained asymptomatic and were managed conservatively. Overall, no statistically significant difference in AEs was observed between the two groups.

DPDS was seen in 87.5% of patients in both groups. One patient in the metal stent group (2.08% of the entire study population) had recurrence. Basha et al. reported 73.8% prevalence of DPDS with recurrence in 13% patients over 18-month follow-up [19]. Because we included patients with WON with ≥20% solid debris, the rate of DPDS was higher in our study [10]. The low recurrence rate despite the high percentage of patients with DPDS in our study was likely due to the short duration of follow up.

Ours is the first RCT evaluating the efficacy of metal and plastic stents in EUS-guided drainage of WON with treatment success as the primary outcome. Because treatment success was defined by both clinical symptom resolution and radiological resolution, this is a more robust outcome parameter. In our study, we exclusively enrolled cases of WON with significant solid debris (>20%), a criterion that distinguishes our study from



prior studies and helps us study these difficult-to-treat groups of patients. To minimize confounding factors, we deliberately excluded patients with a prior drainage procedure (endoscopic or percutaneous). We ensured rigorous follow-up for all patients, and none of the patients were lost to follow up.

Our study, while contributing valuable insight, has a few limitations. Given the nature of the procedure, it was not feasible to blind the clinician and radiologist to the type of stent being placed, thus rendering our RCT open-label. Being a single-center study with relatively short duration of follow-up, our finding might have some limitations in terms of generalizability. Assessment of solid debris in WON may be observer-dependent, and gaining consensus from more endosonologists in that assessment could have increased reliability. It is worth noting that in the metal stent group, we used two different stents, but the minimal difference in their diameters diminishes the potential impact on our outcomes. Our 3-month follow-up relied on US to identify WON recurrence, even though abdominal CT is more adept at such evaluation. While US can detect collection, its capacity for in-depth assessment is suboptimal. The mean duration from onset of pancreatitis to cystogastrostomy was 8 to 12 weeks. By that time, solid material in the WON has often detached from the collection wall and partially liquified. Consequently, our result might not be uniformly applicable to cases of WON that drained earlier. Finally, despite performing a sample size calculation prior to the study, our study's statistical power may not be sufficient for unequivocal conclusions.

## Conclusions

To conclude, this RCT shows that plastic stents are not inferior to metal stents in transmural drainage of WON with significant solid debris (>20%). However, the duration of the drainage procedure is significantly shorter with metal stents. A larger multicenter study is needed to make definite conclusions.

## Conflict of Interest

The authors declare that they have no conflict of interest.

## Clinical trial

Trial registry: Clinical Trials Registry India (<http://www.ctri.nic.in/Clinicaltrials>)  
Registration number (trial ID): CTRI/2020/07/026740  
Type of Study: Randomized

## References

- [1] Banks PA, Bollen TL, Dervenis C et al. Classification of acute pancreatitis—2012: revision of the Atlanta classification and definitions by international consensus. *Gut* 2013; 62: 102–111
- [2] Rana SS, Sharma RK, Gupta P et al. Natural course of asymptomatic walled off pancreatic necrosis. *Digest Liver Dis* 2019; 51: 730–734
- [3] Mukai S, Itoi T, Baron TH et al. Endoscopic ultrasound-guided placement of plastic vs. biflanged metal stents for therapy of walled-off necrosis: a retrospective single-center series. *Endoscopy* 2015; 47: 47–55
- [4] Bapaye A, Dubale NA, Sheth KA et al. Endoscopic ultrasonography-guided transmural drainage of walled-off pancreatic necrosis: Comparison between a specially designed fully covered bi-flanged metal stent and multiple plastic stents. *Digest Endosc* 2017; 29: 104–110
- [5] Rana SS, Sharma R, Dhalaria L et al. Efficacy and safety of plastic versus lumen-apposing metal stents for transmural drainage of walled-off necrosis: a retrospective single-center study. *Ann Gastroenterol* 2020; 33: 426–432
- [6] Siddiqui AA, Adler DG, Nieto J et al. EUS-guided drainage of peripancreatic fluid collections and necrosis by using a novel lumen-apposing stent: a large retrospective, multicenter U.S. experience (with videos). *Gastrointest Endosc* 2016; 83: 699–707
- [7] Abu Dayyeh BK, Mukewar S, Majumder S et al. Large-caliber metal stents versus plastic stents for the management of pancreatic walled-off necrosis. *Gastrointest Endosc* 2018; 87: 141–149
- [8] Chen Y-I, Yang J, Friedland S et al. Lumen apposing metal stents are superior to plastic stents in pancreatic walled-off necrosis: a large international multicenter study. *Endosc Int Open* 2019; 07: E347–354
- [9] Lee B, Song T, Lee S et al. Newly designed, fully covered metal stents for endoscopic ultrasound (EUS)-guided transmural drainage of peripancreatic fluid collections: a prospective randomized study. *Endoscopy* 2014; 46: 1078–1084
- [10] Bang JY, Navaneethan U, Hasan MK et al. Non-superiority of lumen-apposing metal stents over plastic stents for drainage of walled-off necrosis in a randomised trial. *Gut* 2019; 68: 1200–1209
- [11] Rana S, Bhasin D, Kathiresan J et al. Do the morphological features of walled off pancreatic necrosis on endoscopic ultrasound determine the outcome of endoscopic transmural drainage? *Endosc Ultrasound* 2014; 3: 118
- [12] Pal P, Lakhtakia S, Jagtap N et al. Interobserver Agreement on “assessment of debris” during endoscopic ultrasound-guided drainage of walled-off pancreatic necrosis. *Tech Innov Gastrointest Endosc* 2023; 25: 213–220
- [13] Rana SS, Chaudhary V, Sharma R et al. Comparison of abdominal ultrasound, endoscopic ultrasound and magnetic resonance imaging in detection of necrotic debris in walled-off pancreatic necrosis. *Gastroenterol Rep (Oxf)* 2016; 4: 50–53
- [14] Cotton PB, Eisen GM, Aabakken L et al. A lexicon for endoscopic adverse events: report of an ASGE workshop. *Gastrointest Endosc* 2010; 71: 446–454
- [15] Butcher NJ, Monsour A, Mew EJ et al. Guidelines for Reporting Outcomes in Trial Reports: The CONSORT-Outcomes 2022 Extension. *JAMA* 2022; 328: 2252–2264
- [16] Karstensen JG, Novovic S, Hansen EF et al. EUS-guided drainage of large walled-off pancreatic necroses using plastic versus lumen-apposing metal stents: a single-centre randomised controlled trial. *Gut* 2023; 72: 1167–1173
- [17] Bazerbachi F, Sawas T, Vargas EJ et al. Metal stents versus plastic stents for the management of pancreatic walled-off necrosis: a systematic review and meta-analysis. *Gastrointest Endosc* 2018; 87: 30–42
- [18] Muktesh G, Samanta J, Dhar J et al. Endoscopic ultrasound-guided drainage of patients with infected walled-off necrosis: Which stent to choose? *Surg Laparosc Endosc Percutan Tech* 2022; 32: 335–341
- [19] Basha J, Lakhtakia S, Nabi Z et al. Impact of disconnected pancreatic duct on recurrence of fluid collections and new-onset diabetes: do we finally have an answer? *Gut* 2021; 70: 447–449