

Journal section: *Orthodontics*
Publication Types: *Review*

doi:10.4317/jced.58932
<https://doi.org/10.4317/jced.58932>

Impact of rapid maxillary expansion on mouth-breathing children and adolescents: A systematic review

Raquel-Harumi-Uejima-Satto Sakai ¹, Maira-Seabra de Assumpção ¹, José-Dirceu Ribeiro ¹, Eulalia Sakano ²

¹ Universidade Estadual de Campinas (Unicamp), Faculdade de Ciências Médicas, Departamento de Pediatria, Campinas, SP, Brazil

² Universidade Estadual de Campinas, Hospital das Clínicas, Departamento de Otorrinolaringologia, Campinas, SP, Brazil

Correspondence:
705 Frei Manoel da Ressurreição
13073-221, Campinas, SP, Brazil
clnicadraraquel@gmail.com

Received: 05/09/2021
Accepted: 11/10/2021

Sakai RHUS, Assumpção MS, Ribeiro JD, Sakano E. Impact of rapid maxillary expansion on mouth-breathing children and adolescents: A systematic review. J Clin Exp Dent. 2021;13(12):e1258-70.

Article Number: 58932 <http://www.medicinaoral.com/odo/indice.htm>
© Medicina Oral S. L. C.I.F. B 96689336 - eISSN: 1989-5488
eMail: jced@jced.es
Indexed in:
Pubmed
Pubmed Central® (PMC)
Scopus
DOI® System

Abstract

Background: Rapid maxillary expansion (RME) is an orthodontic procedure used to correct transverse maxillary deficiency. Due to the anatomical relationship between the palate and the nasal cavity, RME promotes an increase in nasal dimensions, which should hypothetically improve nasal respiratory function. **Objective:** This review aimed to systematically verify studies that assessed the effects of RME on nasal patency in mouth-breathing children and adolescents.

Material and Methods: An electronic search was performed in the MEDLINE databases via OVID, Scopus and EMBASE. The terms were: “children and adolescents”, “rapid maxillary expansion” and “mouth breathing”. The search was conducted in October 2019, according to the criteria of the Preferred Reporting Items for Systematic Reviews and Meta-Analyses (PRISMA). The assessment of the quality of the studies was conducted by two evaluators, using the Fowkes & Fulton’s guidelines for critical appraisal of medical research.

Results: 475 titles were identified and 18 articles were selected. All of them showed high methodological quality, but without randomized clinical trials. The instruments evaluated were: telerradiography, frontal postero-anterior radiography, computed tomography, acoustic rhinometry and computed rhinomanometry.

Conclusions: This review shows that RME promotes the enlargement of dental arches and of the nasal and maxillary structures, with improved mouth breathing in the short term. However, its long-term benefits could not be proved so far. More robust results of the effectiveness of RME in mouth breathing can be achieved with meta-analysis studies, with a consensual definition of the long-term follow-up period after RME.

Key words: *Child, adolescent, maxillary expansion, palatal expansion, mouth breathing.*

Introduction

Mouth-breathing children often have a narrow upper arch with high palate. These reduced nasal and maxillary transverse dimensions may be related to the increase in nasal flow resistance, observed in these children (1).

Transverse maxillary deficiency (TMD), also called maxillary atresia, when corrected at an early stage, improves the child's craniofacial and stomatognathic development, with beneficial effects on nasal breathing (2,3,4). The most frequently used orthodontic procedure for the correction of TMD is the rapid maxillary expansion (RME), which, through a fixed orthodontic expander positioned on the palate, causes the opening of the median palatal suture (5). Due to the anatomical relationship between the palate and the nasal cavity, RME promotes an increase in nasal dimensions, which should hypothetically improve nasal respiratory function (6-8).

Radiographic exams have proved the effects of RME on dental, nasal and maxillary structures (9). Three-dimensional CT imaging techniques have been increasingly used, with more accurate measurements, without overlapping structures of two-dimensional radiographs, but with a larger amount of radiation (10). International protocols are still being researched with the aim to optimize the amount of radiation used in volumetric cone-beam computed tomography (CBCT), especially in children and adolescents (11).

Several authors (12-14) report the immediate improvement in mouth breathing due to the increase in the nasal base with RME. However, some studies have not provided evidence of its stability in the long term (15,16). The evaluation of the respiratory function of the functional changes of children and adolescents mouth breathers (MB) allows these patients to be followed up, based on medical evaluations and complementary exams. The importance of evaluating these individuals is emphasized, with the possibility of respiratory function being reestablished with the early performance of ERM.

The present systematic review aimed to verify the effects of RME in MB (children and adolescents) on naso-maxillary structures and on nasal respiratory function, as well as to verify if RME remains unchanged in the long term.

Material and Methods

-Search strategy

The search for scientific articles was conducted using the MEDLINE databases via Ovid, Scopus and EMBASE. The search included descriptors and their variant forms based on the Medical Subject Headings (MeSH), DeCs (Health Descriptors) and Emtree (Embase Subject Headings) that identified "rapid maxillary expansion", "mouth breathing" and "children and adolescents". Studies in English and French were selected, without date restrictions. The search was carried out from November

2018 to October 2019. The detailed search strategy with the terms used can be found in the APPENDIX.

-Study selection

The systematic review followed the Preferred Reporting Items for Systematic Reviews and Meta-Analyses (PRISMA) criteria (17). Two independent evaluators conducted the selection of the studies according to pre-established criteria. In case of disagreement, a third evaluator was consulted for a final decision (Fig. 1). At first, the duplicates were selected and removed, and then, the titles and abstracts were screened. Subsequently, the remaining articles were read in full, following the inclusion and exclusion criteria described below. Ultimately, a manual search of the references of the selected studies was performed.

-Inclusion and exclusion criteria

The following inclusion criteria were used: (i) original studies; (ii) studies with mouth-breathing children and adolescents, which evaluated the effects of mouth breathing on nasal respiratory function using RME; (iii) cohort, controlled or randomized longitudinal studies; and (iv) studies published in full in English or French.

The following exclusion criteria were used: (i) book chapters, theses, dissertations, retrospective studies, editorials, letters, abstracts, comments, editorials, presentations in congress, symposia, seminars, round table and debates, post scripts, patents, case reports and case series; (ii) studies that were not available in full on the internet even after contacting the authors; (iii) systematic reviews, literature reviews or meta-analyses; (iv) qualitative studies; (v) studies in which the RME procedure was performed only on nasal breathers and not on mouth breathers; (vi) studies without a diagnosis of nasal breathing pattern; (vii) studies without assessing nasal respiratory function before and after RME; (viii) studies that did not perform RME; and (ix) studies that included adult populations.

-Data extraction

The following data were extracted from the selected studies: nationality, study design, sample size, age and sex of the study group and the control group and instruments evaluated (Table 1, 1 cont). More detailed information such as objective of the study, main results and conclusions were summarized in Table 2, 2 cont., 2 cont.-1, 2 cont.-2.

-Evaluation of Methodological Quality of Studies

The quality of the studies was assessed by two evaluators, using the guidelines for appraisal of medical research proposed by Fowkes & Fulton (18). The questions associated with the evaluated parameters were scored as major (++), minor (+), absent (0) or not applicable (NA). Each study received an initial score of 46 points, with one parameter subtracted from each parameter (+) and two points from each parameter scored with (++). After this process, the evaluators proceeded to the final score, to classify the studies as: low quality (0-14), middle quality (15-30) and high quality (31-46) (Table 3).

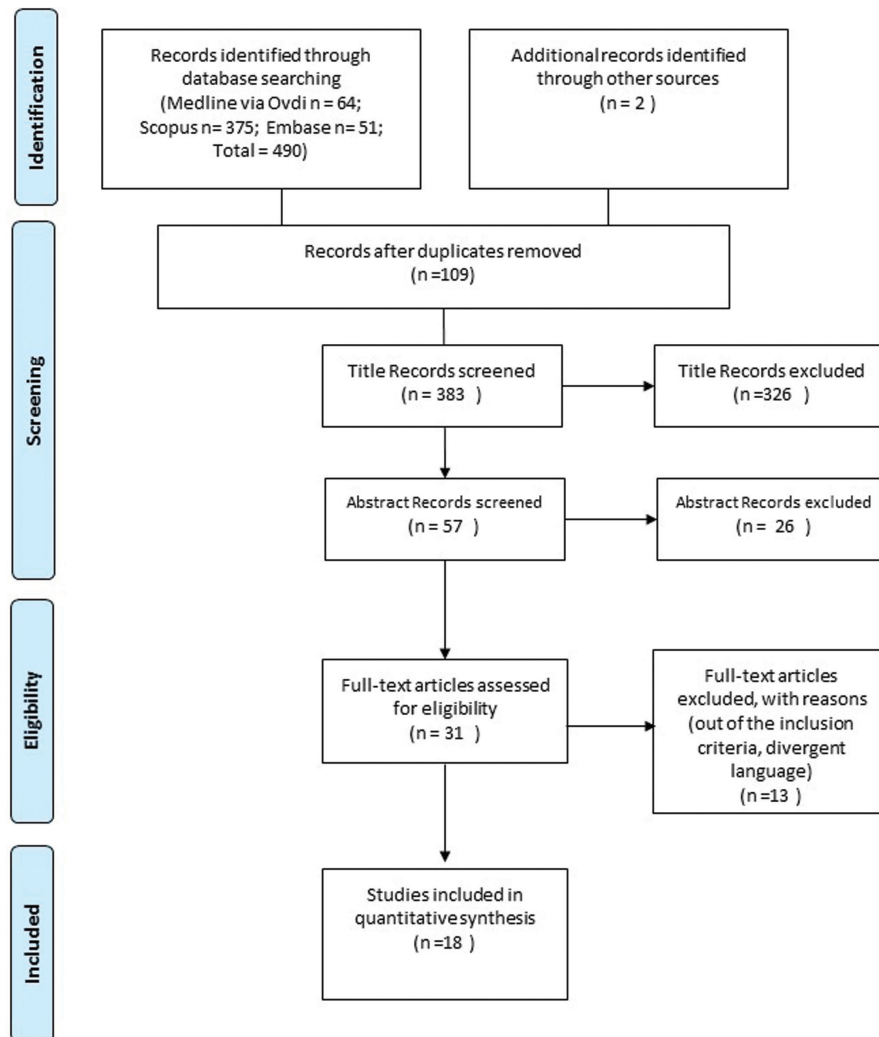


Fig. 1: PRISMA.

All studies analyzed in this systematic review were classified as controlled clinical trials, as they are experimental studies that used the RME orthodontic intervention (Table I). Fowkes and Fulton (16) proposes that in this type of study the results of the treatment group should be compared with another group with similar characteristics that have not received the intervention. Thus, the studies that did not include any comparison group received the score (++) in this first stage of assessment of methodological quality. Studies with a divergent comparison group of mouth breathers with TMD received a score (+). Studies with a wide age range, which did not separately analyze groups of children with groups of adolescents, received a score (++) in the item source of sample. Articles with less than 20 individuals and without a sample size calculation received a score (++) in the sample size item.

Results

-Search and Selection

This systematic review identified 490 titles in the databases, making a total of 18 articles for this systematic review (Fig. 1).

The abstract screening process excluded articles that did not meet the pre-established criteria. For the full articles, one study was excluded as the language did not meet the eligibility criteria: the abstract was in English, but the full article was in Chinese. Other studies were also excluded due to inadequate methodology: retrospective studies, absence of diagnosis of mouth breathing, sample without history of respiratory diseases of the upper airways, nasal hypertrophy or respiratory allergies, absence of nasal respiratory function assessment after RME. Ultimately, one article was excluded because it included adults.

Table 1: Analysis of samples, orthodontic appliances and instruments used in each study.

Study	Country	Design	Population	N	Age in years(a)	Orthodontic Appliances	Instruments
Helal <i>et al.</i> 2019 (27)	USA	Controlled Trial	MB	91	5-13a. mean=7.6a	Bonded Hyrax Expander	Pediatric Sleep Questionnaire
Badreddine <i>et al.</i> 2018 (2)	Brazil	Controlled Trial	MB	39	6.5-14.7a. mean= 9.7±2.28a	Hyrax	Computed tomography
					16 controls with TMD		
Cappellette <i>et al.</i> 2017 (3)	Brazil	Controlled Trial	MB	23	6.4-14.2a. mean=9.6± 2.3a	Hyrax	Computed tomography
					15 controls with TMD		
Cappellette <i>et al.</i> 2017 (12)	Brazil	Controlled Trial	MB	61	6.5-13.1 a. mean=9.6a	Hyrax	Postero-anterior radiography
Izuka <i>et al.</i> 2015 (6)	Brazil	Controlled Trial	MB	25	6-13a. mean=10.5±2.2a	Modified Biedermann	Cone-beam tomography and Questionnaire
Itikawa <i>et al.</i> 2012 (21)	Brazil	Longitudinal Controlled Trial	MB	29	7-10a	Hass	Postero-anterior radiography, acoustic rhinometry and active anterior computed rhinomanometry
Pereira <i>et al.</i> 2012 (7)	Brazil	Longitudinal Controlled Trial	MB	Group A: 20 Group B: 33; Subgroups:16 without RME, 17 with RME	6-12a	Hyrax	Postero-anterior radiography and cephalometric analysis
Torre <i>et al.</i> 2012 (14)	Spain	Longitudinal Controlled Trial	MB NB	44 44 controls without TMD	mean=10.57a	Hyrax	Orthodontic model analysis and peak inspiratory nasal flow
					mean=10.64a		
Langer <i>et al.</i> 2011 (15)	Brazil	Longitudinal Controlled Trial	MB	25	7 -10a, mean=8.2a	Modified Hass	Active anterior computed rhinomanometry and cephalometric analysis
					7-10a		
Matsumoto <i>et al.</i> 2010 (16)	Brazil	Longitudinal Controlled Trial	MB	27		Modified Hass	Active anterior computed rhinomanometry, acoustic rhinometry and postero-anterior radiography

Table 1 cont.: Analysis of samples, orthodontic appliances and instruments used in each study.

Monini <i>et al.</i> 2009 (13)	Italy	Longitudinal Controlled Trial	MB NB	65 50 controls without TMD	5-10a, mean=7,85 ± 2,15a	Modified Hyrax	Cephalometric analysis and active anterior computed rhinomanometry
Giuca <i>et al.</i> 2009 (25)	Italy	Longitudinal Controlled Trial	MB without allergies	17	6-12a	Modified Hyrax	Cephalometric analysis, postero-anterior radiography and active anterior computed rhinomanometry
Cappellette <i>et al.</i> 2008 (19)	Brazil	Controlled Trial	MB	50 20 controls without TMD	4-14a 4-11a	Modified Biedermann	Acoustic rhinometry
Cozza <i>et al.</i> 2007 (24)	Italy	Controlled Trial	MB with hearing loss due to middle ear otitis	24	6-8a, mean=7a	Butterfly Expander	Orthodontic model analysis, audiometry, acoustic rhinometry and impedance
Compadretti <i>et al.</i> 2006 (23)	Italy	Longitudinal Controlled Trial	MB NB	27 24 controls with TMD	5-13a, mean=9,5 ±2,1a 8-12a, mean=10,2±1,5a	Hyrax	Active anterior computed rhinomanometry, acoustic rhinometry. Postero-anterior radiography was performed in 15 patients
Compadretti <i>et al.</i> 2006 (22)	Italy	Longitudinal Controlled Trial	Non-allergic MB without deviated septum	14	7-10a, mean=8,2a	Hyrax	Acoustic rhinometry and postero-anterior radiography
Enoki <i>et al.</i> 2006 (20)	Brazil	Longitudinal Controlled Trial	MB	29	7-10a	Hass	Cephalometric analysis and acoustic rhinometry
Pirelli <i>et al.</i> 2005 (26)	Italy	Longitudinal Controlled Trial	MB with snoring and sleep apnea	42	6-13a, mean=7,3a	Modified Hyrax	Audiometry, tympanometry, active anterior computed rhinomanometry, daytime sleepiness questionnaire and polysomnography

Note: MB – mouth breathers; NB – nasal breathers; RME – rapid maxillary expansion; TMD – transverse maxillary deficiency.

Table 2: Analysis of objectives, variables, follow-up period, main results and conclusions.

Study	Objective	Variables	Follow-up period	Main findings	Conclusions
Helal N <i>et al.</i> 2019 (27)	To investigate parents' perceptions of breathing pattern changes after their children had undergone RME	1) sleep apnea and breathing patterns, 2) sleep quality and fatigue (3) behavior	Pre-RME and 6 months after RME	SC: The increase in nasal area assessed by CBCT was 4.1mm ² , analyzed in only six children FC: The symptoms of mouth breathing perceived by the parents decreased by 31.5%	Parents noticed improvement in sleep quality and breathing patterns with RME
Badreddine <i>et al.</i> 2018 (2)	To evaluate effects of RME on the skeletal and soft tissue structures in MB	CT: Nasal height and width measurements of bone and soft tissues of the nose	Pre-RME and 3 months after RME	SC: Significant increases in all the skeletal and soft tissue variables and width of the piriform aperture when compared with the control group	RME caused alterations in skeletal and soft tissue structures in the short term
Cappellette <i>et al.</i> 2017 (3)	To evaluate the volumetric changes of the nasomaxillary complex in MB with RME	CT: Nasomaxillary, nasal, oropharyngeal and maxillary sinus volumes	Pre-RME and 3 months after RME	SC: The experimental group had a significant increase in the variables analyzed in comparison with the control group	RME caused volumetric increases in the nasal cavity, oropharynx and maxillary sinuses
Cappellett <i>et al.</i> 2017 (12)	To evaluate the effects of RME on the skeletal dimensions of the nasal cavity and to compare the differences between males and females	OMA: intermolar distance; PAR: nasal height, nasal and maxillary widths	Pre-RME and 3 months after RME	SC: Increases in all linear maxillary measurements and nasal cavity dimensions	RME promoted increases in nasal cavity volume. Nasal transverse alterations were not significant in association with sex
Izuka <i>et al.</i> 2015 (6)	To assess short-term changes in the upper airways and quality of life in MB after RME	CBCT: nasal base widths; volume of the nasopharynx and oropharynx airways; QLQ	Pre-RME and immediately after RME	SC: Increases in the width of the nasal floor, volumes of the nasopharynx and nasal cavities FC:QLQ indicated improvement in patients' quality of life after RME	RME promoted a significant dimensional increase in the nasal cavities and nasopharynx and improved the patients' quality of life

Table 2 cont.: Analysis of objectives, variables, follow-up period, main results and conclusions.

<p>Itikawa <i>et al.</i> 2012 (21)</p>	<p>To assess the effects of RME on nasal cavity dimensions and facial morphology using AR and CR</p>	<p>PAR: nasal width, intermaxillary and interzygomatic distances; CR: inspiratory and expiratory nasal resistance; AR: MCA1; MCA2</p>	<p>Pre-RME, immediately after RME and 90 days after RME</p>	<p>SC: Increases in the dimensions of the nasal cavity and jaw bone. There were no significant differences in the nasal area using AR FC: CR showed a decrease in nasal resistance after RME</p>	<p>RME increased the maxillary and nasal bone area, but did not improve nasal resistance</p>
<p>Pereira <i>et al.</i> 2012 (7)</p>	<p>To observe craniofacial changes after adenotonsillectomy and to verify the importance of adding RME to treatment</p>	<p>PAR: nasal and intermaxillary widths; CM: cephalometric measurements</p>	<p>Pre-RME and 14 months after adenotonsillectomy</p>	<p>SC: Adenotonsillectomy balanced transversal, sagittal and vertical growth in both groups, and was more effective in the group undergoing combined treatment (RME and Adenotonsillectomy)</p>	<p>Adenotonsillectomy improved facial growth in children with obstructive hypertrophy, being more effective when associated with RME</p>
<p>Torre <i>et al.</i> 2012 (14)</p>	<p>To analyze changes in nasal airflow after RME</p>	<p>OMA: intercanine, premolar and intermolar widths; PINF: peak inspiratory nasal flow</p>	<p>Pre-RME, 6 after RME and 12 months after RME</p>	<p>SC: Increases in maxillary widths. FC: Six months after RME, there was a significant improvement in PINF in the RME group in relation to control</p>	<p>Nasal airflow improved in mouth-breathing children, six months and one year after RME</p>
<p>Langer <i>et al.</i> 2011 (15)</p>	<p>To assess the effects of RME on the dimension of the nasopharyngeal space and its relationship with nasal resistance</p>	<p>CM: nasopharyngeal space; CR: inspiratory and expiratory nasal resistance</p>	<p>Pre-RME, immediately after RME, 90 days after RME and 30 months after RME</p>	<p>SC: Differences in the nasopharyngeal area observed only in 30 months could be explained by facial growth, and not because of the RME. FC: Decreased nasal resistance immediately after RME, without remaining stable 30 months after RME</p>	<p>RME did not interfere with nasal resistance and nasopharyngeal area in the long-term evaluation</p>

Table 2 cont.-1: Analysis of objectives, variables, follow-up period, main results and conclusions.

<p>Matsumoto <i>et al.</i> 2010 (16)</p>	<p>To assess the effects of RME in the nasal cavity using AR and CR and to determine nasal and maxillary widths 30 months after RME.</p>	<p>PAR: nasal width and interzygomatic distance; CR: inspiratory and expiratory nasal resistance; AR: MCA1 and MCA2</p>	<p>Pre-RME, immediately after RME, 90 days after RME and 30 months after RME</p>	<p>SC: Increased nasal and maxillary widths. AR values did not show any difference between the evaluation times after RME</p>	<p>The decrease in nasal resistance in 90 days did not remain stable in the period of 30 months after RME</p>
<p>Monini <i>et al.</i> 2009 (13)</p>	<p>To assess the effects of RME on nasal flow and nasal resistance and correlate with anterior and/or posterior nasal obstruction.</p>	<p>Inspiratory and expiratory nasal pressure; nasal flow in the standing and supine positions</p>	<p>Pre-RME, immediately after RME and 1 year after RME</p>	<p>FC: Improvement of nasal flow and nasal resistance in supine position. Less noticeable changes were observed in isolated forms of obstruction in the standing position</p>	<p>RME was efficient in improving nasal breathing due to enlargement in the nasopharyngeal cavity</p>
<p>Giuca <i>et al.</i> 2009 (25)</p>	<p>To assess the relationship between crossbite and upper airway permeability, and to observe cephalometric changes in the rhinopharyngeal space after RME.</p>	<p>CM: Lateral analyses of Ricketts, Woodside, Linder-Aronson and Lundstrom; PAR; CR: inspiratory flow and resistance</p>	<p>CM: Pre-RME, 6 and 12 months after RME; CR: Pre-RME and 12 months after RME</p>	<p>SC: CM showed an increase in the rhinopharynx and the PAR showed an increase in the nasal dimension FC: Three children had improved nasal flow and resistance, six children showed no changes and there was a worsening of nasal breathing in eight children</p>	<p>The enlargement in the nasal structures did not correspond to the improvement in airway resistance</p>
<p>Cappellette <i>et al.</i> 2008 (19)</p>	<p>To analyze possible increases in nasal dimensions after RME using AR</p>	<p>AR: MCA1, MCA2, VOL1 and VOL2</p>	<p>Pre-RME, immediately after RME</p>	<p>SC: Increase in most variables of nasal area and volume after RME within the treatment group, except MCA1 and VOL2 in the left nostril. Increase in VOL2 only in the right nostril after RME when compared to the control group</p>	<p>Children with transverse maxillary deficiency, undergoing RME had a longitudinal maxillary and alveolar arch enlargement, associated with enlarged nasal dimensions</p>

Table 2 cont.-2: Analysis of objectives, variables, follow-up period, main results and conclusions.

Cozza <i>et al.</i> 2007 (24)	To investigate MB with atypical chewing, the effects of RME on inspiratory nasal resistance and hearing loss	OMA: intercanine and intermolar distances, maxillary depths	Pre-RME, immediately after RME	SC: increases in nasal cavity width and in transverse dimension of the upper arch. FC: Reduced nasal resistance, increased nasal flow and improved hearing loss	RME promoted improvement in nasal resistance and hearing loss
Compadretti <i>et al.</i> 2006 (23)	To assess the effects of RME using AR, CR and cephalometry.	PAR: nasal width, intermaxillary and interzygomatic distances; CR: inspiratory and expiratory nasal resistance; AR: MCA, VOL	Pre-RME and 12 months after RME	SC: Significant increase in nasal areas and volumes, nasal and intermolar distances FC: Significant reduction in inspiratory nasal resistance	RME was an effective procedure in increasing nasal width and improving mouth breathing
Compadretti <i>et al.</i> 2006 (22)	To assess the effects of RME on the nasal geography using AR	AR: MCA; PAR: nasal width and intermaxillary distance	AR: Pre-RME and 12 months after RME; PR: Pre-RME and 3 months after RME	SC: Increase in maxillary width in all patients. Rhinometric and cephalometric measurements showed an increase in the total decongested nasal volume and in the width of the nasal cavity. Only eight children became nasal breathers	RME promoted significant increases in nasal volumes and maxillary width. However, the improvement in breathing pattern remained debated
Enoki <i>et al.</i> 2006 (20)	To assess the effects of RME on the nasal cavity using AR and CR	AR: MCA1, MCA2; CR: inspiratory and expiratory resistance	Pre-RME, immediately after RME and 90 days after RME	SC: There was no difference in the nasal area between the periods analyzed FC: There was statistically significant reduction in nasal resistance after the expansion	RME lessened nasal resistance, although there was no difference in nasal geometry in AR
Pirelli <i>et al.</i> 2005 (26)	To assess whether RME can improve patency of nasal airway and OSAS	PAR: nasal, intermaxillary and intermolar widths; CBCT; Polysomnography; AR	Pre-RME, 30 days and 4 months after RME	SC: RME enlarged the nasal fossa and released the septum FC: RME improved the nasal air flow and the OSAS	RME intervention was effective in children affected by OSAS, without any other obvious upper airway obstruction

Note: AR – acoustic rhinometry; CBCT – cone-beam computed tomography; CM – cephalometric measurements performed with telerradiography; CR – active anterior computed rhinomanometry; CT – computed tomography; FC-functional changes; MB – mouth breathers; MCA – minimal cross-sectional area; OMA – orthodontic models analysis; OSAS – obstructive sleep apnea syndrome; PAR – postero-anterior radiography; PINF – peak inspiratory nasal flow; QLQ – quality of life questionnaire; RME – rapid maxillary expansion; SC-structural changes; VOL– nasal volume.

Table 3: Analysis of the quality of the studies according to Fowkes and Fulton.

			Helal et al. ²⁷	Badredine et al. ²	Cappellette et al. ³	Cappellette et al. ¹²	Izuka et al. ⁶	Itikawa et al. ²⁰	Pereira et al. ⁷	Torre et al. ¹⁴	Langer et al. ¹⁵	Matsumoto et al. ¹⁶	Monini et al. ¹³	Giuca et al. ²⁵	Cappellette et al. ¹⁹	Cozza et al. ²⁴	Comparedretti et al. ²³	Comparedretti et al. ²²	Enoki et al. ²⁰	Pirelli et al. ²⁶	
Study design appropriate to objectives?	Objective	Common Design																			
	Prevalence	Crosssectional	NA	NA	NA	NA	NA	NA	NA	NA	NA	NA	NA	NA	NA	NA	NA	NA	NA	NA	NA
	Prognosis	Cohort	NA	NA	NA	NA	NA	NA	NA	NA	NA	NA	NA	NA	NA	NA	NA	NA	NA	NA	NA
	Treatment	Controlled trial	++	0	0	++	++	++	0	+	++	++	+	++	+	++	+	++	++	++	++
Study sample representative?	Cause	Cohort, case-control, cross-sectional	NA	NA	NA	NA	NA	NA	NA	NA	NA	NA	0	NA	NA	NA	NA	NA	NA	NA	NA
	Source of sample		0	+	+	0	0	0	0	0	0	0	0	0	+	0	0	0	0	0	0
	Sampling method		0	0	0	0	0	0	0	0	0	0	0	+	0	+	+	+	0	0	0
	Sample size		0	0	0	0	+	+	0	0	0	0	0	++	0	0	0	++	0	0	0
Control group acceptable?	Entry criteria/exclusions		0	0	0	0	0	0	0	0	0	0	0	0	0	0	0	0	0	0	0
	Non-respondents		0	0	0	0	0	0	0	0	0	0	0	0	0	0	0	0	0	0	0
	Definition of controls		NA	0	0	NA	NA	NA	0	0	NA	NA	0	NA	0	NA	0	NA	NA	NA	NA
	Source of controls		NA	0	0	NA	NA	NA	0	0	NA	NA	0	NA	0	NA	0	NA	NA	NA	NA
Quality of measurements and outcomes?	Matching/randomization		NA	++	++	NA	NA	NA	++	0	NA	NA	0	NA	0	NA	0	NA	NA	NA	NA
	Comparable characteristics		NA	0	0	NA	NA	NA	0	+	NA	NA	+	NA	+	NA	+	NA	NA	NA	NA
	Validity		0	0	0	0	0	0	0	0	0	0	0	0	0	0	0	0	0	0	0
	Reproducibility		0	0	0	0	+	+	0	0	+	+	0	+	0	0	0	+	0	+	+
Distorting influences?	Blindness		0	0	0	0	0	0	0	0	0	0	0	0	0	0	0	0	0	0	0
	Quality control		0	0	0	0	0	0	0	0	0	0	0	0	0	0	0	0	0	0	0
	Compliance		+	0	0	0	0	0	0	0	0	0	0	0	0	0	+	0	0	0	0
	Drop-outs		0	0	0	0	0	0	0	0	0	0	0	0	0	0	0	0	0	0	0
	Deaths		0	0	0	0	0	0	0	0	0	0	0	0	0	0	0	0	0	0	0
	Missing data		0	0	0	0	0	0	0	0	0	0	0	0	0	0	0	0	0	0	0
	Extraneous treatments		0	0	0	0	0	0	0	0	0	0	0	0	0	0	0	0	0	0	0
	Contamination		0	0	0	0	0	0	0	0	0	0	0	0	0	0	0	0	0	0	0
Summary questions	Changes over time		0	0	0	0	0	0	0	0	0	0	0	0	0	0	0	0	0	0	0
	Confounding factors		0	0	0	0	0	0	0	0	0	0	0	0	0	+	+	0	0	0	0
	Distortion reduced by analysis		0	0	0	+	0	0	0	0	0	0	0	0		0	0	0	0	0	0
	Bias—Are the results erroneously biased in a certain direction?		NO	NO	NO	NO	NO	NO	NO	NO	NO	NO	NO	NO	NO	NO	NO	NO	NO	NO	NO
FINAL SCORE	any serious confounding or other distorting influences?		NO	NO	NO	NO	NO	NO	NO	NO	NO	NO	NO	NO	NO	NO	NO	NO	NO	NO	NO
	the results occurred by chance?		NO	NO	NO	NO	NO	NO	NO	NO	NO	NO	NO	NO	NO	NO	NO	NO	NO	NO	NO
			43	43	43	43	42	42	44	44	43	43	44	40	43	42	41	40	44	43	
			High Quality	High Quality	High Quality	High Quality	High Quality	High Quality	High Quality	High Quality	High Quality	High Quality	High Quality	High Quality	High Quality	High Quality	High Quality	High Quality	High Quality	High Quality	High Quality

0: No problem, +: Minor problem, ++: Major Problem, NA: Not applicable.

-Study characteristics

Most studies (10/18) were conducted in Brazil (2,3,6,12,15,19,20,21), six in Italy (13, 22-26) , one in Spain (14) and one in the USA (27). The studies dated from 2005 to 2019 (Table 1).

Only seven articles included a control group without the intervention of RME, but these varied according to the type of breathing (nasal or mouth) and as to the presence or absence of TMD (Table I). Four studies (2,3,7,19) included MB (three with TMD (2,3,7)). Some studies (13,23,14) assessed nasal breathers (NB), one with TMD (23).

-Evaluated Instruments

The main instruments evaluated were: teleradiography (cephalometric measurements) (7,13,15,20,25), frontal

postero-anterior radiography (nasal and maxillary widths) (3,16,21-computed tomography (three-dimensional airway measurements) (2,3), acoustic rhinometry (minimal cross-sectional area (MCA) and nasal volume (VOL)), computed rhinomanometry (respiratory resistance), analysis of orthodontic models (intercanine, intermolar and palate depth) and questionnaires on mouth breathing and quality of life (6). Only three studies evaluated using computed tomography scans (2,3,6) with only one using cone-beam computed tomography (6) (Table 2).

-Quality of Studies

The 18 selected studies were classified with high methodological quality (Table III) according to the appraisal guidelines proposed by Fowkes and Fulton (18).

Discussion

In order to assess the effects of RME on naso-maxillary structures and nasal patency in MB as well as to verify the stability of these variables in the long term, the present review found that most studies (16/18) showed an increase in naso-maxillary structures (nasal cavity, oropharynx, nasopharynx, maxillary sinuses, maxillary width and dental arches) with RME (2,6,16,27). The effects on soft tissue structures of the nose were found on computed tomography scans three months after RME in the study by Badreddine *et al.* (2), for example.

Structural changes were detected by postero-anterior radiographic examinations, teleradiographs, conventional CT scans, cone-beam CT scans, dental arch models and acoustic rhinometry examinations (3,19,12,22,23).

In the study by Langer *et al.* (15), differences in nasopharyngeal space were found only after 30 months of RME, and could be explained by facial growth, and not because of the orthodontic procedure. In the study carried out by Enoki *et al.* (20), no statistically significant differences were observed in the measurements of the minimum cross-sectional area of the nasal valve and the inferior nasal concha with acoustic rhinometry, despite the improvement in nasal resistance with RME.

Functional changes were evaluated in eleven studies, through tests that provide objective data on nasal breathing such as active anterior computed rhinomanometry and peak inspiratory nasal flow, in addition to subjective tests. Among the studies analyzed, only Izuka *et al.* (6) and Helal *et al.* (27) used standardized questionnaires on respiratory patterns and symptoms, answered by the parents, showing improvement in the outcomes of the respiratory variables with RME.

Eight studies reported improvement in nasal respiratory function immediately after RME (6,13,14,21,22,24,26). Monini *et al.* (13), in a study with 65 children submitted to RME compared to 50 children in the control group, found differences in nasal flow and resistance in the supine and orthostatic positions immediately and 12 months after RME. Likewise, Compadretti *et al.* (23) found a similar result in nasal resistance after the same follow-up period.

There was little evidence of absence of variation in respiratory flow after RME. In the study by Itikawa *et al.* (21), inspiratory nasal resistance returned to baseline values 90 days after RME. The same fact was observed by Matsumoto *et al.* (16), in the follow-up period of 30 months after RME, with the values of nasal resistance practically returned to baseline values. Such effects were related to the hypertrophied nasal mucosa, given that allergic rhinitis was the main cause of mouth breathing in these children.

Giuca *et al.* (25) reported a decrease in airway resistance in the active anterior rhinomanometry test in only three children, with six children showing no changes; airway

resistance worsened in eight children during a follow-up period of 12 months after RME. In this study, no analysis was performed immediately after RME, showing an increase in structures. Therefore, no correlations were noted between nasal function and the RME procedure.

The enlargement of nasal structures with RME may cause an immediate improvement in breathing, but the persistence of the inflammatory process in the nasal mucosa is likely to favor the recurrence of hypertrophy of the nasal mucosa. When RME is indicated, it must be performed during the treatment or after treating the cause of the nasal obstruction (16).

For RME to be effective, it must be performed before the fusion of the medial palatal suture begins. Studies with cone-beam computed tomography found the beginning of the fusion of the median palatal suture in the palatal bone (a stage of sutural ossification called stage D (28)) in some female individuals at 11 years of age and male from 14 years of age. Therefore, in cases of RME, the structural bone age should be evaluated and not only the chronological age. Individuals who have advanced stages of sutural ossification may need complementary treatments such as RME, with the need for surgical intervention, either with micro-implant assisted rapid palatal expander (MARPE) or surgically assisted rapid maxillary expansion (SARPE) (28).

Imaging exams are important to assess the effects of RME on the medial palatine suture. CT scans allow better visualization of anatomical structures even in the presence of the palatal expander, minimizing the effects of radiographic artifacts (29).

In this review, the following orthodontic appliances were used: the Hyrax and modified Hyrax orthodontic appliances (14 studies) and the Hass and modified Hass appliances (4 studies). Also, the modified Biederman and Butterfly appliances were considered as modified Hyrax appliances.

The studies showed diverging results between the follow-up periods, namely, immediately after, one month, three, fourth, six, 12, 14 and 30 months after RME, showing temporal heterogeneity. Although methodologically adequate, they were not controlled and randomized.

Despite the adequate methodological quality, a great difference in the study methods used was observed. The present review showed that RME improves mouth breathing. On the other hand, there were no randomized controlled trials in MB with TMD, both in the short and long term, highlighting the need for further studies in this area.

Conclusions

The use of ERM promotes the enlargement of the dental arches and of the nasal and maxillary structures, and improves mouth breathing in the short term. However,

its long-term benefits have not been proved so far. More robust results of the effectiveness of RME with MB can be achieved in meta-analysis studies, with a consensual definition of the long-term follow-up period after RME.

References

- Sakai RHUS, Marson FA, Sakuma ET, Ribeiro JD, Sakano E. Correlation between Acoustic Rhinometry, Computed Rhinomanometry and Cone-Beam Computed Tomography in Mouth Breathers with Transverse Maxillary Deficiency. *Braz J Otorhinolaryngol.* 2018;84:40-50.
- Badreddine FR, Fujita R, Alves FEM, Cappellette M. Rapid Maxillary Expansion in Mouth Breathers: A Short-Term Skeletal and Soft-Tissue Effect on the Nose. *Brazilian J Otorhinolaryngol.* 2018;84:196-205.
- Cappellette MJr, Alves FEM, Nagai LHY, Fujita RR, Pignatari SSN. Impact of Rapid Maxillary Expansion on Nasomaxillary Complex Volume in Mouth-Breathers. *Dental Press Journal of Orthodontics.* 2017;22:79-88.
- Ottaviano G, Maculan P, Borghetto G, Favero V, Galletti B, Savietto E, et al De Filippis, C. Favero, L. Nasal Function before and after Rapid Maxillary Expansion in Children: A Randomized, Prospective, Controlled Study. *Int J Pediatr Otorhinolaryngol.* 2018;115:133-138.
- Iwasaki T, Takemoto Y, Inada E, Sato H, Suga H, Saitoh I, et al. The Effect of Rapid Maxillary Expansion on Pharyngeal Airway Pressure during Inspiration Evaluated Using Computational Fluid Dynamics. *Int J Pediatr. Otorhinolaryngol.* 2014;78:1258.
- Izuka EN, Feres MFN, Pignatari SSNM. Immediate Impact of Rapid Maxillary Expansion on Upper Airway Dimensions and on the Quality of Life of Mouth Breathers. *Dental. Press J Orthod.* 2015;20:43-49.
- Pereira SRA, Weckx LLM, Ortolani CLF, Bakor SF. Study of Craniofacial Alterations and of the Importance of the Rapid Maxillary Expansion after Tonsillectomy. *Braz J Otorhinolaryngol.* 2012;78:111-17.
- Trevisan ME, Bellinasso JH, Augé AB, Barros L, Toniolo AMC, Rodrigues EC. Respiratory Mode, Nasal Patency and Palatine Dimensions. *CoDAS.* 2015;27:201-6.
- Pangrazio-Kulbersh V, Wine P, Haughey M, Pajtas B, Kaczynski R. Cone Beam Computed Tomography Evaluation of Changes in the Naso-Maxillary Complex Associated with Two Types of Maxillary Expanders. *Angle Orthod.* 2012;82:448-57.
- Miner RM, Al Qabandi S, Rigali PH, Will LA. Cone-Beam Computed Tomography Transverse Analyses. Part 2: Measures of Performance. *Am. J. Orthod. Dentofacial Orthop.* 2015;148:253-63. <https://doi.org/10.1016/j.jado.2015.03.027>
- Oenning AC, Jacobs R, Pauwels R, Stratis A, Hedesiu M, Salmon B, et al. Cone-Beam CT in Paediatric Dentistry : DIMITRA Project Position Statement. *Pediatr Radiol.* 2018;48:308-16.
- Cappellette Jr M, Nagai LHY, Gonçalves RM, Yuki AK, Pignatari SSN, Fujita RR. Skeletal Effects of RME in the Transverse and Vertical Dimensions of the Nasal Cavity in Mouth-Breathing Growing Children. *Dental Press J Orthod.* 2017;22:61-69.
- Monini S, Malagola C, Pia Villa M, Tripodi C, Tarentini S, Malagnino I, et al. Rapid Maxillary Expansion for the Treatment of Nasal Obstruction in Children Younger than 12 Years. *Arch. Otolaryngol. Head Neck Surg.* 2009;135:22-27.
- Torre H, Alarcón J. Changes in Nasal Air Flow and School Grades after Rapid Maxillary Expansion in Oral Breathing Children. *Med Oral Patol. Oral Cir. Bucal.* 2012;17:865-70.
- Langer MR, Itikawa CE, Valera FC, Matsumoto MA, Anselmo-Lima WT. Does Rapid Maxillary Expansion Increase Nasopharyngeal Space and Improve Nasal Airway Resistance? *International Journal of Pediatric Otorhinolaryngology.* 2011;75:122-25.
- Matsumoto MAN, Itikawa CE, Valera FC, Faria G, Anselmo-Lima WT. Long-Term Effects of Rapid Maxillary Expansion on Nasal Area and Nasal Airway Resistance. *Am J Rhinol Allergy.* 2010;24:161-65.
- Zorzela L, Loke YK, Ionnidis JP, Golder S, Santaguida P, Altman DG, et al. PRISMA Harms Group. PRISMA Harms Checklist: Improving Harms Reporting in Systematic Reviews. *BMJ.* 2016;352:1-17.
- Fowkes FGR, Fulton PM. Critical Appraisal of Published Research. *BMJ.* 1991;302:1136-40.
- Cappellette MJr, Cruz OLM, Carlini D, Weckx LL, Pignatari SSN. Evaluation of Nasal Capacity before and after Rapid Maxillary Expansion. *Am J Rhinol.* 2008;22:74-77.
- Enoki C, Valera FCP, Lessa FCR, Elias AM, Matsumoto MAN, Anselmo-Lima WT. Effect of Rapid Maxillary Expansion on the Dimension of the Nasal Cavity and on Nasal Air Resistance. *Int J Pediatr Otorhinolaryngol.* 2006;70:1225-30.
- Itikawa CE, Valera FC, Matsumoto MA, Lima WTA. Effect of Rapid Maxillary Expansion on the Dimension of the Nasal Cavity and on Facial Morphology Assessed by Acoustic Rhinometry and Rhinomanometry. *Dental Press Journal of Orthodontics.* 2012;17:129-33.
- Compadretti GC, Tasca I, Alessandri-Bonetti G, Peri S, D'Addario A. Acoustic Rhinometric Measurements in Children Undergoing Rapid Maxillary Expansion. *Int J Pediatr Otorhinolaryngol.* 2006;70:27-34.
- Compadretti GC, Tasca I, Bonetti GA. Nasal Airway Measurements in Children Treated by Rapid Maxillary Expansion. *American journal of rhinology.* 2006;20:385-93.
- Cozza P, Girolamo S, Di Ballanti F, Panfilio F. An Interdisciplinary Approach To Solve Otitis Media. *European Journal of Pediatric Dentistry.* 2007;2:83-88.
- Giuca MR, Galli V, Casani AP, Marchetti E, Marzo G. Correlations between Transversal Discrepancies of the Upper Maxilla and Oral Breathing. *European journal of paediatric dentistry: official journal of European Academy of Paediatric Dentistry.* *Eur J Paediatr Dent.* 2009;10:23-28.
- Pirelli P, Maurizio S, Giuseppe A. Obstructive Sleep Apnoea Syndrome (OSAS) and Rhino-Tubular Dysfunction in Children: Therapeutic Effects of RME Therapy. *Progress in orthodontics.* 2005;6:48-61.
- Helal N, Basri O, Gadi LS, Alhameed AF, Grady JM. Parents' Perceptions of Breathing Pattern Changes, Sleep Quality, and Fatigue in Children after Rapid Maxillary Expansion: A Survey and Case Series Study. *The Open Dentistry Journal.* 2019;13:85-92.
- Angelieri F, Cevidanes LHS, Franchi L, Gonçalves JR, Benavides E, McNamara Jr. JA. "Midpalatal Suture Maturation: Classification Method for Individual Assessment before Rapid Maxillary Expansion. *Am J Orthod. Dentofacial Orthop.* 2013;144:759-69.
- Lee D, Chulkyu P, Younghwan L, Hyosung C. A Metal Artifact Reduction Method Using a Fully Convolutional Network in the Sino-gram and Image Domains for Dental Computed Tomography. *J Digit Imaging.* 2020;33:538-546.

APPENDIX

MEDLINE via Ovid

- Palatal Expansion Technique/ (2553)
- rapid maxillary expansion.mp. (782)
- maxillary expansion.mp. (1102)
- palatal expansion techniques.mp. (4)
- 1 or 2 or 3 or 4 (2673)
- Mouth Breathing/ (1244)
- mouth breathers.mp. (117)
- 6 or 7 (1261)
- CHILD/ (1586597)
- child*.mp. (2141818)
- PEDIATRICS/ (50178)
- school aged child*.mp. (5869)
- kids.mp. (4751)
- CHILD, PRESCHOOL/ (864482)
- ADOLESCENT/ (1895691)
- adolescen*.mp. (1925681)
- 7 or 8 or 9 or 10 or 11 or 12 or 13 or 14 or 15 or 16 (3144059)
- 5 and 8 and 17 (63)

EMBASE

('palatal expansion technique' OR 'rapid maxillary expansion' OR 'maxillary expansion' OR 'palatal expansion techniques') AND ('mouth breathing' OR 'mouth breathers') AND (child OR child* OR pediatrics OR 'school aged child Or kids OR 'preschool child OR adolescent OR adolescen*).

SCOPUS

("Palatal Expansion Technique" OR "rapid maxillary expansion" OR "maxillary expansion" OR "palatal expansion techniques") AND ("Mouth Breathing" OR "mouth breathers") ND (child OR child* OR pediatrics OR "school aged child*" R kids OR preschool OR adolescent OR adolescen*).

Conflict of interest

Non declared.