

Emphysematous cholecystitis: Imaging findings in nine patients

Abhijit Sunnapwar, Abhijit A Raut¹, Arpit M Nagar², Rashmi Katre

Department of Radiology, University of Texas Health Science Center at San Antonio, 7703, Floyd curl dr, Texas - 78229, USA, ¹Department of Radiology, Seven Hills Hospital and Health City, Marol Maroshi Road, Andheri - East, Mumbai, Maharashtra 400059, India, ²Division of Abdominal Imaging, Department of Radiology, Ohio State University Medical Ctr 395 W 12th Ave Columbus, OH 43210

Correspondence: Dr. Abhijit Sunnapwar, 7703 Floyd curl dr, San Antonio, Texas 78229, USA. E-mail: sunnapwar@uthscsa.edu

Abstract

Objective: Emphysematous cholecystitis is a severe form of acute cholecystitis and can be rapidly fatal. We present the imaging features of nine patients with proven emphysematous cholecystitis.

Key words: CT scan; emphysematous cholecystitis; gall bladder; radiograph; ultrasound

Introduction

Emphysematous cholecystitis (EC), a potentially life-threatening anaerobic infection, is a variant of acute cholecystitis. The mortality rate for uncomplicated acute cholecystitis is approximately 1.4%; the mortality rate for acute EC, however, is 15%–20%, owing to the increased incidence of gall bladder (GB) wall gangrene and perforation.^[1,2] It can however be diagnosed early using USG and CT scan, both of which are sensitive for detecting the presence of air in soft tissues. Early diagnosis helps in prompt management.

Acute EC is diagnosed on the basis of the radiographic demonstration of air in the wall/lumen of the GB, in tissues adjacent to the GB, or in the biliary ducts in the absence of an abnormal communication with the gastrointestinal tract.^[3] The intriguing imaging findings in EC have been described by a variety of different terms, e.g., pneumocholecystitis, pyopneumocholecystitis, gas phlegmon of the GB, and arocholecystitis.^[4]

Materials and Methods

Imaging studies of nine patients with pathologically proven EC were reviewed retrospectively in a non-blinded fashion. An erect abdominal x-ray (AXR) was followed by USG (HDI 3500, Advanced Technologies Ltd., USA) of the abdomen. A 3.5-mHz curvilinear probe was used to scan the GB along the intercostal and subcostal planes with the patient in the supine and left lateral decubitus positions. The AXR was reviewed for detection of air specks and air–fluid levels in the right upper quadrant, and the USG images were analyzed for reverberation artifact, and air within the biliary radicles. Later, unless there were specific contraindications, a CT scan of the abdomen (Somatom Volume Zoom 4, Siemens, Germany) was performed after oral administration of 750 cc of diluted water-soluble iodinated contrast (1%). A contrast-enhanced scan was obtained using 5-mm slices, 75 s after intravenous injection of 120 cc of iodinated contrast.

The CT scans were analyzed on the basis of the following criteria: presence of gallstones, irregularity or thickening of the wall of the GB, presence of intraluminal/mural air, and presence of pericholecystic fluid. Extension of the inflammatory process into adjacent hepatic parenchyma was also looked for.

All patients underwent a white blood cell (WBC) count and random and postprandial blood sugar analysis.

Results

All the nine patients presented with acute abdomen. Of

Access this article online

Quick Response Code:



Website:
www.ijri.org

DOI:
10.4103/0971-3026.82300

these, four patients were male and five were female between 50–79 years of age (mean age: 61.55 years).

Of the nine patients in this study, six were known diabetics on treatment and two were found to have elevated blood sugar levels. Only one patient was non-diabetic. All patients presented with severe pain and tenderness in the right hypochondrium (RHC). One had fever and two others had vomiting. On clinical examination, there was a lump below the right costal margin in two patients, which correlated with a distended GB on subsequent imaging. The WBC count was elevated in eight of these patients and alkaline phosphatase was high in five. A clinical diagnosis of cholecystitis was made in five of the nine patients. The results are summarized in Table 1.

Plain abdominal radiograph

Five (55%) of the erect AXRs did not show any abnormality, even in retrospect. In two (22%) patients, intramural air

with air–fluid level was seen in the right upper quadrant [Figure 1], while in another two patients air was seen within the intrahepatic biliary radicals (22%).

USG

USG strongly suggested EC in seven patients (77%). Out of three patients with cholelithiasis, one had a calculus in the cystic duct. A linear echogenic focus with a reverberation artifact was seen in five patients [Figure 2], and it was difficult to tell whether air was in the lumen or in the wall of the GB. Two patients showed multiple speckled echogenic bands with acoustic shadowing within the GB wall [Figure 3A and 3B]. In two patients, the GB wall could not be clearly identified. Free air within the biliaryradicles was seen in one patient [Figure 4]. In one patient, there was a pericholecystic collection. An abscess within the adjacent hepatic parenchyma was seen in one patient. In two patients (22%), the USG findings were inconclusive.

Table 1: Demographics and imaging findings in patients with emphysematous cholecystitis

Pt no	Age	Sex	Diabetes	Plain radiograph	Ultrasound		CT
					Gall stones	Reverberation artifact	
1	51	M	Y	Negative	Present	Present	Intramural air
2	58	M	Y	Negative	Not seen	Present	Intramural air
3	62	M	Y	Air in biliary tree	Not seen	Not seen	Air in intrahepaticbiliary ducts
4	70	M	Y	Air fluid level in RUQ	Not seen	Present	Intraluminal air
5	50	F	Y	Negative	Gall bladder could not be well visualized		Intramural air
6	62	F	Y	Air in biliary tree	Present (impacted)	Present	Air in intrahepaticbiliary ducts
7	64	F	Y	Negative	Not seen	Present	Intraluminal air
8	64	F	Y	Negative	Not seen	Present	Intramural air
9	79	F	N	Air fluid level in RUQ	Present	Present	Intraluminal air with hepatic abscess formation

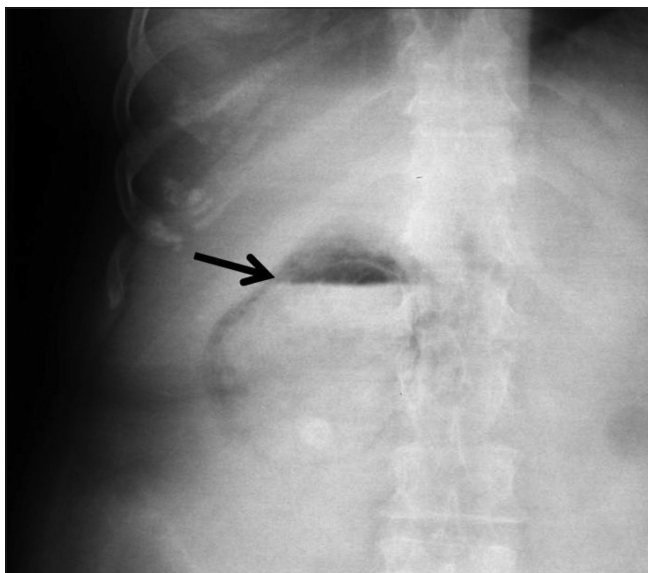


Figure 1: Abdominal radiograph (frontal projection) shows intraluminal air (arrow) with air–fluid levels

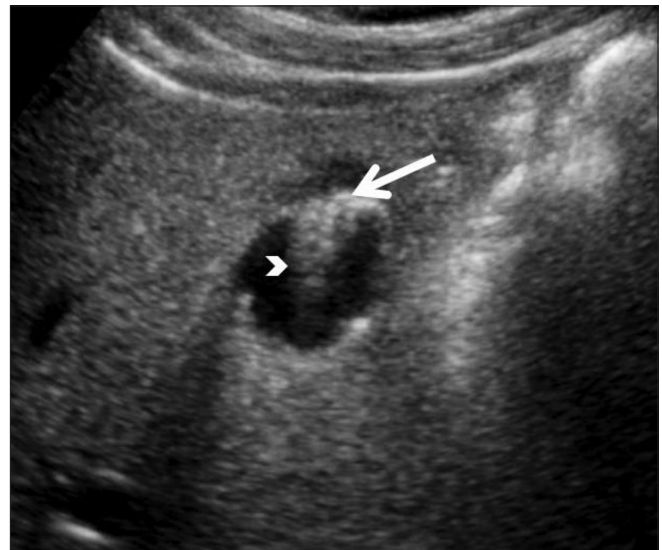


Figure 2: Axial USG image shows a linear echogenic focus (arrow) with a reverberation artifact (arrowhead) at the gall bladder fundus

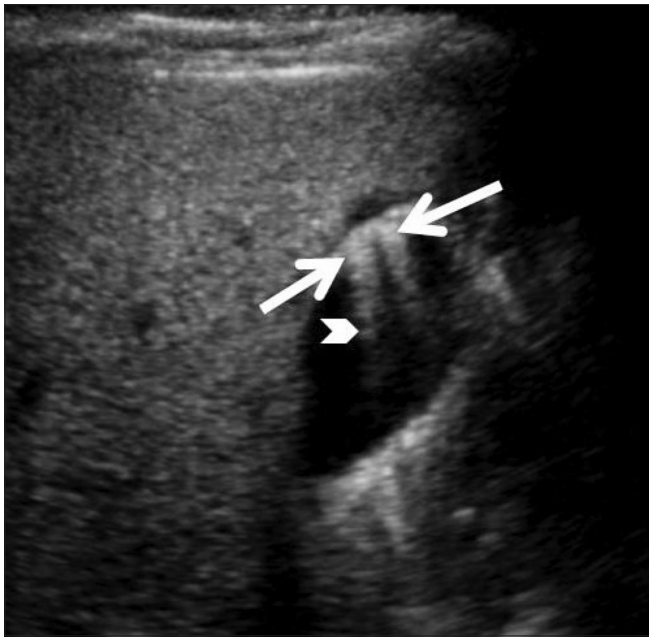


Figure 3: Sagittal USG image of the gall bladder shows multiple speckled echogenic bands (arrows), with acoustic shadowing within its wall (arrowhead)

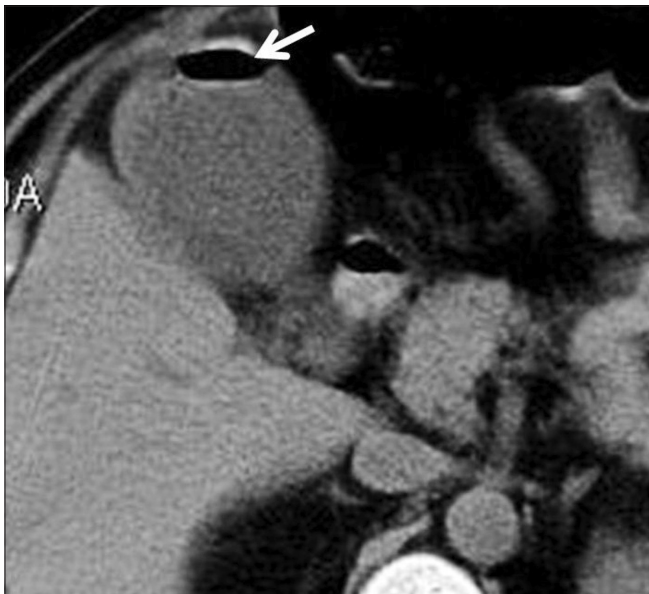


Figure 5: Axial CT scan shows air (arrow) in the gall bladder lumen with an air-fluid level

CT Scan

Air within the GB was demonstrated in all nine cases (100%), which was further differentiated as intraluminal with air-fluid levels in three cases (33%) [Figure 5] and intramural in four patients (44%) [Figures 6 and 7]. Two cases showed extension into the adjacent liver, with hepatic abscess formation and perforation of the GB (22%) [Figure 8]. Two patients (22%) showed air within intrahepatic biliary radicles and one patient showed foci of free intraperitoneal air

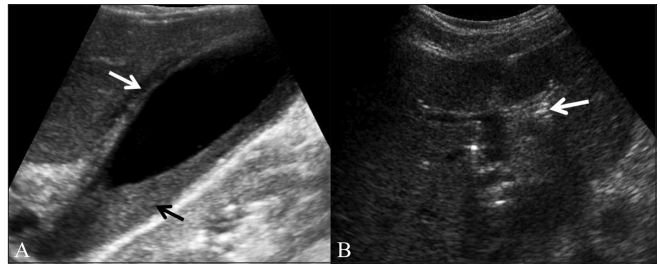


Figure 4 (A,B): Sagittal (A) and axial (B) USG images show sludge (black arrow) and wall thickening (arrow in A) of the gall bladder, consistent with acute cholecystitis with echogenic shadowing foci (arrow in B) within the biliary system

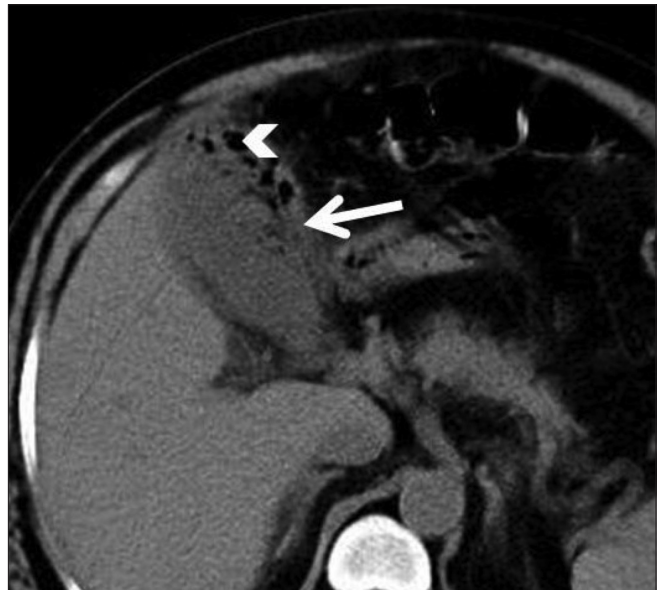


Figure 6: Axial CT scan shows gall bladder wall thickening (arrow), with intramural air (arrowhead)

[Figure 8]. Pericholecystic inflammation was noted in four patients (44%). Cholelithiasis was noted in three patients [Figure 7]. There was reactive right basal pleural effusion and basal atelectasis in two cases (22%). In one patient, coronal reformation helped differentiate air in the GB from colonic air [Figure 9].

Treatment

All nine patients underwent surgery. The operative findings and pathological examination confirmed the diagnosis of EC. Of the nine patients, six patients underwent emergency cholecystectomy; three were treated conservatively, with cholecystectomy done within 15 days of surgery. Out of these three patients, one patient was treated with percutaneous USG-guided cholecystostomy. One patient died following surgery after developing postoperative sepsis.

Discussion

EC was first described at autopsy in 1901 by Stolz, who

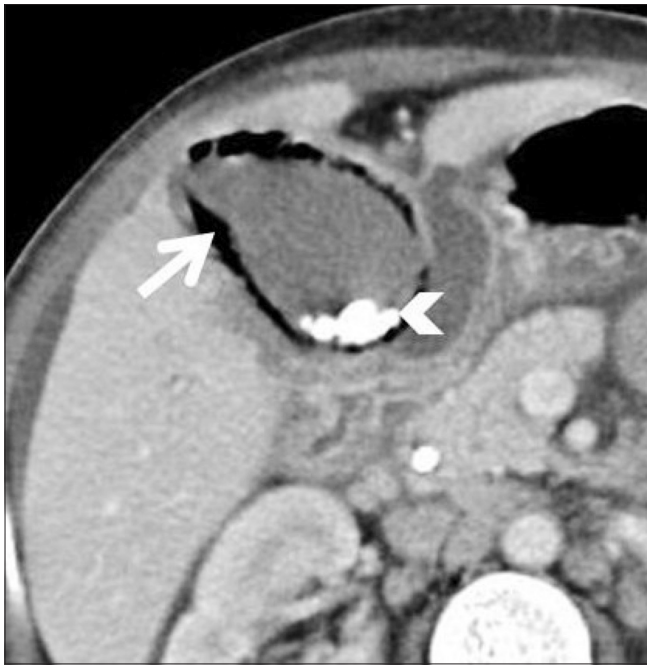

Figure 7: Axial CT scan shows intramural air in the gall bladder (arrow), with cholelithiasis (arrowhead)

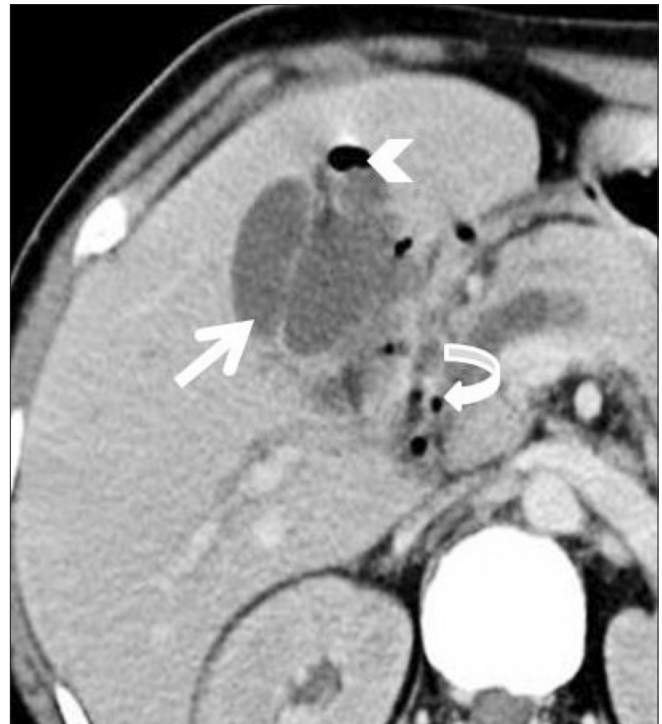


Figure 8: Axial CT scan shows intrahepatic abscess (arrow), with a focus of air (arrowhead). Also note foci of free intraperitoneal air (curved arrow)

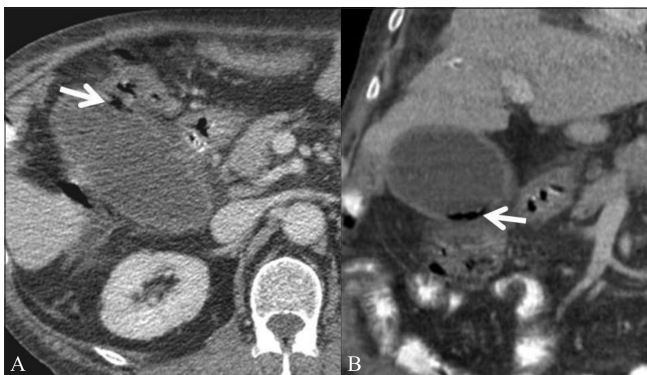


Figure 9 (A,B): Axial CT scan (A) shows an inflamed gall bladder with questionable air in the gall bladder wall (arrow). Coronal reformation (B) confirms air within the gall bladder wall (arrow) suggesting emphysematous cholecystitis

characterized EC by the presence of air within the GB and/or the biliary tree in the absence of an abnormal communication between the biliary system and the gastrointestinal tract.^[5] EC is a life-threatening condition, which in most cases requires early surgical intervention. Hence, early detection of this condition is imperative.

The condition is graded according to the distribution of air within the GB and/or the biliary system, as follows: stage 1 - air in the GB lumen, stage 2 - air in the GB wall, and stage 3 - air in the pericholecystic tissue.^[6] Extension of air along the intrahepaticbiliary radicals indicates severe infection. The anaerobic atmosphere of devitalized tissue, resulting from vascular insufficiency of the GB wall in arteriopathic patients, and the alkaline bile due to the inflammatory

process,^[6-8] favor the growth of anaerobic organisms. Anaerobic organisms are seen in upto 87% of bile specimen culture.^[9] *Clostridium welchii* and *Escherichia coli* are the two most common causative organisms.

A higher incidence of endarteritis is seen in the GB, in EC as compared to acute cholecystitis.^[8] High pressure in the GB/biliary system and consequent compression of blood vessels in the GB wall, obstruction of the cystic artery at hepatic artery embolization, atheromatous embolism of the cystic artery after an abdominal aortogram,^[10-12] and hypoperfusion of the GB during cardiopulmonary resuscitation have all been known to result in EC.

Excess distension of the GB wall can result in leakage of gas through the intact mucosa, with spread into the perimuscular layers to collect under the serosa.^[13] There may even be spread into the peritoneal cavity. EC is a rare cause of free peritoneal gas.^[14,15]

In comparison with acute cholecystitis, EC is associated with a higher incidence of complications such as gangrene and perforation.^[1] Despite the high mortality associated with gangrene and GB perforation, patients with EC do not exhibit alarming clinical signs of sepsis, and the presenting symptoms are often nonspecific and initially indistinguishable from those of uncomplicated acute cholecystitis.^[16] Individuals with diabetic neuropathy may not experience typicalright upper quadrant pain.^[17]

A high mortality rate of up to 25% has been reported in the setting of EC.^[17] Dependence on AXR to detect air within the GB/biliary system is no longer necessary as preliminary USG is now recommended as part of the diagnostic evaluation of all patients at risk from acute cholecystitis. USG findings in EC are thought to depend on the amount and location of the air pockets. In cases with a small amount of air, USG demonstrates echogenic foci with reverberation artifact.^[18] A wide band of acoustic shadowing within the GB fossa represents a large amount of gas.^[6,15] USG however is known to be less sensitive and specific in the detection of air within soft tissues as compared to plain radiography and CT scan and the GB wall may be indistinguishable in 77% of patients.^[3] False negative results on USG can occur if the surrounding pericholecystic air obscures the GB and mimics bowel loops.^[11] This can however be obviated by scanning through the intercostal spaces. The GB may be poorly visualized if the lumen is filled with multiple gallstones or in cases of a 'porcelain GB.'^[19] The M-mode on USG can better detect subtle movement of air pockets on compression with the probe.^[9] Adenomyomatosis of the GB can sometimes mimic EC with reverberation artifact. However these patients are asymptomatic and a review of the patient's chart can be helpful. USG shows echogenic intramural foci that produce 'V'-shaped comet tail reverberation artifacts, a sign quite specific for adenomyomatosis [Figure 10A]. This is due to the unique acoustic signature of cholesterol crystals within the lumina of the Rokitansky-Aschoff sinuses.^[20] However in doubtful situations it would be prudent to get a CT scan to look for air within the GB. MRI is definitive in diagnosing adenomyomatosis and demonstrates multiple diverticuli arising from the GB wall [Figure 10B].^[20]

Of all the imaging techniques, CT scan is the most sensitive and specific for identification of air within the GB/biliary system.^[6,12] CT scan was helpful in the localization of air in all nine patients in our series: it localized the air to the lumen of the GB in three cases, the wall of the GB in four cases, and along the biliary radicles in two cases. In addition, hepatic abscesses were identified in two patients. CT scan

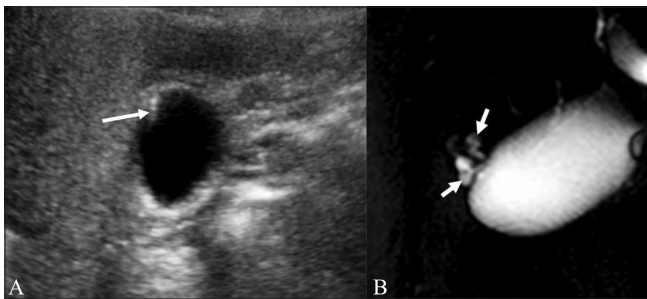


Figure 10 (A,B): Adenomyomatosis of the gall bladder: Axial USG image (A) shows an echogenic focus within the gallbladder wall producing a 'V'-shaped comet tail reverberation artifact (arrow). MRCP image (B) in the same patient shows multiple diverticuli arising from the gall bladder wall (arrow) representing Rokitansky-Aschoff sinuses

can demonstrate other pathologies that can mimic EC, such as cholecystoenteric fistula, GB lipomatosis, and duodenal perforation. Coronal reformations can help differentiate GB air from colonic air.

References

1. May RE, Strong R. Acute emphysematous cholecystitis. *Br J Surg* 1971;58:453-8.
2. Mentzer RM Jr, Golden GT, Chandler JG, Horsley JS 3rd. A comparative appraisal of emphysematous cholecystitis. *Am J Surg* 1975;129:10-5.
3. Hegner CF. Gaseous pericholecystitis and cholelithiasis. *Arch Surg* 1931;22:993-1000.
4. Mentzer RM, Golden GT, Chandler JG, Horsley JS. A Comparative Appraisal of emphysematous cholecystitis. *Am J Surg* 1975;129:10-5.
5. Stolz A. Ubergasbildung in derGollinweger. *Arch Pathol Anat* 1901;165:90-123.
6. Gill KS, Chapman HA, Weston MJ. Changing face of emphysematous cholecystitis. *Br J Radiol* 1997;70:986-91.
7. Jacob H, Appelman R, Stein HD. Emphysematous cholecystitis, *Am J Gastroenterol* 1979;71:325-30.
8. May RE, Strong R. Acute emphysematous cholecystitis. *Br J Surg* 1971;58:453-8.
9. Konno K, Ishida H, Naganuma H. Emphysematous cholecystitis: Sonographic findings. *Abdom Imaging* 2002;27:191-5.
10. Bloom RA, Libson E, Lebensart PD, Craciun E, Klin B, Fields SI, et al. The ultrasound spectrum of emphysematous cholecystitis. *J Clin Ultrasound* 1989;17:251-6.
11. Chih-Shun Wu, Wei-Jen Yao, Chang-Hua Hsaio. Effervescent gall bladder: Sonographic findings in Emphysematous Cholecystitis. *J Clin Ultrasound* 1998;26:272-5.
12. Grayson DE, Abbott RM, Levy AD, Sheman PM. *Radiographics* 2002;22:543-61.
13. Heifetz CJ, Riflun SM. Emphysematous cholecystitis - A case report. *J Abdom Surg* 1961;3:75.
14. Radin DR, Hall JM. Emphysematous cholecystitis presenting with pneumoperitoneum. *AJR Am J Roentgenol* 1987;149:1175-6.
15. Watson DI, Isaacs J, Witham RS. Emphysematous cholecystitis can cause pneumoperitoneum. *Aust N Z J Surg* 1994;64:130-1.
16. Bennett GL, Balthazar EJ. Ultrasound and CT evaluation of emergent gall bladder pathology. *Radiol Clin North Am* 2003;41:1203-16.
17. Garcia-Sancho Tellez L, Rodriguez-Montes JA, Fernandez de Lis S, Garcia-Sancho Martin L. Acute emphysematous cholecystitis. Report of twenty cases. *Hepatogastroenterology* 1999;46:2144-8.
18. Smith EA, Dillman JR, Elsayes KM, Menias CO, Bude RO, Cross-Sectional Imaging of Acute and Chronic Gall bladder Inflammatory Disease. *Am J Roentgenol* 2009;192:188-96.
19. Sauerbrei EE, Nguyen KT, Nolan RL. The gall bladder. In: Sauerbrei EE, Nguyen KT, Nolan RL, editors. *Abdomen sonography*. New York: Raven Press; 1992. p. 25-50.
20. Boscak AR, Al-Hawary M, Ramsburgh SR. Best cases from the AFIP: Adenomyomatosis of the gallbladder. *Radiographics* 2006;26:941-6.

Cite this article as: Sunnapwar A, Raut AA, Nagar AM, Katre R. Emphysematous cholecystitis: Imaging findings in nine patients. *Indian J Radiol Imaging* 2011;21:142-6.

Source of Support: Nil, **Conflict of Interest:** None declared.