

Coincidence of calcified carotid atheromatous plaque, osteoporosis, and periodontal bone loss in dental panoramic radiographs

Aruna Ramesh^{1,*}, Sheila Soroushian², Rumpa Ganguly¹

¹Division of Oral and Maxillofacial Radiology, Department of Diagnosis and Health Promotion, Tufts University School of Dental Medicine, Boston, MA, USA

²Department of Orthodontics, Howard University College of Dentistry, Washington, DC, USA

ABSTRACT

Purpose: This study was performed to assess the correlation of calcified carotid atheromatous plaque (CCAP), the mandibular cortical index, and periodontal bone loss in panoramic radiographs.

Materials and Methods: One hundred eighty-five panoramic radiographs with CCAP and 234 without this finding were evaluated by 3 observers for the presence of osseous changes related to osteoporosis and periodontal bone loss. Chi-squared and Mann-Whitney U tests were used to compare the two groups for an association of CCAP with the mandibular cortical index and periodontal bone loss, respectively.

Results: There was a statistically significant coincidence of CCAP and osseous changes related to osteopenia/osteoporosis, with a p-value <0.001. There was no statistically significant coincidence of CCAP and periodontal bone loss. When comparing the 2 groups, "With CCAP" and "Without CCAP", there was a statistically significant association with the mean body mass index (BMI), number of remaining teeth, positive history of diabetes mellitus, and vascular accidents. There was no statistically significant association with gender or a history of smoking.

Conclusion: This study identified a possible concurrence of CCAP and mandibular cortical changes secondary to osteopenia/osteoporosis in panoramic radiographs. This could demonstrate the important role of dental professionals in screening for these systemic conditions, leading to timely and appropriate referrals resulting in early interventions and thus improving overall health. (*Imaging Sci Dent* 2013; 43 : 235-43)

KEY WORDS: Radiography, Panoramic; Osteoporosis; Atherosclerosis, Alveolar Bone Loss

Introduction

After remaining fairly constant for most of human history, life expectancy, the average number of years a person can expect to live, has nearly doubled in the last 100 years.¹ As people live longer, the leading cause of death in the Western world has shifted from infections to chronic diseases, with atherosclerosis and osteoporosis among the most prevalent.² As systemic health deteriorates with age, so does oral health in the form of periodontitis and tooth

loss.³⁻⁵ Research has identified some commonalities between atherosclerosis and osteoporosis, including the ability to screen for both, to varying degrees, with the dental panoramic radiograph.⁶⁻¹⁴ This routine dental radiograph would provide a cost-effective way to screen a large population to identify those most in need of further diagnostic follow-up.

In the United States (US), approximately 730,000 strokes occur per year,¹⁵ making it the third leading cause of death.² Stroke is linked to peripheral vascular disease, including atherosclerosis of the carotid artery. Atherosclerosis is a progressive disease process that remains relatively asymptomatic until stroke occurs,² making early identification a critical step in improving morbidity and mortality. Accurate and inexpensive, duplex ultrasound is the gold stan-

Received July 6, 2013; Revised July 27, 2013; Accepted August 10, 2013

*Correspondence to : Dr. Aruna Ramesh

Department of Diagnosis and Health Promotion, Tufts University School of Dental Medicine, One Kneeland St, DHS 213, Boston, MA 02111, USA
Tel) 1-617-636-4029, Fax) 1-617-636-3760, E-mail) aruna.ramesh@tufts.edu

Copyright © 2013 by Korean Academy of Oral and Maxillofacial Radiology

This is an Open Access article distributed under the terms of the Creative Commons Attribution Non-Commercial License (<http://creativecommons.org/licenses/by-nc/3.0>) which permits unrestricted non-commercial use, distribution, and reproduction in any medium, provided the original work is properly cited.

Imaging Science in Dentistry · pISSN 2233-7822 eISSN 2233-7830

dard for the diagnosis of carotid artery stenosis; however, screening a large symptom-free population has been shown to be cost-ineffective, even in the elderly.¹⁶ Soft-tissue calcifications of the plaque in the carotid artery, also known as calcified carotid atherosclerotic plaque (CCAP), can be identified in a routine panoramic radiograph.^{6,17,18} This supports evaluation of existing panoramic radiographs routinely taken for dental diagnosis as a minimally invasive, highly cost-effective screening tool to refer patients for further follow-up if needed.

Osteoporosis, another prevalent chronic disease, affects 55% of Americans over 50.^{19,20} Characterized by decreased bone mineral density (BMD), osteoporosis is often not detected until a fracture occurs.²¹ After hip fracture, 20 percent of patients die within one year.²² Early intervention of those at-risk for fracture can enhance bone mass retention and reduce the risk for fracture.²³ Many recent studies have developed qualitative and quantitative measurements on panoramic radiographs to identify at-risk segments of the population. Mandibular cortical width at the mental foramen, either measured or estimated, and the Klemetti index, a method for characterizing the mandibular cortex, have been identified as better panoramic radiographic indicators of general bone mineral density than BMD classification;^{9-11,13,14} although some studies recommend that they only be used in conjunction with other clinical risk factors.^{7,8} Nakamoto et al reported good results when these techniques were used by untrained general dentists to identify osteoporosis risk groups.¹²

Panoramic radiography is routinely used for dental diagnoses, with millions taken annually worldwide either as an alternative, or as a supplement, to intraoral radiography.^{24,25} Existing data confirm the extensive use of panoramic equipment, with estimates of the proportion of dentists using panoramic radiography ranging from 26% to 60% in the US.²⁶⁻²⁸ If routine dental radiographs could be utilized for identifying and triaging individuals with systemic conditions such as osteoporosis and CCAP, the potential exists for early interventions leading to improvement in quality of life.

Periodontal disease, a bacterial infection leading to loss of soft tissue attachment and resorption of alveolar bone, eventually leading to tooth loss, affects 14% of adults aged 45 to 54 and 23% of 65 to 74 year olds and is the etiology of edentulism in 30% of adults 65 years and older.²⁹ Studies have found associations between periodontitis and chronic systemic diseases.³⁰ Radiographic methods of estimating or measuring bone loss on a panoramic radiograph or a panoramic radiograph plus bitewings are also standard

and have been used to show associations between periodontitis and chronic systemic diseases.^{6,31,32}

The current literature not only shows the association between atherosclerosis and osteoporosis,³³⁻³⁶ but also shows a link between alveolar bone loss due to periodontitis and carotid calcification, suggesting that periodontitis-associated inflammation might play a role in cardiac disease.³² The association between periodontitis and osteoporosis has also been documented in the literature. Low mineral status in the skeleton measured using the Klemetti index correlates with higher occurrence of horizontal alveolar bone loss in the mandible,³⁷ and patients with good mineral status were shown to be able to retain teeth with deep probing depths more easily than those with osteopenia/osteoporosis.³¹ Taguchi et al found that measurements of mandibular cortical width also correlated with tooth loss in women in their seventh decade of life; however, this association was not found in men regardless of age.³⁸ In one study, the likelihood of having carotid artery stenosis and radiographic evidence of periodontitis was high, with a dose-response relationship.⁶ Evidence of associations relating atherosclerosis, osteoporosis, and chronic periodontitis together have been suggested, but not without dispute. Chronic periodontitis may be an independent risk factor for atherosclerosis and there might be an association between chronic periodontitis and osteoporosis.³⁹ Many inflammatory mediators are shared among the three diseases; specifically, research in mice has shown that they are linked via a common expression of the lipoxigenase genes and that these genes could provide a means for developing therapeutics.⁴⁰

The aim of this study was to assess the coincidence of radiographic osseous changes related to osteopenia/osteoporosis and periodontal bone loss in patients showing calcified carotid atheromatous plaques in panoramic radiographs. Establishing these correlations could not only support other evidence of these disease correlations, but also encourage the role of dental practitioners in screening for osteoporosis in patients with calcified carotid atheromatous plaques and/or periodontal bone loss in panoramic radiographs.

Materials and Methods

One hundred eighty five panoramic radiographs showing frank evidence of CCAP (With CCAP group) detected during the routine diagnosis and treatment planning process for dental conditions were selected from among the patients of the School of Dental Medicine by a panel of two board-

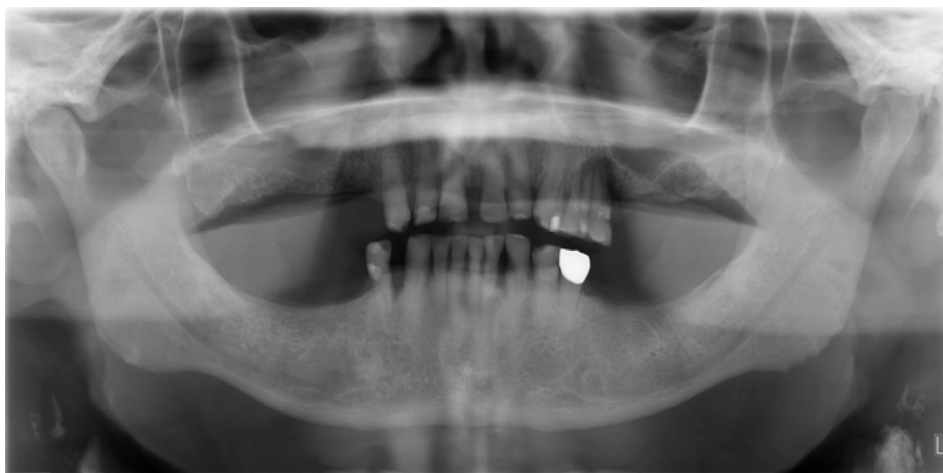

Figure 1. A panoramic radiograph shows bilateral linear soft tissue calcification in the cervical areas most consistent with calcified carotid atherosclerotic plaque. The inferior mandibular cortex represents the C2 Early stage of osteoporosis, showing semilunar defects with a normal cortical width by visual estimation.

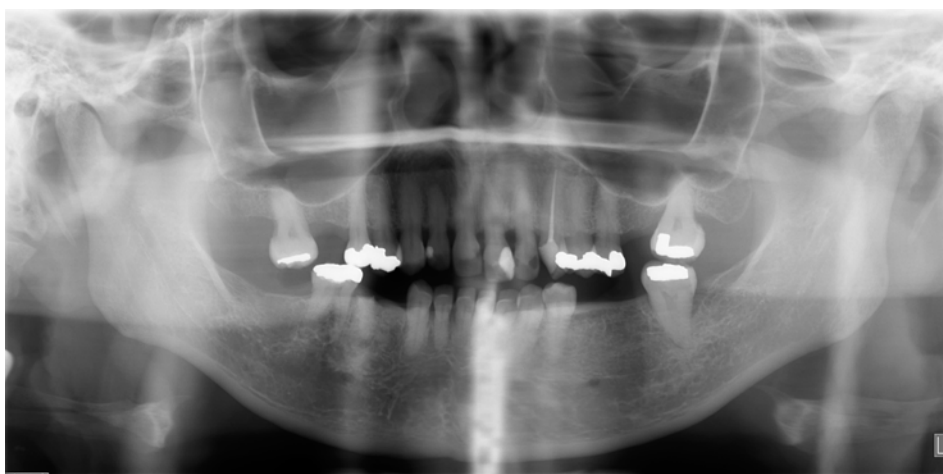


Figure 2. The inferior mandibular cortex on this panoramic radiograph represents the C1 stage of osteoporosis, showing an even and sharp endosteal margin of the cortex.

certified oral and maxillofacial radiologists. An example of this panoramic finding is shown in Figure 1. A control group of 234 digital panoramic radiographs were also randomly selected with a matched age range of 34-94 (the age range of the With CCAP group was 30-93). These panoramic radiographs were reviewed by the two oral and maxillofacial radiologists to confirm the absence of panoramic CCAP in this group (Without CCAP).

All of the panoramic radiographs included in the study were obtained from the patient population at the dental school from 2006 to the present and taken with an OP 100 D (Imaging Instrumentarium, Tuusula, Finland) by radiology certified experienced dental assistants with the patient's head in the recommended position. Bitewing radiographs taken within 1 month of the panoramic radiograph were also reviewed, as a supplement for evaluating the radiographic periodontal status. These were taken with Planmeca intra-oral X-ray equipment (Planmeca Oy, Helsinki, Finland) set at 70 kVp, 8 mA, 0.08-0.1 s using Schick

Elite sensors (Schick Technologies Inc., Long Island City, NY, USA). The MiPACS software (version 3.1.459 Medisor Imaging, Charlotte, NC, USA) was used to acquire, view, and analyze all of the radiographs in this study.

The inclusion criteria used were optimal diagnostic radiographic quality, presence of 4 or more teeth, and the inclusion of the region of the common carotid in the panoramic radiographs.

Radiographic assessment

MiPACS software was used to acquire, view, and analyze the 419 panoramic radiographs in this study. 3 observers completed the observations. Two of the observers were board certified oral and maxillofacial radiologists, and the third observer was a general dentist. The observers were provided a randomized list of electronic chart numbers of the 419 patients for their observations. If there was partial agreement among the observers, with 2 of the 3 obser-

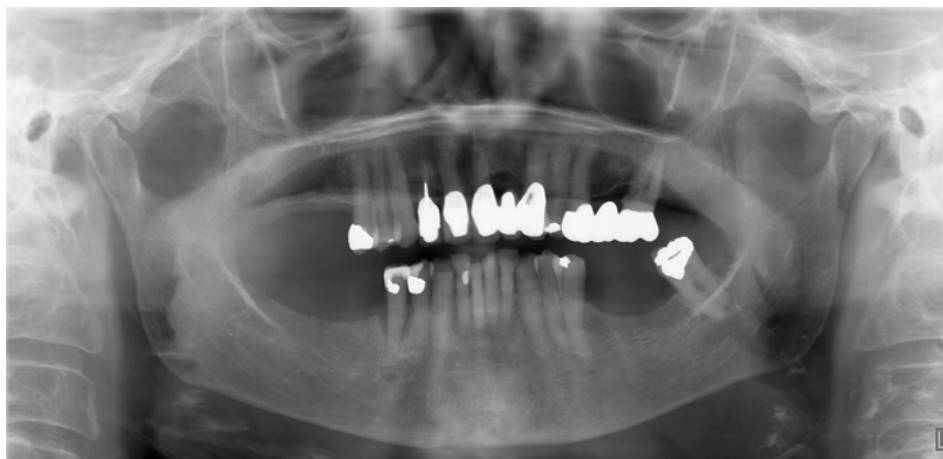


Figure 3. This panoramic radiograph shows the C2 Late stage of osteoporosis, showing semilunar defects extending more than half the cortical width of the inferior mandibular cortex with a very thin cortex by visual estimation.

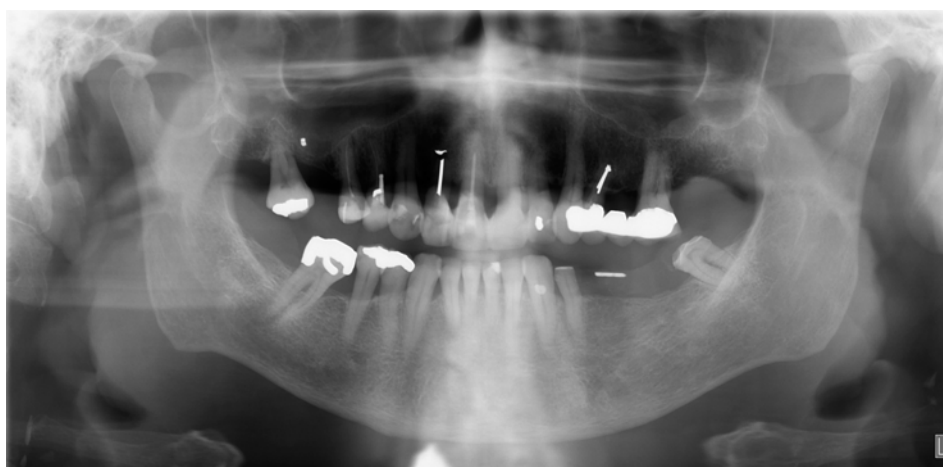

Figure 4. The inferior mandibular cortex on the given panoramic radiograph appears clearly porous (C3 Stage).

vers recording the same score, the same score recorded by the 2 observers was accepted as final. When all 3 observers were in non-agreement, a consensus was reached on a case-by-case basis. All of the radiographic assessments took place in a quiet room with subdued ambient lighting appropriate for radiographic viewing.

The following radiographic observations were made with respect to osteopenia/osteoporosis and periodontal bone loss:

Mandibular cortical index as a measure of osteoporosis

The appearance of the mandibular inferior cortex was assessed bilaterally and classified, based on the index developed by Klemetti et al⁸ and modification suggested by Ledgerton et al⁴¹ as follows. Figures 1-4 are representative images in categories C1-C3, respectively.

C1: The endosteal margin of the cortex was even and sharp.

C2 Early: The endosteal margin presented semilunar defects (lacunar resorption) or appeared to form endosteal

cortical residues but with normal cortical width by visual estimation.

C2 Late: The endosteal margin presented semilunar defects (lacunar resorption) or appeared to form endosteal cortical residues extending beyond 50% of the cortical width, with intermediate or very thin cortical width by visual estimation.

C3: The cortical layer formed heavy endosteal cortical residues and was clearly porous, with C2 Late and C3 identifying those patients at greatest risk of osteopenia/osteoporosis. Both sides of the mandible were evaluated, and when the right and left sides presented different classifications, the more severe classification was used.

Radiographic assessment of periodontal bone loss

Horizontal bone loss greater than 3 mm on the mesial and distal aspects of the remaining teeth as well as interdental bone loss was assigned a score of 0-3 based on the following classification.⁴²

Table 1. Comparison of the With CCAP and Without CCAP Groups

	With CCAP (n=185)	Without CCAP (n=234)	P
Number of Males/Females	116/69	129/105	0.144
Age-range (Mean)	30-93 (69.21)	34-94 (59.01)	
Mean BMI/SD	28.3/5.01	27.2/5.13	0.047
Number of Teeth Present/SD	19.55/6.8	22.43/6.73	<0.001
% osteopenia/osteoporosis	23.8 (44/185)	9 (21/234)	<0.001
% of Periodontal Bone Loss	90.8 (168/185)	88.5 (207/234)	0.067
% with History of Vascular Accident	12.4 (23/178)	3.8 (9/233)	0.001
% with History of Smoking	25.9 (48/178)	19.2 (48/233)	0.086
% with History of Diabetes Mellitus	18.9 (35/178)	9.4 (22/233)	0.005

(CCAP: calcified carotid atheromatous plaque, BMI: body mass index, SD: standard deviation)

0: interproximal bone levels within 3 mm from the cemento-enamel junction and crestal bone intact and no inter-radicular radiolucency.

- 1: if the extent of overall bone loss was less than 25%
- 2: if the extent of bone loss varied between 25% and 50%
- 3: if the overall extent of bone loss exceeded 50% of the root length

The most prevalent assessment of bone loss in all sextants was considered the final periodontal status.

Other data collected from the electronic patient records included patient age, gender, number of teeth, history of smoking, history of diabetes, past history of cerebrovascular or cardiovascular accident, and body mass index (BMI). This information was obtained from the medical history available in the patient's chart. The history included just the presence or absence of diabetes, plus cardiovascular accidents such as heart attacks and/or strokes. The BMI was calculated using the weight and height of the patient, also included in the patient's chart. Mann-Whitney U and chi-squared tests were used to analyze the data obtained.

The study was approved by the university's institutional review board (IRB).

Results

De-identified data were entered into an Excel spreadsheet and checked for accuracy before importing the file into statistical software (SPSS version 19, IBM, Armonk, New York, USA) for analysis. Descriptive statistics were run to assess the distribution of all clinical variables for the sample as a whole and by 'With CCAP' and 'Without CCAP' groupings. The mean age, gender distribution, mean BMI, number of teeth, incidence of history of cerebrovascular or cardiovascular accident, smoking, and diabetes of each of the two groups is presented in Table 1.

Comparing the two groups, the number of teeth, (Mann-

Whitney U test) in the Without CCAP patients group was higher (22.43) than that in the With CCAP group (19.55). This was statistically significant with a p-value <0.001 (Table 1).

With regard to the mandibular cortical index, C1 and C2E were grouped together and C2L and C3 were grouped together for the data analysis. Comparing the two groups in terms of the mandibular cortical index (chi-squared test), 21/234 patients in the Without CCAP group had osteopenia/osteoporosis versus 44/185 in the With CCAP group. This difference was statistically significant with a p-value <0.001 (Table 1). There was also a statistically significant difference (p-value <0.05) in the BMI between the two groups, with the BMI being higher in the With CCAP group.

There was no statistically significant difference in the incidence of periodontal bone loss (Mann-Whitney U) and history of smoking (chi-squared test) between the groups. Table 1 presents the descriptive data.

Comparing the two groups regarding the history of cerebrovascular or cardiovascular incidents (chi-squared test), there was a higher proportion of patients with this relevant medical history in the With CCAP group, and the difference was statistically significant with a p-value of 0.001 (Table 1).

The correlation of CCAP with a history of diabetes mellitus was significant, with a p-value of 0.005 (chi-squared test), with 35/178 of the With CCAP group members having a positive history compared to 22/233 in the Without CCAP group.

Assessment of the association of periodontal bone loss with the mandibular cortical index also showed statistical significance (p=0.014) (Mann-Whitney U test). There were 313/354 patients who had positive radiographic findings for periodontal bone loss but were negative for osteoporosis, while 62/65 patients presented with positive radiographic

findings for both periodontal bone loss and osteoporosis.

Discussion

A limitation of the current study was the lack of confirmation of CCAP detected in panoramic radiographs with Doppler ultrasound. However, the reliability of diagnosis of CCAP in panoramic radiographs has been documented by previous studies.^{19,43} Damaskos et al concluded that panoramic radiographs, as a tool for prediction of luminal stenosis of more than 80%, had a 100% positive predictive value and could be highly suggestive of the presence of carotid artery atherosclerotic occlusive disease.⁴⁴ We found a statistically significant correlation between the presence of panoramic CCAP and a positive history of heart attack or stroke which was in agreement with other studies that concluded that patients with detectable carotid plaque in panoramic radiographs required referral to a physician for further investigation, as they were more likely to have suffered cerebrovascular events.^{17,45} The above correlation in our study could indirectly support the efficacy of panoramic detection of CCAP. Incidental CCAP findings on dental panoramic radiographs have been considered powerful markers for future cerebrovascular and cardiovascular events and death.⁴⁶ Cohen et al also concluded that patients found to have carotid calcification on dental panoramic radiographs should be referred for cerebrovascular evaluation and aggressive management of vascular risk factors.⁴⁶

In the current study, the incidence of osteoporotic mandibular cortical changes was higher in patients with CCAP, and this was statistically significant. This was in concordance with Jørgensen et al, who found that low bone mass was associated with an increased risk of echogenic calcified atherosclerotic plaque,³⁵ but found no association between bone mineral density (BMD) and echolucent (lipid) plaques.³⁵ Pennisi et al also found that patients with carotid or femoral atherosclerotic plaque had a considerably low total body and regional bone mass and found a high occurrence of osteoporosis in patients with peripheral vascular disease independent of age and gender.³⁴

The National Osteoporosis Risk Assessment demonstrated that large segments of the population with no previous diagnosis of osteoporosis were at risk for osteoporotic fracture.⁴⁷ It is difficult in clinical practice to refer all postmenopausal women for BMD testing when considering the cost-effectiveness, as well as the limited number of facilities and trained personnel. The aim of our study was to assess the coincidence of panoramic radiographic evidence of CCAP and osteopenia/osteoporosis, and we found a

statistically significant association. While assessing the diagnostic efficacy of panoramic radiographs in detecting CCAP or osteopenia/osteoporosis, it should be borne in mind that these happen to be incidental findings on routine dental radiographs, which could have a significant effect on the overall health of the patient. When CCAP is detected on panoramic radiographs, assessment for coexisting osteopenic/osteoporotic changes could greatly improve morbidity and mortality if the dental team identifies these potential systemic conditions and provides appropriate timely referrals.

Contrary to many epidemiological studies that have suggested an association between periodontitis and cerebrovascular disease, we found no correlation between periodontal bone loss and CCAP.^{32,48,49} This study was, however, in agreement with Hujoel and others, who found no statistically significant association between periodontitis and the presence of CCAP.⁵⁰ It is noteworthy that assessment of periodontitis in many studies was on clinical and not radiographic measures of periodontitis. It is interesting to note that while there was no correlation between CCAP and periodontal bone loss, the number of teeth present was significantly higher in patients without CCAP (p-value <0.001). Periodontal disease as an etiology for tooth loss has been documented in the literature.⁵¹ The lack of correlation between periodontal bone loss and CCAP in our study could possibly be related to how periodontitis was defined, as other studies have primarily used clinical attachment loss and increased probing depth, while we used radiographic assessment only.

A history of smoking was not related to CCAP in our study, which was in disagreement with other studies that clearly recognized smoking as a contributor to carotid plaque formation.⁵² We did not account for smoking when assessing the correlation between CCAP and periodontal bone loss. This was in disagreement with the cross-sectional study conducted by Persson et al,³² who concluded that the association between cardiovascular disease and periodontitis was significant when smoking was not accounted for. However, when they included smoking in the analysis, this association disappeared. They attributed this finding to decreased statistical power, among other factors. We believe our results may have also been influenced by decreased statistical power. Another confounder could be the way in which the smoking and non-smoking groups were formed. Past and current smokers comprised the smoking group, without taking into account how long ago past smokers had stopped smoking. Studies have shown that the risk associated with smoking decreases rapidly and reaches that

of never-smokers within 2-5 years of quitting.⁵³⁻⁵⁶ Another factor that could influence the effect of smoking is dietary habits, which was not included in this study. It has been documented that dietary habits, specifically fruit and vegetable consumption, results in larger reductions in the coronary heart disease risk in smokers than in nonsmokers.⁵⁷⁻⁵⁹

We found a statistically significant correlation between a documented history of diabetes mellitus and panoramic CCAP, which concurred with findings by other authors. The overall relative risk of stroke and recurrent stroke was reported to be greater in patients with diabetes mellitus.^{60,61}

Our study included just the documented presence/absence of diabetes mellitus in the medical history, as it was not one of the primary objectives. The BMI was statistically significantly higher in the With CCAP group ($p=0.047$).

In conclusion, this study identified a possible concurrence of CCAP and mandibular cortical morphological changes secondary to osteopenia/osteoporosis in panoramic radiographs. We recognized the potential use of routine dental panoramic radiographs in screening for CCAP and/or determining the mandibular cortical index, so referral of these patients to appropriate health professionals could result in early intervention when needed.

References

- Arias E, Curtin LR, Wei R, Anderson RN. U.S. decennial life tables for 1999-2001, United States life tables. *Natl Vital Stat Rep* 2008; 57: 1-36.
- Guyser B, Freedman MA, Strobino DM, Sondik EJ. Annual summary of vital statistics: trends in the health of Americans during the 20th century. *Pediatrics* 2000; 106: 1307-17.
- Marcus SE, Drury TF, Brown LJ, Zion GR. Tooth retention and tooth loss in the permanent dentition of adults: United States, 1988-1991. *J Dent Res* 1996; 75: 684-95.
- Nazliel HE, Hersek N, Ozbek M, Karaagaoglu E. Oral health status in a group of the elderly population residing at home. *Gerodontology* 2012; 29: e761-7.
- Krustrup U, Erik Petersen P. Periodontal conditions in 35-44 and 65-74-year-old adults in Denmark. *Acta Odontol Scand* 2006; 64: 65-73.
- Ravon NA, Hollender LG, McDonald V, Persson GR. Signs of carotid calcification from dental panoramic radiographs are in agreement with Doppler sonography results. *J Clin Periodontol* 2003; 30: 1084-90.
- Devlin H, Horner K. Mandibular radiomorphometric indices in the diagnosis of reduced skeletal bone mineral density. *Osteoporos Int* 2002; 13: 373-8.
- Klemetti E, Kolmakov S, Kröger H. Pantomography in assessment of the osteoporosis risk group. *Scand J Dent Res* 1994; 102: 68-72.
- Leite AF, Figueiredo PT, Guia CM, Melo NS, de Paula AP. Correlations between seven panoramic radiomorphometric indices and bone mineral density in postmenopausal women. *Oral Surg Oral Med Oral Pathol Oral Radiol Endod* 2010; 109: 449-56.
- Klemetti E, Kolmakov S, Heiskanen P, Vainio P, Lassila V. Panoramic mandibular index and bone mineral densities in postmenopausal women. *Oral Surg Oral Med Oral Pathol* 1993; 75: 774-9.
- Halling A, Persson GR, Berglund J, Johansson O, Renvert S. Comparison between the Klemetti index and heel DXA BMD measurements in the diagnosis of reduced skeletal bone mineral density in the elderly. *Osteoporos Int* 2005; 16: 999-1003.
- Nakamoto T, Taguchi A, Ohtsuka M, Sueti Y, Fujita M, Tanimoto K, et al. Dental panoramic radiograph as a tool to detect postmenopausal women with low bone mineral density: untrained general dental practitioners' diagnostic performance. *Osteoporos Int* 2003; 14: 659-64.
- White SC, Taguchi A, Kao D, Wu S, Service SK, Yoon D, et al. Clinical and panoramic predictors of femur bone mineral density. *Osteoporos Int* 2005; 16: 339-46.
- Vlasiadis KZ, Damilakis J, Velegrakis GA, Skouteris CA, Fragouli I, Goumenou A, et al. Relationship between BMD, dental panoramic radiographic findings and biochemical markers of bone turnover in diagnosis of osteoporosis. *Maturitas* 2008; 59: 226-33.
- Williams GR, Jiang JG, Matchar DB, Samsa GP. Incidence and occurrence of total (first-ever and recurrent) stroke. *Stroke* 1999; 30: 2523-8.
- Yin D, Carpenter JP. Cost-effectiveness of screening for asymptomatic carotid stenosis. *J Vasc Surg* 1998; 27: 245-55.
- Friedlander AH, Lande A. Panoramic radiographic identification of carotid arterial plaques. *Oral Surg Oral Med Oral Pathol* 1981; 52: 102-4.
- Almog DM, Horev T, Illig KA, Green RM, Carter LC. Correlating carotid artery stenosis detected by panoramic radiography with clinically relevant carotid artery stenosis determined by duplex ultrasound. *Oral Surg Oral Med Oral Pathol Oral Radiol Endod* 2002; 94: 768-73.
- McBean LD, Forgac T, Finn SC. Osteoporosis: visions for care and prevention - a conference report. *J Am Diet Assoc* 1994; 94: 668-71.
- Friedlander AH. The physiology, medical management and oral implications of menopause. *J Am Dent Assoc* 2002; 133: 73-81.
- NIH Consensus Development Panel on Osteoporosis Prevention, Diagnosis, and Therapy. Osteoporosis prevention, diagnosis, and therapy. *JAMA* 2001; 285: 785-95.
- Riggs BL. Overview of osteoporosis. *West J Med* 1991; 154: 63-77.
- Delaney MF. Strategies for the prevention and treatment of osteoporosis during early postmenopause. *Am J Obstet Gynecol* 2006; 194(2 Suppl): S12-23.
- American Dental Association Survey Center. Survey of dental practice: characteristics of dentists in private practice and their patients. Chicago: American Dental Association; 2000.
- Dental Practice Board. Digest of Statistics 2000/2001. GDS treatment items. By Country and broad age group. Detailed analyses for year ending March 2001 [Internet]. Eastbourne: DPB Information and Probity; 2001 [cited 2013 Oct 18]. Avail-

- ilable from: http://www.nhsbsa.nhs.uk/DentalServices/Documents/ArchivePDF/digest_2001.pdf.
26. Nakfoor CA, Brooks SL. Compliance of Michigan dentists with radiographic safety recommendations. *Oral Surg Oral Med Oral Pathol* 1992; 73: 510-3.
 27. Matteson SR, Morrison WS, Stanek EJ 3rd, Phillips C. A survey of radiographs obtained at the initial dental examination and patient selection criteria for bitewings at recall. *J Am Dent Assoc* 1983; 107: 586-90.
 28. Kaugars GE, Broga DW, Collett WK. Dental radiologic survey of Virginia and Florida. *Oral Surg Oral Med Oral Pathol* 1985; 60: 225-9.
 29. US Department of Health and Human Services. Oral health in America: a report of the surgeon general - executive summary. Rockville, MD: US Department of Health and Human Services, National Institute of Dental and Craniofacial Research, National Institutes of Health; 2000.
 30. Renvert S. Destructive periodontal disease in relation to diabetes mellitus, cardiovascular diseases, osteoporosis and respiratory diseases. *Oral Health Prev Dent* 2003; 1 Suppl 1: 341-59.
 31. Persson RE, Hollender LG, Powell LV, MacEntee MI, Wyatt CC, Kiyak HA, et al. Assessment of periodontal conditions and systemic disease in older subjects. I. Focus of osteoporosis. *J Clin Periodontol* 2002; 29: 796-802.
 32. Persson RE, Hollender LG, Powell VL, MacEntee M, Wyatt CC, Kiyak HA, et al. Assessment of periodontal conditions and systemic disease in older subjects. II. Focus on cardiovascular diseases. *J Clin Periodontol* 2002; 29: 803-10.
 33. Hjortnaes J, Butcher J, Figueiredo JL, Riccio M, Kohler RH, Kozloff KM, et al. Arterial and aortic valve calcification inversely correlates with osteoporotic bone remodeling: a role for inflammation. *Eur Heart J* 2010; 31: 1975-84.
 34. Pennisi P, Signorelli SS, Riccobene S, Celotta G, Di Pino L, La Malfa T, et al. Low bone density and abnormal bone turnover in patients with atherosclerosis of peripheral vessels. *Osteoporos Int* 2004; 15: 389-95.
 35. Jørgensen L, Joakimsen O, Rosvold Berntsen GK, Heuch I, Jacobsen BK. Low bone mineral density is related to echogenic carotid artery plaques: a population-based study. *Am J Epidemiol* 2004; 160: 549-56.
 36. Hak AE, Pols HA, van Hemert AM, Hofman A, Witteman JC. Progression of aortic calcification is associated with metacarpal bone loss during menopause: a population-based longitudinal study. *Arterioscler Thromb Vasc Biol* 2000; 20: 1926-31.
 37. Klemetti E, Collin HL, Forss H, Markkanen H, Lassila V. Mineral status of skeleton and advanced periodontal disease. *J Clin Periodontol* 1994; 21: 184-8.
 38. Taguchi A, Tanimoto K, Sueti Y, Wada T. Tooth loss and mandibular osteopenia. *Oral Surg Oral Med Oral Pathol Oral Radiol Endod* 1995; 79: 127-32.
 39. Pizzo G, Guiglia R, Lo Russo L, Campisi G. Dentistry and internal medicine: from the focal infection theory to the periodontal medicine concept. *Eur J Intern Med* 2010; 21: 496-502.
 40. Serhan CN. Clues for new therapeutics in osteoporosis and periodontal disease: new roles for lipoxygenases? *Expert Opin Ther Targets* 2004; 8: 643-52.
 41. Ledgerton D, Horner K, Devlin H, Worthington H. Radiometric indices of the mandible in a British female population. *Dentomaxillofac Radiol* 1999; 28: 173-81.
 42. Persson RE, Hollender LG, MacEntee MI, Wyatt CC, Kiyak HA, Persson GR. Assessment of periodontal conditions and systemic disease in older subjects. *J Clin Periodontol* 2003; 30: 207-13.
 43. Griniatsos J, Damaskos S, Tsekouras N, Klonaris C, Georgopoulos S. Correlation of calcified carotid plaques detected by panoramic radiograph with risk factors for stroke development. *Oral Surg Oral Med Oral Pathol Oral Radiol Endod* 2009; 108: 600-3.
 44. Damaskos S, Griniatsos J, Tsekouras N, Georgopoulos S, Klonaris C, Bastounis E, et al. Reliability of panoramic radiograph for carotid atheroma detection: a study in patients who fulfill the criteria for carotid endarterectomy. *Oral Surg Oral Med Oral Pathol Oral Radiol Endod* 2008; 106: 736-42.
 45. Friedlander AH, Manesh F, Wasterlain CG. Prevalence of detectable carotid artery calcifications on panoramic radiographs of recent stroke victims. *Oral Surg Oral Med Oral Pathol* 1994; 77: 669-73.
 46. Cohen SN, Friedlander AH, Jolly DA, Date L. Carotid calcification on panoramic radiographs: an important marker for vascular risk. *Oral Surg Oral Med Oral Pathol Oral Radiol Endod* 2002; 94: 510-4.
 47. Siris ES, Miller PD, Barrett-Connor E, Faulkner KG, Wehren LE, Abbott TA, et al. Identification and fracture outcomes of undiagnosed low bone mineral density in postmenopausal women: results from the National Osteoporosis Risk Assessment. *JAMA* 2001; 286: 2815-22.
 48. Beck J, Garcia R, Heiss G, Vokonas PS, Offenbacher S. Periodontal disease and cardiovascular disease. *J Periodontol* 1996; 67: 1123-37.
 49. Mattila KJ, Asikainen S, Wolf J, Jousimies-Somer H, Valtonen V, Nieminen M. Age, dental infections, and coronary heart disease. *J Dent Res* 2000; 79: 756-60.
 50. Hujoel PP, Drangsholt MT, Spiekerman C, DeRouen TA. Periodontal disease and risk of coronary heart disease. *JAMA* 2001; 285: 40-1.
 51. Houshmand M, Holtfreter B, Berg MH, Schwahn C, Meisel P, Biffar R, et al. Refining definitions of periodontal disease and caries for prediction of incident tooth loss. *J Clin Periodontol* 2012; 39: 635-44.
 52. Liang LR, Wong ND, Shi P, Zhao LC, Wu LX, Xie GQ, et al. Cross-sectional and longitudinal association of cigarette smoking with carotid atherosclerosis in Chinese adults. *Prev Med* 2009; 49: 62-7.
 53. Karnath B. Smoking cessation. *Am J Med* 2002; 112: 399-405.
 54. Song YM, Cho HJ. Risk of stroke and myocardial infarction after reduction or cessation of cigarette smoking: a cohort study in Korean men. *Stroke* 2008; 39: 2432-8.
 55. Kawachi I, Colditz GA, Stampfer MJ, Willett WC, Manson JE, Rosner B, et al. Smoking cessation in relation to total mortality rates in women. A prospective cohort study. *Ann Intern Med* 1993; 119: 992-1000.
 56. Rosenberg L, Kaufman DW, Helmrich SP, Shapiro S. The risk of myocardial infarction after quitting smoking in men under 55 years of age. *N Engl J Med* 1985; 313: 1511-4.
 57. Liu S, Lee IM, Ajani U, Cole SR, Buring JE, Manson JE, et al.

- Intake of vegetables rich in carotenoids and risk of coronary heart disease in men: The Physicians' Health Study. *Int J Epidemiol* 2001; 30: 130-5.
58. Hung HC, Joshipura KJ, Jiang R, Hu FB, Hunter D, Smith-Warner SA, et al. Fruit and vegetable intake and risk of major chronic disease. *J Natl Cancer Inst* 2004; 96: 1577-84.
59. Dauchet L, Montaye M, Ruidavets JB, Arveiler D, Kee F, Bingham A, et al. Association between the frequency of fruit and vegetable consumption and cardiovascular disease in male smokers and non-smokers. *Eur J Clin Nutr* 2010; 64: 578-86.
60. Folsom AR, Rasmussen ML, Chambless LE, Howard G, Cooper LS, Schmidt MI, et al. Prospective associations of fasting insulin, body fat distribution, and diabetes with risk of ischemic stroke. The Atherosclerosis Risk in Communities (ARIC) Study Investigators. *Diabetes Care* 1999; 22: 1077-83.
61. Hankey GJ, Jamrozik K, Broadhurst RJ, Forbes S, Burvill PW, Anderson CS, et al. Long-term risk of first recurrent stroke in the Perth Community Stroke Study. *Stroke* 1998; 29: 2491-500.