

An Anatomic Reconstruction of Both the Anterior Cruciate Ligament and Fibular Collateral Ligament Using Autografts



Luke V. Tollefson, B.S., Evan P. Shoemaker, B.A., Nathan J. Jacobson, M.D., Erik L. Slette, M.D., and Robert F. LaPrade, M.D., Ph.D.

Abstract: Fibular collateral ligament (FCL) tears rarely occur in isolation and are typically injured in conjunction with another ligament, including the anterior cruciate ligament (ACL). Reconstruction of both ACL and the FCL is critical to restore proper knee biomechanics and stability. This technique describes an anatomic reconstruction of both the ACL using a bone–patellar tendon–bone autograft and the FCL using a semitendinosus hamstring autograft. Previous biomechanical studies have reported on the effect of ACL and FCL tears on lateral gapping and the importance of reconstruction to restore near native stability. Outcomes studies have reported positive patient outcomes for both techniques individually and together.

Isolated injuries to the fibular collateral ligament (FCL) are rare, occurring in approximately 2% of ligament injuries.^{1,2} The FCL typically is injured in conjunction with the anterior cruciate ligament (ACL), the posterior cruciate ligament, or other structures that make up the posterolateral corner, including the popliteus tendon and popliteofibular ligament.^{1,2} Diagnosis of FCL injuries can be done on varus stress radiographs, with gapping of 2.7 to 4.0 mm indicating a tear of the FCL and 4.0 mm or greater indicating a complete posterolateral corner injury.³

The FCL is the primary structure in preventing lateral gapping throughout full range of motion and resisting external rotation near extension.⁴ The ACL is the primary structure in preventing anterior tibial translation and internal tibial rotation.⁵ Surgical reconstruction of both the ACL and the FCL is critical to restore proper knee biomechanics and prevent the progression of osteoarthritis.⁶ Reconstruction of the

FCL has reported lower failure rates compared with repair.⁷ Failure to reconstruct the FCL can lead to increased pressure in the medial compartment, leading to additional meniscus injuries and the progression of osteoarthritis.⁶ Furthermore, varus instability leads to increased forces through the ACL or ACL reconstruction graft and can lead to ACL failure if not properly reconstructed.⁸ The purpose of this Technical Note is to describe an anatomic ACL reconstruction using a bone–patellar tendon–bone autograft with an anatomic FCL reconstruction using a semitendinosus tendon autograft.

Surgical Technique

Combined anatomic anterior cruciate ligament and fibular collateral ligament reconstructions using autografts technique are shown in [Video 1](#). The step-by-step guide and surgical pearls are in [Table 1](#).

Anesthesia and Positioning

The patient is positioned in the supine position on the operating table and induced under general anesthesia. A knee examination is performed to validate clinical examination findings, including Lachman and pivot shift examinations to assess for ACL stability and varus stress to assess for FCL stability. A well-padded high left thigh tourniquet is placed. The surgical leg is placed in a leg holder (Mizho OSI, Union City, CA) and the nonsurgical leg into an abduction stirrup (Birkova Product LLC,

From Twin Cities Orthopedics, Edina, Minnesota, U.S.A.

Received April 15, 2024; accepted May 3, 2024.

Address correspondence to Robert F. LaPrade, M.D., Ph.D., Twin Cities Orthopedics, 4010 W. 65th St., Edina, Minnesota, 55435, U.S.A. E-mail: laprademdphd@gmail.com

© 2024 THE AUTHORS. Published by Elsevier Inc. on behalf of the Arthroscopy Association of North America. This is an open access article under the CC BY-NC-ND license (<http://creativecommons.org/licenses/by-nc-nd/4.0/>).

2212-6287/24638

<https://doi.org/10.1016/j.eats.2024.103085>

Table 1. Step-by-Step Guide and Surgical Pearls for an Anatomic Reconstruction of the ACL and FCL Using Autografts

| Step-by-Step Guide | Surgical Pearls |
|--|--|
| Incision from midpatella to distal aspect of tibial tubercle. | Incision should be long enough to also perform hamstring harvest in subsequent steps. |
| Harvest BTB patellar tendon autograft for ACL. | A 10- × 20-mm bone plug from the patella and a 10 × 25-mm bone plug from the tibial tubercle should be obtained. |
| The semitendinosus tendon at the pes anserine bursa is isolated and adhesions are removed. | A finger, Cobb elevator, and Metzenbaum scissors can be used to remove all hamstring adhesions. |
| A hamstring harvester is used to harvest the tendon and it is then dissected off the tibia. | Care should be taken to follow tendon trajectory to avoid amputating the graft |
| A posterolateral hockey stick incision is made for the FCL reconstruction. | Incision should be 10 cm in length, extending proximally from the Gerdy tubercle. |
| Peroneal nerve neurolysis should be performed to prevent postoperative foot drop. | Care should be taken in properly identifying nerve to prevent iatrogenic damage. |
| The biceps bursa is entered to identify the FCL attachment on the fibula. | A stitch is placed in the FCL for tensioning to identify the femoral attachment. |
| The FCL attachment on the fibular head is identified, debrided, and a guide pin is drilled followed by a 6-mm reamer. | The FCL fibular attachment is typically 8 mm posterior to the anterior margin of the fibular head and 28 mm distal to the fibular styloid tip. |
| The iliotibial band is split and the attachment site of the FCL on the femur is identified. | The tensioning stitch is useful to determine the attachment point. |
| A guide pin is drilled followed by a 6-mm reamer and then a 7-mm tap. | Tunnel angle should be noted to avoid possible convergence with future ACL tunnel. |
| Medial and lateral parapatellar portal are made. | A third more medial portal is made to help with drilling the ACL femoral tunnel. |
| A guide pin is drilled through the ACL attachment site on the femur and is followed by a 10-mm reamer to a depth of about 20 mm. | Hyperflexion of the knee can help in drilling this tunnel. |
| The tibial tunnel is now drilled with a guide pin first, followed by a 10-mm reamer for the full depth of the tunnel. | The ACL tibial attachment is adjacent to the anterior lateral meniscus root. |
| The ACL graft is pulled up through the tibial tunnel and secured in the femoral tunnel with a 7 × 20-mm titanium screw. | The screw should be located at the posterior aspect of the tunnel. |
| The FCL graft is secured in the femoral tunnel with a 7 × 20-mm bioabsorbable screw. | The graft should be whipstitched to aid in tunnel fixation. |
| The graft is then routed distally, underneath the superficial tissues, and secured in the fibular tunnel with a 7 × 20-mm bioabsorbable screw. | The knee should be in 20° of flexion with a slight valgus force. |
| The ACL is secured in the tibia in extension and neutral rotation with 2 staples. | The graft should be tensioned, and the knee cycled to ensure no impingement is present prior to final graft fixation. |
| Deep and superficial tissues are closed with suture. | Extra bone fragments from the BTB autograft can be used to bone graft sites on the patella and tibia from graft harvest. |

ACL, anterior cruciate ligament; BTB, bone–patellar tendon–bone; FCL, fibular collateral ligament.

Gothenburg, NE). For infection prophylaxis, 2 g of perioperative cefazolin is administered.

Graft Harvest

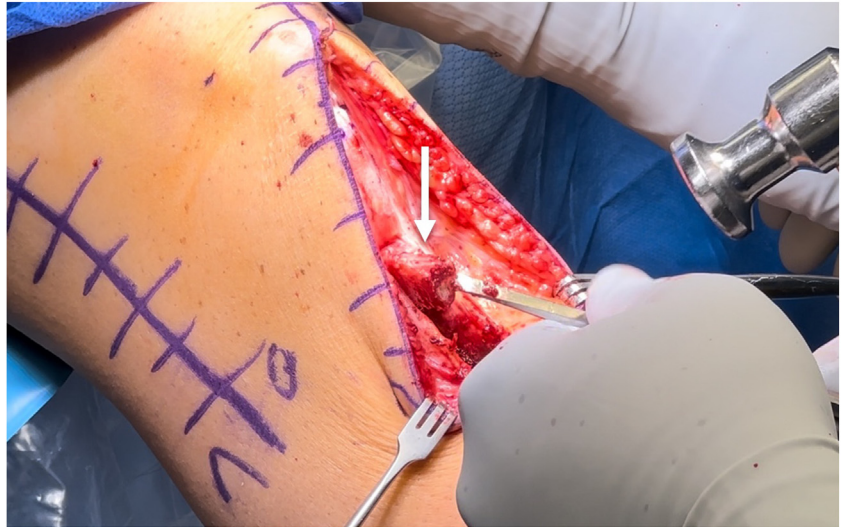
The graft harvest is performed first beginning with the bone–patellar tendon–bone autograft for the ACL reconstruction. An incision is made from the medial patellar distally to the tibial tubercle. The central third of the patellar tendon is harvested with a 10 × 20-mm bone plug off the patella and a 10 × 25-mm bone plug off the tibial tubercle (Fig 1). Next, the attachments of the hamstring tendons at the pes anserine bursa are approached. The semitendinosus tendon is identified and isolated. A large Cobb elevator, Metzenbaum scissors, and the physician's fingers should be used to ensure all adhesions are removed from the tendon. Next, using an open

hamstring harvester, the semitendinosus autograft is harvested proximally and then dissected off the tibia distally (Fig 2).

FCL Tunnels

Next, the locations for the fibular and femoral tunnels for the FCL reconstruction are identified. First, a posterolateral standard hockey stick incision is made extending 10 cm proximally from the Gerdy tubercle. Dissection is carried down to the iliotibial band and bicep femoris tendon. A common peroneal nerve neurolysis is performed to minimize risk of postoperative foot drop. Carefully, the biceps bursa is entered to confirm the FCL is torn. A stitch is placed through the FCL to tension the FCL and facilitate identification of the femur (Fig 3). The FCL attachment on the fibular head is identified and cleared off; this

Fig 1. Right knee patellar tendon bone–patellar tendon–bone harvest with the patient in the supine position for anatomic ACL reconstruction. A 10 × 20-mm bone plug is harvested from the patella with a 10 × 25-mm bone plug from the tibia (white arrow). The center portion of the patella tendon graft is 1 cm in width and the full thickness of the patellar tendon. This incision will be closed at the end of the procedure and the harvest sites will be filled in with bone graft. (ACL, anterior cruciate ligament.)



location is approximately 8 mm posterior to the anterior margin of the fibular head and about 28 mm distal to the fibular styloid tip. A fibular head guide (Smith & Nephew, London, England) is used to drill a guide pin through the fibula (Fig 4). This is overreamed with a 6-mm reamer and a passing stitch is placed. Next, for the femoral tunnel, the iliotibial band is split and the location of the FCL attachment on the femur is identified using the tensioning suture. A guide (Arthrex, Naples, FL) is used to drill a guide pin through the femur, and this is overreamed with a 6-mm reamer, followed by a 7-mm tap, and a passing stitch is placed (Fig 5).

ACL Femoral Tunnel

Next, medial and lateral parapatellar portals are made and the joint is insufflated with saline. The

ACL remnant should be debrided, and the back wall cleared off for the ACL femoral tunnel. A third more medial portal is made, and the knee is hyperflexed. A transportal guide (Arthrex) is used to drill a guide pin through the femur. This is followed by a 10-mm low-profile reamer (Arthrex) to a depth of about 20 mm (Fig 6). The bone bridge between the tunnel and back wall should be approximately 2 mm. A passing stitch is placed.

ACL Tibial Tunnel

Next, the tibial tunnel for the ACL is drilled. Coblation is used to mark the location for the tibia tunnel, which is inline and adjacent to the anterior lateral meniscus root. A guide (Arthrex) is used to drill a guide pin into the joint, originating from

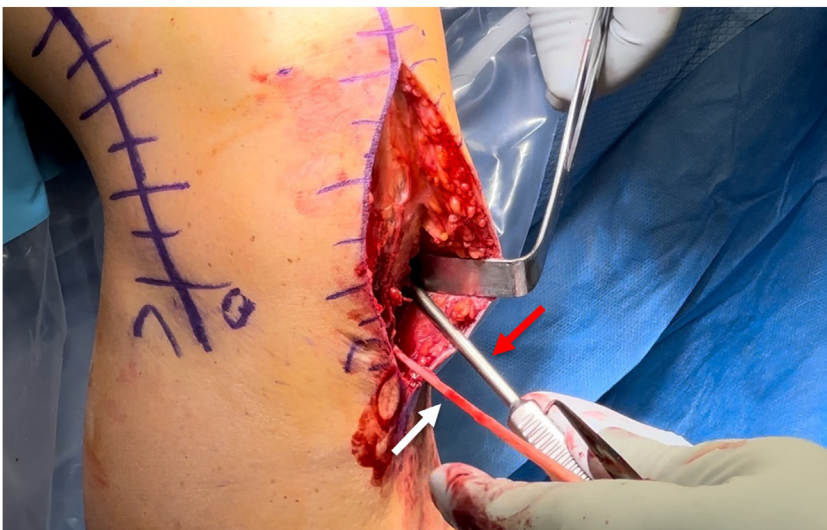

Fig 2. Right knee semitendinosus graft harvest with the patient in the supine position for anatomic FCL reconstruction. The pes anserine bursa is entered, and the hamstring tendons are identified. The semitendinosus tendon (white arrow) should be used for the reconstruction as it is typically more robust than the gracilis tendon. A Cobb elevator, a Metzenbaum scissors, and the physician's finger should be used to remove all adhesions from the graft before harvest. An open hamstring harvester (red arrow) is used to harvest the semitendinosus tendon. The semitendinosus graft is then peeled off the tibia using a scalpel. (FCL, fibular collateral ligament.)

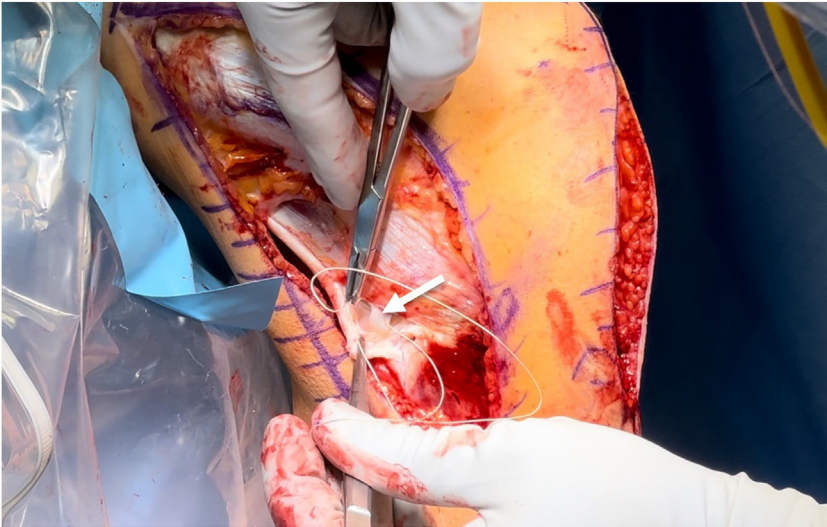


Fig 3. Right knee FCL identification with the patient in the supine position for anatomic FCL reconstruction. After entering the biceps bursa and identifying the FCL attachment on the fibular head (white arrow), a passing stitch is placed through the FCL. This passing stitch can be used to tension the FCL and determine the attachment site on the femur. (FCL, fibular collateral ligament.)

medial to the tibial tubercle (Fig 7). The guide pin is overreamed with a 10-mm reamer. The tunnel is cleared out and a passing stitch is placed.

Graft Passage and Fixation

The ACL graft is secured first by being passed up the tibial tunnel and pulled into position in the femur. A 7 × 20-mm titanium screw (Smith & Nephew) is used to fixate the graft into the ACL femoral tunnel (Fig 8). Next, the FCL semitendinosus autograft, which had been whipstitched, is pulled into the femoral tunnel and fixated with a 7 × 20-mm bioabsorbable screw (Smith & Nephew; Fig 9). Next, the FCL graft is pulled through a channel under the superficial tissues and passed

through the fibular tunnel (Fig 10). The knee is positioned in 20° of flexion, neutral rotation, and slight valgus force. The graft is secured with a 7 × 20-mm bioabsorbable screw (Fig 11). The ACL graft is now secured in the tibia with the knee in extension and with neutral rotation. Two staples (Smith & Nephew) are used to secure the graft (Fig 12). The deep and superficial tissues are closed with a suture.

Postoperative Protocol

After the procedure, the patient is to remain partial weight-bearing for 6 weeks. If any concomitant meniscus pathology is present including root, radial, or horizontal tears, the patient should remain non-weight-bearing for 6 weeks. After 6 weeks, the patient

Fig 4. Right knee FCL tunnel identification on the fibula with the patient in the supine position for anatomic FCL reconstruction. The attachment site of the FCL on the fibula is identified, about 8 mm posterior to the anterior margin of the fibula and 28 mm distal to the fibular styloid (white arrow). The fibula head guide is brought in and a guide pin (black arrow) is drilled through the attachment site with the tunnel directed at the posteromedial downslope of the fibular head. Once the guide pin is drilled, a 6-mm reamer is used to create the tunnel and a passing stitch is placed. (FCL, fibular collateral ligament.)

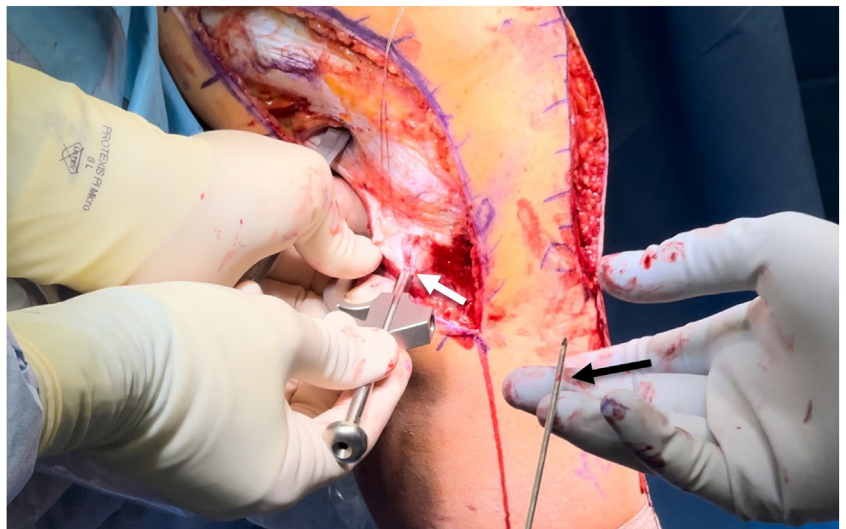


Fig 5. Right knee FCL tunnel identification on the femur with the patient in the supine position for anatomic FCL reconstruction. The previously placed stitch placed into the attachment of the FCL on the fibula is used to tension the FCL and determine the attachment site on the femur (white arrow). The iliotibial band is split at the location of the FCL attachment. Once the attachment of the FCL on the femur is identified, a femoral guide is used to drill as guide pin through the attachment site. A 6-mm reamer with a 7-mm tap is used to create the femoral tunnel. (FCL, fibular collateral ligament.)

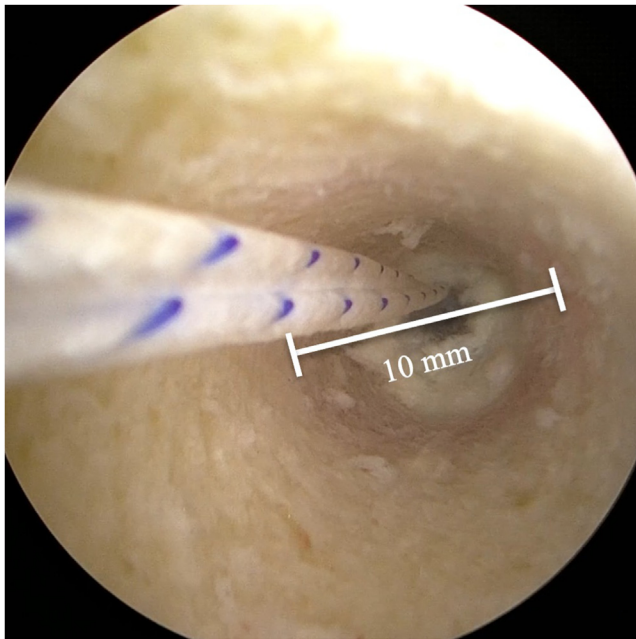
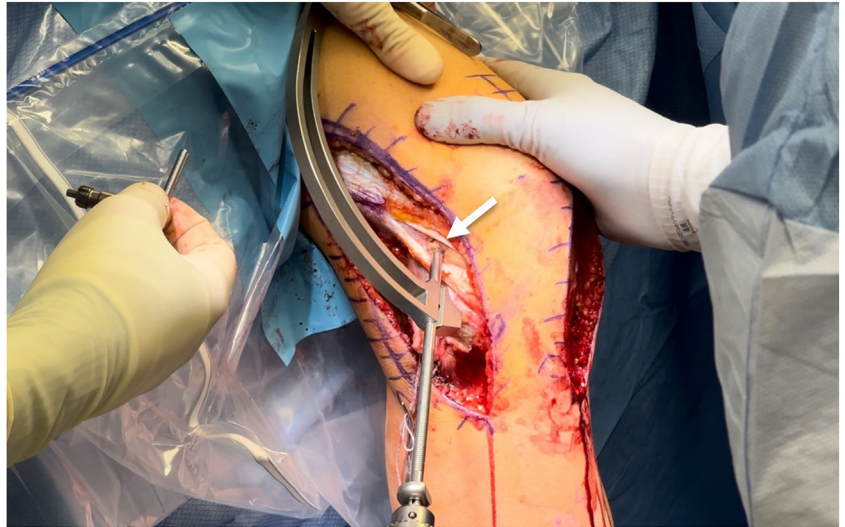


Fig 6. Right knee ACL femoral tunnel drilling with the patient in the supine position for anatomic ACL reconstruction. First, the anatomic attachment of the ACL on the femur is identified and debrided. The knee should be hyperflexed and a guide pin is drilled through the center of the attachment using a transportal guide. A 10-mm low-profile reamer is used to start the tunnel (white line), the reamer should be removed, and the placement of the tunnel verified before drilling to the full depth of 20 mm. A 1.5- to 2-mm backwall should remain. A passing stitch is placed through the tunnel (white and blue suture). (ACL, anterior cruciate ligament.)

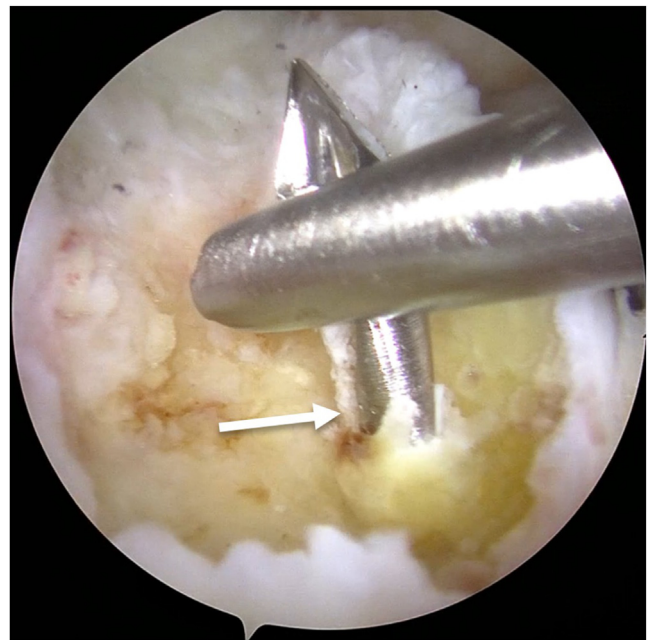


Fig 7. Right knee ACL tibial tunnel drilling with the patient in the supine position for anatomic ACL reconstruction. The ACL attachment on the tibia is identified and the tissue debrided to the bone. This attachment site is directly adjacent to the anterior root of the lateral meniscus. A guide pin is drilled (white arrow) using a tibial ACL guide originating from the medial side of the tibial tubercle. Once the guide pin position location has been verified, a 10-mm acorn reamer is used to drill a full-thickness tunnel. (ACL, anterior cruciate ligament.)

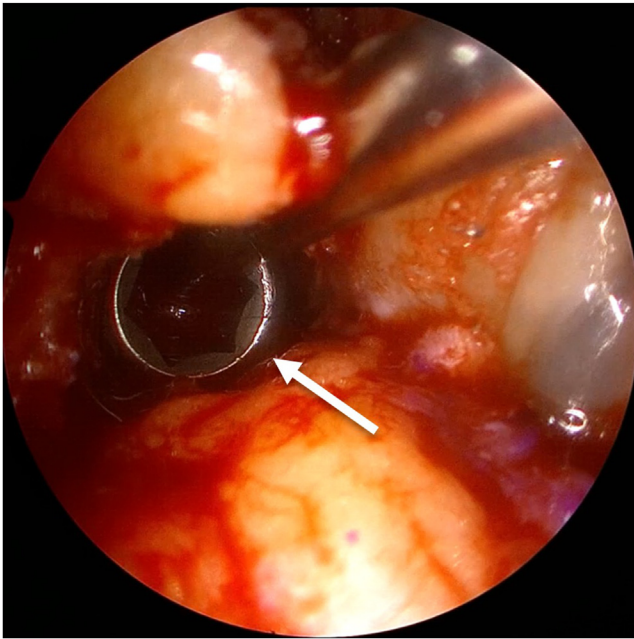


Fig 8. Right knee ACL femoral tunnel screw fixation with the patient in the supine position for anatomic ACL reconstruction. After the ACL tunnels have been drilled, the ACL bone–tendon–bone graft is pulled up through the tibial tunnel and into the femoral tunnel. The knee should be hyperflexed and a blunt-tipped guide is inserted in the tunnel on the superior side of the bone plug. A 7 × 20-mm titanium screw (white arrow) is used to secure the graft at the superior aspect of the tunnel. The cancellous side of the bone plug should be facing superiorly. (ACL, anterior cruciate ligament.)

will progress through a weight-bearing protocol until they can ambulate without a limp. The patient should limit motion to 90° for the first 2 weeks and then increase range of motion as tolerated.

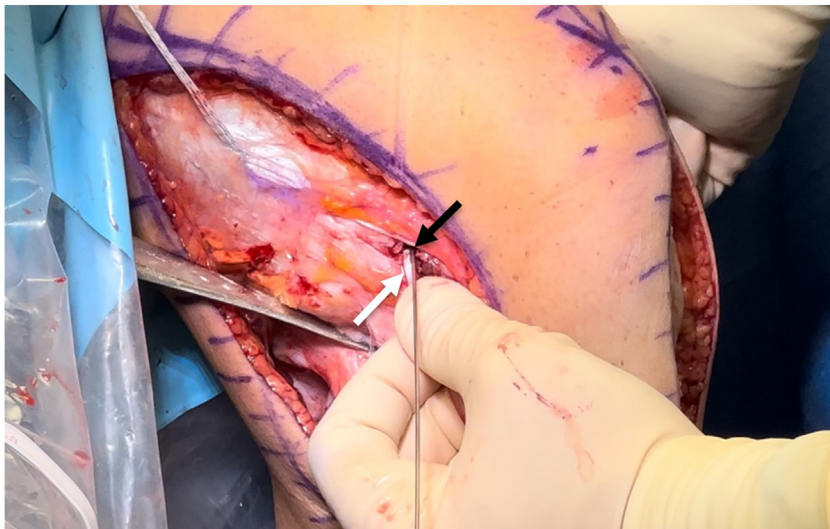


Fig 9. Right knee FCL femoral tunnel screw fixation with the patient in the supine position for anatomic FCL reconstruction. The end of the semitendinosus graft (white arrow) should be whipstitched and pulled into the femoral tunnel using the passing stitch. A blunt-tipped guide is inserted (black arrow) in the superior aspect of the tunnel and tension is applied from the whipstitch attached to the graft on the medial side of the femur. A 7 × 20-mm bioabsorbable screw is used to fixate the graft into the tunnel. (FCL, fibular collateral ligament.)

Discussion

This technique is unique in that it uses autograft for both the ACL reconstruction and the FCL. Reconstruction of both the ACL and FCL is critical to restore knee stability and improve patient outcomes.^{4,7,9} Biomechanically, the ACL and FCL both contribute to varus stress and prevent lateral opening with the ACL contributing to 1.3 mm of lateral opening and the FCL contributing to 2.2 mm of lateral opening.¹⁰ Studies by Coobs et al.¹¹ and Goldsmith et al.¹² reported on the restoration of near-native knee biomechanics after anatomic FCL reconstruction and single-bundle ACL reconstruction, respectively.

Outcomes for ACL reconstructions and FCL reconstructions have reported positive outcomes both together and in isolation.^{4,7,9} A study by Levy et al.⁷ on the outcomes of FCL reconstruction versus repair reported a 40% (4 of 10 patients) failure rate for FCL repairs compared with 6% (1 of 18 patients) failure rate for the reconstruction cohort. In addition, outcomes studies have reported positive patient outcomes for both subjective outcomes scores and objective outcomes for patients undergoing ACL reconstruction with concomitant FCL reconstruction.⁹

The advantages of this technique are that the FCL and ACL are reconstructed in an anatomic fashion which has been reported to best restore knee biomechanics. In addition, the use of all autografts is a cheaper option compared to using allografts. The disadvantages of this technique include donor-site morbidity from the bone–tendon–bone and hamstring autografts harvests and the additional incisions required. The full list of advantages and disadvantages of this study is presented in [Table 2](#).

Fig 10. Right knee FCL graft passage with the patient in the supine position for anatomic FCL reconstruction. After the fixation of the FCL in the femoral tunnel (black arrow), the FCL channel (white line), which is under the superficial layers of the iliotibial band, is identified and adhesions are removed. The FCL graft is then passed through this channel to the location of the FCL fibular tunnel. (FCL, fibular collateral ligament.)

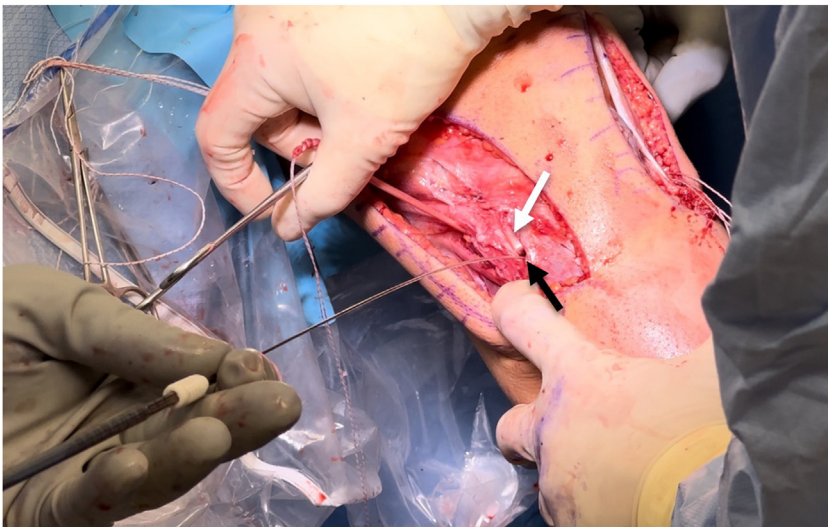
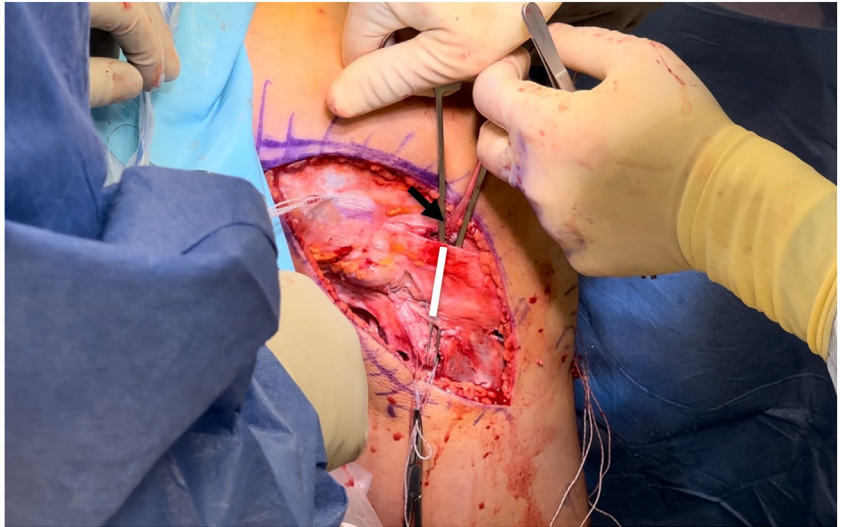


Fig 11. Right knee FCL fibular tunnel screw fixation with the patient in the supine position for anatomic FCL reconstruction. The end of the semitendinosus graft should be pulled through the fibular tunnel from lateral to medial using the passing stitch. A blunt-tipped guide is inserted in the inferior aspect of the tunnel and tension is applied to the graft. A 7 × 20-mm bioabsorbable screw is used to fixate the graft into the tunnel. (FCL, fibular collateral ligament.)

Fig 12. Right knee ACL tibial tunnel fixation with the patient in the supine position for anatomic ACL reconstruction. After the femoral fixation of the ACL and the full fixation of the FCL graft, the ACL should be fixated on the tibia. The knee should be cycled a few times before fixation to ensure there is no impingement. The knee should be in extension with neutral rotation. Because of the length of the patellar tendon and bone plugs, the graft is fixated with 2 staples. This fixation can also be done with a titanium screw if the bone plug is fully immersed in the tunnel. The 2 staples (black arrow) are pounded into the tibia, encapsulating the bone plug (white arrow), while tension is applied to the graft. Final graft position in the knee should be confirmed with arthroscopy. (ACL, anterior cruciate ligament; FCL, fibular collateral ligament.)

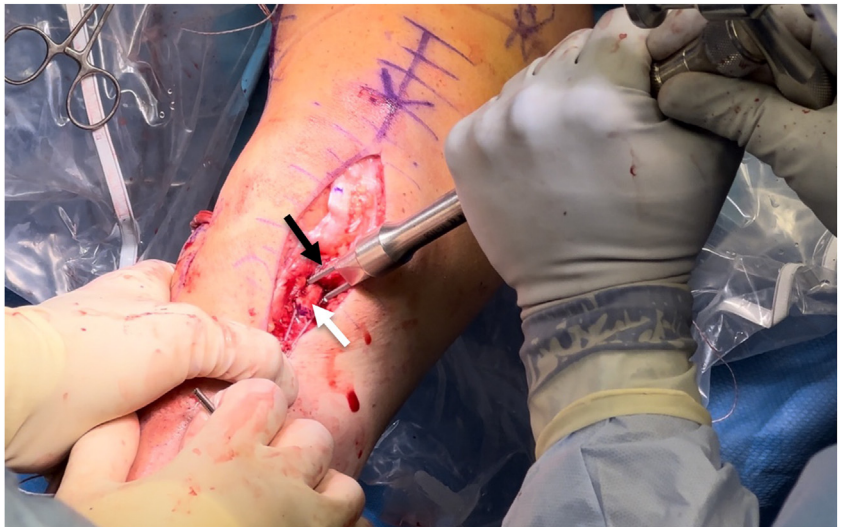

Table 2. Advantages and Disadvantages of a Combined Anatomic Anterior Cruciate Ligament and Fibular Collateral Ligament Reconstructions Using Autograft

| Advantages | Disadvantages |
|---|---|
| Anatomic reconstruction of both ACL and FCL | Donor-site morbidity from both BTB and hamstring autograft harvest |
| Autografts are cheaper compared with allografts | Large incision required for graft harvest and reconstruction |
| Hamstrings can be harvested from same incision as BTB graft harvest | Potential for ACL and FCL femoral tunnel convergence |
| Autografts heal in faster than allografts | Increased surgical time for graft harvest |
| Concomitant meniscus or chondral injuries can be addressed during arthroscopic portion of surgery | Hamstring grafts can be amputated if adhesions are not removed properly |

ACL, anterior cruciate ligament; BTB, bone–patellar tendon–bone; FCL, fibular collateral ligament.

Disclosures

The authors declare the following financial interests/personal relationships which may be considered as potential competing interests: R.L. reports consulting or advisory for and funding grants from Ossur; consulting or advisory for, funding grants from, and travel reimbursement from Smith & Nephew; consulting or advisory for Responsive Arthroscopy; funding grants from with Arthroscopy Association of North America and American Orthopaedic Society for Sports Medicine; speaking and lecture fees from Foundation Medical; and a patent with royalties paid to Ossur. All other authors (L.T., E.S., N.J., E.S.) declare that they have no known competing financial interests or personal relationships that could have appeared to influence the work reported in this paper.

References

1. Figueroa F, Figueroa D, Putnis S, Guiloff R, Caro P, Espregueira-Mendes J. Posterolateral corner knee injuries: A narrative review. *EFORT Open Rev* 2021;6:676-685.
2. LaPrade RF, Wentorf FA, Fritts H, Gundry C, Hightower CD. A prospective magnetic resonance imaging study of the incidence of posterolateral and multiple ligament injuries in acute knee injuries presenting with a hemiarthrosis. *Arthroscopy* 2007;23:1341-1347.
3. LaPrade RF, Heikes C, Bakker AJ, Jakobsen RB. The reproducibility and repeatability of varus stress radiographs in the assessment of isolated fibular collateral ligament and grade-III posterolateral knee injuries. An in vitro biomechanical study. *J Bone Joint Surg Am* 2008;90:2069-2076.
4. Dekker TJ, Schairer WW, Grantham WJ, DePhillipo NN, Aman ZS, LaPrade RF. Fibular collateral ligament reconstruction graft options: Clinical and radiographic outcomes of autograft versus allograft. *Arthroscopy* 2021;37:944-950.
5. Noyes FR, Huser LE, Palmer M. A biomechanical study of pivot-shift and Lachman translations in anterior cruciate ligament-sectioned knees, anterior cruciate ligament-reconstructed knees, and knees with partial anterior cruciate ligament graft slackening: Instrumented Lachman tests statistically correlate and supplement subjective pivot-shift tests. *Arthroscopy* 2021;37:672-681.
6. Griffith CJ, Wijdicks CA, Goerke U, Michaeli S, Ellermann J, LaPrade RF. Outcomes of untreated posterolateral knee injuries: An in vivo canine model. *Knee Surg Sports Traumatol Arthrosc* 2011;19:1192-1197.
7. Levy BA, Dajani KA, Morgan JA, Shah JP, Dahm DL, Stuart MJ. Repair versus reconstruction of the fibular collateral ligament and posterolateral corner in the multiligament-injured knee. *Am J Sports Med* 2010;38:804-809.
8. Moatshe G, Dean CS, Chahla J, Serra Cruz R, LaPrade RF. Anatomic fibular collateral ligament reconstruction. *Arthrosc Tech* 2016;5:e309-e314.
9. Moulton SG, Matheny LM, James EW, LaPrade RF. Outcomes following anatomic fibular (lateral) collateral ligament reconstruction. *Knee Surg Sports Traumatol Arthrosc* 2015;23:2960-2966.
10. Gursoy S, Perry AK, Dandu N, et al. Effect of sectioning of the anterior cruciate ligament and posterolateral structures on lateral compartment gapping: A randomized biomechanical study. *Orthop J Sports Med* 2022;10:23259671221100216.
11. Coobs BR, LaPrade RF, Griffith CJ, Nelson BJ. Biomechanical analysis of an isolated fibular (lateral) collateral ligament reconstruction using an autogenous semitendinosus graft. *Am J Sports Med* 2007;35:1521-1527.
12. Goldsmith MT, Jansson KS, Smith SD, Engebretsen L, LaPrade RF, Wijdicks CA. Biomechanical comparison of anatomic single- and double-bundle anterior cruciate ligament reconstructions: An in vitro study. *Am J Sports Med* 2013;41:1595-1604.