

# Complete treatment with partial cystectomy in giant xanthogranulomatous cystitis case imitating bladder tumor

Mehmet Balasar, Mehmet Giray Sönmez, Pembe Oltulu<sup>1</sup>, Abdülkadir Kandemir, Mehmet Kılıç<sup>2</sup>, Recai Gürbüz

Departments of Urology, <sup>1</sup>Medical Pathology and <sup>2</sup>Medical Pharmacology, Meram Medical Faculty, Necmettin Erbakan University, Konya, Turkey

## Abstract

Xanthogranulomatous cystitis (XC) is a very rare chronic benign inflammatory disease of the bladder. It may cause local invasion although it is not a malign lesion and may occur together with malign lesions. It has a clinical importance as the distinction from malign lesions is difficult clinically and pathologically. Sharing a 37-year-old female case with giant XC imitating bladder tumor referring to the hospital with hematuria and stomach ache, together with current literature, we wanted to present that the disease can be treated with bladder-preserving approaches instead of radical approaches even though the mass is big in these cases. Application of basic excision and partial resection for small masses and radical cystectomy for large masses was reported in literature. We think that our case may provide a contribution to literature in treatment approach since we provided surgical cure with partial resection in a big mass with dimensions of 9 cm × 8 cm which is different from the present literature. Even though XC is a rare disease, it should be considered in prediagnosis for especially big dimensioned masses, and treatment should be planned according to the pathology result after together with cystoscopy in suitable patients.

**Key Words:** Inflammatory disease, magnetic resonance imaging, partial cystectomy, xanthogranulomatous cystitis

## Address for correspondence:

Dr. Mehmet Giray Sönmez, Yunus Emre Quarter, Department of Urology, Meram Medical Faculty, Necmettin Erbakan University, Konya 42080, Turkey.  
E-mail: drgiraysonmez@gmail.com

**Received:** 03.06.2016, **Accepted:** 20.07.2016

## INTRODUCTION

Xanthogranulomatous cystitis (XC) is a very rare chronic benign inflammatory disease of the bladder. Colon, pancreas, stomach, lung, appendix, gall bladder, over, vagina and endometrium cases were also reported apart from the bladder. Function disorder occurring in macrophages due to immunological defect is held responsible. It is considered that chronic irritation plays an important role in etiology. It may cause local invasion although

it is not a malign lesion and may be seen together with malign lesions. It has a clinical significance as its distinction from malign lesions is difficult in clinical and pathological terms.<sup>[1,2]</sup>

In the light of current literature, we wanted to share XC case imitating bladder cancer radiologically and macroscopically in the patient referring with stomach ache and hematuria.

This is an open access article distributed under the terms of the Creative Commons Attribution-NonCommercial-ShareAlike 3.0 License, which allows others to remix, tweak, and build upon the work non-commercially, as long as the author is credited and the new creations are licensed under the identical terms.

**For reprints contact:** reprints@medknow.com

**How to cite this article:** Balasar M, Sönmez MG, Oltulu P, Kandemir A, Kılıç M, Gürbüz R. Complete treatment with partial cystectomy in giant xanthogranulomatous cystitis case imitating bladder tumor. *Urol Ann* 2017;9:204-7.

### Access this article online

#### Quick Response Code:



#### Website:

www.urologyannals.com

#### DOI:

10.4103/0974-7796.204193

## CASE REPORT

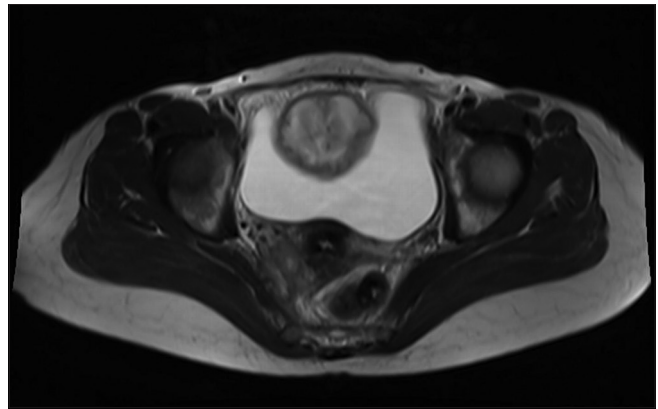
A 37-year-old female was presented to the urology clinic with low abdominal pain throughout the couple last months, yet she was painless for the last half a month. Accompanying low abdominal pain, there was also a 1 week hematuria history. During the physical examination, a hard suprapubic mass, bimanually palpable, was determined. It can mimic clinically and macroscopically malignancy.<sup>[3]</sup>

Laboratory analyses showed a normal hematological and biochemical profile. However, patient's urinalysis revealed plenty of red blood cells per high-power field. The urine culture of the patient was sterile. Patient's ultrasonography showed a heterogeneous mass lesion at the anterior wall of the bladder. Patient's magnetic resonance image (MRI) demonstrated a cyst of 90 mm × 80 mm on the anterior wall of the bladder. The MRI revealed no invasion on the surrounding organs [Figure 1].

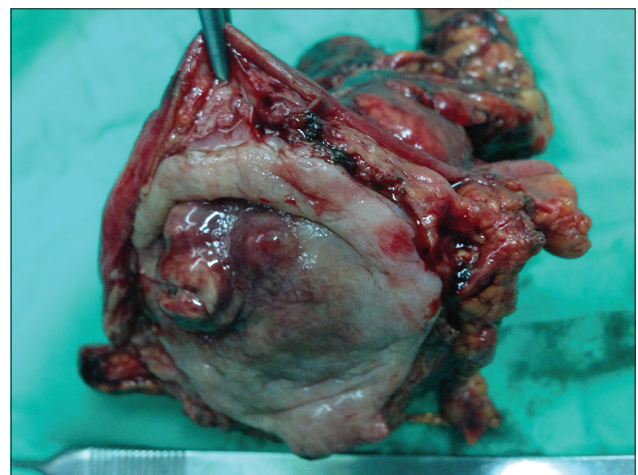
A tumoral fistula opening to the superior bladder wall was observed during patient's cystoscopy. Thereupon, the patient underwent surgical exploration. A solid mass of 9 cm reaching from the bladder into the abdominal cavity was seen. It was removed via mass partial cystectomy and simple excision [Figure 2]. The histological analysis of the obtained specimen revealed chronic inflammatory XC. Xanthogranulomatous macrophages were negative for periodic acid-Schiff-positive material, and calcospherules (Michaelis–Guttman bodies) [Figure 3], CD68-positive epithelioid and foamy macrophages were detected [Figure 4]. Acid-fast bacilli staining was also negative. Likewise was the immunohistochemical staining for cytokeratin. No malignancy or urachal remnant abnormalities were observed. No complications occurred during the postoperative period. Moreover, during the 1-year follow-up, the patient has not reported any complaints.

## DISCUSSION

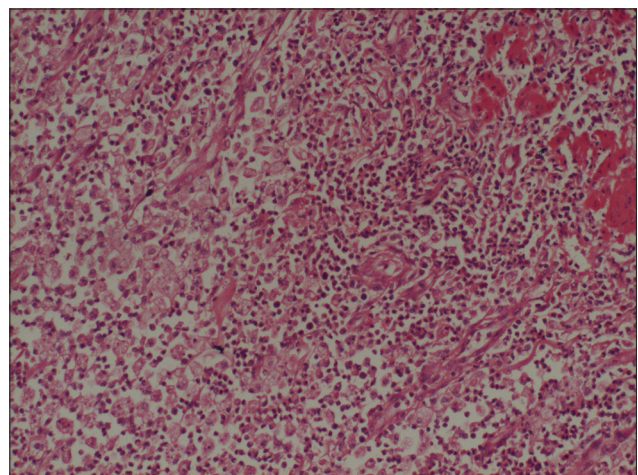
Xanthogranuloma is a rare granulomatous inflammatory condition characterized by the presence of multinucleated giant cells, lipid-laden macrophages (xanthoma cells), and cholesterol crystals.<sup>[4]</sup> Histologically, xanthogranulomatous lesions can be confused with malakoplakia and can be differentiated from it, by the absence of Michaelis–Guttman bodies (basophilic lamellar inclusion bodies) and the presence of large number of monocytes.<sup>[2]</sup> It was first reported in 1932,<sup>[5]</sup> and according to the best of our knowledge, there are less than thirty cases (up to now, more than twenty cases have been reported in PubMed literatures) with the following clinical characteristics: Median age of 45 years; no obvious sexual preference; majority of lesions located in the bladder



**Figure 1:** Magnetic resonance image demonstrated a cyst on the anterior wall of the bladder

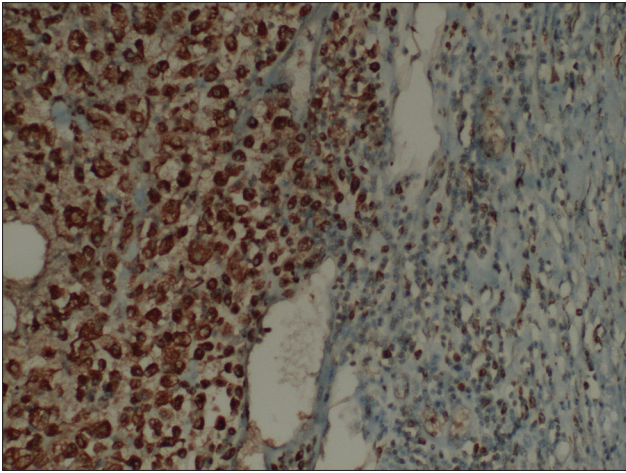


**Figure 2:** Macroscopic partial cystectomy sample image



**Figure 3:** Microscopy of simple excision samples reveals foamy histiocytes and absence of Michaelis–Guttman bodies (×100)

dome (85.7%), and associated mostly with an urachal remnant (70.8%).<sup>[6]</sup> Yang *et al.* reported an unusual mass located on the posterobasal wall of the bladder without a relation to the urachus.<sup>[7]</sup> However, a few were associated with



**Figure 4:** CD68-positive epithelioid and foamy macrophages were detected ( $\times 200$ )

urothelial carcinoma or urachal carcinoma.<sup>[8]</sup> In XC urinary symptoms, abdominal pain or umbilical discharge is present.<sup>[9]</sup> Although hematuria is a common symptom, it may not be seen in every case.<sup>[2]</sup> In the present case, a 37-year-old woman, there were low abdominal pain and hematuria complaints. During initial imaging and surgical procedure, lesion, stemming from the superior bladder wall, was explicit.

Although the etiology of XC is still unclear, some explanations proposed are as follows: A chronic inflammatory process caused by mechanisms such as (a) immunological defect of the macrophage, (b) Gram-negative or anerobic bacteria presence in urinary tract infections or infections after tubal ligation,<sup>[10]</sup> (c) chronic infection or cystitis of the urachal diverticulum, (d) foreign body such as suture material retained,<sup>[11]</sup> (e) local response to bladder tumor,<sup>[8,12]</sup> (f) abnormal lipid metabolism and accumulation, and (g) inflammatory bowel disease.<sup>[13]</sup> In the present case, the underlying reason of XC could be a response to chronic infection without obvious symptoms.

As medical treatment is considered not to yield the expected outcomes, conservative management is rarely preferred.<sup>[6,14]</sup> In the treatments, surgical resection is preferred as there are no reports about postoperative recurrence.<sup>[15]</sup> Many times, a simple excision may suffice for a localized xanthogranuloma; however, if combined with adenoma or an urachal remnant, then partial cystectomy can be considered. If urachal carcinomas are suspected, an extensive surgery including urachal tract excision can be necessary. Additional antibiotic therapy may be considered in cases with positive microbial cultures.<sup>[10]</sup> Yet, as XC is associated with urachal remnant as a source of chronic bacterial infection, conservative treatment is not preferred.<sup>[9]</sup>

Application of basic excision and partial resection for small masses<sup>[1]</sup> and radical cystectomy for large masses<sup>[2]</sup> was reported in literature. We think that our case may provide a contribution to literature in treatment approach since we provided surgical cure with partial resection in a big mass with dimensions of 9 cm  $\times$  8 cm, which is different from the present literature.

To summarize, in the present case, histological features were similar to other XC cases reported. Treatment preferred was simple excision of the lesion and a close follow-up.

## CONCLUSION

Even though XC is a rare disease, it should be considered in prediagnosis for especially big dimensioned masses and treatment should be planned according to the pathology result after together with cystoscopy in suitable patients. Hence, there may be a treatment chance with partial resection for the patient without applying radical treatments as in our case.

## Financial support and sponsorship

Nil.

## Conflicts of interest

There are no conflicts of interest.

## REFERENCES

1. Wang Y, Han XC, Zheng LQ, Miao WL. Xanthogranulomatous cystitis imitating bladder neoplasm: A case report and review of literature. *Int J Clin Exp Pathol* 2014;7:8255-8.
2. Ali AM, Nelvigi GG, Keshavaiah VG, Ratkal CS. Extensive xanthogranulomatous cystitis mimicking bladder cancer. *Urol Ann* 2014;6:373-5.
3. Russack V, Lammers RJ. Xanthogranulomatous endometritis. Report of six cases and a proposed mechanism of development. *Arch Pathol Lab Med* 1990;114:929-32.
4. Ota N. Urachal tumor of inflammatory origin. A case report. *Grangigebie* 1933;7:1205.
5. Wassiljew AI. About the diseases of urachus. *Z Urol Chir* 1932;35:199-212.
6. Ong C, Lee VK, Mohamed Suphan N, Ng JS. Xanthogranulomatous cystitis: A case report and clinicopathological review. *Ann Acad Med Singapore* 2013;42:301-3.
7. Yang KS, Kim YH, Seong YK, Kim IG, Han BH, Kim SJ. Xanthogranulomatous cystitis arising from the posterior wall of the bladder. *Korean J Urol* 2011;52:868-9.
8. Bates AW, Fegan AW, Baihuth SI. Xanthogranulomatous cystitis associated with malignant neoplasms of the bladder. *Histopathology* 1998;33:212-5.
9. Hayashi N, Wada T, Kiyota H, Ueda M, Oishi Y. Xanthogranulomatous cystitis. *Int J Urol* 2003;10:498-500.
10. Tai HL, Chen CC, Yeh KT. Xanthogranulomatous cystitis associated with anaerobic bacterial infection. *J Urol* 1999;162(3 Pt 1):795-6.
11. Chung MK, Seol MY, Cho WY, Seo HK, Kim JS. Xanthogranulomatous cystitis associated with suture material. *J Urol* 1998;159:981-2.
12. Garcia AA, Florentine BD, Simons AJ, Skinner EC, Leichman LW. Xanthogranulomatous cystitis as a cause of elevated carcinoembryonic antigen mimicking recurrent colorectal cancer. Report of a case. *Dis Colon Rectum* 1996;39:1051-4.

13. Chung DE, Carr LK, Sugar L, Hladunewich M, Deane LA. Xanthogranulomatous cystitis associated with inflammatory bowel disease. *Can Urol Assoc J* 2010;4:E91-3.
14. Goel R, Kadam G, Devra A, Patel S, Modi P. Xanthogranulomatous cystitis. *Int Urol Nephrol* 2007;39:477-8.
15. Fornari A, Dambros M, Telöken C, Hartmann AA, Kolling J, Seben R. A case of xanthogranulomatous cystitis. *Int Urogynecol J Pelvic Floor Dysfunct* 2007;18:1233-5.