

Childhood-onset epileptic encephalopathy due to *FGF12* exon 1–4 tandem duplication

Sarah Verheyen, MD, Michael R. Speicher, MD, Barbara Ramler, BSc, and Barbara Plecko, MD

Neurol Genet 2020;6:e494. doi:10.1212/NXG.0000000000000494

Correspondence

Dr. Plecko
barbara.plecko@medunigraz.at

Fibroblast growth factor 12 (*FGF12*) spans 5 exons and encodes for a cytosolic voltage-gated sodium channel binding protein that modulates neuronal excitability.^{1,2} A recurrent activating *FGF12* mutation (NM_021032, [GRCh37] 192053223C>T, p.R114H in A-isoform, p.R52H in B-isoform) causes epileptic encephalopathy (EE) with neonatal onset and intellectual disability (ID).^{2–6} Recently, a tandem duplication involving exons 1–4 of the *FGF12* gene was related to a later onset EE phenotype.⁷ Here, we characterize a second case harboring a *FGF12* exon 1–4 duplication.

A 7-year-old girl, scheduled for second opinion, had to be admitted because of a second untriggered episode of sudden unconsciousness.

She was the product of a second uncomplicated pregnancy of healthy, unrelated Hungarian parents. Her 17-year-old brother was healthy. There was no family history of neurologic disorders. Parents reported normal psychomotor and speech development despite a diagnosis of hypacusis along a neonatal screening test. Since the age of 4 years, she suffered from generalized, tonic, and tonic-clonic seizures that were resistant to valproic acid, phenytoin, and carbamazepine. She was seizure free for 5 months while on phenytoin plus levetiracetam. Under the assumption of an autoimmune disorder, she received 10 sessions of plasmapheresis in her home country at the age of 6 years without any benefit.

Nine months before admission to our hospital, she had a first episode with sudden loss of consciousness that lasted for about 5 hours. Parents reported no triggers, such as fever, vomiting, or irregular administration of her anticonvulsants. She recovered spontaneously without admission to hospital but afterward started to slowly deteriorate with loss of active speech, hand apraxia, and impaired gait along increasing seizure frequency.

On the day of admission, she was found unresponsive in bed, 1 hour after having had breakfast; she had been her usual self the evening before and had taken her anticonvulsants regularly (levetiracetam, phenytoin, clobazam, and lamotrigine). We saw a nondysmorphic, comatose, afebrile 7-year-old girl (Glasgow coma scale, 7) with heart rate 120/min, spontaneous respiratory rate 18/min, and blood pressure 135/75 mm Hg; her physical examination was otherwise normal; weight, length, and head circumference were on the 50th percentile. Pupils were reactive to light, muscle tone was decreased, and bulbar reflexes were preserved. Blood count, interleukine-6, blood gases, lactate, glucose, electrolytes, transaminases, creatine, alkaline phosphatase, lactate dehydrogenase, and ammonia were all normal. EEG showed nonconvulsive status epilepticus (NCSE) (figure 1A, day 1). She spontaneously regained consciousness after a total of 14 hours, followed by frequent, generalized tonic-clonic seizures that prompted the IV administration of phenytoin, 5 mg/kg in 30 minutes, followed by 3.8 mg/kg in 2 single dosages IV/24 hours with cessation of seizure activity over the following days and improved EEG activity (figure 1A; day 2 and day 7). Drug screening for benzodiazepines and gamma hydroxybutyrate, selective screening for inborn errors of metabolism by plasma acylcarnitines,

From the Institute of Human Genetics (S.V., M.R.S., B.R.), Diagnostic and Research Center for MolecularBioMedicine, Medical University of Graz; and Department of Pediatrics and Adolescent Medicine (B.P.), Division of General Pediatrics, Medical University of Graz, Austria.

Go to [Neurology.org/NG](https://www.neurology.org/NG) for full disclosures. Funding information is provided at the end of the article.

The Article Processing Charge was funded by Medical University of Graz.

This is an open access article distributed under the terms of the Creative Commons Attribution-NonCommercial-NoDerivatives License 4.0 (CC BY-NC-ND), which permits downloading and sharing the work, provided it is properly cited. The work cannot be changed in any way or used commercially without permission from the journal.

plasma amino acids, urinary organic acids, enzyme analysis for neuronal ceroid lipofuscinosis types 1 and 2, serum concentrations of anticonvulsants, and 1.5T MRI of the brain were all normal.

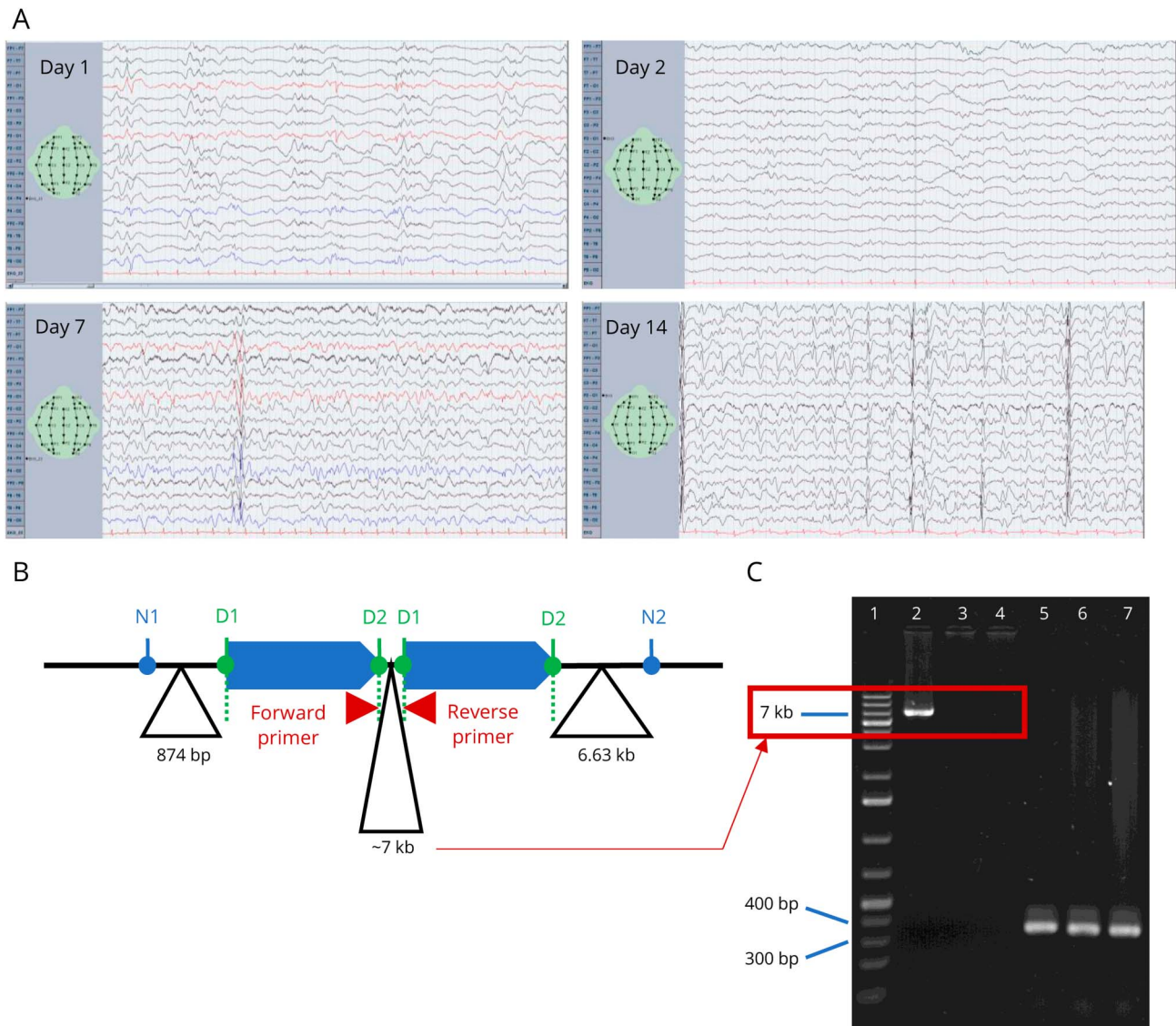
Phenytoin was slowly tapered from day 14 of admission because of parental concerns on potential side effects. After this, she experienced another NCSE that was interrupted by IV midazolam (figure 1A, day 14).

Over the following month, while on lamotrigine, levetiracetam, topiramate, and clobazam, she could be weaned from tube feeding and regained independent walking. She used single

words but had loss of practical hand skills and poor eye contact, inappropriate laughing, and crying as well as sleep disturbances.

Chromosomal analysis was normal (46,XX). Array comparative genomic hybridization revealed a duplication of 583 kb at 3q28-q29, involving exons 1–4 of the *FGF12* gene, [GRCh37] 3q28q29(191874052_192456936x3) (figure e-1, links.lww.com/NXG/A299). The de novo occurrence of the duplicated segment in the patient was confirmed by quantitative real-time PCR of parents' DNA (figure e-2, links.lww.com/NXG/A300). Long-range PCR of the genetic region between the 2 duplicated segments revealed a product of

Figure 1 EEG records, scheme of *FGF12* exon 1–4 tandem duplication, and verification with PCR



(A) Bipolar EEG records (montage as indicated), 30 mm/second; 10 μ vol/mm; 0.300 Hz; 50 Hz Notch filter. Day 1: Glasgow coma scale (GCS) 7, background suppression with periodic bursts of slow wave activity during nonconvulsive status epilepticus (NCSE). Day 2: sleep background, diffuse slowing, and multifocal sharp wave activity. Day 7: primary generalized and bioccipital epileptic discharges. Day 14: GCS 11, NCSE. (B) N1—last nonduplicated DNA oligonucleotide in Array comparative genomic hybridization. D1—begin of duplicated region, first duplicated oligonucleotide. D2—end of duplicated region, last duplicated oligonucleotide. N2—first nonduplicated DNA oligonucleotide in Array CGH. (C) DNA ladder gene ruler 1 kb (1), long-range PCR product: patient DNA (2), paternal DNA (3), and maternal DNA (4). Long-range PCR product was only obtained in case of tandem duplication of *FGF12* because of the primer design (B). Control PCR product of 344 bp using forward primer 5 and reverse primer 6 (within the *FGF12* keltic gene); patient DNA (5), paternal DNA (6), and maternal DNA (7). Primer sequences available in extended materials and methods (links.lww.com/NXG/A303).

about 7 kb, proving tandem arrangement in the affected child, which was absent in her parents (figure 1).

This case shows striking analogies to the patient with tandem duplication involving the *FGF12* gene published by Shi et al.⁷ and suggests that in contrast to mutations of the *FGF12* gene, which cause neonatal onset EE, tandem duplications involving exons 1–4 of *FGF12* cause a different phenotype with normal early development, childhood onset EE, and developmental regression (for comparison of phenotypes, see table e-1, links.lww.com/NXG/A301).

A further case with an exon 1–4 duplication ([GRCh37] Chr3:191,860,089-192,451,114) and a similar phenotype could be extracted from Decipher (Decipher ID: 401650, table e-2, links.lww.com/NXG/A302).

The recurrent missense variant p.R114H/p.R52H that is associated with neonatal or early infantile onset EE is located in exon 3. The affected amino acid is part of the interface between FGF12 and the voltage-gated sodium channel Na_v. The mutation is assumed to decrease binding probability, leading to faster repolarization and consecutive neuronal hyperexcitability.² Duplications or deletions including the whole gene are associated with a variable phenotype from normal development to ID (depending on the size of the aberration), typically without seizures. Small duplications involving exon 1 or exons 4 and 5 only also lack an epilepsy phenotype (for data from Decipher, see table e-2, links.lww.com/NXG/A302).

This supports our assumption that the structural change of the recurrent exon 1–4 duplication, as the recurrent missense variant p.R114H/p.R52H, leads to an altered binding behavior of FGF12 to the sodium channel. Functional studies are warranted to better understand the mechanism of the different variants affecting exon 3 that cause these distinct phenotypes. In the present case, phenytoin led to only transient control of seizures in combination with levetiracetam at the age of 4 years but was beneficial in interrupting a series of frequent tonic-clonic seizures after NCSE at age 7 years.

Acknowledgment

This study makes use of data generated by the DECIPHER community. A full list of centers that contributed to the generation of the data is available at decipher.sanger.ac.uk and can be shared via email upon request (decipher@sanger.ac.uk). Funding for the project was provided by the Wellcome Trust. The authors thank Prof. Dr. Phillip Pearl, Boston, Harvard

Medical School, for discussion on current EEG terminology commonly used in the United States.

Study funding

This study has not been sponsored.

Disclosure

S. Verheyen, M.R. Speicher, B. Ramler, and B. Plecko (corr. author) have nothing to disclose related to the content of this manuscript. Go to Neurology.org/NG for full disclosure.

Publication history

Received by *Neurology: Genetics* January 9, 2020. Accepted in final form May 15, 2020.

Appendix Authors

Name	Location	Contribution
Sarah Verheyen, MD	Medical University of Graz, Austria	Data interpretation and drafting of the manuscript
Michael R. Speicher, MD	Medical University of Graz, Austria	Data interpretation, major input, and revision of the manuscript
Barbara Ramler, BSc	Medical University of Graz, Austria	Array CGH analysis and interpretation of molecular data, drafting of figure 1, and revision of the manuscript
Barbara Plecko, MD	Medical University of Graz, Austria	Characterization of the patient phenotype, major input, and revision of the manuscript

References

1. Goldfarb M, Schoorlemmer J, Williams A, et al. Fibroblast growth factor homologous factors control neuronal excitability through modulation of voltage-gated sodium channels. *Neuron* 2007;55:449–463.
2. Siekierska A, Isrie M, Liu Y, et al. Gain-of-function FHF1 mutation causes early-onset epileptic encephalopathy with cerebellar atrophy. *Neurology* 2016;86:2162–2170.
3. Al-Mehmadi S, Splitt M; For DDD Study Group, et al. FHF1 (*FGF12*) epileptic encephalopathy. *Neurol Genet* 2016;2:e115. doi: 10.1212/NXG.000000000000115.
4. Villeneuve N, Abidi A, Cacciagli P, et al. Heterogeneity of FHF1 related phenotype: novel case with early onset severe attacks of apnea, partial mitochondrial respiratory chain complex II deficiency, neonatal onset seizures without neurodegeneration. *Eur J Paediatr Neurol* 2017;21:783–786.
5. Takrguchi R, Haginoya K, Uchiyama Y, et al. Two Japanese cases of epileptic encephalopathy associated with an *FGF12* mutation. *Brain Dev* 2018;40:728–732.
6. Guella I, Huh L, McKenzie MB, et al. De novo *FGF12* mutation in 2 patients with neonatal-onset epilepsy. *Neurol Genet* 2016;2:e120. doi: 10.1212/NXG.000000000000115.
7. Shi RM, Kobayashi T, Kikuchi A, et al. Phenytoin-responsive epileptic encephalopathy with a tandem duplication involving *FGF12*. *Neurol Genet* 2017;3:e133. doi: 10.1212/NXG.000000000000133.