

The Retrosigmoid Approach: Workhorse for Petroclival Meningioma Surgery

Abstract

Background: Petroclival meningiomas (PCMs) are technically challenging lesions. We retrospectively analyzed our experience with retrosigmoid approach between 2009 and 2015 in 17 patients with PCM to evaluate changes in management strategy. In this study, we evaluated the possible risk factors and challenges for unfavorable clinical outcomes with retrosigmoid approach. **Materials and Methods:** A total of nine patients (53%) of PCM were treated through the retrosigmoid approach in Dr. Ram Manohar Lohia Institute of Medical Sciences, Lucknow. The patients received postoperative neurological and radiological follow-up. The primary difficulty in complete resection and outcomes including postoperative neurological deficits were evaluated, and all potential risk factors were assessed. **Results:** The mean follow-up time was 24 months. The maximum diameter of the tumors ranged from 2.0 cm to 6.8 cm (mean, 3.8 cm). Gross total resection (Simpson Grade II) was achieved in 6 (66%) patients, subtotal resection (Simpson Grade III) in 3 (33%). Two patients (22%) had new neurological deficits or worsening of preexisting deficits. No patient died after surgery. Within the follow-up period, there was no radiographic recurrence in patients with Simpson Grade II excision. Postoperative radiosurgery was administered to three patients who had residual tumors, and no further progression was found in them. **Conclusions:** Tumor characteristics played a critical role in identifying postoperative functional status. The retrosigmoid approach is suitable for treatment of majority of PCMs. It offers Simpson Grade II excision if the main part of the tumor is located in the posterior fossa in the cerebellopontine angle and the lower clivus, and only a minor part of the tumor extends to middle fossa or the posterior wall of the cavernous sinus. With incising tentorium or suprameatal extension middle fossa extension can also be removed. Overall retrosigmoid approach provides a low degree of surgical difficulty and a low complication rate.

Keywords: Cerebellopontine angle, petroclival meningioma, retrosigmoid approach, skull base

Introduction

Meningioma account for 20%–25% of all intracranial tumors and 10% are seen in the posterior fossa. Of posterior fossa meningioma, those arising from the petroclival region account for 5%–11%, thus 0.15% of all intracranial tumors.^[1-3] Originating from the clivus and petrous apex, the tumor may involve the medial part of the tentorium, Meckel's cave, cavernous sinus, and parasellar region. Petroclival meningiomas (PCMs), though typically benign and slow-growing, can become quite large before any clinical symptoms are evident. The majority of patients present with headache, cerebellar signs, or cranial nerve (CN) deficits.^[4-9] Resection of the tumor contributes a great challenge to neurosurgeons. Proximity and adhesion

to CNs, major blood vessels, and the brainstem can make postoperative morbidity and mortality high. Although advances in microneurosurgery have brought out better results, surgical morbidity and mortality still remains high. Understanding the natural history, determining the surgical approach, and knowing the radiosurgical results is important in selecting the ideal treatment modality for PCMs. In this context, we reviewed these issues, discussed the management and treated nine cases of PCM by retrosigmoid approach. The extent of resection and clinical results was satisfactory.

Materials and Methods

From July 2009 to July 2015, we treated nine cases of PCM by retrosigmoid approach. Of the nine patients, four were men and five women, aged 28–

**Neha Singh,
Deepak Kumar
Singh¹,
Faran Ahmad¹,
Rakesh Kumar¹**

*Departments of Radiodiagnosis
and ¹Neurosurgery,
Dr. Ram Manohar Lohia
Institute of Medical Sciences,
Lucknow, Uttar Pradesh, India*

Address for correspondence:

*Dr. Deepak Kumar Singh,
Department of Neurosurgery,
Dr. Ram Manohar Lohia
Institute of Medical Sciences,
Lucknow - 226 010,
Uttar Pradesh, India.
E-mail: gkp.deepak@gmail.com*

Access this article online

Website: www.asianjns.org

DOI: 10.4103/ajns.AJNS_192_18

Quick Response Code:



How to cite this article: Singh N, Singh DK, Ahmad F, Kumar R. The retrosigmoid approach: Workhorse for petroclival meningioma surgery. Asian J Neurosurg 2019;14:188-92.

This is an open access journal, and articles are distributed under the terms of the Creative Commons Attribution-NonCommercial-ShareAlike 4.0 License, which allows others to remix, tweak, and build upon the work non-commercially, as long as appropriate credit is given and the new creations are licensed under the identical terms.

For reprints contact: reprints@medknow.com

56 years (average 44.2 years). The course of the disease ranged from 1 to 24 months. Four of the patients had facial numbness, 7 had headache, 2 diplopia, 2 ataxia, 4 decreased hearing, 1 hemiparesis, 2 decreased gag reflexes, and 1 blurred vision with ptosis. Three patients presented with CN V deficit, 2 with CN VIII deficit, 1 with CN VI, 2 lower CN, 3 CN VII, and 1 CN II. Two patients showed ataxia and hemiparesis, and four patients had no deficits. Tumor size varied from 2 cm to 6.8 cm (average 3.8 cm) according to magnetic resonance imaging (MRI). The tumor extended to the upper and middle clivus in two patients, to the entire width of the clivus in one, and to the middle and lower clivus in six patients. The tumor infiltrated into the cavernous sinus in two patients [Table 1]. All patients were followed up from 7 to 60 months by radiological and neurological examinations.

Surgical technique

Variety of surgical approaches has been described to expose and remove the petroclival tumors depending on the location and epicenter of the tumor, direction of tumor extension and its size.

We selected the retrosigmoid approach for majority of the patients, as a safe alternative to lateral approaches. Combined with tentorial incision or suprameatal approach, it can be safely used for almost every PCM surgery. The lumbar drain was inserted preoperatively in all patients with large tumors (>3 cm). We practice to drain 30 ml of cerebrospinal fluid (CSF) before opening the dura in large tumors.

The patient is placed into the park bench position with the head slightly rotated to bring up the mastoid process on the affected side. Intraoperative facial and trigeminal nerve monitoring was done. Then, a standard retrosigmoid craniotomy is taken. The bone is exposed from the asterion superiorly to the foramen magnum inferiorly. The edges of the transverse, sigmoid sinuses and their junction are exposed widely after craniotomy. An incision is made in the dura with the edges being based on the transverse and sigmoid sinuses. With gentle retraction of the cerebellum from the petrous bone, the arachnoid of the cisterna magna is opened to allow the egress of CSF. Once the cerebellum is relaxed substantially, the attachment of the tumor and inferior surface of the tentorium is exposed. We try to preserve petrosal vein in every case.

In our experience, the 7th and 8th CNs complex is usually located downward and laterally. After identifying CN complex, the characteristics and attachment of the tumor are assessed. Tumor attachment at petrous bone was attacked first. We completely or partially cut-off its blood supply to reduce bleeding. Subsequently, tumor debulking was done through all available surgical corridors, carefully separating the tumor from the brainstem. Tumor dissection from the brain stem is the most important step. If tightly adherent, some tumor capsules may have to be left to prevent significant morbidity.

If part of the tumor invades into some part of middle fossa, the tentorium medial to CN V and superior to the petrous apex is opened as widely as possible. The tentorium is incised from the outside to the inside, beginning at 0.5 cm

Table 1: Tumor characteristics and postoperative outcome

Tumour size and extension	Preoperative symptoms	Excision ratio	Change in symptoms	Additional therapy
2 cm, confined to middle and lower clivus	Headache	Simpson Grade II excision	Improved	None
2.8 cm, confined to middle and lower clivus	Headache	Simpson Grade II excision	Improved	None
3 cm, confined to middle and lower clivus	Headache	Simpson Grade II excision	Improved	None
3.6 cm, confined to middle and lower clivus	Headache	Simpson Grade II excision	Improved	None
3.6 cm, confined to upper and middle clivus	Facial numbness	Simpson Grade II excision	Improved	None
4.0 cm, confined to middle and lower clivus	Facial numbness, decreased hearing	Simpson Grade II excision	Improved	None
4.0cm, Confined to middle and lower clivus	Headache, facial numbness, decreased hearing	Simpson Grade III excision	Improved	Adjuvant stereotactic radiosurgery
4.4 cm, confined to upper and middle clivus, middle fossa nad cavernous sinus invasion	Headache, decreased hearing, diplopia, ataxia, decreased gag reflex	Simpson Grade III excision	Worsening of lower CN paresis, Improved at 3 months follow up	Adjuvant stereotactic radiosurgery
6.8 cm, involved entire width of clivus, middle fossa and cavernous sinus invasion	Headache, facial nubmess, decreased hearing, diplopia, ataxia, decreased gag reflex, hemiparesis, blurred vision with ptosis	Simpson Grade III excision	Worsening of hemiparesis, improvement at 2 months follow up, patient leading independent life at 8 months follow up	Adjuvant stereotactic radiosurgery

CN – Cranial nerve

behind the petrous ridge to preserve the posterior roots of CN IV and CN V and to avoid injuring the superior petrosal sinus. If there are signs of tumor invasion, the tentorium is resected together with the tumor [Figures 1 and 2].

Results

All operations were performed in one stage. The tumors were pathologically graded according to the World Health Organization classification for all nine patients: eight cases were Grade I and one case was Grade II. Gross total resection (GTR) (Simpson Grade II) was achieved in 6 (66.7%) patients. This was confirmed by intraoperative view and postoperative MRI [Figures 3 and 4]. Subtotal resection (Simpson Grade III) was done in 3 (33.3%) cases. Anatomical preservation of CNs was achieved in all patients. Two (22%) patients had new neurological deficits or worsening of preexisting deficits. One developed hemiparesis and one have lower CN paresis. Both improved in the follow-up period. Improved performance Karnofsky Performance Scale was observed in all patients in follow-up period.

Adjuvant radiotherapy was given to patients with Simpson Grade III excision. No patient has tumor recurrence or progression so far.

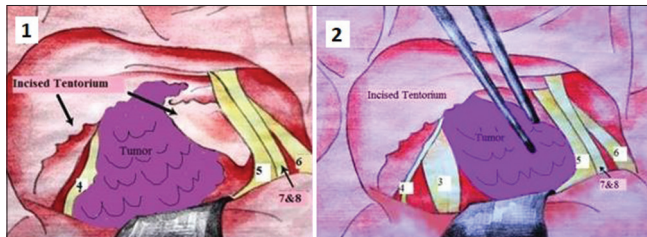


Figure 1: Pictorial representation of removal of middle cranial fossa extension of petroclival meningioma (1) Tentorial incision medial to 5th nerve (2) removal of tumor

Discussion

Different surgical approaches have been used to expose and remove the tumors according to the location of the epicenter of the tumor, direction of tumor extension, tumor size, patient age, medical comorbidity, and proposed radicality of resection. Personal experience, preferences, and the micro-neurosurgical technique can also affect the choice of surgical approach. A total of 17 cases of petroclival meningioma were operated at our center. Three of them were operated using presigmoid retrolabyrinthine approach and five were operated using combined transpetrosal approaches. A comparative evaluation of major approaches can be summarized in Table 2.

Although the combined transpetrosal approach provides a wider surgical field, it also has several disadvantages, including increased risk of postoperative CSF leakage, damage to the facial nerve and functional hearing, temporal lobe retraction, increased risk of injury to the vein of Labbé, and increased operative time. The retrosigmoid approach can provide equivalent working area and angles of attack for petroclival lesions compared with a combined transpetrosal approach.^[10] Furthermore, it has been shown that the retrosigmoid approach provides a significantly larger clival and brainstem working area than Kawase's approach.^[11] Although using cerebellar retraction is a potential risk factor for intraoperative edema and cerebellar infarction, we have never encountered any such problem so far. Our practice of putting preoperative lumbar drain and draining 30 ml of CSF before opening the dura significantly reduces the duration and intensity of required cerebellar retraction. A suprameatal extension increases the degree of surgical freedom at the trigeminal porus and Meckel's cave.^[11] The conventional retrosigmoid approach has been used for lesions with significant mass

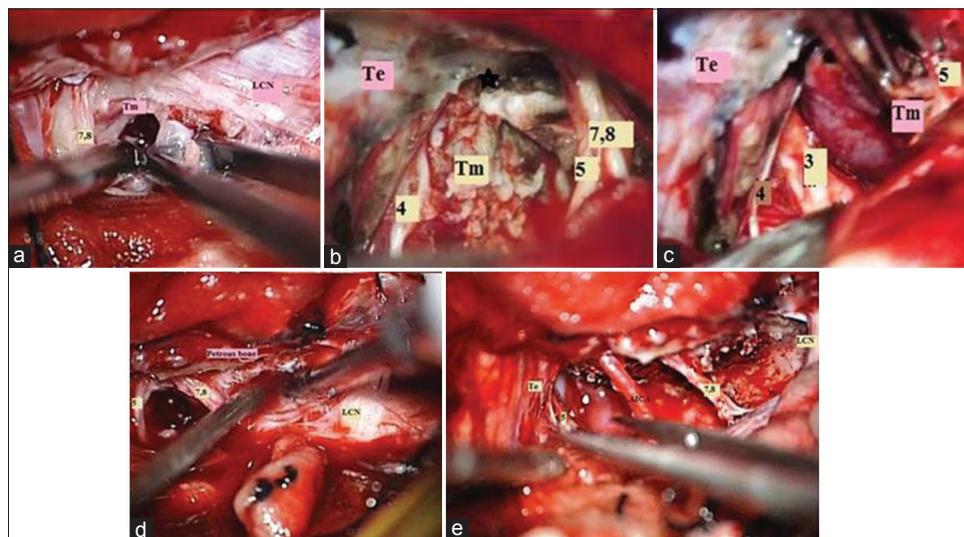


Figure 2: Surgical steps (a) Tumor decompression through neurovascular bundles (b and c) Upper pole dissection and removal of middle fossa extension through tentorial incision medial to 5th nerve (d) tumor dissection from petrous base (e) Final image after total tumor excision and coagulation of dural attachment at petrous bone. Tm – Tumor, Te – Tentorium

Table 2: A comparative evaluation of different surgical approaches to petroclival meningiomas

The presigmoid transpetrosal approach	Combined transpetrosal approach	Retrosigmoid+/suprameatal+/transtentorial approach
<p>Advantage: An extensive view of surgical field, short route lateral access, wide exposure of CNs and main arteries of posterior circulation and higher preservation chance of the vein of Labbe</p> <p>Disadvantage-Advanced anatomic knowledge and surgical training. Time-consuming, may cause more morbidities due to a large surgical wound</p>	<p>Advantage-much wider vision and shorter distance to access to the petroclival area, when they significantly grow equally into both the middle and posterior fossae</p> <p>Disadvantage-advanced anatomic knowledge and surgical training. Time-consuming, may cause more morbidities due to a large surgical wound, also increases a potential risk of injury to the vein of Labbe</p>	<p>Advantage-lesser morbidity, familiarity and less time consumption, abundant exposure of operative sight without more traction of cerebellum and venous sinuses. Can be combined with suprameatal drilling and tentorial cutting to gain extended exposure to the whole region of clivus from dorsum sellae to foramen magnum region and middle fossa</p> <p>Disadvantage: The tumor could not be resected just only by this approach when the main part of tumor located at middle cranial fossa, or invaded into cavernous sinus, especially invading the internal structures of cavernous sinus. The resection of tumor was mainly achieved through numerous neurovascular intervals; therefore the risk of iatrogenic injury of neurovascular structures was relative higher</p>

CN – Cranial nerve

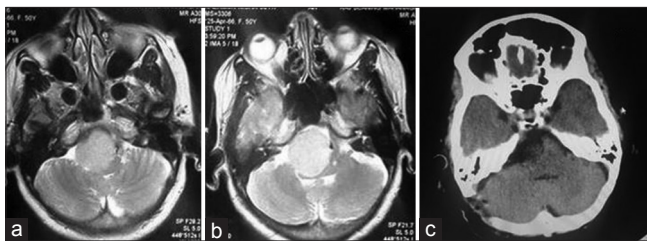


Figure 3: Petroclival meningioma with mid and lower clivus involvement (a and b) Preoperative Computed tomography image (c) postoperative Computed tomography image

in the posterior fossa and involving the cerebellopontine angle.^[7,12] A modified approach, retrosigmoid intradural suprameatal approach, includes a retrosigmoid craniotomy and intradural drilling of the bone located above and anterior to the internal auditory canal (IAC).^[13] The retrosigmoid intradural suprameatal approach is suitable for lesions mainly in the posterior middle fossa.^[13] However, it is difficult to remove lesions with a large extension in the middle fossa because this procedure makes the approach neither shallow nor broad. With time and experience, we have moved away from the aggressive combined transpetrosal approach toward a conventional retrosigmoid approach for the great majority of PCMs, particularly for lesions that extend lateral to the IAC or those without a significant supratentorial extension.^[14] With larger tumors, combined transpetrosal approaches remain an important tool.^[9,15] Our experience with these lesions suggests that majority of these lesions can be dealt with conventional retrosigmoid approach and its extensions.^[16] It must be remembered that many factors that prevent GTR are independent of the particular surgical approach chosen or even of the surgical skill or experience of the surgical team. These factors have been well described and include cavernous sinus invasion, brainstem pial invasion, neurovascular structures encasement, and firm tumor consistency. Factors such as tumor location in relation to the IAC, involvement of one or both cranial fossae, and preoperative hearing functional status are critical

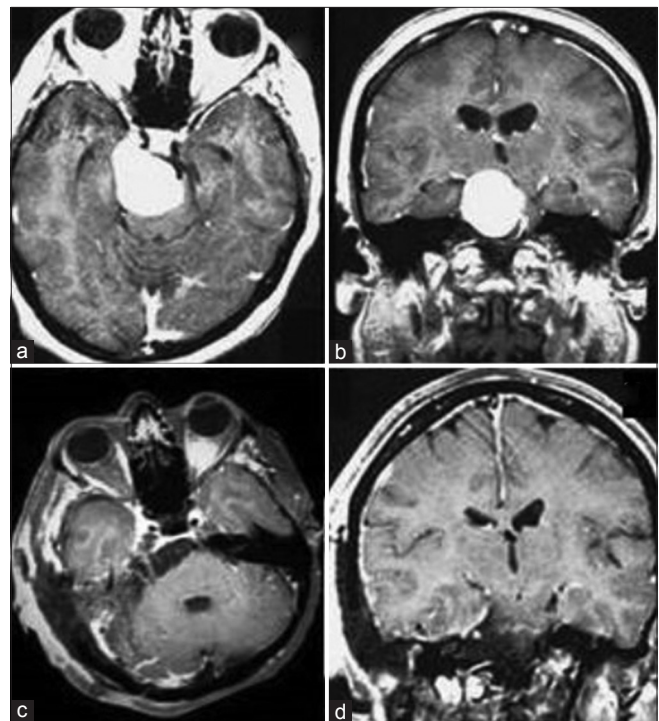


Figure 4: Petroclival meningioma involving upper and middle clivus with middle fossa extension (a and b) preoperative magnetic resonance imaging images (c and d) postoperative magnetic resonance imaging image showing complete excision

considerations in determining the optimal strategy for treating these challenging lesions.

Conclusions

The retrosigmoid approach for the treatment of the PCMs provides favorable outcomes of neurological function and quality of life when GTR is attempted. This approach serves the goal of a safe and uncomplicated, less invasive access to the petroclival region for resection of PCMs, especially when the tumor is located mainly in posterior fossa with limited extension into the supratentorial area and/or the middle fossa.

Financial support and sponsorship

Nil.

Conflicts of interest

There are no conflicts of interest.

References

1. Castellano F, Ruggiero G. Meningiomas of the posterior fossa. *Acta Radiol Suppl* 1953;104:1-77.
2. Martínez R, Vaquero J, Areitio E, Bravo G. Meningiomas of the posterior fossa. *Surg Neurol* 1983;19:237-43.
3. Nishimura S, Hakuba A, Jang BJ, Inoue Y. Clivus and apicopetroclivus meningiomas – Report of 24 cases. *Neurol Med Chir (Tokyo)* 1989;29:1004-11.
4. Al-Mefty O, Fox JL, Smith RR. Petrosal approach for petroclival meningiomas. *Neurosurgery* 1988;22:510-7.
5. Bricolo AP, Turazzi S, Talacchi A, Cristofori L. Microsurgical removal of petroclival meningiomas: A report of 33 patients. *Neurosurgery* 1992;31:813-28.
6. Couldwell WT, Fukushima T, Giannotta SL, Weiss MH. Petroclival meningiomas: Surgical experience in 109 cases. *J Neurosurg* 1996;84:20-8.
7. Samii M, Tatagiba M. Experience with 36 surgical cases of petroclival meningiomas. *Acta Neurochir (Wien)* 1992;118:27-32.
8. Seifert V, Raabe A, Zimmermann M. Conservative (labyrinth-preserving) transpetrosal approach to the clivus and petroclival region – Indications, complications, results and lessons learned. *Acta Neurochir (Wien)* 2003;145:631-42.
9. Sekhar LN, Wright DC, Richardson R, Monacci W. Petroclival and foramen magnum meningiomas: Surgical approaches and pitfalls. *J Neurooncol* 1996;29:249-59.
10. Siwanuwatn R, Deshmukh P, Figueiredo EG, Crawford NR, Spetzler RF, Preul MC, *et al.* Quantitative analysis of the working area and angle of attack for the retrosigmoid, combined petrosal, and transcochlear approaches to the petroclival region. *J Neurosurg* 2006;104:137-42.
11. Chang SW, Wu A, Gore P, Beres E, Porter RW, Preul MC, *et al.* Quantitative comparison of Kawase's approach versus the retrosigmoid approach: Implications for tumors involving both middle and posterior fossae. *Neurosurgery* 2009;64:44-51.
12. Samii M, Ammirati M, Mahrn A, Bini W, Sepehrnia A. Surgery of petroclival meningiomas: Report of 24 cases. *Neurosurgery* 1989;24:12-7.
13. Samii M, Tatagiba M, Carvalho GA. Retrosigmoid intradural suprameatal approach to Meckel's cave and the middle fossa: Surgical technique and outcome. *J Neurosurg* 2000;92:235-41.
14. Samii M, Gerganov V, Giordano M, Samii A. Two step approach for surgical removal of petroclival meningiomas with large supratentorial extension. *Neurosurg Rev* 2010;34:173-9.
15. Sekhar LN, Schessel DA, Bucur SD, Raso JL, Wright DC. Partial labyrinthectomy petrous apicectomy approach to neoplastic and vascular lesions of the petroclival area. *Neurosurgery* 1999;44:537-50.
16. Samii M, Tatagiba M, Carvalho GA. Resection of large petroclival meningiomas by the simple retrosigmoid route. *J Clin Neurosci* 1999;6:27-30.