

The diagnostic yield of neuroimaging in sixth nerve palsy - Sankara Nethralaya Abducens Palsy Study (SNAPS): Report 1

Akshay Gopinathan Nair, Selvakumar Ambika, Veena Olma Noronha¹, Rashmin Anilkumar Gandhi

Aims: The aim was to assess the etiology of sixth nerve palsy and on the basis of our data, to formulate a diagnostic algorithm for the management in sixth nerve palsy. **Design:** Retrospective chart review. **Results:** Of the 104 neurologically isolated cases, 9 cases were attributable to trauma, and 95 (86.36%) cases were classified as nontraumatic, neurologically isolated cases. Of the 95 nontraumatic, isolated cases of sixth nerve palsy, 52 cases were associated with vasculopathic risk factors, namely diabetes and hypertension and were classified as vasculopathic sixth nerve palsy (54.7%), and those with a history of sixth nerve palsy from birth (6 cases) were classified as congenital sixth nerve palsy (6.3%). Of the rest, neuroimaging alone yielded a cause in 18 of the 37 cases (48.64%). Of the other 19 cases where neuroimaging did not yield a cause, 6 cases were attributed to preceding history of infection (3 upper respiratory tract infection and 3 viral illnesses), 2 cases of sixth nerve palsy were found to be a false localizing sign in idiopathic intracranial hypertension and in 11 cases, the cause was undetermined. In these idiopathic cases of isolated sixth nerve palsy, neuroimaging yielded no positive findings. **Conclusions:** In the absence of risk factors, a suggestive history, or positive laboratory and clinical findings, neuroimaging can serve as a useful diagnostic tool in identifying the exact cause of sixth nerve palsy. Furthermore, we recommend an algorithm to assess the need for neuroimaging in sixth nerve palsy.

Key words: Abducens palsy, computed tomography, cranial nerve palsy, magnetic resonance imaging, mononeuropathy, neuroimaging, sixth nerve palsy

Sixth nerve palsy is a commonly encountered condition in many ophthalmic and neurological centers. One population-based study found the age-adjusted incidence of sixth nerve palsy to be 11.3/100 000 in a geographically defined population.^[1] Cranial nerve palsies are one of the most common indications for neuroimaging.^[2] The large population and limited radiological facilities in a developing country like India often necessitate long waiting periods before investigations are actually performed. While radiological investigations like magnetic resonance imaging (MRI) have been able to detect lesions and conditions that would have gone undetected earlier, imaging every patient of a cranial mononeuropathy, in this case sixth nerve palsy, may not be always be needed. There exist well-established guidelines for the imaging protocols in case of other nerve palsies such as third nerve palsy.^[2,3] However, while there have been attempts at framing similar guidelines regarding the timing and need for neuroimaging isolated sixth nerve palsy, the recommendations have differed.^[1,4-7] We designed this study to assess the etiology of sixth nerve palsy and on the basis of our data, to formulate a diagnostic algorithm

for the management in sixth nerve palsy. Furthermore, there has been no previous study to investigate the etiology of sixth nerve palsy from India.

Materials and Methods

The medical records of 110 consecutive patients of sixth nerve palsy who were examined at our tertiary eye care center, prior to December 2009 were studied. Each chart was studied in detail to ascertain the etiology of the sixth nerve palsy.

Furthermore, specific emphasis was laid on documenting the findings of neuroimaging studies: MRI and computed tomography (CT) in cases when the clinician specifically ordered it (e.g., trauma). In a few cases, the patient had previously been examined at other hospitals and subsequently referred to our hospital, and they had the records of neuroimaging studies with them. In some patients, neuroimaging was ordered after presentation at our hospital. In both the cases, the images were interpreted by a single neuro-radiologist. In the investigations recommended at our center, the use of intravenous Gadolinium as a contrast material was done in cases where the neuro-radiologist deemed necessary. The cause of sixth nerve palsy was divided primarily into traumatic and nontraumatic. Nontraumatic causes were further classified into congenital, inflammatory, tumor-related causes, vasculopathic, (secondary to microvascular ischemia due to diabetes mellitus (DM) or hypertension, or both) and idiopathic. Strict diagnostic criteria were used to assess the presence of diabetes or hypertension. DM was defined as present if subjects were taking insulin, oral hypoglycemic agents, or using diet and/or exercise to control elevated plasma glucose, or if elevated plasma glucose was documented within 1 month of the time of nerve palsy diagnosis. Elevated plasma glucose was defined as either a fasting plasma

This paper was awarded The 2011 S D Athawale Award for best paper in Neuro-Ophthalmology at the annual All India Ophthalmic Conference at Ahmedabad, India.

Department of Neuro-Ophthalmology, Sankara Nethralaya, A Unit of Medical Research Foundation, Nungambakkam, ¹VRR Scans, T-Nagar, Chennai, Tamil Nadu, India

Correspondence to: Dr. Akshay Gopinathan Nair, A Unit of Medical Research Foundation, Sankara Nethralaya, 18, College Road, Nungambakkam, Chennai - 600 006, Tamil Nadu, India. E-mail: akshaygn@gmail.com

Manuscript received: 06.07.14; **Revision accepted:** 23.09.14

Access this article online

Website:

www.ijo.in

DOI:

10.4103/0301-4738.146000

Quick Response Code:



glucose >126 mg/dl, symptoms of diabetes with a random plasma glucose >200 mg/dl, or plasma glucose >200 mg/dl at 2 h into an oral glucose tolerance test.^[8] Hypertension was defined as present if subjects were taking antihypertensive medications, or if blood pressure was elevated within 1 month of diagnosis of sixth nerve palsy. Elevated blood pressure was defined as systolic blood pressure >140 mmHg or diastolic blood pressure >90 mmHg on 2 occasions separated by at least 2 weeks.^[9] Multiple sclerosis (MS) was entered as a diagnosis only if criteria were met for a clinically definite or laboratory-supported diagnosis based on well-accepted published criteria.^[10] An independent intensivist made the diagnoses of systemic conditions.

Cases of sixth nerve palsy were also classified as isolated or nonisolated. The presence of any other neurological sign including other cranial neuropathies and bilateral sixth nerve palsies were considered as nonisolated cases.

Results

A total of 110 patients was enrolled in this study. Of these, 81 were male and 29 were female. The age ranged from 4 months to 71 years with a mean of 41.61 years. 59 of these cases had right-sided sixth nerve palsy, whereas 48 had left-sided disease. There were 3 patients who had bilateral disease. The distribution of the etiology of sixth nerve palsy is explained in Table 1.

Trauma

In our study, trauma accounted for 12 (10.90%) of the 110 cases of sixth nerve palsy. Of these, 3 cases were nonisolated sixth nerve palsies (involving other cranial nerves or bilateral disease).

Isolated versus nonisolated

A total of 104 cases was neurologically isolated, and only 6 cases were not neurologically isolated.

Nontraumatic, neurologically isolated

Of the 104 neurologically isolated cases, 9 cases were attributable to trauma, and 95 (86.36%) cases were classified as nontraumatic, neurologically isolated cases. Of the 95 nontraumatic, isolated cases of sixth nerve palsy, 52 cases were associated with vasculopathic risk factors, namely diabetes and hypertension and were classified as vasculopathic sixth nerve palsy (54.7%), and those with a history of sixth nerve palsy from birth (6 cases) were classified as congenital sixth nerve palsy (6.3%). Of the rest, neuroimaging alone yielded a cause in 18 of the 37 cases (48.64%). The etiology of sixth nerve palsy in these 18 cases were as follows: 3 vascular causes (aneurysm-related), 6 cases were tumor-related and 9 cases were inflammatory in origin: (4-Tolosa-Hunt syndrome, 3 patients had lesions which were investigated and found to be tubercular in origin, one patient was diagnosed with MS and one patient had a pseudotumor which responded to oral corticosteroids) [Table 2]. Of the other 19 cases where neuroimaging did not yield a cause, 6 cases were attributed to preceding history of infection (3 upper respiratory tract infection and 3 viral illnesses), 2 cases of sixth nerve palsy were found to be a false localizing sign in idiopathic intracranial hypertension and in 11 cases, the cause was undetermined. In these idiopathic cases of isolated sixth nerve palsy, neuroimaging yielded no positive findings.

Discussion

Broadly, the causes for sixth nerve palsy have been studied before, namely in the population-based study by Patel *et al.*, where the leading cause was undetermined (26%), hypertension alone (19%), co-existent hypertension and diabetes (12%), trauma (12%), MS (7%), neoplasm (5%), diabetes alone (4%).^[1] In contrast, our study revealed a different picture, with co-existent hypertension and DM accounting for 25.5% of cases followed by undetermined causes (16.4%), DM 17 (15.4%) and hypertension alone being the cause of sixth nerve palsy only in 8.2% of the causes.

One plausible reason for diabetes being associated with a larger percentage of isolated sixth nerve palsy could be due to the higher incidence of type II diabetes in India (our study population) when compared to the United States (the population studied by Patel *et al.*): 14.3% versus 8.2%.^[11,12]

Regarding the role of neuroimaging in sixth nerve, a prospective study by Bendszus *et al.* have stated that in nontraumatic, neurologically isolated cases of acute sixth nerve palsy, a lesion was identified on the initial MRI relevant to the sixth nerve palsy in 63% of patients.^[5] Of these patients in whom lesions were identified, 21 cases (49%) were found to have a tumor or the tumor-like lesion and the frequency of presumed vasculopathy in this group was 15%. In our study, 6 patients were found to have tumors, of which only one patient was hypertensive. That particular patient was a 54-year-old diabetic, hypertensive male on treatment, who presented with a 6-month-old history of left-sided VI nerve palsy. Axial T2-weighted

Table 1: The distribution of the etiology of sixth nerve palsy

Etiology	Percentage
DM+hypertension*	25.5
DM*	17
Undetermined	16.4
Inflammatory	10.5
Hypertension*	8.2
Trauma	8
Tumor	5.5
Congenital	5.5

*Vasculopathic, DM: Diabetes mellitus

Table 2: The causes of isolated, non-traumatic sixth nerve palsy not classified as ischemic or congenital

Cause	Numbers
Undetermined	11
Inflammatory	9
Tumor	6
Presumed viral	6
Vascular	3
IIH	2

Inflammatory, tumour related and vascular causes (aneurysms) were diagnosed on neuro-imaging; where as sixth nerve palsy of presumed viral origin and those attributable to IIH were diagnosed clinically with no positive findings on imaging. Those without positive clinical or radiological findings were classified as undetermined. IIH: Idiopathic intracranial hypertension

image [Fig. 1, left] and coronal T2-weighted fast relaxation fast spin echo image [Fig. 1, right] showing a large fairly well-circumscribed lobulated heterogenous mass in the left cavernous sinus, displaying a heterogenous hyperintense signal. The patient was referred to a neuro-oncologist and underwent neurosurgery. Given that he first presented to us with a 6-month-old history of sixth nerve palsy, it is unlikely that any examining physician would have deferred neuroimaging. In the study of Bendszus *et al.*, the population in whom the initial MRI demonstrated a causative lesion had a mean age of 43 years.^[5] It is understandable that a younger age group is more likely to show a causative lesion on neuroimaging since vasculopathic risk factors are, usually, not present at that age.

Further, in addition to stating that causative lesions may have been overlooked and misdiagnosed as vasculopathic or idiopathic, Bendszus *et al.* have also put forth another possible reason for a higher positivity rate being the fact that the patients in their study underwent high resolution MRI to identify small lesions which might have been overlooked on CT or standard MRI.^[5]

With regard to neoplasm as the cause of isolated, nontraumatic, sixth nerve palsy, our study showed previously undiagnosed tumor, primary or metastatic; to be the causative lesion in 6.31% (6 out of 95). Bendszus *et al.* found a high proportion of cases (60.4%) to be caused by tumors, tumor like lesions (21) and metastases (5).^[5] However, it is not clear if the sixth nerve palsy was the presenting sign of a previously undiagnosed tumor or if the tumor had already been diagnosed and the palsy was a sign of progression of the tumor growth.

On the contrary, Patel *et al.* have reported that they did not find a single case of sixth nerve palsy where a previously undiagnosed tumor was the causative lesion.^[1] It is difficult to explain such vast variations in the incidence of tumor-related isolated abducens palsy.

Multiple sclerosis was the cause of isolated nontraumatic sixth nerve palsy in only 1 (2.7%) patient in our study. Peters *et al.*, in their report have showed MS to cause 24% of isolated

sixth nerve palsy.^[13] It must be mentioned that their study included only patients below the age of 50. However, given the age at which MS, usually, presents, it is likely that the number of sixth nerve palsies resulting from MS would stand largely unchanged. The incidence of MS in India is known to be lesser than the west, and this could be extrapolated to explain the low association of MS with sixth nerve palsy among Indians.^[14]

Patel *et al.* state that if sixth nerve palsy is not accompanied by other neurologic signs (excluded by a comprehensive neurologic examination), and no historical features suggest an etiology, it is reasonable to defer imaging while continuing to observe the patient monthly.^[1] They believe this would reduce patient medical expenses. While they also mention that they expect the major objection to not performing neuroimaging on presentation, in cases of isolated sixth nerve palsy is missing the diagnosis of an intracranial neoplasm. They further mention that in the rare case of intracranial neoplasm in which isolated sixth nerve palsy was the presenting sign; it is unlikely that prognosis would be sufficiently altered by delaying the diagnosis for 2-3 months to allow observation for progression or resolution of the sixth nerve palsy. In our study, however, as mentioned above, we found 6 cases out of the total of 95 isolated, nontraumatic sixth nerve palsies, to have a previously undiagnosed malignancy as the underlying cause. This included a 51-year-old female with no vasculopathic risk factors and a history of acute sixth nerve palsy. MRI of the brain showed a lytic lesion in the basi-sphenoid. On further evaluation, the patient was found to have a follicular carcinoma of the thyroid gland, which had metastasized to the basi-sphenoid presenting as sixth nerve palsy. The patient was referred to an oncologist and was subsequently lost to follow-up.

Warwar *et al.* have reported a case where a 68-year-old diabetic, hypertensive man presented with a left sixth cranial nerve palsy.^[15] As he had ample risk factors for an ischemic cause, brain imaging was deferred. He subsequently developed ipsilateral third cranial nerve palsy, and while undergoing medical stabilization, the patient had hyperthermia and died. On autopsy, the presumed cause of death was pituitary apoplexy and compression of the hypothalamus. Rare cases like this may indicate while neuroimaging should not be deferred. And if deferred, the patient must be made aware of the need for a close follow-up.

Bendszus *et al.* believe that MRI should be performed routinely in all cases with an acute sixth nerve palsy, even those with evidence of a vasculopathy.^[5,16] They found a causative lesion in 15% of vasculopathic patients. They believe this high proportion of severe and potentially treatable lesions justifies early MRI in patients with a vasculopathy.^[16] Similarly, Tamhankar *et al.*, in their study, found that in the group of patients who had vasculopathic risk factors only, with no other significant medical condition, 10% of patients were found to have other causes, including midbrain infarction, neoplasms, inflammation, pituitary apoplexy, and giant cell arteritis. Their recommendation, is that brain MRI and laboratory workup have a role in the initial evaluation of older patients with isolated acute ocular motor nerve palsies regardless of whether vascular risk factors are present.^[17]

In our study, of the nontraumatic neurologically isolated patients, only one patient with vasculopathic risk factors had a positive finding on MRI. The only case was a 58-year-old male with a history of systemic hypertension who

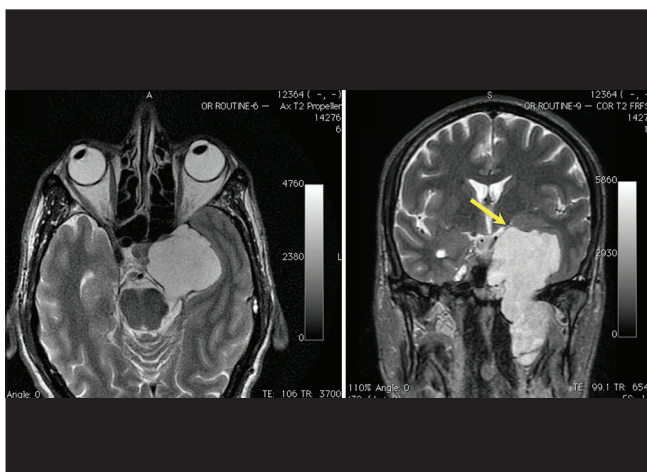


Figure 1: Axial T2-weighted image (Figure 1, left) and coronal T2-weighted fast relaxation fast spin-echo image (Figure 1, right) showing a large fairly well-circumscribed lobulated heterogenous mass in the left cavernous sinus, displaying a heterogenous hyperintense signal

presented with acute left-sided sixth nerve palsy. MRI brain showed an ill-defined lesion of the sphenoid sinus extending to the cavernous sinus. The patient refused interventional diagnosis in the form of biopsy or lumbar puncture and on further investigations, he was found to have a tubercular focus in the lungs. Both the orbital and the pulmonary lesions responded to the antitubercular treatment.

Conversely, Miller *et al.* in their study, state no lesion was identified on MRI in patients with a history of vasculopathy.^[6] Of the 53 patients with vasculopathic risk factors in our study, 29 underwent neuroimaging (18 had an MRI done, 8 had undergone CT, and 3 patients underwent both CT and MRI). Of these, only 2 patients showed a lesion causing sixth nerve palsy (7%), which meant that 93% of patients with vasculopathic risk factors had normal MRIs.

Conclusion

In the absence of risk factors, a suggestive history, or positive laboratory and clinical findings, neuroimaging can serve as a useful diagnostic tool in identifying the exact cause of sixth nerve palsy.

We disagree with the protocols suggested by Patel *et al.*^[1] We believe that by delaying an MRI in an isolated nontraumatic sixth nerve palsy, the risk of not diagnosing an intracranial

tumor certainly exists. With reference to the recommendations of Bendszus *et al.*, we believe that there is not enough evidence to support the recommendations.^[5,16] Neuroimaging for all patients presenting with a sixth nerve palsy is a costly management practice, as pointed out by Chi and Bhatti^[4,8] and Murchison *et al.*,^[7] also routinely performed MRI in every patient with sixth nerve palsy in a developing country may not always be feasible and financially viable.^[4] We largely favor the algorithms recommended by Miller *et al.* and Murchison *et al.*^[6,7]

The decision of whether to image or not in a case of nontraumatic, isolated acute sixth nerve palsy lies largely with the examining clinician and must be taken on a case to case basis depending on the index of suspicion. On the basis of our study, we propose the following recommendations [Fig. 2]: Patients above the age of 50, with the presence of vasculopathic risk factors or MS, may be treated conservatively with management focusing on the underlying systemic condition; however, these patients in our opinion need to be monitored weekly and depending on the recovery, the next step may be taken. Worsening, nonimprovement for a period of 3 months or greater and progressive involvement of other cranial nerves needs urgent neuroimaging. Furthermore, in patients >50 years of age, isolated sixth nerve palsy in the absence of vasculopathic risk factors requires neuroimaging. In patients below 50 presenting with isolated nontraumatic acute sixth nerve palsy,

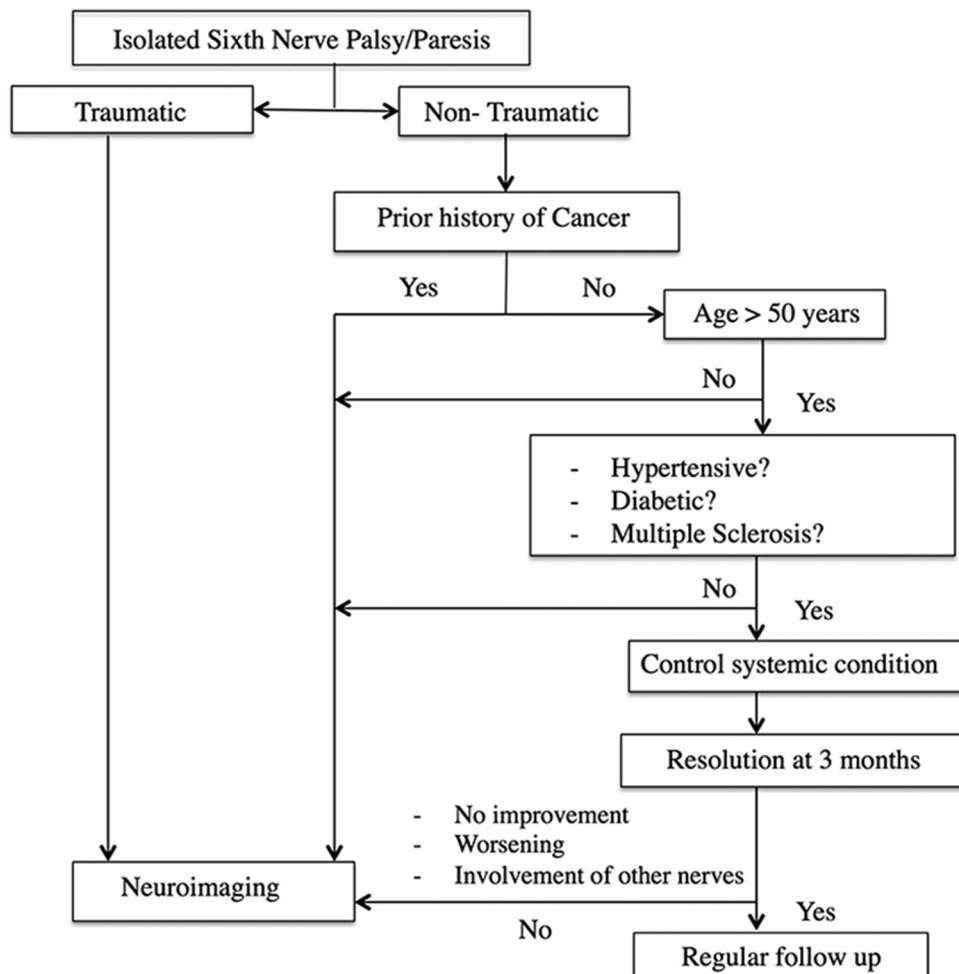


Figure 2: A proposed algorithm for clinical evaluation and neuroimaging of a case of acquired, isolated sixth nerve palsy

we believe neuroimaging on presentation is warranted. Any history of a malignancy in the past or at presentation is a case of immediate neuroimaging.

However, given the varying incidence of vasculopathic and tumor-related causes of sixth nerve palsy in India and in the above quoted studies, larger, prospective, cross-sectional studies to study the role of neuroimaging in acute sixth nerve palsy are warranted. It would also be of interest to investigate the role of other risk factors such as hyperlipidemia and hypercholesterolemia.

Acknowledgment

The authors would like to acknowledge the assistance provided by Sumedh S Hoskote, MD, Critical Care Medicine; Mayo Clinic, Rochester, MN, USA and Veena R Iyer, MD, Department of Radiodiagnosis, University of Minnesota, MN, USA.

References

- Patel SV, Mutyala S, Leske DA, Hodge DO, Holmes JM. Incidence, associations, and evaluation of sixth nerve palsy using a population-based method. *Ophthalmology* 2004;111:369-75.
- Lee AG, Brazis PW, Garrity JA, White M. Imaging for neuro-ophthalmic and orbital disease. *Am J Ophthalmol* 2004;138:852-62.
- Bose S. Neuroimaging in neuroophthalmology. *Neurosurg Focus* 2007;23:E9.
- Chi SL, Bhatti MT. The diagnostic dilemma of neuro-imaging in acute isolated sixth nerve palsy. *Curr Opin Ophthalmol* 2009;20:423-9.
- Bendszus M, Beck A, Koltzenburg M, Vince GH, Brechtelsbauer D, Littan T, *et al.* MRI in isolated sixth nerve palsies. *Neuroradiology* 2001;43:742-5.
- Miller RW, Lee AG, Schiffman JS, Prager TC, Garza R, Jenkins PF, *et al.* A practice pathway for the initial diagnostic evaluation of isolated sixth cranial nerve palsies. *Med Decis Making* 1999;19:42-8.
- Murchison AP, Gilbert ME, Savino PJ. Neuroimaging and acute ocular motor mononeuropathies: A prospective study. *Arch Ophthalmol* 2011;129:301-5.
- Report of the Expert Committee on the Diagnosis and Classification of Diabetes Mellitus. *Diabetes Care* 1997;20:1183-97.
- The sixth report of the Joint National Committee on prevention, detection, evaluation, and treatment of high blood pressure. *Arch Intern Med* 1997;157:2413-46.
- Poser CM, Paty DW, Scheinberg L, McDonald WI, Davis FA, Ebers GC, *et al.* New diagnostic criteria for multiple sclerosis: Guidelines for research protocols. *Ann Neurol* 1983;13:227-31.
- Mohan V, Sandeep S, Deepa R, Shah B, Varghese C. Epidemiology of type 2 diabetes: Indian scenario. *Indian J Med Res* 2007;125:217-30.
- Wild S, Roglic G, Green A, Sicree R, King H. Global prevalence of diabetes: Estimates for the year 2000 and projections for 2030. *Diabetes Care* 2004;27:1047-53.
- Peters GB 3rd, Bakri SJ, Krohel GB. Cause and prognosis of nontraumatic sixth nerve palsies in young adults. *Ophthalmology* 2002;109:1925-8.
- Bansil S, Singhal BS, Ahuja GK, Ladiwala U, Behari M, Friede R, *et al.* Comparison between multiple sclerosis in India and the United States: A case-control study. *Neurology* 1996;46:385-7.
- Warwar RE, Bhullar SS, Pelstring RJ, Fadell RJ. Sudden death from pituitary apoplexy in a patient presenting with an isolated sixth cranial nerve palsy. *J Neuroophthalmol* 2006;26:95-7.
- Bendszus M. When to use MRI in isolated palsies of the sixth cranial nerve? *Neuroradiology* 2002;44:713-4.
- Tamhankar MA, Biousse V, Ying GS, Prasad S, Subramanian PS, Lee MS, *et al.* Isolated third, fourth, and sixth cranial nerve palsies from presumed microvascular versus other causes: A prospective study. *Ophthalmology* 2013;120:2264-9.

Cite this article as: Nair AG, Ambika S, Noronha VO, Gandhi RA. The diagnostic yield of neuroimaging in sixth nerve palsy - Sankara Nethralaya Abducens Palsy Study (SNAPS): Report 1. *Indian J Ophthalmol* 2014;62:1008-12.

Source of Support: Nil, **Conflict of Interest:** None declared.