

Treatment of Parotid Non-Hodgkin Lymphoma: A Meta-Analysis

abstract

Purpose This meta-analysis aimed to review the published outcomes of parotid non-Hodgkin lymphoma (NHL) pertaining to different treatment modalities.

Materials and Methods A total of 48 journal articles published between 1993 and 2015, comprising 742 cases of parotid NHL, were initially evaluated. In total, 108 patients from 12 studies who had sufficient data for analysis, including age, tumor histopathology, treatment modality, and outcome at final follow-up, were included. Patients were randomly assigned to different categories on the basis of histopathology and treatment modality. Groups were compared using Kaplan-Meier survival curve analysis and the Mann-Whitney *U* test.

Results Log-rank tests demonstrated that for early-stage (I and II) parotid NHL of all histopathology variants, radiation therapy significantly improved the survival rate versus chemotherapy ($P = .043$), as well as combined treatment with chemotherapy and radiation therapy ($P = .023$). For early-stage diffuse large B-cell lymphoma, combined treatment significantly improved survival versus single treatment ($P = .028$). No treatment was received by seven patients with early-stage mucosa-associated lymphoid tissue lymphoma after undergoing parotidectomy. When the clinical outcomes of these patients were compared with those of other patients with the same histology who underwent further treatment, no significant differences were noted in survival outcomes.

Conclusion Radiation therapy seems to be a valid treatment of early-stage parotid NHL. However, for diffuse large B-cell lymphoma, survival was higher with combined treatment versus single treatment. For early-stage parotid mucosa-associated lymphoid tissue lymphoma, complete excision of the tumor through superficial parotidectomy may have similar survival outcome.

J Glob Oncol 00. © 2017 by American Society of Clinical Oncology Licensed under the Creative Commons Attribution 4.0 License

INTRODUCTION

The head and neck region is a common site for extranodal non-Hodgkin lymphoma (NHL). The prevalence of extranodal NHL is most common in the GI tract, whereas the head and neck region serves as the second most frequent anatomic site of extranodal lymphomas.^{1,2} The salivary glands serve as the site for nearly 12% of extranodal lymphomas of the head and neck region, which accounts for 2% to 5% of salivary gland neoplasms. Parotid glands serve as the most common site for salivary gland lymphomas, whereas nearly 20% of salivary gland lymphomas infect the submandibular and minor salivary glands.¹⁻⁵ Mucosa-associated lymphoid tissue (MALT) lymphomas are regarded as the most common histologic type of lymphomas affecting the salivary glands. Moreover, follicular lymphoma and diffuse large B-cell lymphoma (DLBCL) are also included among common histologic forms

of lymphoma, which most often target the salivary glands.³⁻⁵

In the case of malignant lymphoma, chemotherapy and/or radiation therapy are performed; however, the selection of treatment modalities is entirely on the basis of parameters including the histologic subtype and stage of lymphoma. The diagnosis of parotid malignant lymphoma is performed by the surgeon, who either obtains a tissue sample through fine-needle aspiration or open surgical biopsy. In the majority of parotid lymphomas cases, patients experience a painless mass resembling benign parotid tumors. For this reason, excisional parotidectomy is recommended for patients with suspected parotid lymphoma, and the diagnosis is entirely on the basis of outcomes of the excisional parotidectomy. This meta-analysis aimed to analyze the literature illustrating the outcomes of parotid NHL treatment and compared the outcomes using different treatment modalities for parotid lymphoma.

Basem Jamal

Author affiliations and support information (if applicable) appear at the end of this article.

Corresponding author: Basem Jamal, DSc, Dept of Oral and Maxillofacial Surgery, King Abdulaziz University, University Road, PO Box 80209, Jeddah 21589, Makkah, Saudi Arabia; Twitter: @BasemJamal; e-mail: bjamal@kau.edu.sa.

Table 1. Summary of Studies Included in the Current Meta-Analysis

First Author	Publication Year	Years Studied	No. of Patients Included	Reported Ages in Years (range)	Treatment Modality
Mada et al ⁶	2015	2004-2014	4	62, 67, 47, 75	RT
Shum et al ⁷	2014	—	3	53, 53, 63	RT/CH
Wyss et al ⁸	2012	1992-2008	21	Mean 66 (28-93)	Surgery/RT/CH
Dizpenza et al ⁹	2011	1988-2008	8	Mean 60 (45-80)	Surgery plus CH/RT
Alvarez-Buylla Blanco et al ¹⁰	2010	1996-2003	7	Mean 74 (52-85)	Surgery/CH with or without RT
Kolokotronis et al ¹¹	2005	1998-2002	4	Mean 64 (27-84)	Surgery/CH
MacDermid et al ¹²	2004	1969-2002	16	Median 56 (26-83)	All
Dunn et al ⁴	2004	1990-2001	6	Median 61 (27-86)	All
Wenzel et al ¹³	2003	1995-2002	14	Median 54 (31-82)	All
von Stritzky et al ¹⁴	1998	1985-1995	5	Mean 70 (51-92)	All
Hirokawa et al ¹⁵	1998	1985-1995	5	Mean 55.4 (44-74)	RT with or without CH
Mehle et al ¹⁶	1993	1973-1988	16	Mean 61.4	All

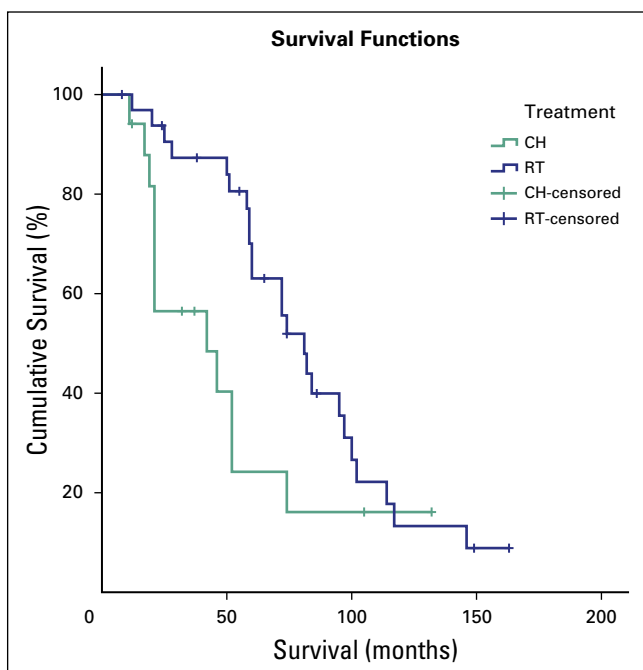
Abbreviations: CH, chemotherapy; RT, radiotherapy.

MATERIALS AND METHODS

Review Context

A literature review related to diversified treatment procedures for parotid NHL was initiated by searching globally conducted studies, to acquire insight to treatment procedures used for parotid NHL from a broader perspective.

Fig 1. Log-rank test showing survival for early stage (I and II) parotid non-Hodgkin lymphoma comparing radiation therapy (RT) with chemotherapy (CH).



Inclusion and Exclusion Criteria

Studies published between 1993 and 2015 that included three or more patients were included in this meta-analysis. Moreover, studies providing sufficient patient-related data, including age, tumor histopathology, treatment modality, and outcome at final follow-up were considered appropriate for inclusion. Studies reporting single cases were excluded. If multiple research articles were published by a single institution and all of them focused on the same patient population, the most recently conducted studies were included in this meta-analysis to avoid redundancy.

Search Strategy

The literature was searched systematically for studies that were conducted to analyze treatment strategies for parotid NHL. The most relevant articles for this meta-analysis were searched for using terms such as "parotid non-Hodgkin's lymphoma," "parotid lymphoma," and "treatment modalities." These search terms were separated by using the Boolean operators "OR" and "AND."

The Medline database was used to search for relevant articles. This database was selected because it can provide access to updated literature on the effectiveness of diversified treatment strategies for parotid NHL. A total of 48 journal articles were retrieved from the Medline database.

These retrieved articles comprised approximately 742 cases of parotid NHL. An initial screening of these articles was conducted. Among the retrieved articles, studies that did not provide data regarding the involvement of submandibular or parotid gland tumors were excluded, with the exception of studies highlighting > 85% of the sample population affected with parotid NHL.

After the screening process, 108 patients with parotid NHL from 12 studies were found to be eligible for this study. The studies included in this meta-analysis are listed in Table 1. Patients were further categorized into different groups, on the basis of treatment modalities and histopathology. Clinical outcomes and effectiveness of treatment strategies were compared by using statistical tools, including the Mann-Whitney *U* test and Kaplan-Meier survival curve. For this meta-analysis, test results with a *P* value < .05 were considered as significant.

RESULTS

Of the 48 retrieved journal articles,¹⁻⁴⁸ 12^{4,6-16} were considered to be eligible. These 12 articles met the inclusion criteria and provided sufficient data in 108 patients. Approximately 58% of the participants included in this meta-analysis were female and between 31 and 38 years of age (median age, 59 years). A wide majority of participants included in this study presented with

the initial stages of parotid NHL (stage I and II), whereas 23% of participants were diagnosed as having stage III and IV NHL.

The most common histology was MALT lymphoma (48 patients), followed by follicular lymphoma (33 patients). DLBCL was diagnosed in 20 patients, and seven patients were diagnosed as having other less common histology types. Approximately 64% of patients underwent a parotidectomy procedure rather than open surgical biopsy for diagnosis. Nearly one-third of the patients were treated using either chemotherapy or radiation therapy, and 27% received combined chemoradiation therapy. The remaining 12% of patients received neither chemotherapy nor radiation therapy.

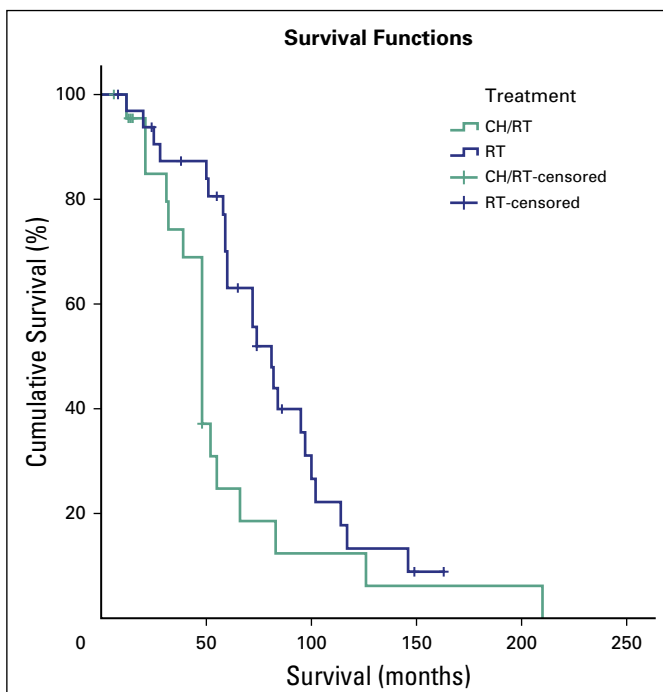
Outcomes of log-rank tests revealed that for early-stage parotid NHL (stage I and II) of all histopathology variants, radiation therapy alone significantly improved the survival rate compared with chemotherapy (*P* = .043; Fig 1). Radiation therapy also significantly improved the survival rate compared with combined treatment with chemotherapy and radiation therapy (*P* = .023; Fig 2).

For the DLBCL variant, combined treatment significantly improved the survival rate compared with single treatment (*P* = .028; Fig 3). Among the evaluated participants, seven patients with early-stage MALT lymphoma did not receive any treatment after undergoing parotidectomy. When the clinical outcomes of these patients were compared with those of patients who had similar histology and had received further treatment, no significant difference was noted in the survival outcome.

DISCUSSION

MALT lymphoma of salivary glands has a high recurrence rate and aggressive behavior during an indolent clinical course. The recurrence rate of MALT lymphoma of salivary glands is higher than that of MALT lymphoma of the thyroid and stomach. The 10-year recurrence-free rate of MALT lymphoma of salivary glands is 68%, whereas the 10-year recurrence-free rate of MALT lymphoma of the thyroid and stomach was reported to be 95% and 92%, respectively. Extragastric lymphomas are reported to be more aggressive. The risk for recurrence of head and neck MALT lymphomas is further enhanced when only local therapies are applied for treatment.^{13,36}

Fig 2. Log-rank test showing survival for early-stage (I and II) parotid non-Hodgkin lymphoma comparing radiation therapy (RT) with combined treatment with chemotherapy (CT) and RT.



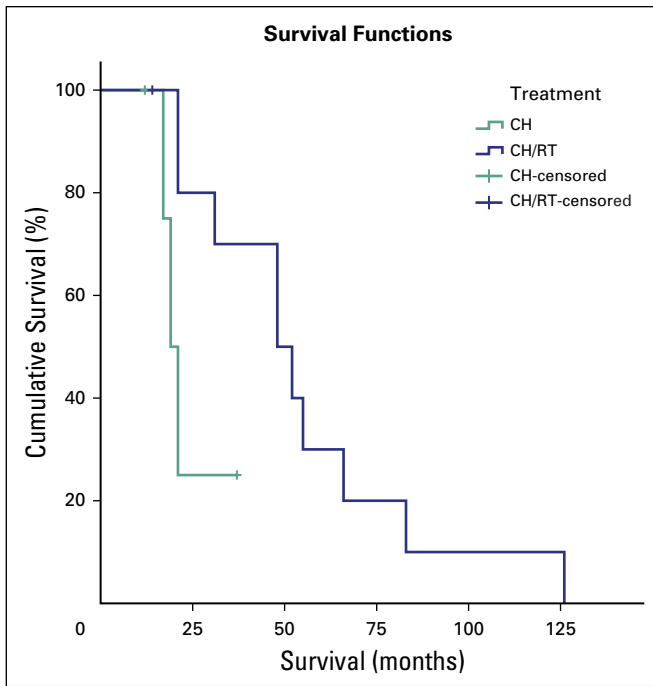


Fig 3. Log-rank test showing survival for diffuse large B-cell lymphoma comparing chemotherapy (CH) to combined CH and radiation therapy (RT).

Parotid lymphomas are considered to be more aggressive than MALT lymphomas, whereas parotid lymphomas are more likely to be of low grade. Patients suspected of having parotid lymphoma demonstrate better prognosis compared with patients suspected of having other types of extranodal lymphomas.^{37,38}

Olivier et al³⁹ conducted a randomized controlled trial consisting of patients with stage I and II parotid NHL, who were categorized into intervention and control groups. The intervention group was treated with radiation therapy, whereas the control group received treatment other than radiation therapy. Patients with parotid NHL who were treated with radiation therapy demonstrated significant improvement in clinical outcomes in terms of local control. On the other hand, there was no significant improvement in overall survival or disease-specific survival between the groups after 10 years of follow up. The current study revealed improved survival rates for patients

in the initial stages of parotid NHL, who were treated with radiation therapy, compared with patients receiving either chemotherapy or combined treatment.

A study conducted by Tiplady et al⁴⁰ acquired data from the Scotland and New Castle Lymphoma Group registry. Their findings revealed that patients with stage I low-grade diseases (follicular lymphoma and MALT lymphoma) did not experience different clinical outcomes. Patients included in the study were treated using different modalities, whereas some of the patients included in the current study were treated by surgical procedures. However, considering the outcomes of this meta-analysis, seven patients with early-stage MALT lymphoma received no further treatment other than parotidectomy. However, there was no difference in the survival rate of these patients compared with that of patients with a similar histology who received further treatment.

Feinstein et al⁴¹ conducted an analysis of 2,140 patients with parotid lymphoma. Data were acquired from the SEER database, and the findings revealed that patients who were treated with surgical procedures were at a 35% reduced risk of mortality compared with patients who underwent other treatment procedures.

The findings of this meta-analysis revealed that parotid lymphomas behave differently than lymphomas in other organs.⁴²⁻⁴⁶

In conclusion, the findings of this meta-analysis suggest that radiation therapy is a valid treatment of early-stage parotid NHL, with the exception of the DLBCL variant. Combined treatment significantly improved survival compared with single treatment. For the early-stage parotid MALT lymphoma variant, complete excision of the tumor via superficial parotidectomy may have a similar survival outcome.

DOI: <https://doi.org/10.1200/JGO.17.00071>

Published online on jgo.org on November 16, 2017.

AUTHOR'S DISCLOSURES OF
POTENTIAL CONFLICTS OF INTEREST

The following represents disclosure information provided by authors of this manuscript. All relationships are considered compensated. Relationships are self-held unless noted. I = Immediate Family Member, Inst = My Institution.

Relationships may not relate to the subject matter of this manuscript. For more information about ASCO's conflict of interest policy, please refer to www.asco.org/rwc or ascopubs.org/jco/site/ifo.

Basem Jamal

No relationship to disclose

Affiliation

Basem Jamal, King Abdulaziz University, Jeddah, Makkah, Saudi Arabia.

REFERENCES

1. Hart S, Horsman JM, Radstone CR, et al: Localised extranodal lymphoma of the head and neck: The Sheffield Lymphoma Group experience (1971-2000). *Clin Oncol (R Coll Radiol)* 16:186-192, 2004
2. Vega F, Lin P, Medeiros LJ: Extranodal lymphomas of the head and neck. *Ann Diagn Pathol* 9:340-350, 2005
3. Wolvius EB, van der Valk P, van der Wal JE, et al: Primary non-Hodgkin's lymphoma of the salivary glands. An analysis of 22 cases. *J Oral Pathol Med* 25:177-181, 1996
4. Dunn P, Kuo TT, Shih LY, et al: Primary salivary gland lymphoma: A clinicopathologic study of 23 cases in Taiwan. *Acta Haematol* 112:203-208, 2004
5. Weber AL, Rahemtullah A, Ferry JA: Hodgkin and non-Hodgkin lymphoma of the head and neck: Clinical, pathologic, and imaging evaluation. *Neuroimaging Clin N Am* 13:371-392, 2003
6. Mada Y, Koshitsuka K, Ihara F, et al: A clinical study of a mucosa-associated lymphoid tissue (MALT) lymphoma of salivary glands [in Japanese]. *Nihon Jibiinkoka Gakkai Kaiho* 118:25-33, 2015
7. Shum JW, Emmerling M, Lubek JE, et al: Parotid lymphoma: A review of clinical presentation and management. *Oral Surg Oral Med Oral Pathol Oral Radiol* 118:e1-e5, 2014
8. Wyss E, Mueller-Garamvölgyi E, Ghadjar P, et al: Diagnosis and treatment outcomes for patients with lymphoma of the parotid gland. *Laryngoscope* 123:662-669, 2013
9. Dispenza F, Cicero G, Mortellaro G, et al: Primary non-Hodgkins lymphoma of the parotid gland. *Rev Bras Otorrinolaringol (Engl Ed)* 77:639-644, 2011
10. Alvarez-Buylla Blanco M, Martínez Moran A, Vázquez Barro JC, et al: Primary non-Hodgkin lymphoma of the parotid gland: Revision of 8 cases [in Spanish]. *Acta Otorrinolaringol Esp* 61:371-374, 2010
11. Kolokotronis A, Konstantinou N, Christakis I, et al: Localized B-cell non-Hodgkin's lymphoma of oral cavity and maxillofacial region: A clinical study. *Oral Surg Oral Med Oral Pathol Oral Radiol Endod* 99:303-310, 2005
12. MacDermid D, Thurber L, George TI, et al: Extranodal nonorbital indolent lymphomas of the head and neck: Relationship between tumor control and radiotherapy. *Int J Radiat Oncol Biol Phys* 59:788-795, 2004
13. Wenzel C, Fiebigler W, Dieckmann K, et al: Extranodal marginal zone B-cell lymphoma of mucosa-associated lymphoid tissue of the head and neck area: High rate of disease recurrence following local therapy. *Cancer* 97:2236-2241, 2003
14. von Stritzky M, Wereldsma JJC, Pegels JG: Parotid mass as first symptom of a malignant lymphoma. *J Surg Oncol* 67:25-27, 1998
15. Hirokawa N, Hareyama M, Akiba H, et al: Diagnosis and treatment of malignant lymphoma of the parotid gland. *Jpn J Clin Oncol* 28:245-249, 1998
16. Mehle ME, Kraus DH, Wood BG, et al: Lymphoma of the parotid gland. *Laryngoscope* 103:17-21, 1993
17. Etemad-Moghadam S, Tirgary F, Keshavarz S, et al: Head and neck non-Hodgkin's lymphoma: A 20-year demographic study of 381 cases. *Int J Oral Maxillofac Surg* 39:869-872, 2010
18. Fujimura K, Yoshida M, Sugimoto T, et al: Two cases of non-Hodgkin's lymphoma in the accessory parotid gland. *Auris Nasus Larynx* 31:195-198, 2004
19. Iguchi H, Wada T, Matsushita N, et al: Anatomic distribution of hematolymphoid malignancies in the head and neck: 7 years of experience with 122 patients in a single institution. *Acta Otolaryngol* 132:1224-1231, 2012
20. Jaehne M, Ussmüller J, Jäkel KT, et al: The clinical presentation of non-Hodgkin lymphomas of the major salivary glands. *Acta Otolaryngol* 121:647-651, 2001
21. Kojima M, Shimizu K, Nishikawa M, et al: Primary salivary gland lymphoma among Japanese: A clinicopathological study of 30 cases. *Leuk Lymphoma* 48:1793-1798, 2007

22. Konofaos P, Spartalis E, Katsaronis P, et al: Primary parotid gland lymphoma: A case report. *J Med Case Reports* 5:380, 2011
23. Loggins JP, Urquhart A: Preoperative distinction of parotid lymphomas. *J Am Coll Surg* 199:58-61, 2004
24. Mian M, Capello D, Ventre MB, et al: Early-stage diffuse large B cell lymphoma of the head and neck: Clinico-biological characterization and 18 year follow-up of 488 patients (IELSG 23 study). *Ann Hematol* 93:221-231, 2014
25. Nakamura S, Ichimura K, Sato Y, et al: Follicular lymphoma frequently originates in the salivary gland. *Pathol Int* 56:576-583, 2006
26. Nathu RM, Mendenhall NP, Almasri NM, et al: Non-Hodgkin's lymphoma of the head and neck: A 30-year experience at the University of Florida. *Head Neck* 21:247-254, 1999
27. Paliga A, Farmer J, Bence-Bruckler I, et al: Salivary gland lymphoproliferative disorders: A Canadian tertiary center experience. *Head Neck Pathol* 7:381-388, 2013
28. Passali V, D'Ascanio GF, Olivieri D: Primary lymphoma of the parotid gland [in Italian]. *Minerva Stomatol* 43:145-153, 1994
29. Picard A, Cardinne C, Denoux Y, et al: Extranodal lymphoma of the head and neck: A 67-case series. *Eur Ann Otorhinolaryngol Head Neck Dis* 132:71-75, 2015
30. Sarris AH, Papadimitrakopoulou V, Dimopoulos MA, et al: Primary parotid lymphoma: The effect of International Prognostic Index on outcome. *Leuk Lymphoma* 26:49-56, 1997
31. Setoyama T, Natsugoe S, Okumura H, et al: α -catenin is a significant prognostic factor than E-cadherin in esophageal squamous cell carcinoma. *J Surg Oncol* 95:148-155, 2007
32. Suh C, Huh J, Roh JL: Extranodal marginal zone B-cell lymphoma of mucosa-associated lymphoid tissue arising in the extracranial head and neck region: A high rate of dissemination and disease recurrence. *Oral Oncol* 44:949-955, 2008
33. Triantafyllidou K, Dimitrakopoulos J, Iordanidis F, et al: Extranodal non-Hodgkin lymphomas of the oral cavity and maxillofacial region: A clinical study of 58 cases and review of the literature. *J Oral Maxillofac Surg* 70:2776-2785, 2012
34. Wierzbicka M, Bartochowska A, Kopeć T, et al: MALT-type parotid lymphoma—A case report and the review of the literature [in Polish]. *Otolaryngol Pol* 67:61-65, 2013
35. Zapater E, Bagán JV, Carbonell F, et al: Malignant lymphoma of the head and neck. *Oral Dis* 16:119-128, 2010
36. Zinzani PL, Magagnoli M, Ascani S, et al: Nongastrointestinal mucosa-associated lymphoid tissue (MALT) lymphomas: Clinical and therapeutic features of 24 localized patients. *Ann Oncol* 8:883-886, 1997
37. Jacobs C, Hoppe RT: Non-Hodgkin's lymphomas of head and neck extranodal sites. *Int J Radiat Oncol Biol Phys* 11:357-364, 1985
38. Freeman C, Berg JW, Cutler SJ: Occurrence and prognosis of extranodal lymphomas. *Cancer* 29:252-260, 1972
39. Olivier KR, Brown PD, Stafford SL, et al: Efficacy and treatment-related toxicity of radiotherapy for early-stage primary non-Hodgkin lymphoma of the parotid gland. *Int J Radiat Oncol Biol Phys* 60:1510-1514, 2004
40. Tiplady CW, Taylor PRA, White J, et al: Lymphoma presenting as a parotid tumour: A population-based study of diagnosis, treatment and outcome on behalf of the Scotland and Newcastle Lymphoma Group. *Clin Oncol (R Coll Radiol)* 16:414-419, 2004
41. Feinstein AJ, Ciarleglio MM, Cong X, et al: Parotid gland lymphoma: Prognostic analysis of 2140 patients. *Laryngoscope* 123:1199-1203, 2013
42. Ambrosetti A, Zanotti R, Pattaro C, et al: Most cases of primary salivary mucosa-associated lymphoid tissue lymphoma are associated either with Sjogren syndrome or hepatitis C virus infection. *Br J Haematol* 126:43-49, 2004
43. Avilés A, Delgado S, Huerta-Guzmán J: Marginal zone B cell lymphoma of the parotid glands: Results of a randomised trial comparing radiotherapy to combined therapy. *Eur J Cancer B Oral Oncol* 32B:420-422, 1996
44. Barnes L, Myers EN, Prokopakis EP: Primary malignant lymphoma of the parotid gland. *Arch Otolaryngol Head Neck Surg* 124:573-577, 1998
45. Chi HS, Lee KW, Chiang FY, et al: Head and neck extranodal lymphoma in a single institute: A 17-year retrospective analysis. *Kaohsiung J Med Sci* 28:435-441, 2012
46. Crampsey DP, Savage SA, McKay P, et al: Parotid lymphoma in west Scotland: Two-year 'snapshot' of diagnosis, management and core issues. *J Laryngol Otol* 123:1237-1241, 2009
47. Stein ME, Brunnel A, Lewis D, et al: Primary malignant lymphoma of the parotid gland report of three cases. *Tumori* 87:346-348, 2001
48. Morinière S, Périé S, Lacau St Guily J: Primary and non-primary parotid malignancies: Comparison of treatment modalities and outcomes. *Eur Arch Otorhinolaryngol* 264:1231-1237, 2007