

Quantitative Computed Tomographic Volumetry after Treatment of a Giant Intracranial Aneurysm with a Pipeline Embolization Device

Woong Jae Lee¹, Jun Soo Byun¹, Jae Kyun Kim¹, and Taek Kyun Nam²

Departments of ¹Radiology and ²Neurosurgery, Chung-Ang University Hospital, Seoul, Korea.

Recently developed flow diverters, such as the pipeline embolization device (PED), allow for safe and efficacious treatment of giant intracranial aneurysms, with high occlusion rates and a low incidence of complications. However, incomplete obliteration after PED treatment may lead to aneurysm regrowth and delayed rupture. Herein, we report a case of a partially thrombosed giant aneurysm of the cavernous internal carotid artery that showed progressive recanalization at 1–3 months after application of a PED. We monitored inflow volume in the aneurysm by computed tomographic angiography (CTA) and computed tomographic volumetric imaging (CTVI). Based on the imaging results, rather than applying additional PED, we decided to make the switch from a dual antiplatelet medication to low-dose aspirin alone at 3 months after the treatment; complete obliteration of the aneurysm was noted at 21 months. Similar to the findings in this unusual case, CTA and CTVI may be useful follow-up methods for optimal management of patients with giant intracranial aneurysms after PED treatment.

Key Words: Intracranial aneurysm, therapeutic embolization, medical device, computed tomography, angiography

INTRODUCTION

Recently developed flow diverters, such as the pipeline embolization device (PED), allow for safe and efficacious treatment of giant aneurysms, with high occlusion and relatively low complication rates.^{1,2} Incomplete obliteration of giant aneurysms after PED treatment may lead to delayed aneurysm rupture; hence, monitoring of inflow volume by follow-up imaging is important. Herein, we describe a partially thrombosed giant aneurysm of the cavernous internal carotid artery (ICA) that showed dynamic inflow volume change after application

of a single PED and discuss the possible causes and clinical significance of early recanalization of giant aneurysms after successful PED treatment.

CASE REPORT

A 62-year-old woman with headache after a head contusion was referred to our hospital. Brain computed tomographic angiography (CTA), magnetic resonance imaging (MRI), and digital subtraction angiography (DSA) revealed a partially thrombosed giant aneurysm (maximum diameter, 33 mm) in the right cavernous ICA (Fig. 1A, B, and C). The patient had no neurologic symptoms associated with the aneurysm. The patient was premedicated with aspirin (100 mg once daily) and clopidogrel (75 mg once daily) for 3 weeks prior to treatment. Platelet inhibition tests demonstrated acceptable responses to aspirin and clopidogrel. She was treated by using a 4×25 mm PED (Covidien, Irvine, CA, USA) that spanned the ICA terminus, crossed the aneurysm neck, and terminated at the horizontal cavernous ICA. Completion DSA revealed disrupted flow into the aneurysm, with redirection of the primary inflow jet axis toward the posteroinferior aspect of the aneurysm sac

Received: August 25, 2016 **Revised:** October 8, 2016

Accepted: November 10, 2016

Corresponding author: Dr. Jun Soo Byun, Department of Radiology, Chung-Ang University Hospital, 102 Heukseok-ro, Dongjak-gu, Seoul 06973, Korea.
Tel: 82-2-6299-3194, Fax: 82-2-6263-1557, E-mail: flightdr61@cau.ac.kr

Conference presentation:
Thirteenth Congress of the World Federation of Interventional & Therapeutic Neuro-radiology (WFITN), 2015, Gold Coast, Australia.

•The authors have no financial conflicts of interest.

© Copyright: Yonsei University College of Medicine 2017

This is an Open Access article distributed under the terms of the Creative Commons Attribution Non-Commercial License (<http://creativecommons.org/licenses/by-nc/4.0>) which permits unrestricted non-commercial use, distribution, and reproduction in any medium, provided the original work is properly cited.

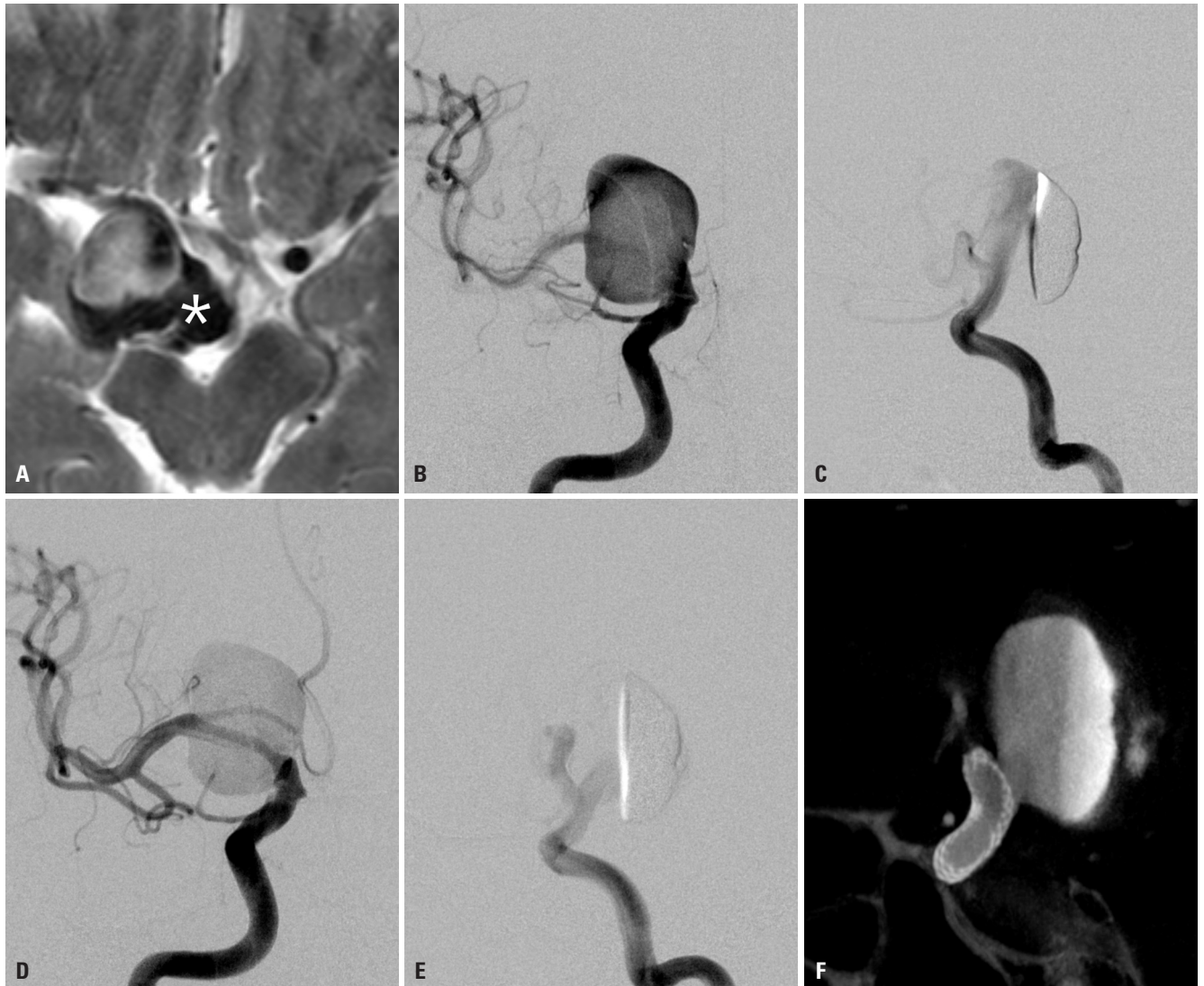

Fig. 1. Images of the partially thrombosed aneurysm pre- and post-stenting. (A) Initial T2-weighted magnetic resonance imaging shows a partially thrombosed (asterisk) giant aneurysm in the cavernous segment of the right internal carotid artery. (B and C) Preoperative digital subtraction angiography reveals a giant aneurysm with the inflow jet axis oriented posterosuperiorly toward the aneurysm dome on the sagittal plane. (D and E) Post-treatment completion angiography shows significantly decreased inflow to the aneurysm sac with redirection of the initial inflow jet axis toward the posteroinferior aspect on the sagittal plane. (F) DynaCT identifies the optimal stent position across the aneurysm neck.

(Fig. 1D and E). Immediate DynaCT confirmed optimal stent positioning across the aneurysm neck (Fig. 1F). The patient has consented to the submission of this case report for publication.

We assessed the patient's condition using CTA and computed tomographic volumetric imaging (CTVI) after PED treatment. Conventional brain CTA was performed using a 256-slice multiple detector computed tomography (CT) scanner (Brilliance iCT; Philips Healthcare, Cleveland, OH, USA). The scanning parameters were as follows: 120 kVp, 140 mAs, 0.9-mm slice thickness with 0.45-mm overlaps, 0.33 second rotation time, 22-cm field of view, and a 512×512 pixel matrix. Volumetric images were reconstructed in a multimodality workstation (Extended Brilliance Workspace; Philips Healthcare) using semi-automated methods and the tissue segmentation tool as follows: 1) set the CT number to the volume of interest at a level

of 1160 Hounsfield unit (HU) and a width of 2048 HU; 2) initially select the candidate region including the contrast-filled portions of the aneurysm, adjacent vessels, and the PED; 3) manually isolate and remove adjacent vessels on a section-by-section basis to refine the aneurysm; and 4) automatically calculate the volume of the contrast-filled portion of the aneurysm.

The preoperative inflow volume of the aneurysm was 3883.8 mm³ (except the thrombosed portion, 100%). Progressive thrombosis was observed at 1 week after PED treatment: the inflow volume was 756.6 mm³ (19.5%), but increased thereafter, 1385.4 mm³ (35.7%) at 1 month, and 1565.7 mm³ (40.3%) at 3 months (Fig. 2). CTA did not detect any stent foreshortening or endoleaks. Because the patient's antiplatelet status presumably accounted partly for the reduced thrombosis and rather than applying additional PED, we switched from a dual anti-

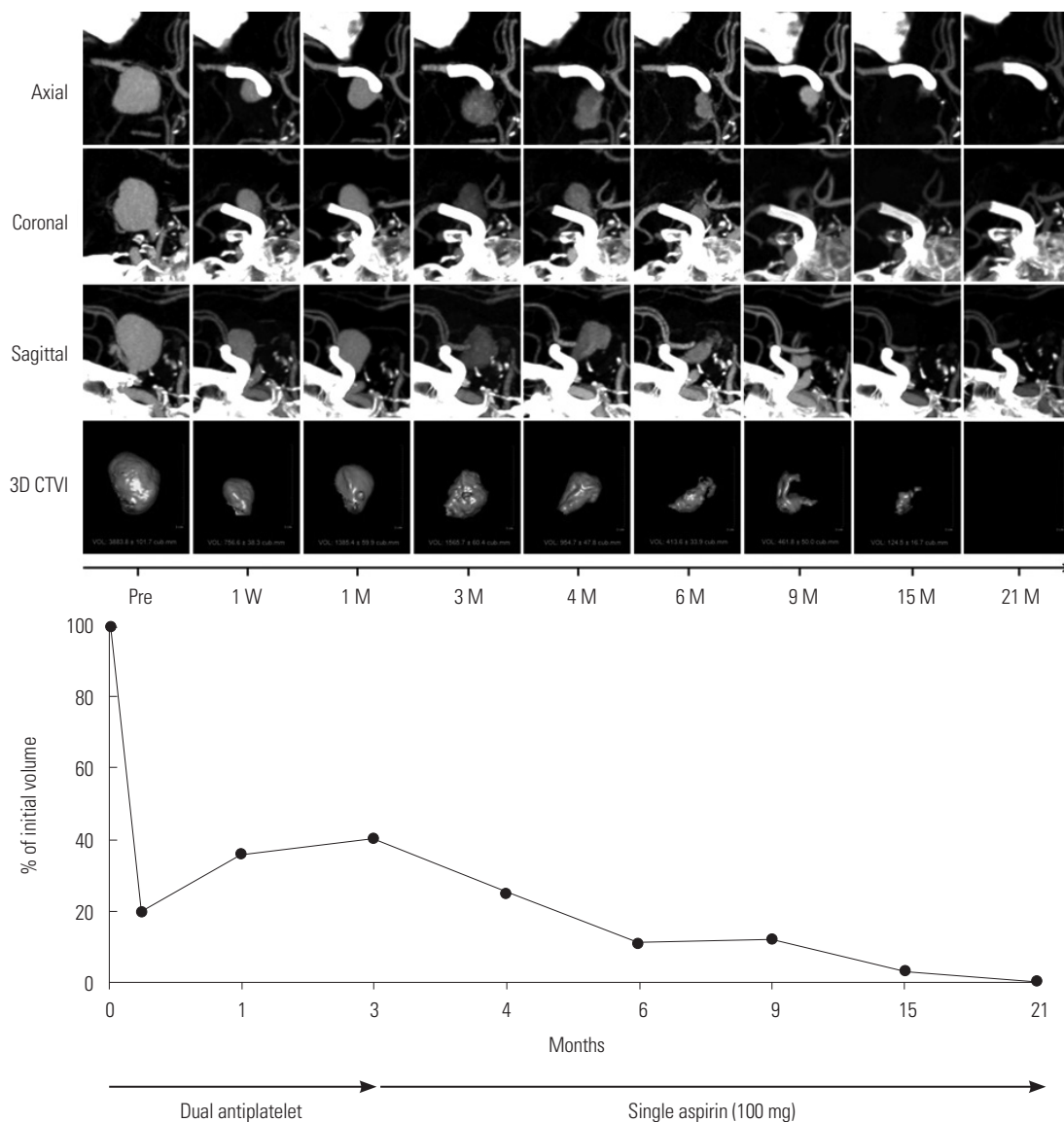


Fig. 2. Serial computed tomographic angiography and computed tomographic volumetric images of a giant aneurysm treated by applying a single pipeline embolization device. The results show a decrease in the inflow volume 1 week after treatment (756.6 mm³, 19.5% of the initial volume) followed by an increase at 1 (1385.4 mm³, 35.7%) and 3 (1565.7 mm³, 40.3%) months. After replacing the antiplatelet with low-dose aspirin alone, the inflow volume decreased to 954.7 mm³ (24.6%) at 4 months, and only a small remnant (124.5 mm³, 3.2%) was detected at 15 months. Inflow into the aneurysm disappeared completely at 21 months. Note the posteroinferior redirection of the aneurysm axis during obliteration on the sagittal images. CTVI, computed tomographic volumetric image.

platelet medication to low-dose aspirin alone. The inflow volume steadily decreased to 954.7 mm³ (24.6%) at 4 months and 413.6 mm³ (10.6%) at 6 months. Based on the results of sequential CTA and CTVI, we again decided not to apply additional PED; instead, we continued to follow up the patient. The inflow volume further decreased at 15 months (124.5 mm³, 3.2%), and complete obliteration was achieved at 21 months. The patient had no neurological events during the follow-up period.

DISCUSSION

Flow diverters reduce the extent of hemodynamic exchange

between an aneurysm and parent artery, which promotes thrombosis within the aneurysm sac, and provide a framework for neointimization of the aneurysm neck.³ Immediate aneurysm exclusion is not expected; complete exclusion requires time. A recent review reported complete occlusion rates of 80% for small aneurysms, 74% for large aneurysms, and 76% for giant aneurysms 6 months after PED treatment.²

Progressive aneurysm recanalization in partially thrombosed giant intracranial aneurysms after successful PED treatment is rare. Causes of intra-aneurysmal thrombus formation include reduced inflow velocity, reduced vorticity, and increased turnover time.⁴ Dual antiplatelet therapy (aspirin and clopidogrel) synergistically inhibits platelet aggregation, in-

stent thrombus formation within stents,⁵ and together with other events, thrombus formation within the aneurysm sac. Low-dose aspirin alone has modest effects, compared with aspirin plus clopidogrel.

Progressive recanalization may also result from immature thrombus formation following PED deployment. Unlike a thrombus after PED, a spontaneous thrombus in a giant aneurysm is regarded as a mural hematoma, owing to the nature of its formation.^{6,7} Factors contributing to spontaneous thrombus formation and growth include wall dissections, intramural hemorrhages, and intra-thrombotic vascular channels.⁶ Martin, et al.⁷ found that mural thrombus had relatively constant MRI features (T1 high and T2 low signal intensities) over a long period and, hence, suggested that mature thrombi are either relatively static or at equilibrium. In the present case, a preexisting mural thrombus showed T1 high and T2 low signal intensities on pretreatment MRI and may be a mature, rather than a fresh mural thrombus. Serial CTA revealed that recanalization occurred in the newly formed fresh thrombus, separate from the mural thrombus, and progressed toward the posteroinferior portion of the aneurysm sac, similar to the flow redirection (initially posterosuperior) observed on completion DSA. We speculate that recanalization resulted from both the antiplatelet status caused by the dual antiplatelet medication and the immature thrombus with inflow redirection.

The potential association between progressive recanalization and delayed aneurysm rupture is concerning. The incidence of rupture is higher in giant than in small or large aneurysms, and most ruptures occur within 1 month of PED treatment.⁸ Causes of delayed aneurysm rupture include wall shear stress at the aneurysm dome, unfavorable hemodynamic status, and autolysis of the aneurysm wall by thrombosis-induced proteases.⁹⁻¹¹ Although yet to be established, we believe that progressive recanalization with redirected inflow may be a risk factor for rupture and a signal for further intervention.

Because DSA detects contrast flow in the partially thrombosed aneurysm, it likely underestimates the inflow volume after PED deployment, owing to contrast stasis and turbulent flow within the sac. Thus, CTA and magnetic resonance angiography are superior to DSA for evaluating inflow volume after PED treatment.^{7,12} CTVI provides quantitative volume in cubic millimeters and may have less inter-observer variation. Radiation exposure during CTA is concerning. In our case, the mean dose-length product of each CTA was 1269.2 mGy-cm, and the calculated total patient effective radiation dose was 24.0 mSv for 21 months (16.7 mSv for 1 year), which may be

reasonable¹³ given the potential risk of delayed aneurysm rupture.

REFERENCES

1. Becske T, Kallmes DF, Saatci I, McDougall CG, Szikora I, Lanzino G, et al. Pipeline for uncoilable or failed aneurysms: results from a multicenter clinical trial. *Radiology* 2013;267:858-68.
2. Brinjikji W, Murad MH, Lanzino G, Cloft HJ, Kallmes DF. Endovascular treatment of intracranial aneurysms with flow diverters: a meta-analysis. *Stroke* 2013;44:442-7.
3. Kallmes DF, Ding YH, Dai D, Kadirvel R, Lewis DA, Cloft HJ. A new endoluminal, flow-disrupting device for treatment of saccular aneurysms. *Stroke* 2007;38:2346-52.
4. Lieber BB, Stancampiano AP, Wakhloo AK. Alteration of hemodynamics in aneurysm models by stenting: influence of stent porosity. *Ann Biomed Eng* 1997;25:460-9.
5. Makkar RR, Eigler NL, Kaul S, Frimerman A, Nakamura M, Shah PK, et al. Effects of clopidogrel, aspirin and combined therapy in a porcine ex vivo model of high-shear induced stent thrombosis. *Eur Heart J* 1998;19:1538-46.
6. Krings T, Alvarez H, Reinacher P, Ozanne A, Baccin CE, Gandolfo C, et al. Growth and rupture mechanism of partially thrombosed aneurysms. *Interv Neuroradiol* 2007;13:117-26.
7. Martin AJ, Hetsch SW, Dillon WP, Higashida RT, Halbach V, Dowd CF, et al. MR imaging of partially thrombosed cerebral aneurysms: characteristics and evolution. *AJNR Am J Neuroradiol* 2011;32:346-51.
8. Rouchaud A, Brinjikji W, Lanzino G, Cloft HJ, Kadirvel R, Kallmes DF. Delayed hemorrhagic complications after flow diversion for intracranial aneurysms: a literature overview. *Neuroradiology* 2016;58:171-7.
9. Hampton T, Walsh D, Tolia C, Fiorella D. Mural destabilization after aneurysm treatment with a flow-diverting device: a report of two cases. *J Neurointerv Surg* 2011;3:167-71.
10. Ikeda H, Ishii A, Kikuchi T, Ando M, Chihara H, Arai D, et al. Delayed aneurysm rupture due to residual blood flow at the inflow zone of the intracranial paraclinoid internal carotid aneurysm treated with the Pipeline embolization device: histopathological investigation. *Interv Neuroradiol* 2015;21:674-83.
11. Siddiqui AH, Kan P, Abila AA, Hopkins LN, Levy EI. Complications after treatment with pipeline embolization for giant distal intracranial aneurysms with or without coil embolization. *Neurosurgery* 2012;71:E509-13.
12. Carneiro A, Rane N, Küker W, Cellerini M, Corkill R, Byrne JV. Volume changes of extremely large and giant intracranial aneurysms after treatment with flow diverter stents. *Neuroradiology* 2014;56:51-8.
13. National Research Council, Division on Earth and Life Studies, Board on Radiation Effects Research, Committee to Assess Health Risks from Exposure to Low Levels of Ionizing Radiation. *Health Risks from Exposure to Low Levels of Ionizing Radiation: BEIR VII Phase 2*. Washington, DC: National Academies Press; 2006.