

Case report

# Endogenous *Brucella* endophthalmitis: A case report



Merih Oray<sup>a,\*</sup>; Zafer Cebeci<sup>a</sup>; Nur Kir<sup>a</sup>; Banu Turgut Ozturk<sup>b</sup>; Lutfiye Oksuz<sup>c</sup>; Ilknur Tugal-Tutkun<sup>a</sup>

## Abstract

Brucellosis may be associated with a wide range of ophthalmic manifestations including endophthalmitis, which is a sight-threatening condition that needs to be rapidly recognized and treated to avoid permanent visual loss. A 26-year-old female with a 6-month history of vision loss in the left eye was treated with high dose systemic corticosteroids and azathioprine with an initial misdiagnosis elsewhere. A dense vitreous haze with opacities at the posterior hyaloid and a wide area of retinochoroiditis led to the diagnosis of endogenous endophthalmitis at presentation to us. The vitreous sample and blood cultures demonstrated growth of *Brucella melitensis*. She received 6 months of systemic antibiotherapy, which resulted in resolution of inflammation; however, visual acuity remained poor due to irreversible damage. Infectious etiology, including brucellosis in endemic countries, has to be considered in the differential diagnosis before administering immunomodulatory therapy in patients with panuveitis of unknown origin.

**Keywords:** Endogenous endophthalmitis, Ocular brucellosis, Panuveitis

© 2017 The Authors. Production and hosting by Elsevier B.V. on behalf of Saudi Ophthalmological Society, King Saud University. This is an open access article under the CC BY-NC-ND license (<http://creativecommons.org/licenses/by-nc-nd/4.0/>). <http://dx.doi.org/10.1016/j.sjopt.2017.03.002>

## Introduction

Brucellosis (Malta fever) is a zoonotic systemic disease caused by *Brucella melitensis* or *Brucella abortus*. Humans usually get infected through ingestion of infected raw milk, dairy products, or raw meat.<sup>1</sup> Although the incidence of brucellosis has declined, it still remains as an important health problem in endemic areas such as the Middle East, the Mediterranean, and Asia.<sup>1</sup>

Brucellosis is a multisystem disease that may present with a broad spectrum of clinical manifestations.<sup>1</sup> It may be associated with a wide range of ophthalmic manifestations such as dacryoadenitis, conjunctivitis, episcleritis, nummular keratitis, anterior or posterior uveitis, endophthalmitis, exudative retinal detachment, multifocal choroiditis, optic neuritis, and ocular muscle paresis.<sup>2–7</sup>

We herein present an unusual case of endogenous endophthalmitis due to *B. melitensis*.

## Case report

A 26-year-old female was referred with a 6-month history of vision loss in the left eye along with an initial complaint of weight loss and fatigue. Based on reports of ocular examination elsewhere, initial visual acuity was 20/20 OD and 20/30 OS. Biomicroscopic examination revealed fine keratic precipitates, 2 + cells in both anterior chamber and vitreous in the left eye. There was optic disc hyperemia, periphlebitis, and retinal infiltrates scattered in the superior and nasal quadrants of the left eye (Fig. 1). There was no ocular pathology in the right eye. Extensive laboratory workup regarding infectious (syphilis, toxoplasmosis, tuberculosis, hepatitis A, hepatitis

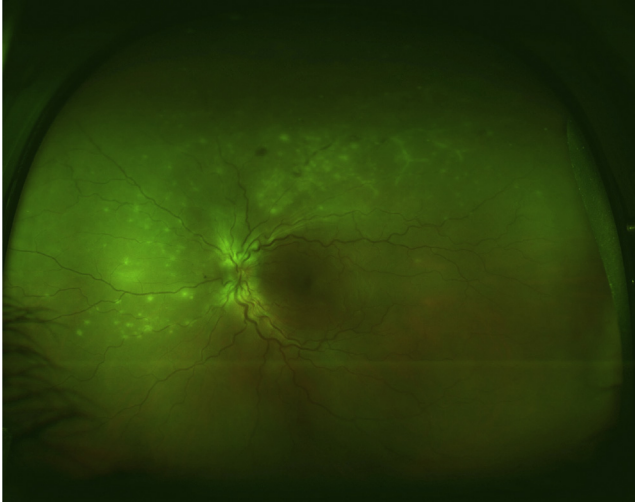
Received 15 March 2016; received in revised form 26 January 2017; accepted 5 March 2017; available online 12 March 2017.

<sup>a</sup> Istanbul University, Istanbul Faculty of Medicine, Department of Ophthalmology, Istanbul, Turkey

<sup>b</sup> Selcuk University Faculty of Medicine, Department of Ophthalmology, Konya, Turkey

<sup>c</sup> Istanbul University, Istanbul Faculty of Medicine, Department of Microbiology and Clinical Microbiology, Istanbul, Turkey

\* Corresponding author at: Istanbul Tıp Fakültesi, Göz Hastalıkları A.D., 34390 Capa, Istanbul, Turkey. Fax: +90 212 4142026. e-mail address: [emerih@yahoo.com](mailto:emerih@yahoo.com) (M. Oray).



**Figure 1.** Color fundus photograph at presentation elsewhere shows optic disc hyperemia, periphlebitis, and retinal infiltrates scattered in the superior and nasal quadrants of the left eye.

B, hepatitis C, human immunodeficiency virus, and brucellosis) and autoimmune etiologies revealed positive Rose Bengal test for brucellosis. Additionally, the patient had a history of consumption of unpasteurized milk products. However, pulmonary nodules without lymphadenopathy were found on computerized tomography scan of the chest, angiotensin-converting enzyme and lysozyme levels were slightly elevated, and tuberculin skin test was 0 mm, which led to a diagnosis of presumed sarcoidosis. She was given systemic high dose corticosteroid treatment. In the following weeks, ocular inflammation and pulmonary nodules showed resolution; however, after tapering systemic corticosteroid therapy she had a rebound ocular inflammation manifesting with a hypopyon, increased vitreous cells, and progression of retinal infiltrates. She was given subtenon triamcinolone acetonide injection, systemic corticosteroid dose was increased, and azathioprine was added to the regimen. These interventions resulted in worsening of inflammation and the patient was referred to our clinic for consideration of biologic therapy.

At presentation to us, the patient was still on an oral dose of 8 mg/day prednisolone and 150 mg/day azathioprine. She was cushingoid and had bilateral avascular necrosis of the hip due to prior corticosteroid therapy. She had a visual acuity of 20/20 in the right and counting fingers at 3 feet in the left eye. The right eye was healthy. The left eye had granulomatous and fine keratic precipitates, 2+ anterior chamber cells, mobile pupil, clear lens, and 3+ vitreous haze. Intraocular pressure was 12 mmHg in both eyes. Laser flare-meter readings were 4.4 photons/ms in the right and 34.6 photons/ms in the left eye. Fundus examination revealed vitreous opacities at the posterior hyaloid and a wide area of retinochoroiditis at the superotemporal quadrant (Fig. 2).

She was hospitalized with an initial diagnosis of endogenous endophthalmitis. Systemic corticosteroid and azathioprine therapy was stopped immediately. Other than high C-reactive protein level (21.51; normal: 0–5) initial laboratory results consisted of a normal complete blood count and biochemistry. Patient underwent vitreous biopsy and removal of subtenon corticosteroid particles. The vitreous sample and blood cultures were sent to bacteriological analysis. The samples were incubated in Bactec FX system (Beckton Dickinson,

USA) that showed positive signal after 48 h. The specimens taken from positive bottles were inoculated onto 5% sheep-blood agar and chocolate agar mediums and incubated at 5–10% CO<sub>2</sub> atmosphere. After 48 h grey-small colonies were seen in mediums and little coccobacilli in Gram stain. The bacteria were positive for oxidase and urease tests, identified as *Brucella* spp. with automatized identification system (API ID32 GN, bioMerieux, France) and exhibited agglutination with *B. melitensis* antisera. The microorganism was found to be sensitive to rifampicin, tetracycline, and doxycycline using gradient test (E-test, bioMerieux, France).

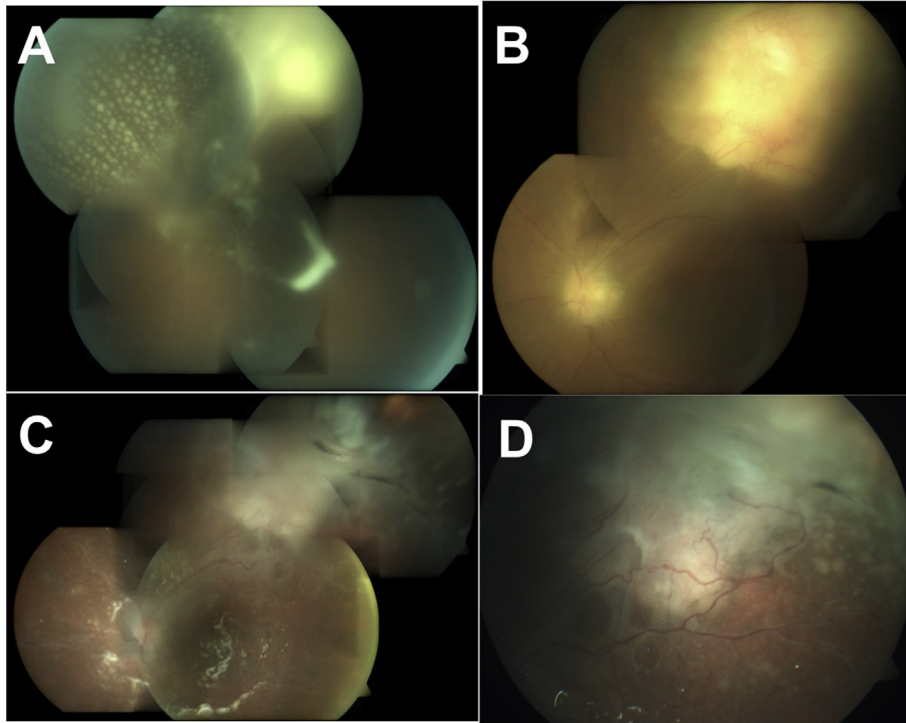
Urine culture was negative for pathological bacterial growth. Echocardiogram and arthrocentesis ruled out endocarditis and osteomyelitis secondary to brucellosis.

She was started on oral doxycycline 100 mg BID and rifampicin 600 mg/day along with topical cycloplegic twice a day and prednisolone acetate hourly. Due to ongoing inflammation despite treatment and for better visualization of the posterior segment, she underwent pars plana vitrectomy (PPV) and lensectomy on the 20th day of the treatment. Retinochoroidal granuloma surrounded by exudative retinal detachment at the superior quadrant and scattered multiple superficial retinal precipitates in all 4 quadrants were noted during surgery. Intravenous ceftriaxone 1 g BID was added to the regimen and continued for 1 month. Rifampicin was stopped on the 29th day of treatment because of nausea and trimethoprim-sulfamethoxazole (160 mg/800 mg BID) was added to the regimen. Retinal detachment developed on the 30th day of therapy. She then underwent scleral buckling, PPV with endolaser and silicone oil placement. Treatment was continued with oral doxycycline 100 mg BID and trimethoprim-sulfamethoxazole (160 mg/800 mg BID).

Visual acuity was 20/20 OD and 20/200 OS after completing 6th month of antibiotherapy. Slit-lamp examination showed quiet anterior chamber in both eyes. Intraocular pressure was 13 mmHg in the right and 7 mmHg in the left eye. Laser flare-meter readings were 3.7 photons/ms in the right eye and 40.1 photons/ms in the left eye. Fundus examination revealed a large fibrotic scar superiorly, an epiretinal membrane extending from the scar to the posterior pole associated with macular schisis, barely perceptible retinal precipitates, and gliotic sheathing of the vessels in the left eye (Fig. 2). The patient was followed up for 1 year after resolution of the endophthalmitis and during this time period there were no signs of active intraocular inflammation.

## Discussion

*B. melitensis* is an important human pathogen in endemic regions; however, due to rarity of the disease, ocular involvement of Brucellosis remains poorly recognized and there are no guidelines in the literature for optimal management of these patients. As described here, endogenous endophthalmitis is one of the manifestations of brucellosis, which results from the hematogenous spread of microorganisms and is an ophthalmic emergency that can have severe sight-threatening complications. The diagnosis of brucella endophthalmitis may be quite challenging and requires a high index of suspicion in the absence of characteristic systemic features. Furthermore, as in all infectious uveitis entities, immunosuppressive treatment due to initial misdiagnosis may lead to an aggressive course, and prolonged treatment may be required in such cases.



**Figure 2.** Color fundus photograph of the left eye at presentation to us shows vitreous opacities at the posterior hyaloid and retinochoroiditis at the superotemporal quadrant (A). Retinochoroidal granuloma at superotemporal quadrant was seen following pars plana vitrectomy, on the 32nd day of antibiotherapy (B). Indistinct margins of the optic disc, persistent sheathing of the retinal vessels, the reflex of silicone oil, and a fibrotic scar at the superotemporal quadrant were seen on the 45th day of treatment (C). At final visit, after completing 6th month of antibiotherapy, there was a fibrotic scar at the superotemporal quadrant (D).

Current recommended treatment regimen of Brucellosis involves the use of two or more antibiotics including doxycycline, streptomycin, rifampin, gentamicin, or trimethoprim-sulfamethoxazole in combination to avoid relapses.<sup>8</sup> In the present case report, initially the patient had received a combination of doxycycline and rifampicin as suggested in the literature. Additionally, intravenous ceftriaxone was also added to the regimen following PPV due to ongoing inflammation. Furthermore rifampicin was switched to trimethoprim-sulfamethoxazole because of side effects and she continued with a combination therapy of doxycycline and trimethoprim-sulfamethoxazole until 6th month of follow-up. The treatment duration was long because of severe inflammation due to initial mistreatment with immunosuppressive therapy elsewhere.

In conclusion, infectious etiologies should be ruled out prior to initiation of immunomodulatory treatment and systemic and/or local corticosteroid therapy. Additionally, although the prevalence of brucellosis has decreased in many countries and ophthalmic complications are rare, it should still be considered as a probable causative agent in infectious uveitis. An increased awareness of this atypical presentation may allow early diagnosis and prompt treatment to achieve a better visual outcome.

### Conflict of interest

The authors declared that there is no conflict of interest.

### Acknowledgment

None of the authors has any financial or proprietary interest in any material or method mentioned in this paper. Ilknur Tugal-Tutkun has received financial support outside the submitted work, including honoraria from Servier and AbbVie and lecture fees from Allergan. No government or non-government funding support has been obtained.

### References

1. Doganay M, Aygen B. Human brucellosis: an overview. *Int J Infect Dis* 2003;7:173–82.
2. Rolando I, Olarte L, Vilchez G, et al. Ocular manifestations associated with brucellosis: a 26-year experience in Peru. *Clin Infect Dis* 2008;1:1338–45.
3. Al Faran MF. *Brucella melitensis* endogenous endophthalmitis. *Ophthalmologica* 1990;201:19–22.
4. Karahocagil MK, Demirok A, Kiliç A, et al. Brucellosis and uveitis. *Ann Ophthalmol (Skokie)* 2008;40:48–50.
5. Sungur GK, Hazirolan D, Gurbuz Y, et al. Ocular involvement in brucellosis. *Can J Ophthalmol* 2009;44:598–601.
6. Walker J, Sharma OP, Rao NA. Brucellosis and uveitis. *Am J Ophthalmol* 1992;114:374–5.
7. Tabbara KF, Al-Kassimi H. Ocular brucellosis. *Br J Ophthalmol* 1990;74:249–50.
8. Yousefi-Nooraie R, Mortaz-Hejri S, Mehrani M, Sadeghipour P. Antibiotics for treating human brucellosis. *Cochrane Database Syst Rev* 2012;10, CD007179.