

Case Report

Interleukin 10-Mediated Response and Correlated Anemia in a Patient with Advanced Non-Small Cell Lung Carcinoma

Khalil Choucair^a Jesse D. Kelso^a Joseph R. Duff^a Christine S. Cassidy^a
Mary T. Albrethsen^a Mushtaq Ashraf^a Cherian Verghese^a Martin Oft^b
F. Charles Brunicardi^a Lance Dworkin^a John Nemunaitis^a

^aUniversity of Toledo College of Medicine and Life Sciences, Toledo, OH, USA;

^bARMO Biosciences Inc., Redwood City, CA, USA

Keywords

Anemia · Combined immunotherapy · Clinical trial · Hyper-ferritinemia · Tumor response correlate

Abstract

Anemia in cancer patients is associated with poor quality of life, reduced response to therapy, and decreased overall survival. We describe a case of a 56-year old woman with advanced metastatic non-small cell lung carcinoma who demonstrated marked response to a novel combinational immunotherapy approach involving a long-acting PEGylated construct of recombinant human Interleukin-10 with Nivolumab, an anti-PD-L1 checkpoint inhibitor. While on treatment, the patient developed severe anemia and hyper-ferritinemia requiring RBC transfusion support. Here we discuss a possible novel immune mechanism of IL10-mediated anemia in correlation with tumor response.

© 2019 The Author(s)
Published by S. Karger AG, Basel

Background

The importance of early diagnosis and prompt management of anemia in a patient with cancer, goes beyond both controlling its debilitating signs/symptoms and improving quality of life: anemia has been associated with reduced response to therapy, poor loco-regional control and decreased overall survival. It has also been suggested that anemia may be an independent poor prognostic factor in cancer patients [1].

IL-10 is a cytokine synthesis inhibitor produced by helper T lymphocytes (Th2) cells. It is involved in broad immune-regulatory and anti-inflammatory activities mediated by binding to IL-10 receptor (IL-10R) [2]. Activation of the IL-10R generates a signaling cascade through the JAK1-STAT3 pathway, leading to complex pleiotropic effects including anti-inflammatory, immune-suppression and immune-stimulation [2].

IL-10 is also involved in tumor surveillance via enhancement of CD8+ T cell survival and proliferation, induction and maturation of memory T cells, enhancement of infiltration into the intratumoral space, enhancement of interferon-Gamma (γ -IFN)/granzyme expression activity and increased expression of tumor MHC [3, 4]. Recent work by Naing et al., demonstrated that IL-10 induced systemic immune activation of CD8+ T cells is correlated with tumor response [5]. Moreover, studies involving genetically engineered IL-10 deficient mouse models testing for inflammatory bowel disease (IBD) have revealed simultaneous development of IBD and cancer suggesting that reduction in IL-10 facilitates cancer growth and development [2, 6].

Case Description

We recently entered a patient (#01) into a randomized phase 2 clinical trial (NCT03382912) studying AM0010 (PEGylated Interleukin 10; peg-IL-10) in combination with Nivolumab. AM0010 (pegilodecakin) is a long-acting PEGylated form of recombinant human Interleukin-10 (IL-10). Results from a prior Phase 1/1b clinical trial in over 350 cancer patients demonstrated a good safety/tolerability profile for AM0010 and sustained anti-tumor effects across several different cancer types, including pancreatic cancer, renal cell carcinoma, NSCLC and others. The most common side effects of AM0010 were anemia, thrombocytopenia and fatigue. No patients developed adverse autoimmune activation [7]. We observed a unique episode of IL-10 induced anemia in correlation with significant tumor response.

Patient #01 is a 56-year-old female, first diagnosed with adenocarcinoma of the lung in October 2015. Initial imaging revealed an 8 × 7 cm mass of the right upper lobe (RUL) invading into the mediastinum, with a metastatic lesion of the right adrenal gland, consistent with stage IV disease. Following four cycles of paclitaxel/carboplatin from November 2015 to January 2016 and adjuvant radiation therapy to the lung and adrenal masses, a PET-CT scan in February 2018 revealed an enlarging lesion in the RUL and an increased SUV uptake of 7.7 of units, consistent with progressive disease. In March 2018, the patient experienced severe headaches and expressive aphasia and brain MRI portrayed a mass in the left temporal lobe. Surgical resection showed metastatic non-small cell carcinoma. Patient #01 then received stereotactic radiation to the left temporal lobe bed, MRI of the brain in April 2018 showed peripheral enhancement consistent with post-radiation inflammation, although residual malignancy could not be ruled out. Then on 04/18/2018, PET-CT demonstrated recurrent disease in the RUL with SUV uptake of 11.2. Patient #01 elected to participate in a trial with combination of Nivolumab and AM0010.

The initial dosing schedule (05/16/2018) consisted of Nivolumab (240 mg IV q 2 weeks) and AM0010 (0.8 mg subcutaneous injection) daily. Two weeks after treatment initiation, a reduction in hemoglobin (Hb) from a baseline of 11.1–8.5 g/dL was observed. There was no evidence of bleeding, hemolysis, iron/folate/B12 deficiency and ferritin level was 1,054 ng/mL. Given the patient's stable clinical status, treatment was continued and repeat Hb levels at the end of cycle 2 (6/13/2018) revealed no change in Hb (Fig. 1). However, by the end of the 3rd cycle of therapy (6/30/2018), the patient experienced a grade III anemia with a hemoglobin drop to 6.6 g/dL with no evidence of bleeding or hemolysis. Two packed units of red blood cells (PURBC) were administered along with darbepoetin alpha, an erythropoietin (EPO) stimulating protein. Subsequent dosing schedule of IL-10 was reduced ~30% from 7 to 5 days per week. Hb levels remained stable through cycles 4–6, however, at the end of cycle 7 (8/21/2018), and despite prior transfusion with 2 more PURBCs (8/7/2018), levels diminished to below 10 g/dL (9 g/dL; 8/7/2018), (8.7 g/dL; 8/21/2018) and correlated with rising levels of ferritin, 3,252 ng/mL and 3,954 ng/mL, respectively. Prior to initiation of cycle 8, Patient #01 was further transfused with 3 PURBCs (8/22/2018) and darbepoetin alpha was discontinued as this appeared to be of no advantage and we wanted to minimize possible risk of EPO related immune suppressive activity [8].

Four months following treatment initiation (9/4/2018), PET-CT scan revealed marked reduction in SUV from 11.2 to below pathogenic level, 2.7 in the RUL and no evidence in tumor activity in the adrenal glands (Fig. 2). Brain MRI also revealed no evidence of residual tumor or new metastatic pathology. However, given the persistence of anemia (Hb of 9.4 on 9/4/2018), we held AM0010 and continued Nivolumab for four weeks based on anemia related fatigue and exertional dyspnea. Patient #01 was transfused with 2 more PURBCs on 9/4/2018 (pre-transfusion Hb: 9.4 g/dL) and 2 other PURBCs on 9/19/2018 (pre-transfusion Hb: 9 g/dL). Of significance, ferritin levels at the cycle 10 mark were markedly elevated compared to prior high levels (3,954 ng/mL), reaching up to 6,732 ng/mL, in parallel to rising reticulocyte percent (5.26% absolute count of 0.1567). Direct Coomb's test (anti-globulin) was however negative for anti-C3 and anti-IgG antibodies.

Following the four-week hold (10/2/2018), Hb levels stabilized to near baseline with a value of 10.9 g/dL, and corresponding decrease in ferritin levels down to 3,486 ng/mL. Treatment was resumed with AM0010 using a further reduced schedule of 70% (2 days on, and 5 days without injections). For the following 6 weeks (cycle 13 completed on 11/14/2018) Hb levels stabilized above 10 g/dL, reaching near baseline value of 11 g/dL. This corresponded with a decrease in reticulocyte count, a descending trend in ferritin levels. Haptoglobin and total bilirubin levels in blood were within normal limits (122 and 0.6 mg/dL, respectively) and no uro-bilinogen was detected in the urine. Clinically, and following treatment hold, transfusions and change in dosing schedule, Patient #01 experienced significant improvement in energy levels with decreased fatigue and an ability to resume activities of daily living and travel to Italy on her own. CT and PET scans of the chest and pelvis were repeated in November 2018 and February 2019, showing no active disease.

Discussion

The case history of Patient #01 illustrates the clinical effectiveness of a unique combination of a checkpoint inhibitor with IL-10 to potentiate immune stimulation. However, in correlation with tumor response, we observed an unexpected and previously unreported side

effect of severe anemia. Although IL-10 has previously been described to be associated with anemia [7], the mechanism of the latter remains uncharacterized.

High levels ferritin, which were observed, along with elevated transferrin are consistent with a process of active iron sequestration. Ferritin levels have been shown to be elevated in several diseases and conditions such as hemochromatosis, chronic inflammatory states such as rheumatoid arthritis, liver disease, chronic alcohol consumption, and renal failure. Patient #01 did not have any of the aforementioned conditions. Furthermore, following the multiple transfusions at different time points, which could induce elevated ferritin, the ferritin levels were consistently elevated to >3,000 ng/mL which is very unusual for RBC transfusion relationship. Typical values of ferritin associated with transfusion-induced iron overload range between 1,000–3,000 ng/mL in patients who are chronically transfused [9]. This patient did not have a history of chronic transfusion.

The onset of anemia in Patient #01 was also relatively acute and occurred within two weeks of treatment initiation, therefore, strongly suggestive of relationship to nivolumab or IL10.

Checkpoint inhibitors present a wide spectrum of immune-related toxicities. Nivolumab-induced autoimmune hemolytic anemia has been reported in relationship to warm auto-antibody (IgG) mediated autoimmune hemolysis and positive anti-globulin Coomb's test [10]. This patient was negative for that. Furthermore, nivolumab related autoimmune anemia, when reported, is not observed until later in the course of treatment (>2 cycles) [10]. This timeline is consistent with our current understanding of immune anti-tumor activity, which often takes longer before the appearance of measurable effects compared to conventional cytotoxic therapies, and includes a phase of apparent progression, known as pseudo-progression [11]. Thus, the absence of detectable auto-antibodies and normal haptoglobin levels in the workup, along with the relatively quick onset of anemia, makes nivolumab less likely to be the cause in Patient #01's anemia.

IL-10 induced anemia has been previously described in states of chronic inflammatory disorders, often referred to as anemia of chronic disease (ACD) [12]. A hallmark of ACD is the disruption of iron hemostasis, leading to diversion of iron from the circulation into storage sites thus limiting the availability of iron for erythroid progenitor cells. This translates into reduced serum iron concentration, low TIBC, normal to increased transferrin due to active iron sequestration, and normal to increased ferritin, the iron-storage form of iron. Several studies have investigated the role of inflammatory cytokines, including IL-10, in mediating iron hemostasis mostly by regulation of hepcidin [13–15], the main effector in the iron sequestration process. In Hodgkin lymphoma patients, cytokines such as IL-6 and IL-10 are present in high levels in the microenvironment and are thought to induce hepcidin expression through STAT-3-dependent transcription, although IL-6 rather than IL-10 most significantly correlated with levels of hepcidin [13]. Human macrophages exposed to *Plasmodium falciparum* show an increased production of IL-10 and IL-6, as part of the inflammatory reaction; in this model, IL-10 was found to induce hepcidin secretion in a dose-dependent manner, through STAT-3 phosphorylation, hence demonstrating a role for IL-10 in modulating iron sequestration during acute phase infection [14]. This mechanism alone, however would not explain the excessively high levels of ferritin in Patient #01 that ranged between 7 and 45 fold above what is expected in iron sequestration seen in chronic inflammation (normal to slight elevation above the upper normal level of 150 ng/mL).

Another mechanism involving IL-10 in mediating anemia has also been described in a murine skin cancer model, whereby IL-10 mediated suppression of erythropoiesis was shown to induce upregulation of STAT1/3 along with release of IFN- γ [3]. Both STAT1 and IFN- γ in

turn suppress erythropoiesis, via upregulation of STAT1-dependent expression of IL-15 [16]. This suppression is maintained by IL-15 positive feedback to both IL-10 and IFN- γ , further increasing their expression level, and thus erythropoiesis suppression. Lastly, IL-10 has been reported to directly inhibit the growth of burst-forming-unit erythroid, the first progenitor in erythrocyte differentiation from stem cells [17].

Based on Patient #01's presentation and laboratory results, and in light of the above findings, we hypothesize that the anemia we observed along with the hyper-ferritinemia, are the result of active and excessive IL-10-mediated iron sequestration, as well as IL-10-mediated suppression of erythropoiesis. We noticed that modification of IL-10 dosing schedules with either withholding therapy or decreasing IL-10 dose, reflected in improvement of Hb levels, and relative decrease in ferritin concentrations, most clearly seen following cycle# 10 (Fig. 1). The role of IL-10 in inducing anemia was similarly reported in Crohn's model whereby a survey of 329 patients with chronic Crohn's disease revealed a correlation between IL-10 levels and increased serum ferritin and soluble transferrin, leading to disruption of iron available to erythroid progenitor cells. Furthermore, the study revealed a relatively new mechanism through which IL-10 and IFN- γ were shown to increase *de novo* synthesis of ferritin mRNA [12]. This highlights the complexity associated with the role of IL-10 in mediating anemia, and the multiple mechanisms discussed can potentially explain our experience with Patient #01.

The use of multiple RBC transfusions, in this case, were essential in both alleviating the patient's symptoms and maintaining her on study from which she benefited and remains on treatment 10 months later without evidence of active disease. Whether anemia likely related to IL-10 will be a common correlate to tumor immune response benefit remains to be seen through further clinical investigation.

Statement of Ethics

The research presented in the manuscript was ethically conducted in accordance with the World Medical Association Declaration of Helsinki and the appropriate guidelines for human studies. The study protocol was approved by the Institutional Review Board (IRB) Committee on Human Research (IRB# 202962). Patient's informed consent was obtained prior to study initiation.

Disclosure Statement

There are no financial conflicts of interest to disclose.

Funding Sources

N/A.

Author Contributions

All authors made substantial contributions to the conception of the work, the acquisition, analysis, and interpretation of relevant data, and participated in drafting the work, revising it critically for important intellectual content, and approved the final version to be published.

References

- Dunst J, Kuhnt T, Strauss HG, Krause U, Pelz T, Koelbl H, et al. Anemia in cervical cancers: impact on survival, patterns of relapse, and association with hypoxia and angiogenesis. *Int J Radiat Oncol Biol Phys*. 2003 Jul;56(3):778–87.
- Oft M. IL-10: master switch from tumor-promoting inflammation to antitumor immunity. *Cancer Immunol Res*. 2014 Mar;2(3):194–9.
- Mumm JB, Emmerich J, Zhang X, Chan I, Wu L, Mauze S, et al. IL-10 elicits IFN γ -dependent tumor immune surveillance. *Cancer Cell*. 2011 Dec;20(6):781–96.
- Walsh MD, Dent OF, Young JP, Wright CM, Barker MA, Leggett BA, et al. HLA-DR expression is associated with better prognosis in sporadic Australian clinicopathological Stage C colorectal cancers. *Int J Cancer*. 2009 Sep;125(5):1231–7.
- Naing A, Infante JR, Papadopoulos KP, Chan IH, Shen C, Ratti NP, et al. PEGylated IL-10 (Pegilodecakin) Induces Systemic Immune Activation, CD8+ T Cell Invigoration and Polyclonal T Cell Expansion in Cancer Patients. *Cancer Cell*. 2018 Nov;34(5):775–791.e3.
- Berg DJ, Davidson N, Kühn R, Müller W, Menon S, Holland G, et al. Enterocolitis and colon cancer in interleukin-10-deficient mice are associated with aberrant cytokine production and CD4(+) TH1-like responses. *J Clin Invest*. 1996 Aug;98(4):1010–20.
- Naing A, Infante JR, Papadopoulos KP, Wong DJ, Autio KA, Falchook GS, et al. Antitumor activity and immune correlates of PEGylated human IL-10 (AM0010) alone or in combination with anti-PD-1. *Cancer Immunol Res*. 2016;4(11):PR08–08.
- Wood MA, Goldman N, DePierri K, Somerville J, Riggs JE. Erythropoietin increases macrophage-mediated T cell suppression. *Cell Immunol*. 2016 Aug-Sep;306-307:17–24.
- Files B, Brambilla D, Kutlar A, Miller S, Vichinsky E, Wang W, et al. Longitudinal changes in ferritin during chronic transfusion: a report from the Stroke Prevention Trial in Sickle Cell Anemia (STOP). *J Pediatr Hematol Oncol*. 2002 May;24(4):284–90.
- Tardy MP, Gastaud L, Boscagli A, Peyrade F, Gallamini A, Thyss A. Autoimmune hemolytic anemia after nivolumab treatment in Hodgkin lymphoma responsive to immunosuppressive treatment. A case report. *Hematol Oncol*. 2017 Dec;35(4):875–7.
- Chiou VL, Burotto M. Pseudoprogression and Immune-Related Response in Solid Tumors. *J Clin Oncol*. 2015 Nov;33(31):3541–3.
- Tilg H, Ulmer H, Kaser A, Weiss G. Role of IL-10 for induction of anemia during inflammation. *J Immunol*. 2002 Aug;169(4):2204–9.
- Hohaus S, Massini G, Giachelia M, Vannata B, Bozzoli V, Cuccaro A, et al. Anemia in Hodgkin's lymphoma: the role of interleukin-6 and hepcidin. *J Clin Oncol*. 2010 May;28(15):2538–43.
- Huang H, Lamikanra AA, Alkaitis MS, Thézénas ML, Ramaprasad A, Moussa E, et al. Interleukin-10 regulates hepcidin in Plasmodium falciparum malaria. *PLoS One*. 2014 Feb;9(2):e88408.
- Huang P, Wang J, Lin X, Yang FF, Tan JH. Effects of IL-10 on iron metabolism in LPS-induced inflammatory mice via modulating hepcidin expression. *Eur Rev Med Pharmacol Sci*. 2017 Aug;21(15):3469–75.
- Mullarky IK, Szaba FM, Kummer LW, Wilhelm LB, Parent MA, Johnson LL, et al. Gamma interferon suppresses erythropoiesis via interleukin-15. *Infect Immun*. 2007 May;75(5):2630–3.
- Oehler L, Kollars M, Bohle B, Berer A, Reiter E, Lechner K, et al. Interleukin-10 inhibits burst-forming unit-erythroid growth by suppression of endogenous granulocyte-macrophage colony-stimulating factor production from T cells. *Exp Hematol*. 1999 Feb;27(2):217–23.

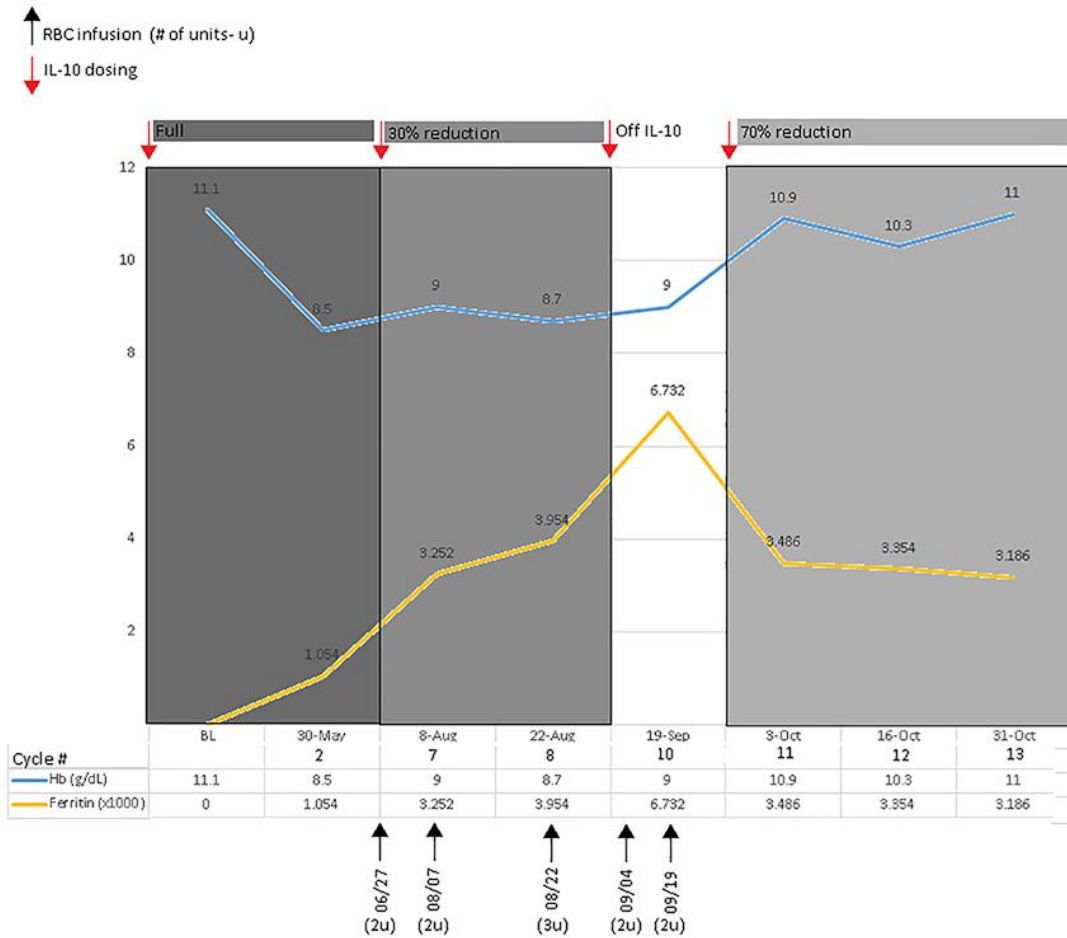


Fig. 1. Trends of Hb and Ferritin in time with respect to cycles and IL-10 dosing. Relationship between levels of Hb, and Ferritin over time in relation to RBC infusion and IL-10 dosing.

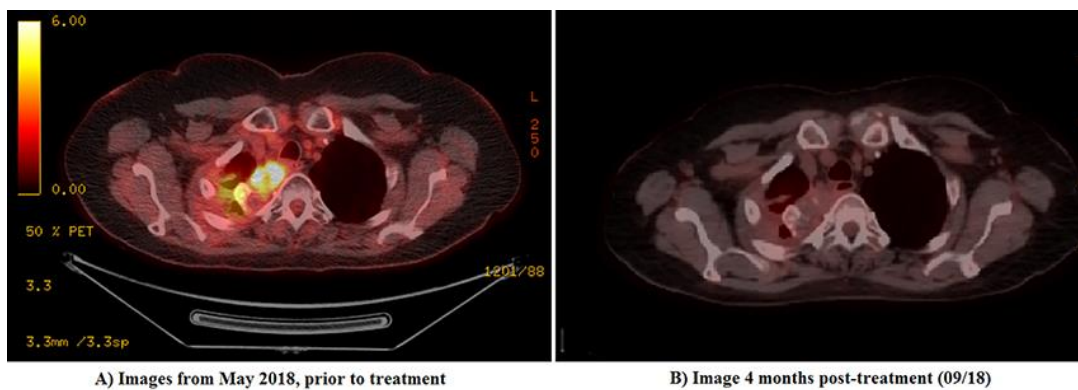


Fig. 2. PET-CT scan images for Patient #01 prior (A) and 4 months following (B) treatment with Nivolumab + AM0010.