



Case report

Lobular panniculitis associated with chikungunya fever: A case report

Siripan Sangmala^{a,1}, Thanadon Eksomtramage^{a,1}, Kumpol Aiempakit^{a,*},
Kanokphorn Chiratikarnwong^a, Sauvarat Auepemkiate^b

^a Division of Dermatology, Department of Internal Medicine, Faculty of Medicine, Prince of Songkla University, Hat Yai, Songkhla, Thailand

^b Department of Pathology, Faculty of Medicine, Prince of Songkla University, Hat Yai, Songkhla, Thailand

ARTICLE INFO

Article history:

Received 11 October 2018

Received in revised form 24 October 2018

Accepted 24 October 2018

Keywords:

Chikungunya

Cutaneous

Panniculitis

Skin

Subcutaneous tissue

ABSTRACT

Chikungunya fever is a mosquito-borne viral disease classically characterized by an acute onset of fever, arthralgia, and skin rash. In this article, we report the acute febrile illness of an adult female with arthropathy and morbilliform eruptions. The patient developed panniculitis lesions on both shins. This report aims to describe an infrequent cutaneous presentation of chikungunya fever.

© 2018 Published by Elsevier Ltd. This is an open access article under the CC BY-NC-ND license (<http://creativecommons.org/licenses/by-nc-nd/4.0/>).

Introduction

Chikungunya, a word derived from the Kimakone/Makonde language, means 'to become distorted' as it is associated with leaning in the forward position or bending over due to severe joint pain [1]. Infected mosquitoes cause chikungunya fever in endemic areas [1]. The classic clinical manifestations are acute fever, arthralgia, and skin rash. The most common cutaneous presentation is generalized papulomacular eruptions [2,3]. Herein, we report a case of chikungunya fever with the atypical presentation of panniculitis in the lower extremities. To the best of our knowledge, there are no previous reports of lobular panniculitis in patients with chikungunya fever.

Case presentation

A 33-year-old female, presented to our out-patient department as a result of developing discrete painful erythematous plaques and nodules in both legs within one day prior to presentation. Previously, she had experienced high-grade fever, shivering and severe arthralgia exclusively in the lower extremities for six days, without any other specific symptoms. Thenceforth, she developed low-grade fever, painful oral aphthous ulcers, and erythematous rash. The dermatologic examination revealed a generalized

branchable erythematous rash on her face, trunk and extremities, and three discrete ill-defined erythematous, tender nodules on both shins (Fig. 1A and B).

The laboratory investigations revealed leukopenia with a normal platelet count, mild transaminitis (aspartate transaminase 40 (0–32) U/L, alanine transaminase 37 (0–33) U/L), and positive IgM finding for the chikungunya virus. The dengue serology (nonstructural protein 1, IgM, IgG) and rubella IgM results were negative. She subsequently underwent a tissue biopsy on her left leg because the panniculitis lesions required further investigation for precise identification and to rule out any malignancy. The dermatopathological studies showed an infiltration of lymphohistiocytes and neutrophils, and distorted cells around both superficial and deep blood vessels, involving the lobules of subcutaneous tissues without evidence of leukocytoclastic vasculitis (Fig. 2A and B). The immunohistochemistry studies demonstrated that the lymphocytes located in the fat lobules were positive for CD3, CD4, CD5, CD8, CD68, CD56, and negative for CD20. The direct immunofluorescent studies were negative for IgG, IgM, IgA, C3, and C1q.

Hence, the patient was diagnosed with chikungunya fever with lobular panniculitis. She was treated with nonsteroidal anti-inflammatory drugs. After the treatment, the fever and arthralgia improved within one day, and the panniculitis lesions resolved entirely within five days.

* Corresponding author at: Division of Dermatology, Department of Internal Medicine, Prince of Songkla University, Hat Yai, Songkhla 90110, Thailand.

E-mail address: akumpol@medicine.psu.ac.th (K. Aiempakit).

¹ These authors contributed equally to this article.

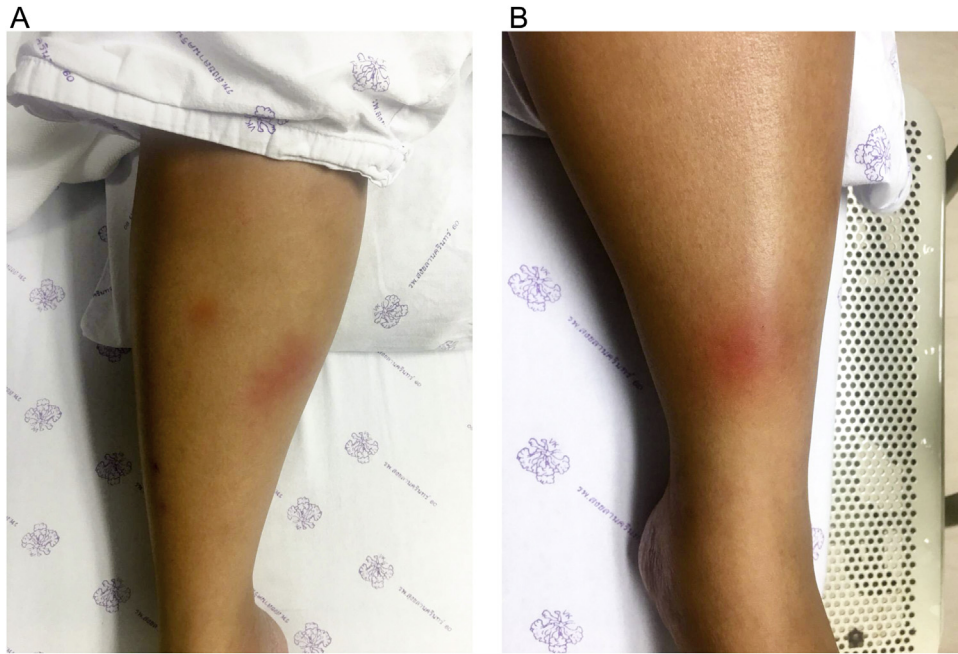


Fig. 1. A, B photographs showing three ill-defined, erythematous, tender nodules and plaques on both shins.

Discussion

The chikungunya virus, an alphavirus appertaining to the Togaviridae family, is a mosquito-borne infection, associated especially with the *Aedes* species—*Aedes aegypti*, *Aedes albopictus*, *Aedes polynesiensis*—and *Culex*, which originated in Africa and is characterized by periodical outbreaks [1]. Lately, the disease has spread out and has become endemic in over 60 countries around the Indian Ocean and the Pacific Ocean. Since the virus infection persists throughout the lifespan of the primary host, chikungunya can be transmitted to all age groups and both genders equally [1]. The incubation period is around 2–7 days, followed by replication in the human skin, and assumable propagation to the liver, spleen, joints, lymphatic tissue by the blood, which result in the chikungunya fever [1–3].

As a consequence of the human mediating immune responses, the patient presents with acute high-grade fever

for 2–4 days, which is explained by the high viral load, headache, conjunctival injection, lymphadenopathy, and morbilliform eruptions on the trunk and extremities [1–4]. Moreover, cutaneous manifestations are reported with vesiculobullous, peculiar pigmentation over the nose (chik sign), the Stevens-Johnson syndrome, and toxic epidermal necrolysis-like lesions [2,3,5]. In this case, we report panniculitis that is characterized by deeply erythematous inflammatory nodules or plaques, which can be explained by the inflammation of subcutaneous fat.

Moreover, almost all patients mention joints pain affecting their extremities (hands, ankles, knuckles) for two weeks and, at times, up to longer than a year [1]. In severe cases, among infants and elderly patients with multiple co-morbidities, this condition can lead to mortality. Even though no specific antiviral therapy or vaccination exists for this disease, it is usually associated with a spontaneous recovery within 7–14 days; thus, supportive

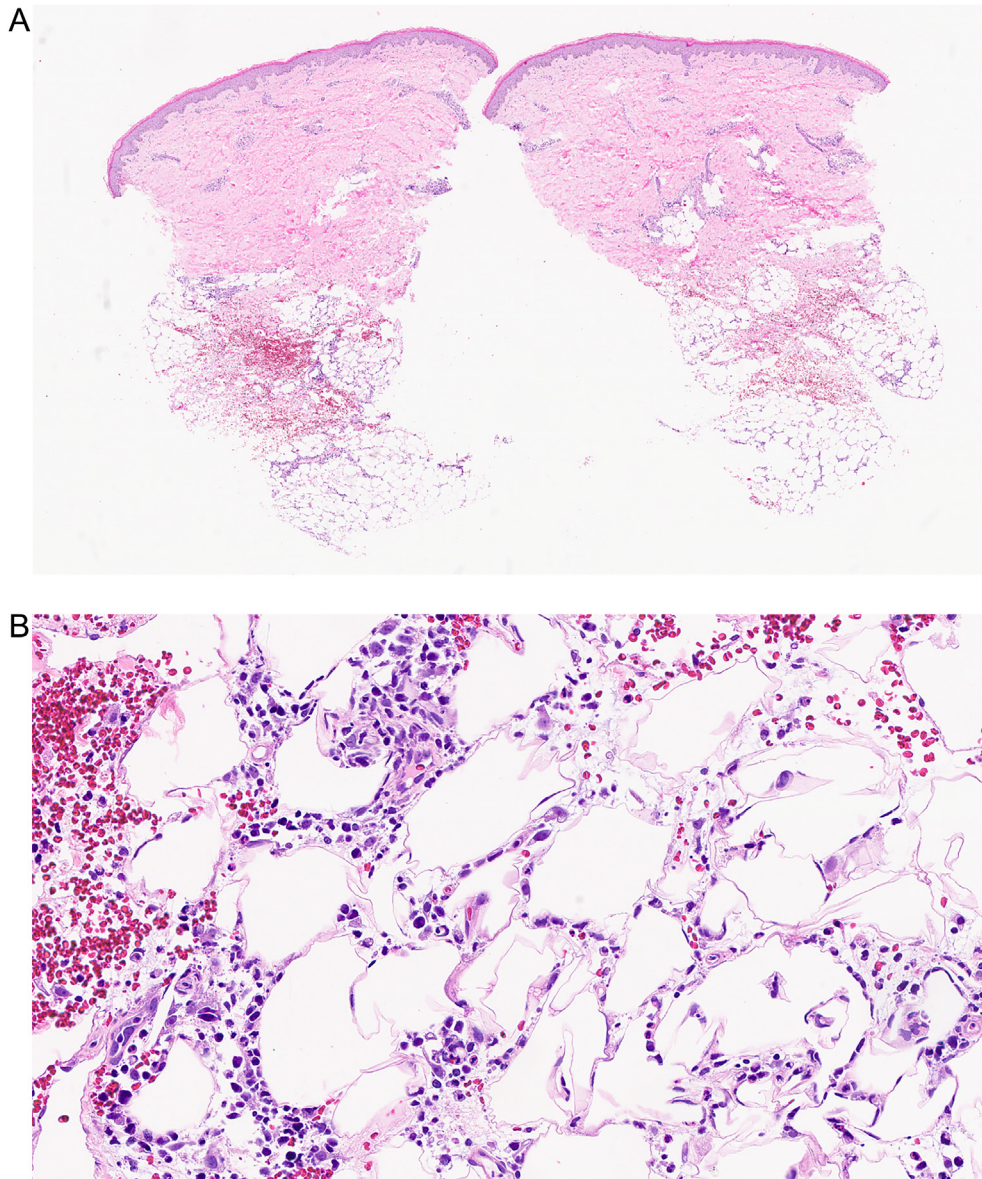


Fig. 2. Skin biopsy specimens from the right shin. A, Low magnification shows the superficial and deep perivascular infiltration of inflammatory cells as well as into fat lobules (hematoxylin-eosin stain, original magnification x2). B, Lymphohistiocytes and neutrophils infiltration into subcutaneous fat lobules (hematoxylin-eosin stain, original magnification x20).

treatment such as rest, adequate intravenous fluid administration, and pain control are recommended.

Conclusion

The authors report a patient with chikungunya fever, which manifested with lobular panniculitis. To our knowledge, there is no earlier publication of a panniculitic reaction in chikungunya viral infection.

Funding

This research did not receive any specific grant from funding agencies in the public, commercial, or not-for-profit sectors.

Conflict-of-interest

All authors declare that they have no conflicting interests in relation to this report.

Acknowledgments

The authors are grateful to the staff of the International Affairs Office, Faculty of Medicine, Prince of Songkla University for their proofreading and editing services. This case report was approved by the Research Ethics Committee, Faculty of Medicine, Prince of Songkla University (REC.61-323-14-1).

References

- [1] Lo Presti A., Lai A, Cella E, Zehender G, Ciccozzi M. Chikungunya virus, epidemiology, clinics and phylogenesis: a review. *Asian Pac J Trop Med* 2014;7(12):925–32.
- [2] Riyaz N, Riyaz A, Rahima Abdul, Latheef EN, Anitha PM, Aravindan KP, et al. Cutaneous manifestations of chikungunya during a recent epidemic in Calicut, north Kerala, south India. *Indian J Dermatol Venereol Leprol* 2010;76(6):671–6.
- [3] Bandyopadhyay D, Ghosh SK. Mucocutaneous features of Chikungunya fever: a study from an outbreak in West Bengal, India. *Int J Dermatol* 2008;47(11):1148–52.
- [4] Tini ML, Rezza G. Morbilliform skin rash with prominent involvement of the palms in Chikungunya fever. *IDCases* 2018;13:e00421.
- [5] Garg T, Sanke S, Ahmed R, Chander R, Basu S. Stevens-Johnson syndrome and toxic epidermal necrolysis-like cutaneous presentation of chikungunya fever: a case series. *Pediatr Dermatol* 2018;35(3):392–6.