

Adhesive capsulitis: MRI correlation with clinical stages and proposal of MRI staging

Amarnath Chellathurai, Komalavalli Subbiah, Atchaya Elangovan, Sivakumar Kannappan

Department of Radio Diagnosis, Govt Stanley Medical College, Affiliated to The Tamilnadu Dr. MGR Medical University, No 69, Anna Salai, Guindy, Chennai, India

Correspondence: Dr. Komalavalli Subbiah, Department of Radiodiagnosis, Government Stanley Medical College, Chennai - 600001, India. E-mail: drkomalarajesh@gmail.com

Abstract

Objective: The purpose of this study was to correlate the magnetic resonance imaging (MRI) findings of adhesive capsulitis with clinical stages and thereby propose a MR staging system. **Materials and Methods:** This study consisted of 74 patients with clinically diagnosed adhesive capsulitis. The edema of the inferior glenohumeral ligament (IGHL), pericapsular edema, thickness of anterior band of IGHL, axillary pouch, thickness of coracohumeral ligament, and obliteration of fat in the subcoracoid triangle were evaluated by MRI. **Results:** Thickening of the anterior band of IGHL showed most significant correlation with the clinical stages. The distribution of edema of IGHL and pericapsular edema also showed significant correlation with the clinical stages of adhesive capsulitis. Pericapsular edema and IGHL edema was not observed in stage IV. **Conclusion:** MR is a useful tool for evaluation and prediction of clinical stage of adhesive capsulitis.

Key words: Adhesive capsulitis; magnetic resonance imaging; MRI staging; shoulder

Introduction

Adhesive capsulitis, also called frozen shoulder^[1,2] is a clinical syndrome of pain and severely decreased joint motion caused by thickening and contraction of the joint capsule and synovium.^[2,3] The risk factors are female sex, patients aged >40 years, trauma, diabetes, prolonged immobilization, thyroid disease, stroke, myocardial infarction, and autoimmune disease.

The diagnosis is by clinical criteria.^[4] There are four clinical stages of adhesive capsulitis.^[5] The clinical manifestations of adhesive capsulitis usually resemble other shoulder pathologies which makes the clinical diagnosis of the

condition difficult. So, magnetic resonance imaging (MRI) can serve as an adjunct to the clinical diagnosis.

To our knowledge, studies about MRI staging of adhesive capsulitis have not yet been published in the literature. MRI can be used to diagnose all the stages even when the clinical findings are subtle like in stage I, so that appropriate treatment can be initiated. The treatment protocol is dependent on the clinical staging, but since the clinical manifestations overlap various other shoulder pathologies, MR aids in accurate and early diagnosis and thereby shortens the clinical course. The purpose of this study was to correlate the MR findings with the clinical

This is an open access journal, and articles are distributed under the terms of the Creative Commons Attribution-NonCommercial-ShareAlike 4.0 License, which allows others to remix, tweak, and build upon the work non-commercially, as long as appropriate credit is given and the new creations are licensed under the identical terms.

For reprints contact: reprints@medknow.com

Cite this article as: Chellathurai A, Subbiah K, Elangovan A, Kannappan S. Adhesive capsulitis: MRI correlation with clinical stages and proposal of MRI staging. Indian J Radiol Imaging 2019;29:19-24.

Access this article online	
<p>Quick Response Code:</p> 	<p>Website: www.ijri.org</p> <p>DOI: 10.4103/ijri.IJRI_116_18</p>

stages of adhesive capsulitis and propose a staging system.

Materials and Methods

This was a single institutional prospective analysis of patients with clinically diagnosed adhesive capsulitis. All patients who were clinically diagnosed as adhesive capsulitis between August 2013 to May 2017 and underwent MRI either for diagnosis or for follow up were included. Patients with symptoms of unilateral adhesive capsulitis referred from the orthopedics department of our institution were included in this study. We had a total of 74 patients, of which 43 were males and 31 were females. The age group ranged from 37 to 75 years with mean age of 53 years.

Inclusion criteria

Patients with presumptive clinical diagnosis of adhesive capsulitis with detailed clinical information and history which permitted clinical staging of adhesive capsulitis and patients with normal range of motion (ROM) in the opposite shoulder were included.

Exclusion criteria

Patients who have received treatment for adhesive capsulitis, patients with other shoulder pathologies, rotator cuff injuries, patients with active infection, patients with history of trauma, and patients with a history of surgery related to onset of adhesive capsulitis were excluded from the study.

Clinical assessment

The patients were assessed in the orthopedics department of our institution based on the duration of the symptoms, active and passive movements of the shoulder, movements associated with pain, restriction of range of movements, and clinical stage was given to each patient based on the clinical staging system adapted from Hannafin and Chiaia^[5] [Table 1].

MRI protocol

MRI examinations were done in 1.5 T system (Siemens, MAGNETOM AERA, Germany). The sequences obtained were proton density (PD) fat suppressed: coronal oblique,

sagittal, and axial. Fast spin echo T1-weighted sagittal images.

The parameters used were: coronal fat-suppressed PD imaging – TR-2710, TE-37; slice thickness – 3.5 mm; FOV-17 cm, axial fat-suppressed PD imaging – TR-3080, TE-37; slice thickness – 3.5 mm; FOV-17 cm, sagittal fat-suppressed PD imaging – TR/TE, 2710–37; slice thickness – 3.5 mm; FOV-17 cm, sagittal T1-weighted imaging – TR-708, TE-11; slice thickness – 3.5 mm; FOV-16 cm.

The MRI examinations were read by two experienced radiologists who were blinded to the clinical stages of the patients. Edema of the inferior glenohumeral ligament (IGHL) in the humeral and glenoid portions of the axillary pouch, anterior and posterior pericapsular edema, fluid around the biceps tendon, bone marrow edema, obliteration of the fat in the subcoracoid triangle, thickness of the humeral and glenoid portions of the anterior band of IGHL, thickness of the humeral and glenoid portions of the capsule at the axillary pouch, thickness of the coracohumeral ligament, and height and width of the axillary pouch were evaluated.

Edema of the IGHL was defined as high-signal intensity on coronal fat-suppressed PD images of the humeral and glenoid portions of axillary pouch [Figure 1A]. Edema of the IGHL was categorized as either present/absent/mild. Anterior and posterior pericapsular edema was defined as high-signal intensity on sagittal fat-suppressed PD images [Figure 1B]. Fluid around the biceps tendon was considered significant when the fluid depth was >2 mm on axial fat-suppressed PD images at the level of humeral neck [Figure 1C]. Amount of fluid around the biceps tendon sheath and in the axillary pouch was compared. Obliteration of the subcoracoid fat was defined as low-signal intensity in the triangular area formed by the coracoid process, coracohumeral ligament, and the humeral head seen on sagittal T1-weighted images in comparison to the subcutaneous fat [Figure 1D]. Obliteration of the fat outside this triangle anterior to the coracohumeral ligament was assessed similarly. The maximum thickness of the anterior band of IGHL on the humeral and glenoid aspect was

Table 1: Clinical staging of adhesive capsulitis[#]

Clinical stage	Duration of symptoms (months)	Pain	Range of motion	Pathology
I	0-3	Pain with active and passive movements	Normal or minimal loss of ROM	Hypertrophic, hypervascular synovitis
II	3-9	Chronic pain with active and passive movements	Significant limitation of forward flexion, abduction, internal rotation, external rotation	Hypertrophic, hypervascular synovitis with fibrosis, scar formation
III	9-15	Minimal pain except at end of ROM	Significant limitation of ROM with rigid end feel	No significant hypertrophy or hypervascularity. Dense scar formation of the capsule
IV	15-24	Minimal pain	Progressive improvement in ROM	

[#]Clinical staging is adapted from Hannafin, Chiaia (2000) Adhesive capsulitis: A treatment approach. ROM=range of motion

measured on axial fat-suppressed PD images [Figure 2A]. The maximal thickness of the humeral and glenoid portions of the IGHL was measured at the mid-axillary pouch at the level of glenohumeral joint on coronal PD fat-suppressed images [Figure 2B]. The maximal height and width of the axillary pouch was measured at the same level on coronal PD fat-suppressed images [Figure 2D]. The maximal thickness of the coracohumeral ligament was measured on sagittal T1-weighted images [Figure 2C].

Observation and Results

The collected data were analyzed with the IBM SPSS statistics software 23.0 Version. To describe about the data descriptive statistics, frequency analysis and percentage analysis were used for categorical variables and the mean and standard deviation were used for continuous variables. For the multivariate analysis the one-way analysis of variance (ANOVA) with the Tukey's post-hoc test was used. To find the significance in categorical data the Chi-square test was used. In both the above statistical tools the probability value (*P* value) 0.05 is considered as significant level.

Correlations between the MRI findings and the clinical stages are shown in Table 2. Edema on the humeral aspect was present in 100% of the patients in stage I adhesive capsulitis,

88.5% in stage II capsulitis, 5% in stage III capsulitis, and 0% in stage IV. Mild edema was present in 14.3% in stage III and 7.7% in stage IV. The distribution of edema in the different clinical stages was significant (*P* 0.001). Edema on the glenoid aspect was found in 88.9% in stage I, 69.5% in stage II, 9.5% in stage III, and 0% in stage IV. Mild edema was found in 11.5% in stage II and 9.5% in stage III. The distribution of this finding in the different clinical stages was significant (*P* 0.001). The incidence of edema was more common in stages I and II which progressively decreases in stages III and IV. The pericapsular edema on both anterior and posterior aspect was found in 44.4% in stage I, 61.5% in stage II, 9.5% in stage III, and 0% in stage IV. The distribution of this finding in the different clinical stages was significant (*P* 0.001). Highest incidence was found in stages I and II which progressively decreases in stages III and IV.

Effusion around the biceps tendon was found in 100% in stage I, 96.2% in stage II, 81% in stage III, and 61.5% in stage IV. The highest incidence was found in stage I, than in stage II, then decreases in stages III and IV. This distribution was statistically significant (*P* 0.016). Effusion around the biceps tendon was more than the fluid in the axillary pouch which also showed similar distribution with statistical significance of *P* 0.016.

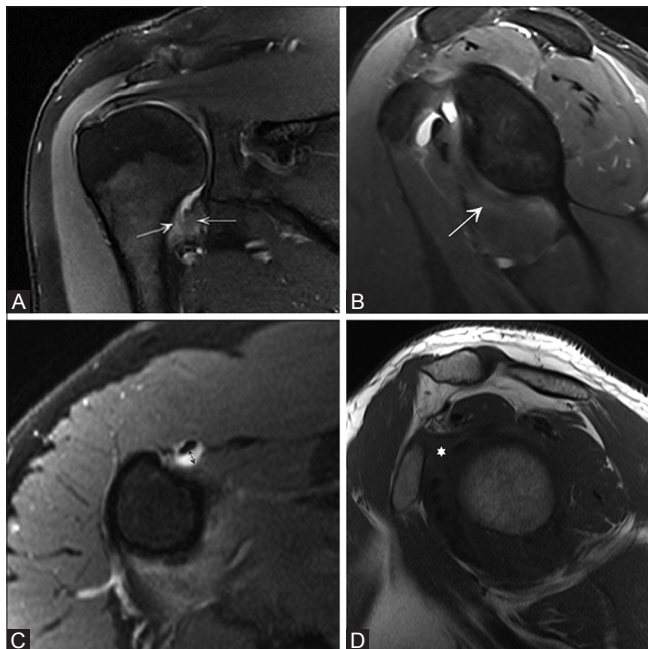


Figure 1(A-D): (A) Coronal fat-suppressed proton density (PD) image at the level of axillary pouch shows edema of inferior glenohumeral ligament on both the humeral and glenoid aspects (arrows). (B) Sagittal fat-suppressed PD image shows anterior pericapsular edema (arrow). (C) Axial fat-suppressed PD image at the level of humeral neck shows fluid around the biceps tendon (arrow). (D) Sagittal T1-weighted image shows obliteration of fat in the subcoracoid triangle (asterisk)

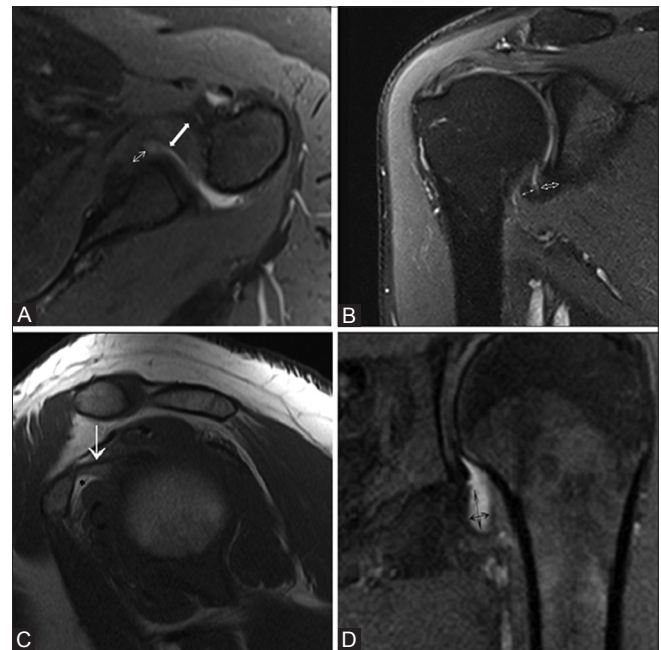

Figure 2(A-D): (A) Axial proton density (PD) fat-suppressed image shows the measurement of maximal thickness of the humeral (solid arrow) and glenoid portions (line arrow) of the anterior band of inferior glenohumeral ligament (IGHL). (B) Coronal PD fat-suppressed image shows the measurement of maximal thickness of the humeral (solid arrow) and glenoid portions (open arrow) of the IGHL at the midaxillary pouch at the level of glenohumeral joint. (C) Sagittal T1-weighted image shows the coracohumeral ligament (arrow). Normal fat in subcoracoid triangle (asterisk). (D) Coronal PD fat-suppressed image shows the measurement of maximal height and width of the axillary pouch

Obliteration of the fat in the subcoracoid triangle was present in 44.4% in stage I, 46.2% in stage II, 90.5% in stage III, and 84.6% in stage IV. This distribution was significant ($P < 0.005$). Highest incidence was found in stage III than in stage IV. Obliteration of the fat outside the subcoracoid triangle was found in 11.1% in stage I, 15.4% in stage II, 42.9% in stage III, and 69.2% in stage IV. This was significantly more common in stages III and IV ($P < 0.010$). The obliteration of fat in the subcoracoid triangle showed more statistical significance than the obliteration of fat outside the subcoracoid triangle.

The thickness of the anterior band of the IGHL differed significantly ($P < 0.001$) between stage I (4.5 ± 0.9 mm), stage II (7.6 ± 1.9 mm), stage III (6.4 ± 1.9 mm), and stage IV (5.2 ± 1.3 mm) on the humeral aspect and stage I (4.5 ± 0.9 mm), stage II (6.7 ± 1.3 mm), stage III (5.4 ± 1.5 mm), and stage IV (4.9 ± 1.2 mm) on the glenoid aspect ($P < 0.001$). The thickness on the humeral side showed more significant correlation with the clinical stage than on the glenoid side. The thickness of the IGHL at the axillary pouch on the humeral aspect also showed significant ($P < 0.001$) variation between the stage I (4.1 ± 0.8 mm),

stage II (5.2 ± 1.2 mm), stage III (4.4 ± 0.8 mm), and stage IV (4.3 ± 0.9 mm). The thickness of the anterior band on the humeral side showed more significant variation with the clinical stages than the thickness of the axillary pouch. On comparison of the thickness of anterior band on humeral side between the stages [Table 3], there was a significant variation between stages I and II ($P < 0.001$), stages III and stage IV ($P < 0.005$).

The age of the patient, thickness of the axillary pouch on the glenoid aspect, height and width of the axillary pouch, and thickness of the coracohumeral ligament did not show any significant variation between the stages.

Discussion

Adhesive capsulitis is characterized clinically by pain and significant loss of ROM in the shoulder.^[6] There are two types: primary adhesive capsulitis and secondary adhesive capsulitis. Primary adhesive capsulitis is an idiopathic condition. It is common in females >40 years of age. Risk factors include thyroid disease and diabetes. Causes for

Table 2: Correlation between MRI parameters and clinical staging in patients with adhesive capsulitis

MRI parameter	Stage 1		Stage 2		Stage 3		Stage 4		P#
	No. of patients	%	No. of patients	%	No. of patients	%	No. of patients	%	
Quantitative data									
Edema of ighl									
Humeral aspect	9	100	23	88.5	5	23.8	0	0	0.001
Glenoid aspect	8	88.9	18	69.2	2	9.5	0	0	0.001
Pericapsular edema									
Anterior and posterior	4	44.4	16	61.5	2	9.5	0	0	0.001
Anterior	4	44.4	7	26.9	10	47.6	1	7.7	0.001
Effusion around the biceps tendon	9	100	25	96.2	17	81	8	61.5	0.016
Fluid around biceps tendon > fluid in axillary pouch	9	100	25	96.2	17	81	8	61.5	0.016
Obliteration of fat in the subcoracoid triangle	4	44.4	12	46.2	19	90.5	11	85.6	0.005
Obliteration of fat outside the subcoracoid triangle	1	11.1	4	15.4	9	42.9	9	69.2	0.010
Qualitative data									
	Mean + SD (standard deviation)								P (Chi-square test)
Thickness of anterior band of ighl									
Humeral aspect	4.5±0.91		7.6±1.92		6.4±1.91		5.2±1.30		0.001
Glenoid aspect	4.5±0.98		6.7±1.34		5.4±1.51		4.9±1.22		0.001
Thickness of axillary pouch									
Humeral aspect	4.1±0.82		6.1±1.60		5.2±1.66		4.6±0.94		0.001
Glenoid aspect	4.1±0.81		5.2±1.47		4.4±0.84		4.3±0.99		0.031
Height of the axillary pouch	6.8±2.04		6.6±2.19		6.4±2.69		7.7±2.55		0.218
Width of the axillary pouch	1.6±0.80		2.1±0.78		2.0±1.17		2.7±2.19		0.484
Thickness of the coracohumeral ligament	1.6±0.49		2±0.69		2.1±0.92		1.8±0.84		0.405

$P < 0.05$ is considered as significant. IGHL=inferior glenohumeral ligament; MRI=magnetic resonance imaging; ANOVA=analysis of variance

Table 3: Interstage comparison of significant continuous variables

MRI parameter	Stage 1			Stage 2			Stage 3			Stage 4		
	2	3	4	1	3	4	1	2	4	1	2	3
Thickness of anterior band on humeral aspect	0.001	0.079	0.833	0.001	0.232	0.005	0.079	0.232	0.312	0.833	0.005	0.312
Thickness of anterior band on glenoid aspect	0.002	0.421	0.913	0.002	0.035	0.006	0.421	0.035	0.783	0.913	0.006	0.783
Thickness of axillary pouch on humeral aspect	0.003	0.221	0.857	0.003	0.165	0.016	0.221	0.165	0.618	0.857	0.016	0.618

P - Tukey's post-hoc test

secondary adhesive capsulitis include trauma and previous surgeries.^[6] The pathophysiological mechanism of adhesive capsulitis is not clear. During the early stages, there is considerable pain caused by hypertrophic hypervascular synovitis with ongoing process of fibrosis. During the later stages, the inflammation decreases and the fibrosis of the joint capsule reaches its peak.^[7,8]

The treatment protocol for adhesive capsulitis depends on the clinical stage. Therefore, accurate diagnosis and identification of the various stages of adhesive capsulitis affects the treatment and ultimately shortens the clinical course.^[9]

Many studies have been previously done on correlation between the MR findings and clinical findings of adhesive capsulitis which only compare the MR findings with the clinical findings. In our study, we have aimed to propose an imaging-based staging system.

Gondim Teixeira *et al.*^[10] reported that edema at the axillary recess is a good diagnostic tool for adhesive capsulitis. Park *et al.*^[11] have studied the correlation between MR findings and clinical findings of adhesive capsulitis and reported that anterior extracapsular edema and joint capsule edema in the humeral portion of the axillary recess are related to ROM. However, the anterior band thickness was not considered. In our study, we found that incidence of edema was significantly more common in stages I and II which progressively decreases in stages III and IV.

Sofka *et al.*^[12] reported that joint capsule thickness in the axillary recess correlates with clinical stage and that joint capsule edema in the axillary recess is common in stage 2. In our study, there is a significant correlation between the degree of thickness of the anterior band of IGHL on the humeral aspect and the clinical stage. The normal range was determined to be 2.9 mm or less.^[13] The mean range in stage I patients is 4.5 ± 0.9 mm. This increases to 7.6 ± 1.9 mm in stage II, reflecting the hypertrophic synovitis which is most predominant at this stage. It again decreases to 6.4 ± 1.9 mm which corresponds to the decrease in inflammatory process and initiation of the fibrotic process in stage III. In stage IV, it comes down to 5.2 ± 1.3 mm which reflects the capsular fibrosis and scar formation in stage IV. The thickness of the anterior band of IGHL on the glenoid aspect and thickness of IGHL at the axillary pouch showed similar variations with the clinical stages but the thickness of the anterior band of IGHL on the humeral aspect showed most significant variation between the stages I and II and stages III and IV. Effusion around the biceps tendon was more than the fluid in the axillary pouch in all the patients with the highest incidence seen in stages I and II.

Ahn *et al.*^[14] reported that the thickness of the joint capsule in the axillary pouch correlates with pain and ROM in patients

with adhesive capsulitis. Lee *et al.* found no correlation between the capsule thickness and ROM. This may be due to the difference in the measurement methods. In both these studies, only the thickness at the axillary pouch was measured. In our study, thickness of anterior band of the IGHL was measured which showed more significant correlation with the clinical stages than the thickness of the axillary pouch by Ahn *et al.*

Lee *et al.*^[15] and Ahn *et al.*^[14] reported no association between obliteration of the fat in the subcoracoid triangle and clinical impairment. However, we found that this finding was more common in stages III and IV which is related to the fibrosis in the late stages of capsulitis. We believe that this difference was mainly because in previous studies, signal changes in the subcoracoid fat triangle on PD fat-suppressed images were taken as significant. In our study, obliteration of fat on T1 images was assessed which reflected the true fibrosis. Obliteration of fat outside the subcoracoid triangle was also found more frequently in stages III and IV which relates to the ongoing fibrosis and scar formation.

Li *et al.*^[16] reported that thickened coracohumeral ligament is highly suggestive of adhesive capsulitis. Kerimoglu *et al.*^[17] reported that coracohumeral ligament thickness did not correlate with the restriction of ROM in patients with adhesive capsulitis. In accordance with that, we found that thickness of the coracohumeral ligament did not show any significant variation between the different clinical stages of capsulitis.

In the previous studies, only the thickening of the axillary pouch was described in cases of adhesive capsulitis for assessment of capsule thickness. In our study, the findings which showed significant correlation with clinical staging are:

The thickness of anterior band of IGHL on humeral side which is more in early stages (stage II > stage I) and decreased in late stages (stage III > stage IV). There is a significant difference of thickness between stage I vs. stage II (P 0.001) and stage III vs. stage IV (P 0.005).

Obliteration of fat in the subcoracoid triangle which was observed in stages III and IV. Distribution of edema of the IGHL and anterior and posterior pericapsular edema (more in stages I and II, less in stage III, and nil in stage IV) also significantly correlated with the clinical stages.

Based on the correlation between MR findings and clinical staging, we propose a MR staging of adhesive capsulitis [Table 4]. The thickness of anterior band of IGHL on humeral side in range of 4.5 ± 0.9 mm with no obliteration of fat in the subcoracoid triangle seen in

Table 4: Proposed MR staging of adhesive capsulitis

Stages	MRI parameters
Stage 1	Thickness of anterior band of IGHL – 4.5 ± 0.9 mm Edema of IGHL on humeral and glenoid aspect Pericapsular edema on anterior and posterior aspect No significant obliteration of fat in the subcoracoid triangle
Stage 2	Thickness of anterior band of IGHL – 7.6 ± 1.9 mm Edema of IGHL on humeral and glenoid aspect Pericapsular edema on anterior and posterior aspect No significant obliteration of fat in the subcoracoid triangle
Stage 3	Thickness of anterior band of IGHL – 6.4 ± 1.9 mm Mild edema of IGHL on humeral and glenoid aspect Pericapsular edema on anterior and posterior aspect Obliteration of fat in the subcoracoid triangle
Stage 4	Thickness of anterior band of IGHL – 5.2 ± 1.3 mm No edema of IGHL on humeral and glenoid aspect No pericapsular edema on anterior and posterior aspect Obliteration of fat in the subcoracoid triangle

stage I and thickness of anterior band of IGHL on humeral side in range of 7.6 ± 1.9 mm with no obliteration of fat in subcoracoid triangle seen in stage II. Obliteration of fat in subcoracoid triangle with mild edema of IGHL is seen in stage III and obliteration of fat in subcoracoid triangle with no edema of IGHL is seen in stage IV. Other variables which are useful for diagnosis of adhesive capsulitis but are stage non-specific includes effusion around the biceps tendon, fluid around the biceps tendon in comparison with fluid in axillary pouch, and reduction in the height and width of axillary pouch.

Limitation of our study is that the progression of the disease in all patients could not be followed up due to ongoing treatment.

Conclusion

MRI is a useful tool for evaluation and prediction of clinical stage of adhesive capsulitis. We believe that imaging-based grading system can aid in the diagnosis of various stages of the disease even when the clinical manifestations are subtle. This helps in the initiation of appropriate treatment to halt the disease progression, prevent the complications, and avoid invasive treatment procedures.

Financial support and sponsorship

Nil.

Conflicts of interest

There are no conflicts of interest.

References

- Codman EA. Tendinitis of the Short Rotators in the Shoulder: Rupture of the Supraspinatus Tendon and other Lesions in or about the Subacromial Bursa. Boston, MA: Thomas Todd and Company; 1934.
- Neviaser J. Adhesive capsulitis of the shoulder: Study of pathologic findings in peri-arthritis of the shoulder. J Bone Joint Surg 1945;27:211-22.
- Ozaki J, Nakagawa Y, Sakurai G, Tamai S. Recalcitrant chronic adhesive capsulitis of the shoulder. Role of contracture of the coracohumeral ligament and rotator interval in pathogenesis and treatment. J Bone Joint Surg Am 1989;71:1511-5.
- Dias R, Cutts S, Massoud S. Frozen shoulder. BMJ 2005;331:1453-56.
- Hannafin JA, Chiaia TA. Adhesive capsulitis: A treatment approach. Clin Orthop 2000;372:95-109.
- Neviaser TJ. Adhesive capsulitis. In: McGinty JB, Caspari RB, Jackson RW, Poehling GG, editors. Operative Arthroscopy, 2nd ed. Philadelphia: Lippincott-Raven; 1996.
- Rodeo SA, Hannafin JA, Tom J, Warren RF, Wickiewicz TL. Immunolocalization of cytokines and their receptors in adhesive capsulitis of the shoulder. J Orthop Res 1997;15:427-36.
- Grey RG. Brief note. The natural history of "idiopathic" frozen shoulder. J Bone Joint Surg Am 1978;60-A: 564.
- Griggs SM, Ahn A, Green A. Idiopathic adhesive capsulitis. A prospective functional outcome study of nonoperative treatment. J Bone Joint Surg Am 2000;82-A: 1398-407.
- Gondim Teixeira PA, Balaj C, Chanson A, Lecocq S, Louis M, Blum A. Adhesive capsulitis of the shoulder: Value of inferior glenohumeral ligament signal changes on T2-weighted fat-saturated images. AJR Am J Roentgenol 2012;198:W589-96.
- Park S, Lee D-H, Yoon S-H, Lee HY, Kwack K-S. Evaluation of adhesive capsulitis of the shoulder with fat-suppressed T2-Weighted MRI: Association between clinical features and MRI findings. AJR Am J Roentgenol 2016;207:135-41.
- Sofka CM, Ciavarrá GA, Hannafin JA, Cordasco FA, Potter HG. Magnetic resonance imaging of adhesive capsulitis: Correlation with clinical staging. HSS J 2008;4:164-9.
- Emig EW, Schweitzer ME, Karasick D, Lubowitz J. Adhesive capsulitis of the shoulder: MRI diagnosis. Am J Roentgenol 1995;164:145.
- Ahn KS, Kang CH, Oh YW, Jeong WK. Correlation between magnetic resonance imaging and clinical impairment in patients with adhesive capsulitis. Skeletal Radiol 2012;41:1301-08.
- Lee SY, Park J, Song SW. Correlation of MR arthrographic findings and range of shoulder motions in patients with frozen shoulder. AJR Am J Roentgenol 2012;198:173-9.
- Li JQ, Tang KL, Wang J, Li QY, Xu HT, Yang HF, et al. MRI findings for frozen shoulder evaluation: Is the thickness of the coracohumeral ligament a valuable diagnostic tool? PLoS One 2011;6:e28704.
- Kerimoglu U, Aydingoz U, Atay OA, Ergen FB, Kirkpantur A, Arici M. Magnetic resonance imaging of the rotator interval in patients on long term haemodialysis: Correlation with the range of shoulder motions. J Comput Assist Tomogr 2007;31:970-5.