



Endothelial dysfunction and hypercoagulability in severe sickle-cell acute chest syndrome

Etienne-Marie Jutant ¹, Guillaume Voiriot^{1,2}, Vincent Labbé^{1,2}, Laurent Savale ^{3,4,5}, Hayat Mokrani^{2,6,7}, Patrick Van Dreden⁸, Grigorios Gerotziafas^{2,6,7} and Muriel Fartoukh^{1,2}

¹Service de Médecine Intensive Réanimation, Département Médico-Universitaire APPROCHES, Hôpital Tenon, Assistance Publique-Hôpitaux de Paris (AP-HP), Paris, France. ²Faculté de Médecine, Sorbonne Université, Paris, France. ³Université Paris-Saclay, School of Medicine, Le Kremlin-Bicêtre, France. ⁴INSERM UMR_S 999 “Pulmonary Hypertension: Pathophysiology and Novel Therapies”, Hôpital Marie Lannelongue, Le Plessis-Robinson, France. ⁵Assistance Publique – Hôpitaux de Paris (AP-HP), Dept of Respiratory and Intensive Care Medicine, Pulmonary Hypertension National Referral Center, Hôpital Bicêtre, Le Kremlin-Bicêtre, France. ⁶Research group “Cancer, Haemostasis and Angiogenesis”, INSERM U938, Centre de Recherche Saint-Antoine, Institut Universitaire de Cancérologie, Paris, France. ⁷Service d’Hématologie Biologique Hôpital Tenon, Hôpitaux Universitaires de l’Est Parisien, AP-HP, Paris, France. ⁸Clinical Research Dept, Diagnostica Stago, Gennevilliers, France.

Corresponding author: Muriel Fartoukh (muriel.fartoukh@aphp.fr)



Shareable abstract (@ERSpublications)

Severe sickle-cell acute chest syndrome is associated with an activation of the pulmonary vascular endothelium and of coagulation, with higher levels of pro-coagulant microparticles in cases of associated acute pulmonary hypertension <https://bit.ly/3sjkaYy>

Cite this article as: Jutant E-M, Voiriot G, Labbé V, *et al.* Endothelial dysfunction and hypercoagulability in severe sickle-cell acute chest syndrome. *ERJ Open Res* 2021; 7: 00496-2021 [DOI: 10.1183/23120541.00496-2021].

Copyright ©The authors 2021

This version is distributed under the terms of the Creative Commons Attribution Non-Commercial Licence 4.0. For commercial reproduction rights and permissions contact permissions@ersnet.org

This article has supplementary material available from openres.ersjournals.com

Received: 5 Aug 2021
Accepted: 5 Aug 2021

Abstract

Rationale Acute pulmonary hypertension (PH) may develop during sickle-cell acute chest syndrome (ACS), and is associated with an increased mortality. Its mechanisms remain poorly known. We questioned whether there is endothelial dysfunction and hypercoagulability in severe ACS, with and without acute PH.

Methods In a prospective monocentre cohort follow-up study, all sickle-cell adult patients with ACS admitted to the intensive care unit underwent transthoracic echocardiography and measurement of biomarkers of coagulation, endothelial activation and platelet and erythrocyte activation. Acute PH was defined as a high echocardiographic probability of PH. The biological profiles of sickle-cell patients were analysed at the time of ACS, contrasting with the existence of acute PH, and compared with steady-state and with non-sickle-cell controls (healthy subjects and community-acquired pneumonia).

Results Most patients (36 patients with 39 ACS episodes; 23 males; median age 27 years) had thoracic pain, dyspnoea and computed tomography scan lung consolidation. Acute PH was diagnosed in seven (19%) patients. Erythrocyte- and platelet-derived microparticles and the pro-coagulant activity of microparticles were higher in ACS patients with acute PH, compared with their counterparts. Compared with healthy controls, ACS patients had higher levels of tissue factor, fibrin monomers, D-dimer, release of pro-coagulant microparticles and erythrocyte- and platelet-derived microparticles. Compared with community-acquired pneumonia patients, ACS patients had increased levels of fibrin monomers and erythrocyte- and platelet-derived microparticles.

Conclusions Severe ACS is characterised by endothelial dysfunction and hypercoagulability, with a marked pro-coagulant profile in cases of associated PH.

Introduction

Sickle-cell disease is one of the most common autosomal recessive genetic disorders, affecting 300 000 newborns worldwide each year [1, 2]. Sickle-cell disease is caused by a point mutation of the gene coding for the β -globin chain of haemoglobin, substituting a glutamic acid with a valine, and resulting in the production of sickle haemoglobin (HbS), which polymerises when deoxygenated, resulting in red-cell sickling, chronic haemolytic anaemia and vaso-occlusion [3]. This life-threatening disease presents very variable faces, and is associated with a reduction in life expectancy of ~30 years [1]. Among acute complications, the acute chest syndrome (ACS) is one of the leading causes of death [4]. This syndrome is



characterised as the combination of chest pain, fever, leukocytosis and new radiological infiltrates [5]. It may result from several causes (lower respiratory tract infection, fatty embolism, pulmonary infarction) that lead to regional alveolar hypoventilation and HbS polymerisation [4, 6]. The clinical expression of ACS is heterogeneous, ranging from a “simple form” requiring hospitalisation to acute respiratory distress syndrome (ARDS) [7]. Acute pulmonary hypertension (PH) is one of the markers of ACS severity [8]. The mechanisms of acute PH in ACS are incompletely understood and may be multiple [9–11]. However, pulmonary vascular endothelium function and the coagulation pathway have not been assessed in ACS. The question was to assess whether there is endothelial dysfunction and a hypercoagulability state in severe ACS, with and without acute PH.

Material and methods

Patients and study design

Sickle-cell patients

A prospective monocentre cohort follow-up was conducted in the intensive care unit (ICU) of Tenon Hospital (Paris, France), a referral centre for sickle-cell disease. All adult sickle-cell patients admitted to the ICU from November 2015 to May 2017 with a diagnosis of ACS were included. Pregnant or breastfeeding women, patients with a known chronic PH (mean pulmonary arterial pressure ≥ 25 mmHg at rest measured by right cardiac catheterisation) or a known systolic or diastolic heart failure, and those transfused in the four preceding months were excluded. The diagnosis of ACS was established in cases of fever or chest pain in combination with a new radiological infiltrate of at least one lung segment [8]. Patients were followed-up until a medical visit at steady state, ≥ 3 months after the index ACS episode (from May 2016 to April 2018). Adapted from BALLAS [12], the steady state was defined by a point in time where the patient was not experiencing an acute painful crisis, ≥ 3 months after the ACS with no history of an acute painful episode, of intercurrent illness such as infection and inflammation and no need for antibiotics during the previous 4 weeks and no need for transfusion since the ACS episode. When a patient had several episodes of ACS, only one visit at steady state was performed.

Control populations

Clinical and biological data of patients with severe community-acquired pneumonia (CAP) and healthy volunteers (medical students or members of the medical or laboratory staff, without medical history) were used as control populations.

Characteristics at diagnosis, data recording and outcomes

The following data were collected on ICU admission, after patient-centred interview and medical chart analysis: demographics, sickle-cell disease baseline characteristics, past medical history and comorbidities, chronic treatments and ACS characteristics. Conventional laboratory tests included blood count, liver and kidney functions, fibrinogen and lactate dehydrogenase (LDH). Specialised biology focused on the coagulation pathway, the pulmonary vascular endothelium function and the platelet and erythrocyte activation. The coagulation pathway was assessed on the measurement of *in vivo* thrombin generation marker (fibrin monomers), fibrinolysis debris (D-dimers) and a test for the release of pro-coagulant microparticles (Procoag-PPL) (supplementary methods). The vascular endothelium function was assessed on the dosage of tissue factor (supplementary methods). Platelet and erythrocyte activation was assessed on the measurement of erythrocyte and platelet-derived microparticles, using a flow cytometry assay, as described previously [13].

Computed tomography (CT) angiography of the chest findings included the presence of alveolar consolidation, ground-glass opacity, pleural effusion and pulmonary embolism (proximal, segmental or subsegmental), as well as pulmonary artery to ascending aorta diameter ratio (PA/A) and the right-to-left ventricular diameter ratio. Transthoracic echocardiography (TTE) was performed at inclusion by the same skilled cardiologist (V. Labbé), blinded to the results of the specialised biology measurements (supplementary methods). The echocardiographic probability of acute PH was classified as low, intermediate or high, on the basis of the echocardiographic signs (peak tricuspid regurgitation velocity (PTRV) and other echo PH signs) used to assess the probability of chronic PH [14] (supplementary tables S1 and S2). As echocardiographic evaluation has a low positive predictive value for PH in sickle-cell disease [15], and to be confident in the diagnosis of acute PH, acute PH was defined when there was a high echocardiographic probability of PH.

The use of mechanical ventilation, blood products transfusion and antimicrobial therapy, as well as ICU and hospital lengths of stay and corresponding vital status were recorded. When possible, patients had a follow-up medical visit at steady state, ≥ 3 months after the index ACS episode, with repeated specialised biology and TTE.

Ethics consideration

The institutional review board for human studies approved the experiments for the sickle-cell patients and for healthy and pneumonia controls (reference number 15020 and number 16143, Comité de Protection des Personnes Ile de France V) and all the subjects provided written informed consent. After inclusion, all data regarding the clinical status, main outcomes, biological and radiological features were recorded in an anonymous database registered to the National Commission on Informatics and Liberty (number 1852665).

Statistical analysis

Quantitative data were expressed as median (interquartile range (IQR), presented as first quartile–third quartile). Qualitative data were expressed as number of occurrences, n (%). In patients with several episodes of ACS, each episode was considered individually, but the patient's characteristics were considered once. Patients were separated into two groups, according to their echocardiographic profiles, as follows: low-to-intermediate probability of PH and high probability of PH. Acute PH was defined when there was a high echocardiographic probability of PH. Groups were compared using the nonparametric Mann–Whitney U-test or the Kruskal–Wallis test with Dunn's multiple comparisons test for continuous variables, and Fisher's exact test for categorical variables. Within-group comparisons were performed using the Wilcoxon matched-pair signed rank test.

Differences were considered significant when $p < 0.05$. Analyses were performed using GraphPad Prism v8.0 (La Jolla, CA, USA).

Results

Clinical characteristics of patients on ICU admission

During the study period, 82 sickle-cell disease patients (90 episodes) were admitted to the ICU for the management of ACS. Of those, 36 patients (39 ACS episodes) were included (figure 1). Most patients (64% males, median age 27 years, IQR 22–31 years) had homozygous sickle-cell disease and had already experienced an episode of ACS. The most frequent chronic complications were biliary lithiasis and retinopathy. Two-thirds of the patients were treated with hydroxyurea (table 1). The median (IQR) time from ACS symptom onset to ICU admission was 3 (1–7) days. The majority of patients presented with

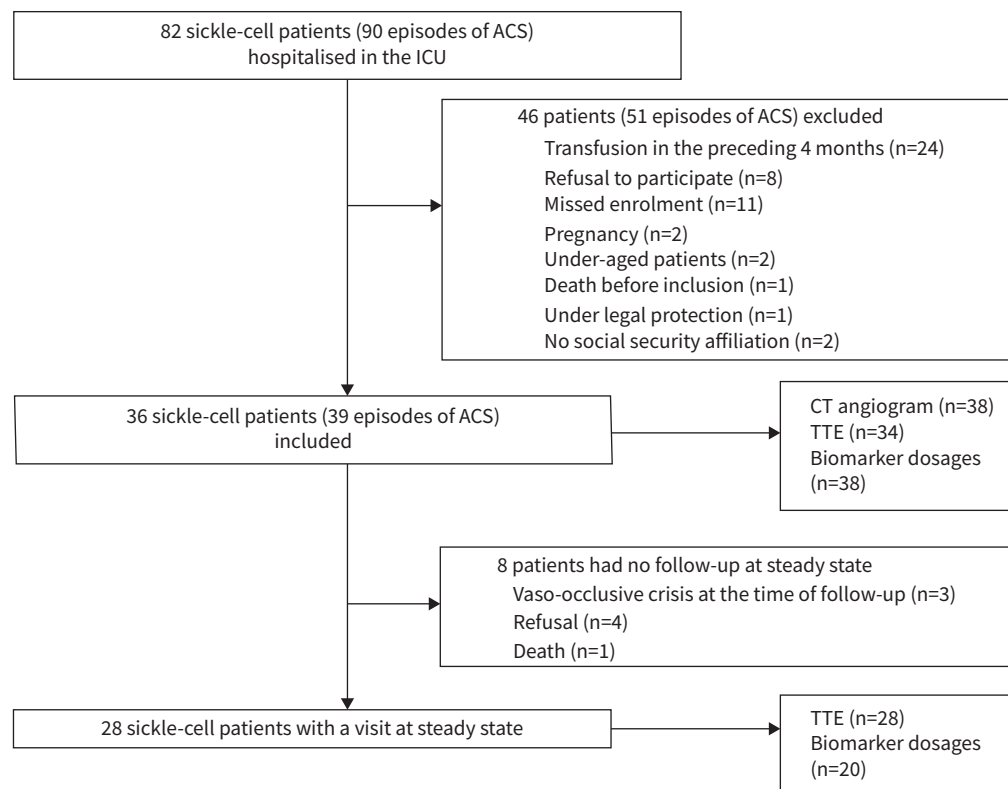


FIGURE 1 Flow chart of the study. ACS: acute chest syndrome; ICU: intensive care unit; CT: computed tomography; TTE: transthoracic echocardiography.

TABLE 1 Baseline characteristics of the patients included in the study

| | |
|---|------------------|
| Patients | 36 |
| Age, years | 27 (22–31) |
| Male/female (ratio) | 23/13 (1.8) |
| BMI, kg·m⁻² | 21.5 (19.6–24.1) |
| Smoker or ex-smoker | 7 (20) |
| Ethnicity | |
| Sub-Saharan Africa | 27 (75) |
| Caribbean | 6 (17) |
| Other | 3 (8) |
| Sickle-cell disease characteristics | |
| Genotype | |
| SS | 34 (94) |
| SC | 1 (3) |
| S β-thalassaemia | 1 (3) |
| Baseline haemoglobin, g·dL ⁻¹ | 8.8 (8.0–9.5) |
| History of acute complications | |
| Vaso-occlusive crisis | 36 (100) |
| Acute chest syndrome | 31 (86) |
| Healthcare consumption in the preceding year | |
| Emergency room | 2 (1–5) |
| Hospitalisation in conventional ward | 2 (1–4) |
| Hospitalisation in ICU | 0 (0–1) |
| Chronic complications | |
| Proteinuria | 9 (25) |
| Chronic renal insufficiency | 0 (0) |
| Retinopathy | 18 (50) |
| Biliary lithiasis | 23 (64) |
| Cholecystectomy | 20 (56) |
| Splenectomy | 3 (8) |
| Bone complications [#] | 13 (36) |
| Leg ulcers | 1 (3) |
| Chronic treatments | |
| Hydroxyurea | 24 (67) |
| Chronic exchange transfusions | 0 (0) |
| Data are presented as n, median (interquartile range) or n (%). BMI: body mass index; ICU: intensive care unit. #: osteonecrosis, arthrosis and osteomyelitis. | |

thoracic pain and dyspnoea, but only one-third of them had fever (table 2). All patients needed oxygen therapy, at a median (IQR) level of 4 (2–5) L·min⁻¹. Baseline characteristics of the control populations are detailed in supplementary table S3.

Biology on ICU admission

Leukocytosis and hyperfibrinogenaemia were frequent and associated with a marked haemolysis. There was no thrombopenia, but the platelet count remained normal (table 2). As compared with healthy controls, specialised biomarkers were suggestive of a hypercoagulability (increase in the levels of fibrin monomers and D-dimers, and in the release of pro-coagulant microparticles, as assessed by a shorter time of anticoagulation in the Procoag-PPL test), as well as of an activated pulmonary vascular endothelium (increase in the level of tissue factor) in ACS patients. Erythrocyte and platelet-derived microparticles were also higher in ACS patients than in healthy controls (figure 2). As compared with severe CAP controls, specialised biomarkers were highly suggestive of a hypercoagulability state (increase in the levels of fibrin monomers) and of platelet and erythrocyte activation (increase in the levels of erythrocyte- and platelet-derived microparticles) in ACS patients (figure 2).

Radiology on ICU admission

All patients except one underwent a chest CT scan. Lung consolidation was the most frequent pattern (92% of cases), and lesions predominated in inferior lobes in all cases. CT pulmonary angiography was performed in 37 patients, demonstrating an acute pulmonary embolism in two patients (one segmental and one subsegmental), one of whom had golden sputum and an associated acute PH. A leg Doppler ultrasound was realised in the two patients with pulmonary embolism, excluding deep vein thrombosis. The PA/A diameter ratio was enlarged in 42% of cases, but the right ventricle was not dilated. The injection quality was

TABLE 2 Characteristics of the acute chest syndrome

| | Available data | All patients (n=39) |
|--|----------------|---------------------|
| Clinics | | |
| Time from symptom onset to ICU referral, days | 39 | 3 (1–7) |
| Thoracic pain | 39 | 34 (87) |
| Cough | 39 | 17 (44) |
| Dyspnoea | 39 | 29 (74) |
| Golden sputum | 39 | 14 (36) |
| Fever | 39 | 12 (31) |
| Limb pain | 39 | 26 (67) |
| Systolic blood pressure, mmHg | 39 | 122 (117–135) |
| Diastolic blood pressure, mmHg | 39 | 72 (67–84) |
| Heart rate, beats·min ⁻¹ | 39 | 104 (92–117) |
| Temperature, °C | 39 | 37.2 (36.9–38.1) |
| Respiratory rate, breaths·min ⁻¹ | 28 | 26 (21–30) |
| Crepitation | 39 | 24 (62) |
| Tubal breath | 39 | 7 (18) |
| Biology | | |
| Haemoglobin, g·dL ⁻¹ | 39 | 7.5 (6.3–8.5) |
| Platelets, cells·mm ⁻³ | 39 | 270 (200–391) |
| Leukocytes, cells·mm ⁻³ | 39 | 17.1 (14.5–20.6) |
| Neutrophils, cells·mm ⁻³ | 39 | 12.6 (10.0–15.2) |
| Reticulocytes, cells·mm ⁻³ | 39 | 272 (180–335) |
| Total bilirubin, µmol·L ⁻¹ | 39 | 51 (36–69) |
| LDH, IU·L ⁻¹ | 39 | 542 (414–882) |
| Fibrinogen, g·L ⁻¹ | 33 | 4.4 (3.8–5.7) |
| Microbiological documentation | | |
| MSSA | 39 | 6 (15) |
| <i>Streptococcus pneumoniae</i> | 39 | 2 (5) |
| Respiratory virus | 39 | 3 (8) |
| HRCT data | | |
| Alveolar consolidation | 38 | 35 (92) |
| Ground glass opacity | 38 | 11 (29) |
| Pleural effusion | 38 | 7 (18) |
| Pulmonary embolism | 38 | 2 (5) |
| PA:A ratio >1 | 38 | 16 (42) |
| RV:LV ratio >1 | 38 | 0 (0) |
| Data are presented as n, median (interquartile range) or n (%). ICU: intensive care unit; LDH: lactate dehydrogenase; MSSA: methicillin-sensitive <i>Staphylococcus aureus</i> ; HRCT: high-resolution computed tomography; PA:A ratio: pulmonary artery to ascending aorta diameter ratio; RV:LV ratio: right ventricular to left ventricular diameter ratio. | | |

suboptimal in 19 examinations, not allowing the search for segmental and subsegmental pulmonary embolism in those latter exams. Figure 3 shows typical CT scans in four included patients.

Echocardiography on ICU admission

TTE was performed in 34 patients. There was no evidence of left or right ventricular dysfunction, and no right ventricle dilation. A high probability of acute PH was diagnosed in seven patients, on the following criteria: PTRV ≥ 3.4 m·s⁻¹ (n=2), PTRV 2.8–3.4 m·s⁻¹ in association with right ventricular outflow Doppler acceleration time <105 ms (n=4) or with early diastolic pulmonary regurgitation velocity >2.2 m·s⁻¹ (n=1). Intermediate and low probabilities of PH were documented in 13 patients and 14 patients, respectively (supplementary table S4). Patients were separated into two groups, according to their echocardiographic profiles, as follows: low-to-intermediate probability and high probability of PH, which was considered as acute PH (table 3).

Management and outcomes

All patients received antibiotics during their ICU stay. Bacterial and viral lower respiratory tract infections were diagnosed in eight (21%) patients and three (8%) patients, respectively. Curative anticoagulation was initiated in the two patients diagnosed with pulmonary embolism. One-third of the patients received at least one blood product transfusion during their ICU stay (table 4).

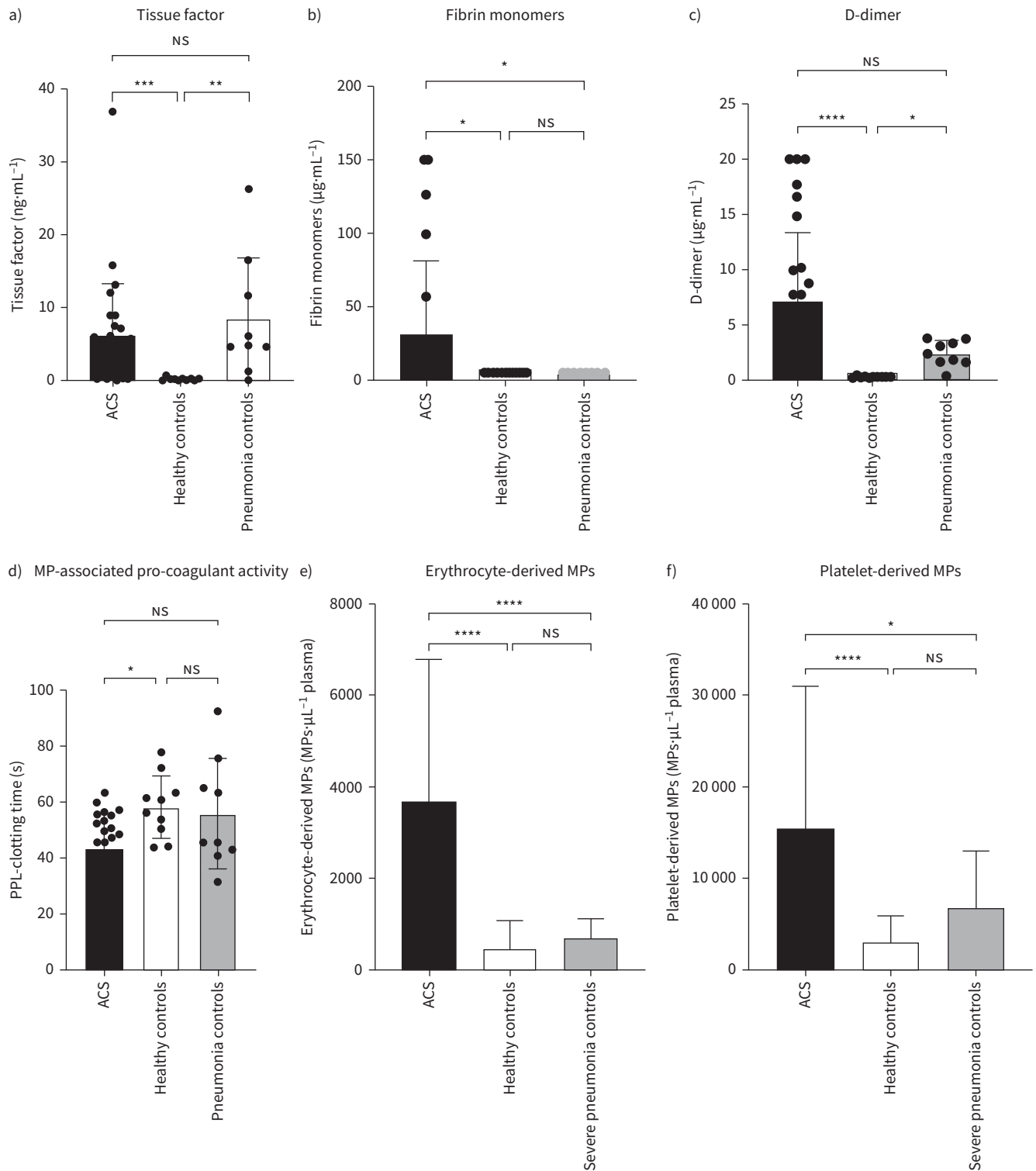


FIGURE 2 Biomarkers of endothelial dysfunction and hypercoagulability state in sickle-cell patients with acute chest syndrome (ACS), as compared with controls. Levels of a) tissue factor, b) fibrin monomers, c) D-dimer, d) pro-coagulant microparticle (MP) activity (pro-coagulant phospholipid (PPL) clotting time; a shorter time is associated with a higher pro-coagulant activity), e) erythrocyte-derived MPs and f) platelet-derived MPs, in ACS patients (n=38) and controls (healthy subjects n=10, patients with severe community-acquired pneumonia n=13). Comparisons were made using the Kruskal–Wallis test with Dunn’s multiple comparisons test. NS: nonsignificant. *: p<0.05; **: p<0.001; ***: p<0.0001; ****: p<0.00001.

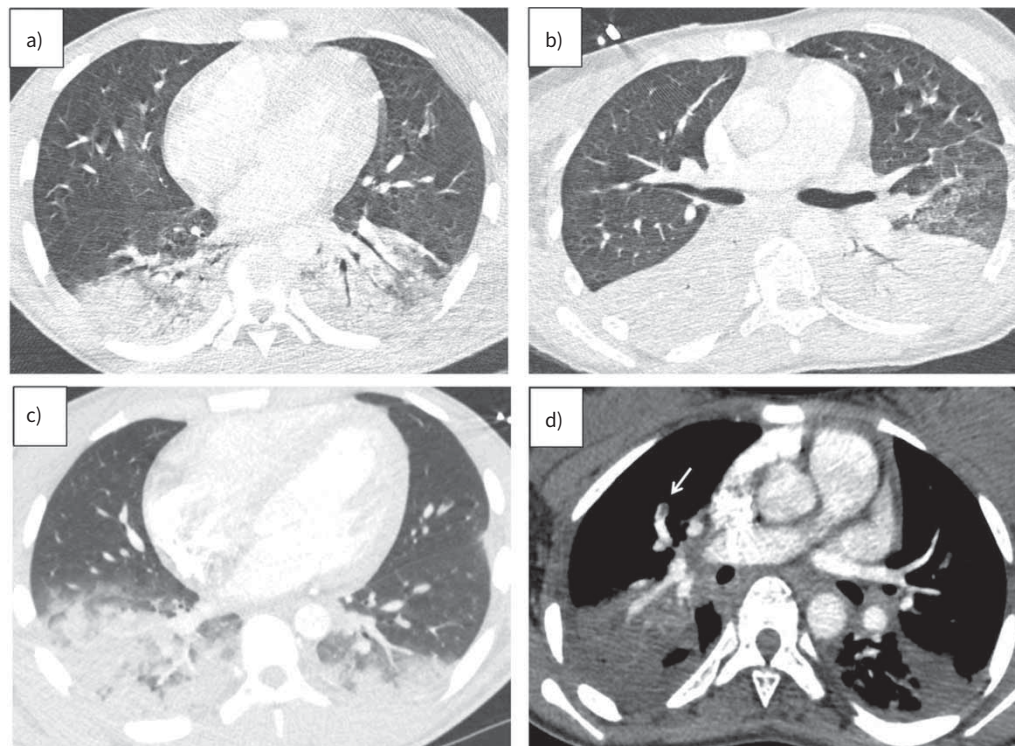


FIGURE 3 Typical high-resolution computed tomography (HRCT) of the chest of patients with severe acute chest syndrome included in the study. **a)** Axial HRCT image of the middle lobe, lingula and lower lobes in a 19-year-old male showing alveolar consolidation with air bronchogram and ground-glass opacities in the lower lobes. **b)** Axial HRCT image of the middle lobe, lingula and lower lobes, in a 26-year-old female showing alveolar consolidation with air bronchogram in the lower lobes. **c)** Axial HRCT image of the middle lobe, lingula and lower lobes in a 19-year-old male showing alveolar consolidation and ground-glass opacities in the lower lobes. **d)** Axial contrast-enhanced HRCT image of the upper lobes in an 18-year-old female showing a segmental pulmonary embolism in the right upper pulmonary artery and alveolar consolidation in the upper lobes.

The course was favourable in most patients, with a decrease in the level of supplemental oxygen at 48 h (table 4). The median (IQR) length of stay in the ICU was 4 (3–5) days. One death occurred, in a 34-year-old man with SS sickle-cell disease with an initial intermediate probability of PH.

Comparisons of patients according to the presence of acute PH

Seven patients had a high echocardiographic probability of acute PH. Compared with their counterparts at baseline, they were more likely to be Caribbean, had less frequent SS disease and less past medical history of ACS (supplementary table S5). At the time of ACS, they required higher levels of supplemental oxygen despite less frequent alveolar CT scan consolidation; they had more frequent lower limb pain; and biological examinations showed a higher platelet count and a lower level of total bilirubin (supplementary table S6). The activity of pro-coagulant microparticles (median (IQR) 35 (29–41) *s* versus 50 (38–56) *s*; $p=0.016$) and the levels of erythrocyte-derived (median (IQR) 7834 (4401–13963) *versus* 3414 (1397–5606) microparticles per μL plasma; $p=0.018$) and platelet-derived (median (IQR) 44686 (16171–53138) *versus* 13956 (9332–24076) microparticles per μL plasma; $p=0.012$) microparticles were higher in ACS patients with high echocardiographic probability of PH, compared with their counterparts (figure 4). However, the levels of tissue factor, fibrin monomers and D-dimer were similar (figure 4). The outcomes of patients are detailed in supplementary table S7, contrasting low-to-intermediate and high probability of PH.

Evaluation at steady state

28 (78%) sickle-cell patients had a follow-up visit at steady state, a median 4.5 months (IQR 3–6 months) after the index episode of ACS. All had returned to their baseline clinical condition. A significant reduction of PTRV from a median $2.8 \text{ m}\cdot\text{s}^{-1}$ (IQR $2.6\text{--}3.0 \text{ m}\cdot\text{s}^{-1}$) to $2.5 \text{ m}\cdot\text{s}^{-1}$ (IQR $2.1\text{--}2.6 \text{ m}\cdot\text{s}^{-1}$)

TABLE 3 Echocardiographic parameters, contrasting low-to-intermediate and high probability of acute pulmonary hypertension (PH)

| | Probability of PH | | p-value |
|---|---------------------|------------------|---------|
| | Low to intermediate | High | |
| Patients | 27 | 7 | |
| Heart rate, beats·min ⁻¹ | 107 (86–113) | 96 (83–117) | 0.90 |
| Left atrial surface, cm ² | 20 (18–24) | 22 (20–26) | 0.33 |
| Right atrial surface, cm ² | 15 (13–17) | 17 (14–20) | 0.23 |
| End-diastolic ventricular area ratio | 0.56 (0.52–0.63) | 0.64 (0.58–0.71) | 0.09 |
| E wave at the mitral level, cm·s ⁻¹ | 94 (79–103) | 106 (84–120) | 0.3 |
| A wave at the mitral level, cm·s ⁻¹ | 68 (57–83) | 68 (49–95) | 0.88 |
| E/A ratio | 1.4 (1.1–1.7) | 1.4 (1.3–1.9) | 0.64 |
| Lateral Ea wave, cm·s ⁻¹ | 17 (15–20) | 16 (15–24) | 0.78 |
| E/Ea ratio | 5.3 (4.2–6.9) | 5.2 (4.7–7.0) | 0.83 |
| LVEF, % | 63 (60–67) | 57 (55–65) | 0.15 |
| Cardiac index, L·min ⁻¹ ·m ⁻² | 3.2 (2.9–3.6) | 3.2 (2.8–4.1) | 0.97 |
| TAPSE, cm | 25 (21–29) | 25 (22–25) | 0.63 |
| Tricuspid annular peak systolic velocity (s'), cm·s ⁻¹ | 17 (15–19) | 19 (14–21) | 0.47 |
| Peak tricuspid regurgitation velocity, m·s ⁻¹ | 2.6 (2.5–2.8) | 3.1 (3.0–3.4) | 0.0001 |
| Right ventricular outflow Doppler acceleration time, s | 113 (94–125) | 91 (81–109) | 0.04 |
| Inferior cava diameter, mm | 11 (8–17) | 16 (14–18) | 0.31 |
| Systolic pulmonary artery pressure, mmHg | 31 (29–37) | 44 (39–51) | 0.0003 |

Data are presented as n or median (interquartile range), unless otherwise stated. LVEF: left ventricular ejection fraction; TAPSE: tricuspid annular plane systolic excursion.

TABLE 4 Treatments and outcomes of the acute chest syndromes

| | Available data | All patients (n=39) |
|---|----------------|---------------------|
| Treatments | | |
| Supplemental oxygen at admission, L·min ⁻¹ | 39 | 4 (2–5) |
| 1–5 L·min ⁻¹ | | 29 (74) |
| >5 L·min ⁻¹ | | 10 (26) |
| Mechanical ventilation | 39 | 1 (3) |
| Antimicrobial therapy | 39 | 39 (100) |
| Blood product transfusion | 39 | 14 (36) |
| Outcomes | | |
| ICU length of stay, days | 39 | 4 (3–5) |
| Hospital length of stay, days | 39 | 10 (7–13) |
| Supplemental oxygen at 48 h from admission | 36 | |
| 0 L·min ⁻¹ | | 3 (8) |
| 1–5 L·min ⁻¹ | | 32 (89) |
| >5 L·min ⁻¹ | | 1 (3) |
| Death [#] | 39 | 1 (3) |

Data are presented as n, median (interquartile range) or n (%). ICU: intensive care unit. #: the patient who died was a 34-year-old male nonsmoker of normal weight (body mass index 18.4 kg·m⁻²), with a history of multiple vaso-occlusive crises and acute chest syndrome (ACS), bone complications and cholecystectomy. He presented at hospital for isolated fever initially, but rapidly developed a meningeal syndrome, signs of ACS (fever, chest pain and dyspnoea with opacities on chest radiography) with 6 L·min⁻¹ need of oxygen, and was referred to the ICU. Large basal consolidations were evidenced on computed tomography scan, without pulmonary embolism. *Streptococcus pneumoniae* was identified in the cerebrospinal fluid, but respiratory tract samples remained sterile. Laboratory findings included a severe central bicytopenia (haemoglobin 4.4 g·dL⁻¹, reticulocytes 20 300 cells·mm⁻³, platelets 91 000 cells·mm⁻³) and high inflammation (leukocytes 35 600 cells·mm⁻³). The patient had an intermediate probability of pulmonary hypertension at initial transthoracic echocardiography. Initial levels of erythrocyte- and platelet-derived microparticles were low (1398 and 1601 microparticles per µL plasma, respectively). Despite antibiotics and transfusion, the patient deteriorated and developed confusion, acute respiratory failure and acute renal failure requiring intubation and dialysis. The signs evolved towards a severe and fatal acute respiratory distress syndrome 6 days after ICU admission.

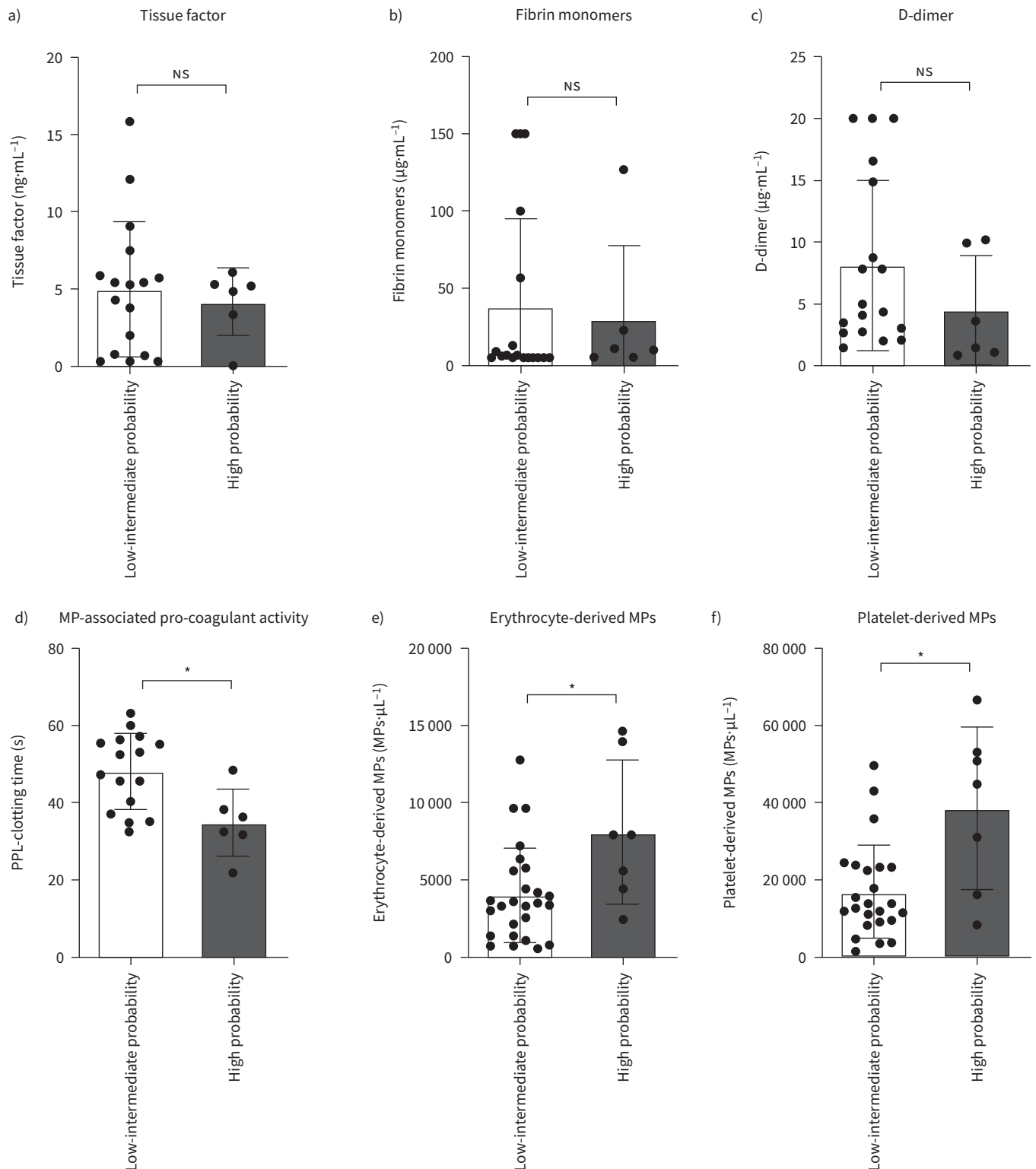


FIGURE 4 Biomarkers of endothelial dysfunction and hypercoagulability state in sickle-cell patients in acute chest syndrome, contrasting low-to-intermediate (n=27) and high (n=7) probability of acute pulmonary hypertension. **a)** Tissue factor; **b)** fibrin monomers; **c)** D-dimer; **d)** pro-coagulant microparticle (MP) activity (pro-coagulant phospholipid (PPL) clotting time; a shorter time is associated with a higher pro-coagulant activity); **e)** erythrocyte-derived MPs; **f)** platelet-derived MPs. Comparisons were made using Mann–Whitney U-test. NS: nonsignificant. *: p<0.05.

($p=0.003$) was noted in the 19 patients who had an available measure of PTRV both during ACS and at steady state (supplementary figure S1 and supplementary table S8).

A significant reduction of tissue factor and D-dimer was observed at the time of steady state, as compared with the time of ACS (supplementary figure S2). Fibrin monomers, PPL activity and erythrocyte- and platelet-derived microparticles did not significantly decrease at steady state, as compared with the time of ACS (supplementary figure S2). Those latter biomarkers remained significantly different from those of healthy controls at steady state (supplementary figure S3). Erythrocyte microparticles remained higher at steady state after an episode of ACS with acute PH, as compared with an episode of ACS with no PH (supplementary figure S4).

Discussion

In this pilot study, we investigated the pro-coagulant activation of the endothelium, the activation of coagulation pathway and the place of erythrocyte and platelet-derived microparticles in a cohort of sickle-cell disease patients with ACS admitted to the ICU. Our findings were as follows: 1) the endothelium was activated during ACS, and there was a hypercoagulability state, as compared with healthy and severe pneumonia controls; 2) erythrocyte- and platelet-derived microparticles and the pro-coagulant activity of microparticles were particularly increased in case of acute PH; 3) at steady state, the levels of tissue factor and D-dimer significantly decreased, as compared with the time of ACS, but the pro-coagulant activity of microparticles and erythrocyte- and platelet-derived microparticles levels remained increased, despite the significant reduction of PTRV in most patients.

ACS is a common acute complication of sickle-cell disease [16] and the leading cause of death [17, 18]. A moderate increase in systolic pulmonary arterial pressure, assessed indirectly by a $\text{PTRV} \geq 2.5 \text{ m}\cdot\text{s}^{-1}$ on TTE, has been shown to be a major independent risk factor for mortality [19]. Moreover, chronic PH is known to be a frequent and severe complication of sickle-cell disease, as it has been shown to occur in 6–10% of patients, and to be associated with an overall survival of 60% at 5 years [15, 20]. A study comparing PTRV at steady state and at the time of vaso-occlusive crisis in 26 sickle-cell patients showed a significant increase in PTRV from $2.4 \pm 0.07 \text{ m}\cdot\text{s}^{-1}$ to $2.9 \pm 0.07 \text{ m}\cdot\text{s}^{-1}$, and a resolution at distance from the crisis, regardless of the intensity of haemolysis [21]. In a series of 70 episodes of severe ACS, the PTRV at admission was $>3 \text{ m}\cdot\text{s}^{-1}$ in 31% of the cases [8]. Of note, the patients treated with mechanical ventilation ($n=5$) and those who died ($n=4$) were all characterised by a $\text{PTRV} >3 \text{ m}\cdot\text{s}^{-1}$ [8]. Another study has suggested that acute pulmonary vascular dysfunction and acute PH were more common during ARDS associated with sickle-cell disease than during ARDS from other causes [22]. In our study, we used the echocardiographic probability of PH, based on PTRV measure and associated echocardiographic signs of PH, as PTRV measure alone is known to lack of precision for estimating the pulmonary arterial pressures in sickle-cell disease [15]. Altogether, seven (21%) out of 34 patients were classified as having a high probability of acute PH. This prevalence is in the low range, as compared with other series [8]. This discrepancy might be related to the stricter definition of acute PH we used, as we combined PTRV with other echo PH signs, while the others used PTRV alone, but also to an overall lower severity of ACS in our series, as compared with others [8, 18].

The mechanisms of acute PH during ACS are probably multiple. Indeed, ACS is associated with many pathological modifications such as worsening of haemolytic anaemia, hypoxic vasoconstriction and high cardiac output, which can temporarily increase pulmonary arterial pressure [21]. The increase in haemolysis can also be accompanied by a decrease in the bioavailability of nitric oxide by sequestration by free haemoglobin, and thus by acute endothelial dysfunction [23]. This acute endothelial dysfunction may be exacerbated by an increase in endothelin 1, a potent vasoconstrictor, which has been observed during vaso-occlusive crisis [24]. Another explanatory mechanism for acute PH during ACS may be acute microvascular or more proximal pulmonary vascular thrombosis [25, 26]. Acute pulmonary vascular thrombosis may be favoured by fatty emboli, by the increase in the adhesion of red blood cells to the pathological endothelium, but also by a state of hypercoagulability favoured by acute endothelial dysfunction, which possibly increases during ACS, with the intervention of ischaemia-reperfusion lesions. The presence of pulmonary microvascular thrombi associated with pulmonary arteriolar changes has been described in an autopsy series [27]. In our population, two patients with ACS developed acute pulmonary embolism, but only one had acute PH. None had associated deep-vein thrombosis, suggesting *in situ* thrombosis [26]. It is noteworthy that lower limb pain was more often reported in the high probability group, as compared with the low-intermediate probability group, which may promote bone necrosis and ultimately pulmonary fat embolism. Interestingly, in our study, platelet count was higher in patients with acute PH. Among 121 ACS episodes, MEKONTSO DESSAP *et al.* [26] reported higher platelet counts in ACS episodes associated with pulmonary embolism than in ACS episodes without pulmonary embolism, and

the authors discussed the direct relationship between increased platelet count and thrombosis. Another study reported the association of thrombocytosis and elevated pulmonary artery pressures in sickle-cell disease [28]. High platelet count could therefore participate to local thrombosis and to the onset of acute PH. The increase in erythrocyte and platelet-derived microparticles and in the pro-coagulant activity of microparticles could also be responsible for *in situ* microvascular thrombosis, and be one of the missing links to explain the pathophysiology of ACS, especially in case of acute PH. Circulating microparticles are anucleated membrane fragments of 0.1–1 µm in diameter produced by damaged or activated cells [29, 30]. They contain surface proteins, but also intracellular material such as RNA. Several series have already shown increased rates of erythrocyte- and platelet-derived microparticles in sickle-cell disease patients, as compared with healthy controls [31–33], but the increase of these microparticles during acute episodes compared to steady state is more controversial [34, 35]. Our study is the first to show an increase of these microparticles in severe ACS, as compared with severe pneumonia, suggesting that these microparticles should be more than a spectator in the pathophysiology of ACS. Moreover, it is the first to show a higher increase of erythrocyte- and platelet-derived microparticles in case of acute PH. A series found that levels of erythrocyte-derived vesicles and intravascular haemolysis were linked, as suggested by the correlation between levels of vesicles and plasma haemoglobin [36], which was consistent with a higher level of LDH in patients with acute PH and higher levels of microparticles in our series. In addition, it has been shown that erythrocyte-derived microparticles promote thrombin generation [13, 36]. Platelet-derived microparticles have been shown to be implicated in ACS, as shown in an *in vivo* model of sickle-cell disease in which the activation of platelets produced platelet-derived microparticles which activated neutrophils and other platelets to form large platelet–neutrophil aggregates that occlude pulmonary arterioles [30]. Therefore, we assume that erythrocyte- and platelet-derived microparticles could promote acute PH in ACS, by favouring acute pulmonary endothelial dysfunction by an action on local nitric oxide and an activation of microvascular thrombosis, through the promotion of thrombin generation.

Our study has limitations. First, because of the necessary strict exclusion criteria such as transfusion in the previous 4 months, only a small population was included. Moreover, given its design, this study showed an association, but did not allow us to conclude on a causal link between increased microparticle levels and acute PH in ACS. Given its prospective and real-life design, some examinations were not performed in all patients, and the number of patients assessed at steady state was limited. Furthermore, as it was a routine care study and it was expected that we would not draw more blood from patients on inclusion than the usual amount, we chose to assay only certain markers, representative of endothelial dysfunction and activation of thrombosis. We were unable to assay certain markers of endothelial dysfunction such as adhesion molecules and von Willebrand factor, which would have given a more complete characterisation of endothelial dysfunction. Likewise, we were not able to characterise all the plasma microparticles and we focused on the erythrocyte and platelet microparticles, which are the most relevant in sickle-cell disease. Finally, the healthy control population and the control CAP population were not matched for age and sex with the sickle-cell disease population and the groups were too small to allow multivariate analysis. Nevertheless, these limitations were reduced by the fact that the healthy control group had a similar age and sex ratio and the control CAP population had similar severity of lung disease, as only one developed ARDS, and as most of these patients were treated with high levels of oxygen, like those in the sickle-cell disease population.

The activation of the endothelium with an increase in thrombosis, pro-coagulant activity of microparticles and erythrocyte- and platelet-derived microparticles in ACS could be one of the missing links to explain the pathophysiology of ACS. This study is a pilot study which does not currently allow the results to be applied directly in clinical practice or in terms of prognosis or prediction. However, further and larger studies are needed to evaluate biomarkers assessing endothelial dysfunction and hypercoagulability as prognostic markers to prompt to more aggressive treatment or close monitoring of patients or as therapeutic targets in ACS.

Provenance: Submitted article, peer reviewed.

Acknowledgements: The authors thank the patients, their families and all healthcare professionals and administrative staff from Tenon Hospital (AP-HP, Paris, France) for their outstanding support, as well as the healthy volunteers. They thank particularly Alexandre Elabbadi and Isabelle Dubois (Service de Médecine Intensive Réanimation, Département Médico-Universitaire APPROCHES, Hôpital Tenon) for their help in the collection of data.

Conflict of interest: E-M. Jutant has nothing to disclose. G. Voiriot reports grants and personal fees from Biomérieux, and grants from Janssen and SOS Oxygene, outside the submitted work. V. Labbé reports personal

fees from AMOMED outside the submitted work. L. Savale reports personal fees and nonfinancial support from Actelion and MSD, and grants, personal fees and nonfinancial support from GSK, outside the submitted work. H. Mokrani has nothing to disclose. P. Van Dreden has nothing to disclose. G. Gerotziakas has nothing to disclose. M. Fartoukh reports grants from BioMerieux and personal fees from Pfizer, outside the submitted work.

References

- 1 Piel FB, Steinberg MH, Rees DC. Sickle cell disease. *N Engl J Med* 2017; 376: 1561–1573.
- 2 Piel FB, Hay SI, Gupta S, et al. Global burden of sickle cell anaemia in children under five, 2010–2050: modelling based on demographics, excess mortality, and interventions. *PLoS Med* 2013; 10: e1001484.
- 3 Kato GJ, Piel FB, Reid CD, et al. Sickle cell disease. *Nat Rev Dis Primers* 2018; 4: 18010.
- 4 Gladwin MT, Vichinsky E. Pulmonary complications of sickle cell disease. *N Engl J Med* 2008; 359: 2254–2265.
- 5 Charache S, Scott JC, Charache P. “Acute chest syndrome” in adults with sickle cell anemia. Microbiology, treatment, and prevention. *Arch Intern Med* 1979; 139: 67–69.
- 6 Vichinsky EP, Neumayr LD, Earles AN, et al. Causes and outcomes of the acute chest syndrome in sickle cell disease. National Acute Chest Syndrome Study Group. *N Engl J Med* 2000; 342: 1855–1865.
- 7 Medoff BD, Shepard J-AO, Smith RN, et al. Case records of the Massachusetts General Hospital. Case 17–2005. A 22-year-old woman with back and leg pain and respiratory failure. *N Engl J Med* 2005; 352: 2425–2434.
- 8 Mekontso Dessap A, Leon R, Habibi A, et al. Pulmonary hypertension and cor pulmonale during severe acute chest syndrome in sickle cell disease. *Am J Respir Crit Care Med* 2008; 177: 646–653.
- 9 Hebbel RP, Osarogiagbon R, Kaul D. The endothelial biology of sickle cell disease: inflammation and a chronic vasculopathy. *Microcirculation* 2004; 11: 129–151.
- 10 Zhang D, Xu C, Manwani D, et al. Neutrophils, platelets, and inflammatory pathways at the nexus of sickle cell disease pathophysiology. *Blood* 2016; 127: 801–809.
- 11 Bennewitz MF, Jimenez MA, Vats R, et al. Lung vaso-occlusion in sickle cell disease mediated by arteriolar neutrophil-platelet microemboli. *JCI Insight* 2017; 2: e89761.
- 12 Ballas SK. More definitions in sickle cell disease: steady state v base line data. *Am J Hematol* 2012; 87: 338.
- 13 Gerotziakas GT, Van Dreden P, Chaari M, et al. The acceleration of the propagation phase of thrombin generation in patients with steady-state sickle cell disease is associated with circulating erythrocyte-derived microparticles. *Thromb Haemost* 2012; 107: 1044–1052.
- 14 Galiè N, Humbert M, Vachiery J-L, et al. 2015 ESC/ERS Guidelines for the diagnosis and treatment of pulmonary hypertension: The Joint Task Force for the Diagnosis and Treatment of Pulmonary Hypertension of the European Society of Cardiology (ESC) and the European Respiratory Society (ERS). *Eur Respir J* 2015; 46: 903–975.
- 15 Parent F, Bachir D, Inamo J, et al. A hemodynamic study of pulmonary hypertension in sickle cell disease. *N Engl J Med* 2011; 365: 44–53.
- 16 Castro O, Brambilla DJ, Thorington B, et al. The acute chest syndrome in sickle cell disease: incidence and risk factors. The Cooperative Study of Sickle Cell Disease. *Blood* 1994; 84: 643–649.
- 17 Platt OS, Brambilla DJ, Rosse WF, et al. Mortality in sickle cell disease. Life expectancy and risk factors for early death. *N Engl J Med* 1994; 330: 1639–1644.
- 18 Cecchini J, Lionnet F, Djibré M, et al. Outcomes of adult patients with sickle cell disease admitted to the ICU: a case series. *Crit Care Med* 2014; 42: 1629–1639.
- 19 Gladwin MT, Sachdev V, Jison ML, et al. Pulmonary hypertension as a risk factor for death in patients with sickle cell disease. *N Engl J Med* 2004; 350: 886–895.
- 20 Savale L, Habibi A, Lionnet F, et al. Clinical phenotypes and outcomes of precapillary pulmonary hypertension of sickle cell disease. *Eur Respir J* 2019; 54: 1900585.
- 21 Machado RF, Mack AK, Martyr S, et al. Severity of pulmonary hypertension during vaso-occlusive pain crisis and exercise in patients with sickle cell disease. *Br J Haematol* 2007; 136: 319–325.
- 22 Cecchini J, Boissier F, Gibelin A, et al. Pulmonary vascular dysfunction and cor pulmonale during acute respiratory distress syndrome in sicklers. *Shock* 2016; 46: 358–364.
- 23 Reiter CD, Wang X, Tanus-Santos JE, et al. Cell-free hemoglobin limits nitric oxide bioavailability in sickle-cell disease. *Nat Med* 2002; 8: 1383–1389.
- 24 Ergul S, Brunson CY, Hutchinson J, et al. Vasoactive factors in sickle cell disease: *in vitro* evidence for endothelin-1-mediated vasoconstriction. *Am J Hematol* 2004; 76: 245–251.
- 25 Bhalla M, Abboud MR, McLoud TC, et al. Acute chest syndrome in sickle cell disease: CT evidence of microvascular occlusion. *Radiology* 1993; 187: 45–49.
- 26 Mekontso Dessap A, Deux J-F, Abidi N, et al. Pulmonary artery thrombosis during acute chest syndrome in sickle cell disease. *Am J Respir Crit Care Med* 2011; 184: 1022–1029.
- 27 Anea CB, Lyon M, Lee IA, et al. Pulmonary platelet thrombi and vascular pathology in acute chest syndrome in patients with sickle cell disease. *Am J Hematol* 2016; 91: 173–178.

- 28 Pashankar FD, Carbonella J, Bazy-Asaad A, *et al.* Prevalence and risk factors of elevated pulmonary artery pressures in children with sickle cell disease. *Pediatrics* 2008; 121: 777–782.
- 29 Hebbel RP, Key NS. Microparticles in sickle cell anaemia: promise and pitfalls. *Br J Haematol* 2016; 174: 16–29.
- 30 Vats R, Brzoska T, Bennewitz MF, *et al.* Platelet extracellular vesicles drive inflammasome-IL-1 β -dependent lung injury in sickle cell disease. *Am J Respir Crit Care Med* 2020; 201: 33–46.
- 31 Shet AS, Aras O, Gupta K, *et al.* Sickle blood contains tissue factor-positive microparticles derived from endothelial cells and monocytes. *Blood* 2003; 102: 2678–2683.
- 32 van Beers EJ, Schaap MCL, Berckmans RJ, *et al.* Circulating erythrocyte-derived microparticles are associated with coagulation activation in sickle cell disease. *Haematologica* 2009; 94: 1513–1519.
- 33 van Tits LJ, van Heerde WL, Landburg PP, *et al.* Plasma annexin A5 and microparticle phosphatidylserine levels are elevated in sickle cell disease and increase further during painful crisis. *Biochem Biophys Res Commun* 2009; 390: 161–164.
- 34 Kasar M, Boža C, Yeral M, *et al.* Clinical significance of circulating blood and endothelial cell microparticles in sickle-cell disease. *J Thromb Thrombolysis* 2014; 38: 167–175.
- 35 Tantawy AAG, Adly AAM, Ismail EAR, *et al.* Circulating platelet and erythrocyte microparticles in young children and adolescents with sickle cell disease: relation to cardiovascular complications. *Platelets* 2013; 24: 605–614.
- 36 Westerman M, Pizzey A, Hirschman J, *et al.* Microvesicles in haemoglobinopathies offer insights into mechanisms of hypercoagulability, haemolysis and the effects of therapy. *Br J Haematol* 2008; 142: 126–135.