

Case Report

Vaginoscopic Incision of Oblique Vaginal Septum in an Adolescent Girl with OHVIRA Syndrome: Simple Management of Complicated Anomaly

Aruna Nigam, Pragati Aggarwal, Anamika Baghel, Neha Gupta, Sumedha Sharma, Abhinav Jain¹

Departments of Obstetrics and Gynaecology and ¹Radiology, Hamdard Institute of Medical Science and Research, Jamia Hamdard, New Delhi, India

ABSTRACT

OHVIRA syndrome comprises uterine didelphys, obstructed hemivagina, and ipsilateral renal agenesis. It usually presents with pain abdomen and pelvic or vaginal mass with normal menses. Early diagnosis is important to prevent complications in later life. The case of a 12-year-old girl who presented with pain abdomen and progressive dysmenorrhea for the last 6 months (since menarche) is discussed. She was managed successfully with vaginoscopic septal incision with simultaneous preservation of hymenal integrity.

KEYWORDS: Mullerian anomaly, OHVIRA syndrome, vaginoscopy

INTRODUCTION

OHVIRA syndrome stands for obstructed hemivagina, and ipsilateral renal agenesis, also called Herlyn–Werner–Wunderlich syndrome. It is a rare Mullerian anomaly associated with uterus didelphys, with an incidence between 0.1% and 3% of all Mullerian anomalies.^[1] It usually presents as an acute pain abdomen, pelvic or vaginal mass, abnormal vaginal discharge, and rarely with primary infertility.^[2,3] In symptomatic adolescent girls with this syndrome, minimal surgery with hymen preservation should be the main aim of treatment whenever possible.

CASE REPORT

A 12-year-old girl presented with lower pain abdomen for 1 month which was cramping, radiating to back and thighs. It was not associated with fever, vomiting, or any bowel and bladder complaints. She attained menarche 6 months back and her menses were regular, associated with progressively increasing dysmenorrhea. She was not sexually active. There was no significant medical, surgical, or family history. On examination, the patient was conscious and well oriented. Vitals were stable, with a body mass index of 27.5 kg/m². Breast, axillary, and pubic hair were Tanner Stage 4. The abdomen was soft

with no palpable mass. Local examination revealed normal genitalia. Rectal examination revealed a cystic bulge 5 cm above the anal verge; the upper margin of the bulge was not felt. Vaginal examination was not done as she was sexually inactive. All blood investigations were within normal limits. Ultrasonography (USG) whole abdomen revealed absent right kidney with uterine didelphys with hematometra in the horn on the right side with right-sided hematosalpinx. Magnetic resonance imaging (MRI) findings [Figures 1 and 2] suggested uterine didelphys with normal left horn of the uterus and cervix communicating with vagina. The right horn of the uterus was distended with blood suggestive of hematometra and communicating with the upper part of the vagina which was also distended with blood with abrupt ending in the upper part only. Right-sided hematosalpinx was also present. Both ovaries appeared normal. The diagnosis of OHVIRA syndrome was made, and the patient was planned for vaginoscopic examination under anesthesia. Consent was taken from the patient and the parents for the operative procedure. The parents insisted on preservation

Address for correspondence: Prof. Aruna Nigam, Department of Obstetrics and Gynaecology, Hamdard Institute of Medical Science and Research, Jamia Hamdard, New Delhi, India. E-mail: prakasharuna@hotmail.com

Received: 14-03-2021
Accepted: 16-05-2021

Revised: 16-05-2021
Published: 30-08-2021

Access this article online

Quick Response Code:



Website:
www.jhrsonline.org

DOI:
10.4103/jhrs.jhrs_46_21

This is an open access journal, and articles are distributed under the terms of the Creative Commons Attribution-NonCommercial-ShareAlike 4.0 License, which allows others to remix, tweak, and build upon the work non-commercially, as long as appropriate credit is given and the new creations are licensed under the identical terms.

For reprints contact: WKHLRPMedknow_reprints@wolterskluwer.com

How to cite this article: Nigam A, Aggarwal P, Baghel A, Gupta N, Sharma S, Jain A. Vaginoscopic incision of oblique vaginal septum in an adolescent girl with OHVIRA syndrome: Simple management of complicated anomaly. J Hum Reprod Sci 2021;14:313-6.

of hymen if possible. Vaginoscopic examination [Figure 3] by 4 mm hysteroscope revealed a single cervix at 1 O'clock and a bulge on the right side at 10 O'clock position. Hysteroscopic examination of the right uterine cavity was normal with normal ostia. Eight-millimeter resectoscope with Collin's knife was introduced through hymenal opening, and a 1.5 cm transverse nick was given over the bulge on the right side of the cervix. Old collected blood drained from newly created opening. Silicone catheter no. 20 was inserted for continuous drainage. Her postoperative period was uneventful with no pain. Postoperative USG revealed complete disappearance of hematosalpinx, hematometra, and hematocolpos on the 2nd day [Figure 4]. The patient was discharged with catheter *in situ* for 2 months to avoid any obstruction of newly created vaginal opening. Six-month follow-up of the case revealed no development of hematometra suggestive of patent newly created vaginal opening.

DISCUSSION

Etiology of OHVIRA syndrome is not completely understood, but it is hypothesised that it occurs secondary to mesonephric duct-induced Mullerian defects as urinary and genital systems arise from a common ridge of mesoderm.^[4] Paired paramesonephric ducts of the genetically female embryo fuse together in the midline and form the uterus, cervix, and the upper four-fifths of the vagina. In OHVIRA syndrome, at 5 weeks, metanephric diverticulum fails to develop from mesonephric duct leading to agenesis of ipsilateral ureter and kidney. At around 9-week gestation, the paramesonephric ducts fail to unite, resulting in uterine didelphys. Developmental arrest of ipsilateral mesonephric duct results in failure of distal hemivagina to develop, thereby resulting in obstructed hemivagina. The condition has also been reported to be associated with high-riding aortic bifurcation, inferior vena cava duplication, intestinal malrotation, and ovarian malposition.^[5] OHVIRA syndrome has been further classified (Rock and Jone classification) into three types:

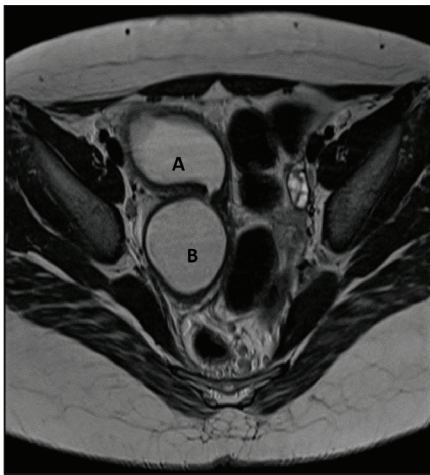


Figure 1: Magnetic resonance imaging images. 1. Image showing right uterine horn (a) and right hemivagina (b) filled with blood

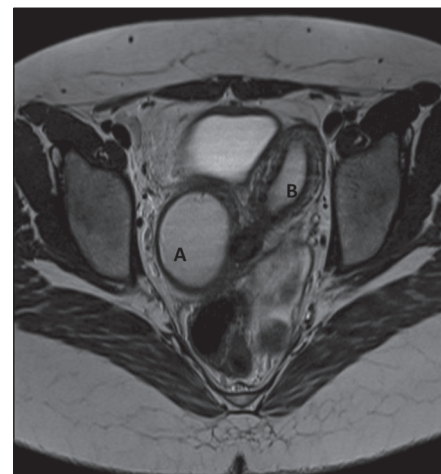


Figure 2: Magnetic resonance imaging image showing right uterine horn (a) distended with blood and normal left uterine horn (b)

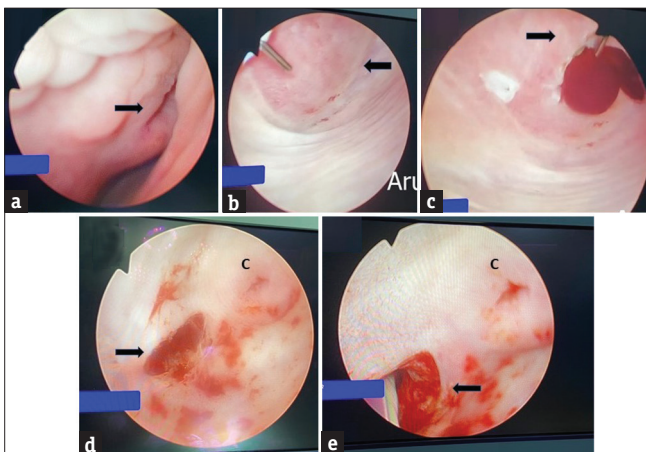


Figure 3: Peroperative images – (a) normal cervix, (b) bulge of hematocolpos at fornix near the cervix, (c) old blood from incised bulge, (d) newly created opening near-normal cervix (c), (e) catheter in the right neovaginal opening

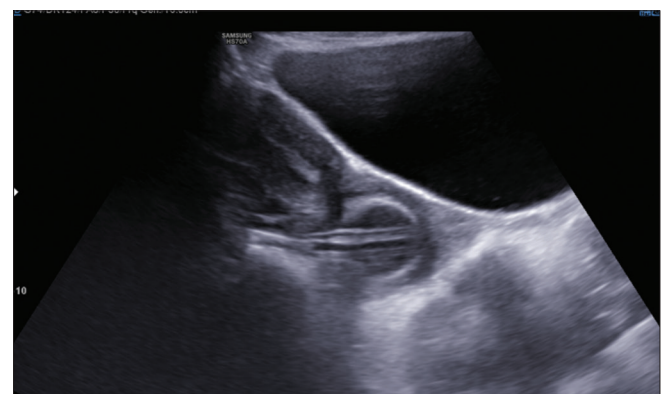


Figure 4: Postoperative ultrasonography showing resolution of hematometra and hematocolpos with catheter *in situ*

- Type I: Blind hemivaginal septum without an opening. In this case, the uterine horn behind the septum has no connection to the outside nor into the contralateral uterus and menstrual blood accumulates in the cavity behind the vaginal septum
- Type II: Blind hemivaginal septum with an opening. In this case, there is a pinpoint-size hole in the septum through which a limited amount of menstrual blood drains out
- Type III: Complete hemivaginal septum with cervical fistula. In this case, a fistula connects the two cervixes of the obstructed vagina and the contralateral cervix.

This case belonged to type 1 OHVIRA syndrome with very high oblique septa. Various imaging modalities used to diagnose this condition include USG, conventional and sonohysterosalpingography, and MRI. Computed tomography has a limited role in evaluation of the female pelvis. Ultrasound, especially three-dimensional USG, is a cheap, noninvasive, widely available imaging modality that helps in the diagnosis of this condition. MRI is the investigation of choice but delineation of exact location and the size of septa in case of large hematocolpos is still difficult. Vaginoscopy with the help of hysteroscope in these cases is very helpful for diagnosis as well as management.

Surgical management is the treatment of choice, and it should be carried out as soon as possible in order to relieve symptoms and to prevent long-term complications related to retrograde menstrual flow including hematocolpos, pyocolpos, endometriosis, and pelvic adhesions. Conventional treatment with insertion and manipulation with long vaginal instruments in unmarried nulliparous females is cumbersome along with difficult visualization, especially in cases of high septa, and is associated with disruption of hymen.

Vaginoscopic septal incision is a feasible option at all ages with special emphasis of its use in adolescent girls where the introitus is small, vagina is narrow, and distensibility is less. There are only few case series where this condition has been managed by vaginoscopy in order to avoid postoperative pain and preservation of hymen. Cheng *et al.* managed 14 adolescent girls by vaginoscopic resection of transverse vaginal septum using no-touch technique over a period of 8 years. They revealed no vaginal stenosis or reforming of septum on follow-up.^[6] Kriplani *et al.* managed eight adolescent girls with OHVIRA syndrome by vaginoscopic resection of septum over a period of 6 years and concluded that it is an effective method to treat OHVIRA syndrome.^[7] Ludwin *et al.* introduced a unique concept of hymen-sparing management with the use of

transrectal ultrasound-guided vaginoscopic septoplasty in four adolescent girls.^[8]

Besides good visualization of hematocolpos bulge through vaginoscopy and easy maneuverability in these adolescent girls with the use of vaginoscopy, preservation of hymen integrity during the procedure gives an added satisfaction to the parents due to its social benefit. Small capacity of vagina as well tiny introitus gives a benefit of less leakage of fluid during vaginoscopy and easy distension. The insertion of the silicone catheter is optional and is done to prevent the cicatrization of the opening in the immediate postoperative period. Good size incision should be given during the start of resection as the flow of blood from the opening can occlude the vision, and once the bulge subsides, it is difficult to extend incision in a small vagina safely. One must not try to visualize the cervix inside this opening as this can cause spillage of blood in the peritoneal cavity. Complete resolution of hematosalpinx occurred on the 2nd postoperative day, therefore, there is no need of laparoscopy in these cases for the treatment of hematosalpinx.

CONCLUSION

OHVIRA syndrome is a rare congenital anomaly and its management can be made simple, effective, and satisfying by the use of vaginoscopic incision and drainage.

Consent

Informed written consent has been taken from the patient and her parents for the publication of operative and radiological images.

Declaration of patient consent

The authors certify that they have obtained all appropriate patient consent forms. In the form, the patient and her parents have given their consent for images and other clinical information to be reported in the journal. The patient and her parents understand that name and initials will not be published and due efforts will be made to conceal identity, but anonymity cannot be guaranteed.

Financial support and sponsorship

Nil.

Conflicts of interest

There are no conflicts of interest.

REFERENCES

1. Zurawin RK, Dietrich JE, Heard MJ, Edwards CL. Didelphic uterus and obstructed hemivagina with renal agenesis: Case report and review of the literature. *J Pediatr Adolesc Gynecol* 2004;17:137-41.

2. Nigam A, Raghunandan C, Yadav R, Tomer S, Anand R. OHVIRA syndrome: Rare cause of chronic vaginal discharge in an unmarried female. *Congenit Anom (Kyoto)* 2011;51:153-5.
3. Jindal G, Kachhawa S, Meena GL, Dhakar G. Uterus didelphys with unilateral obstructed hemivagina with hematometocolpos and hematosalpinx with ipsilateral renal agenesis. *J Hum Reprod Sci* 2009;2:87-9.
4. Bajaj SK, Misra R, Thukral BB, Gupta R. OHVIRA: Uterus didelphys, blind hemivagina and ipsilateral renal agenesis: Advantage MRI. *J Hum Reprod Sci* 2012;5:67-70.
5. Coskun A, Okur N, Ozdemir O, Kiran G, Arýkan DC. Uterus didelphys with an obstructed unilateral vagina by a transverse vaginal septum associated with ipsilateral renal agenesis, duplication of inferior vena cava, high-riding aortic bifurcation, and intestinal malrotation: A case report. *Fertil Steril* 2008;90:e9-11.
6. Cheng C, Subedi J, Zhang A, Johnson G, Zhao X, Xu D, *et al.* Vaginoscopic incision of oblique vaginal septum in adolescents with OHVIRA syndrome. *Sci Rep* 2019;9:20042.
7. Kriplani A, Dalal V, Kachhawa G, Mahey R, Yadav V, Kriplani I. Minimally invasive endoscopic approach for management of OHVIRA syndrome. *J Obstet Gynaecol India* 2019;69:350-5.
8. Ludwin A, Ludwin I, Bhagavath B, Martins WP, Lindheim SR. Virginity-sparing management of blind hemivagina in obstructed hemivagina and ipsilateral renal anomaly syndrome. *Fertil Steril* 2018;110:976-8.