

**Case
Report****Total Aortic Arch Replacement after Thoracic Endovascular Aortic Repair Using Left Subclavian Arterial Perfusion**

Taijiro Sueda, MD, PhD, Shinya Takahashi, MD, PhD, and Keijiro Katayama, MD, PhD

We present the case of an 86-year-old male with an aortic arch saccular aneurysm who underwent zone 1 thoracic endovascular aortic repair (TEVAR) with debranching from the right subclavian artery to the left carotid and left subclavian arteries. The patient developed a type Ia endoleak 1 month later. Postoperative contrast computed tomography (CT) showed a hematoma around the aneurysm, concerning for impending rupture. He thus underwent emergency endograft removal and replacement with a one-branched graft using selective cerebral perfusion via the left subclavian artery perfusion. The left subclavian artery was used for systemic and cerebral perfusion without need for cannulation of the cervical arteries. The patient was successfully discharged 6 months after surgery.

Keywords: zone 1 TEVAR, type Ia endoleak, removal of endograft, total arch replacement

Introduction

Thoracic endovascular aortic repair (TEVAR) has emerged as an alternative to traditional open aortic aneurysm repair. However, TEVAR can be complicated by endoleaks, which require secondary intervention. The rate of secondary intervention after TEVAR ranges from 0.4% to 7%.^{1,2)} The causes of open repair after TEVAR include endoleak (type I), aorto-enteric fistula, endograft infection, and device collapse or migration. Open conversion after TEVAR consists of extraction of a full or partial endograft, depending on the cause of removal.

Department of Cardiovascular Surgery, Hiroshima University, Graduate School of Medicine, Hiroshima, Hiroshima, Japan

Received: January 11, 2018; Accepted: February 20, 2018
Corresponding author: Taijiro Sueda, MD, PhD. Department of Cardiovascular Surgery, Hiroshima University, Graduate School of Medicine, 1-2-3 Kasumi, Minami-ku, Hiroshima, Hiroshima 734-8551, Japan
Email: suedata@hiroshima-u.ac.jp



This work is licensed under a Creative Commons Attribution-NonCommercial-NoDerivatives International License.

©2020 The Editorial Committee of *Annals of Thoracic and Cardiovascular Surgery*

We present a case of total arch replacement after zone 1 TEVAR due to a type 1a endoleak. We discuss the process of selective cerebral perfusion during the procedure.

Case Report

An 86-year-old man was referred to our hospital due to a saccular aneurysm in the distal aortic arch that was identified on chest computed tomography (CT; **Fig. 1a**). The aneurysm had a maximal diameter 64 mm × 48 mm. Proximal distance from the aneurysm to the innominate artery was 30 mm in the larger curve and 26 mm in the lesser curve. We reasoned that a zone 1 TEVAR with a C-Tag (Gore corp.) device could be performed because the C-Tag device is often used for zone 1 TEVAR and is only infrequently associated with type Ia endoleak. Thus, a zone 1 TEVAR with C-Tag (Gore corp. size 40 mm × 40 mm × 20 cm) was performed after debranching from the right subclavian artery to the left carotid artery and the left subclavian artery was performed (using 8 mm Dacron graft). The proximal edges of the left carotid and the left subclavian artery were ligated to prevent type 2 endleak. Neither a bird-beak configuration nor migration of the C-Tag device was observed on postoperative contrast CT immediately after TEVAR (**Fig. 1b**).

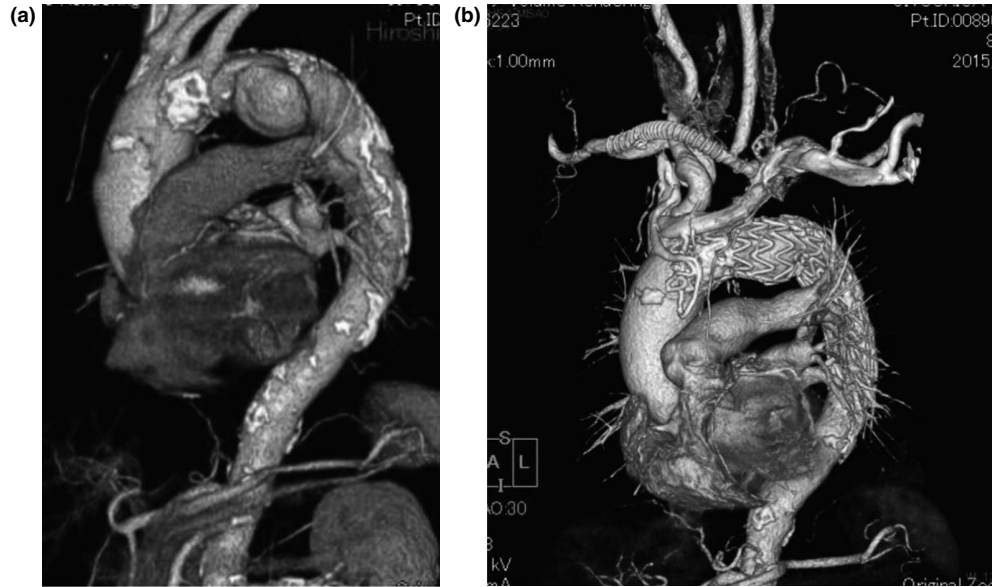

Fig. 1 (a) Preoperative contrast 3D-CT. The preoperative CT showed a saccular aneurysm (diameter: 64 mm × 48 mm) in the distal aortic arch. (b) Postoperative contrast 3D-CT. The postoperative CT showed the patent debranch graft from the right subclavian artery to the left carotid and the left subclavian artery. Neither a bird-beak configuration nor migration of the C-Tag device was observed on postoperative contrast CT immediately after TEVAR. TEVAR: thoracic endovascular aortic repair; 3D-CT: three-dimensional computed tomography

However, postoperative serial contrast CTs showed a gradual increase in the size of the aneurysm and contrast medium was observed in the proximal end of the endograft. The patient was diagnosed with a type Ia endoleak and was scheduled to undergo an additional TEVAR using another C-Tag device. However, a hematoma around the aneurysm rapidly increased in size and extended toward the ascending aorta (**Fig. 2**). A ruptured aneurysm was suspected, and the patient underwent emergent surgery.

Median sternotomy revealed adhesion of the ascending aorta and the aortic arch. A Dacron prosthesis (8 mm diameter) was anastomosed to the left subclavian artery as the route of systemic and selective cerebral perfusion. Extracorporeal circulation was established with left subclavian arterial perfusion and bi-caval venous drainage. Blood temperature decreased to 28°C and systemic circulation was terminated. Selective cerebral perfusion using left subclavian arterial perfusion was established with a blood flow rate of 800 mL/min using the left subclavian artery without the need to cannulate other cervical branches. A blood flow of cerebral perfusion was determined according to cerebral perfusion flow of normal total arch replacement. There was significant difference of mean artery pressure between the right radial

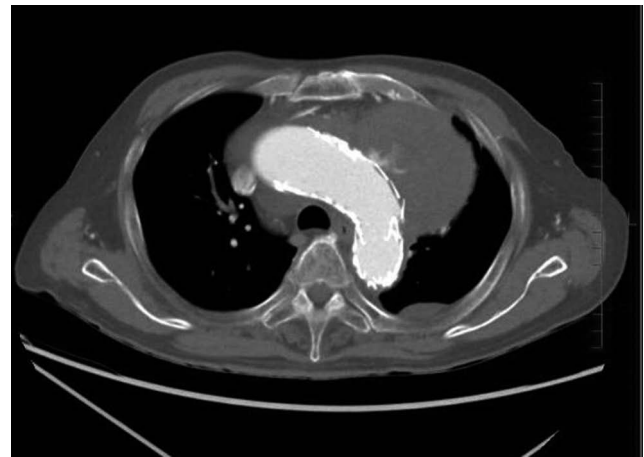


Fig. 2 Postoperative CT. The hematoma around the aneurysm increased in size and extended toward the ascending aorta. CT: computed tomography

artery and the left radial artery, such as 40 mmHg at the right radial artery and 80 mmHg at the left radial artery. After circulatory arrest and cardiac arrest using retrograde cardioplegia, the ascending aorta was transected and the proximal part of the C-Tag was moved to the end of the aortic arch aneurysm. The distal aortic arch aneurysm was resected and the distal anastomotic site was trimmed, a piece of double-folded elephant trunk

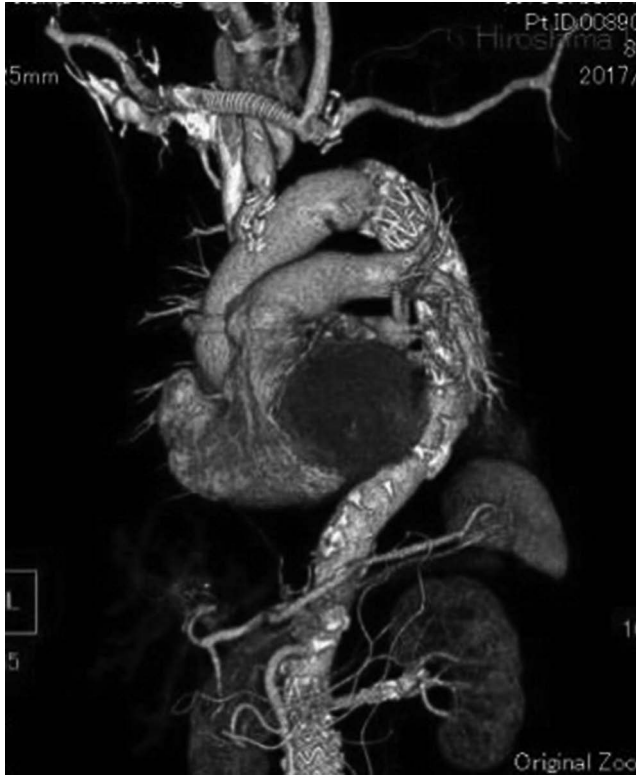

Fig. 3 CT after open conversion. Postoperative 3D-CT showed good configuration of the one-branched graft and a patent debranching graft from the right subclavian artery to the left carotid artery and the left subclavian artery. 3D-CT: three-dimensional computed tomography

(Dacron graft, length 5 cm, diameter 28 mm) was inserted into the descending aorta and anastomosed to the distal edge of the aorta. Then, the folded part of the elephant trunk was pulled out and anastomosed to the one-branched graft (Zelweave Dacron graft, Termo corp. size 28 mm, branch graft size 10 mm). Because the prosthetic wall of C-Tag was fragile and there was a risk of anastomotic tear, we inserted a piece of Dacron graft (Zelweave Dacron graft, Termo corp. size: 28 mm, length: 5 cm) as an elephant trunk to prevent anastomotic tear and endleak. After termination of the proximal anastomosis on the ascending aorta, the branch graft was anastomosed to the brachiocephalic artery. The cardiopulmonary bypass time and the aortic cross clamping time were 92 min and 62 min, respectively. We encountered no difficulties with extracorporeal circulation during the procedure.

Postoperative three-dimensional (3D)-CT showed complete reconstruction of the branched graft and a patent debranching graft from the right subclavian artery to the left carotid artery and the left subclavian

artery (**Fig. 3**). The patient suffered from mediastinitis due to *methicillin-resistant Saphylococcus aureus* and received negative pressure wound therapy (VAC therapy) and antibiotic (Vancomycin) for 20 days. He was discharged 6 months after surgery and continued rehabilitation at home.

Discussion

Endoleaks are well-known complications of TEVAR and result from blood flow into the aneurysmal sac. Endoleaks are categorized into four types, type I—reperfusion at the proximal (Ia) or distal (Ib) landing zone, type II—retrograde reperfusion from branching vessels, type III—reperfusion from a gap between devices, and type IV (rare)—reperfusion through porous fabric. There is little guidance regarding when to use open repair to treat endoleaks. Japanese guidelines³⁾ state that most endoleaks can be resolved using an endovascular approach, but open repair is suggested for aortic enlargement. Type Ia endoleaks are a common indication for open repair after endovascular repair. In fact, the most common indication for subsequent open repair is aneurysmal expansion related to a type Ia endoleak.⁴⁾ Conversion to open repair occurs more often when the landing zone is shorter than recommended.⁵⁾ Among the 278 TEVAR cases performed at our institution during past 6 years, six cases (2.1%) required open repair. Of these six cases, three had a type Ia endoleak. Here, we present a case in which a type Ia endoleak occurred after zone 1 TEVAR using a C-Tag device. The C-Tag device landed proximally between the brachiocephalic artery and the left common carotid artery with debranching from the right subclavian artery to the left carotid artery and the left subclavian artery. Although contrast CT immediately after TEVAR showed good configuration of the proximal end of the C-Tag device and no endoleak, serial contrast CTs showed a type Ia endoleak and enlargement of the aneurysmal diameter. It is possible that migration or bird-beaking of the proximal end of the C-Tag device occurred late after TEVAR deployment.⁶⁾

We replaced the ascending aorta and aortic arch while using selective cerebral perfusion. Because this case involved debranching from the right subclavian artery to the left carotid and left subclavian arteries, we were able to achieve systemic perfusion and selective cerebral perfusion via left subclavian arterial perfusion. A prosthesis was anastomosed to the left subclavian

artery to perfuse the entire body and brain without the need to cannulate cervical arteries during extracorporeal circulation. This is an advantage of zone 1 TEVAR with debranching.

We excised the proximal part of the C-Tag device and inserted a piece of elephant trunk into the descending aorta to reinforce the C-Tag graft. The prosthetic wall of C-Tag seemed to be thin and easy to tear. We were afraid of anastomotic tear and occurrence of new endleak, then inserted a piece of Dacron graft as an elephant trunk to prevent anastomotic tear. If this case is a case of prosthetic graft infection, we have to remove endograft completely.⁷⁾ This case was not endograft infection, then we removed C-Tag graft until the end of aortic arch aneurysm. Postoperative enhanced CT revealed no abnormality of the replaced ascending aorta, arch, or and the brachiocephalic artery with debranching.

Based on our review of the literature, this is the first report of endograft removal after zone 1 TEVAR.

Conclusion

We successfully performed open repair after zone 1 TEVAR. Left subclavian arterial perfusion was a safe and feasible route of systemic and cerebral perfusion during the procedure.

Disclosure Statement

The authors declare no conflicts of interest.

References

- 1) Patterson B, Holt P, Nienaber C, et al. Aortic pathology determines midterm outcome after endovascular repair of the thoracic aorta: report from the Medtronic Thoracic Endovascular Registry (MOTHER) database. *Circulation* 2013; **127**: 24-32.
- 2) Nozdrzykowski M, Luehr M, Garbade J, et al. Outcomes of secondary procedures after primary thoracic endovascular aortic repair. *Eur J Cardiothorac Surg* 2016; **49**: 770-7.
- 3) Usui A. TEVAR for type B aortic dissection in Japan. *Gen Thorac Cardiovasc Surg* 2014; **62**: 282-9.
- 4) Scali ST, Beck AW, Butler K, et al. Pathology-specific secondary aortic interventions after thoracic endovascular aortic repair. *J Vasc Surg* 2014; **59**: 599-607.
- 5) LeMaire SA, Green SY, Kim JH, et al. Thoracic or thoracoabdominal approaches to endovascular device removal and open aortic repair. *Ann Thorac Surg* 2012; **93**: 726-32; discussion 733.
- 6) Roselli EE, Abdel-Halim M, Johnston DR, et al. Open aortic repair after prior thoracic endovascular aortic repair. *Ann Thorac Surg* 2014; **97**: 750-6.
- 7) Takano T, Terasaki T, Wada Y, et al. Treatment of prosthetic graft infection after thoracic aorta replacement. *Ann Thorac Cardiovasc Surg* 2014; **20**: 304-9.