

Case report

Aseptic necrosis of the femoral head after pregnancy: a case report

Kawtar Nassar^{1, &}, Wafae Rachidi¹, Saadia Janani¹, Ouafa Mkinsi¹

¹Rheumatology Department, Ibn Roch University Hospital, Casablanca, Morocco

[&]Corresponding author: Nassar Kawtar, Rheumatology Department, Ibn Roch University Hospital, Casablanca, Morocco

Key words: Aseptic necrosis, pregnancy, femoral head, risk factors

Received: 22/06/2015 - Accepted: 19/02/2016 - Published: 07/07/2016

Abstract

A documented case of beginning aseptic necrosis of the femoral head associated with pregnancy together with a review of the literature about this rare complication of pregnancy is presented. The known risk factors of osteonecrosis are; steroid use, alcoholism, organ transplantation, especially after kidney transplant or bone marrow transplantation bone, systemic lupus erythematosus, dyslipidemia especially hypertriglyceridemia, dysbaric decompression sickness, drepanocytosis and Gaucher's disease. Among the less established factors, we mention procoagulations abnormalities, HIV infection, chemotherapy. We report a case of osteonecrosis of femoral head after pregnancy.

Pan African Medical Journal. 2016; 24:195 doi:10.11604/pamj.2016.24.195.7325

This article is available online at: <http://www.panafrican-med-journal.com/content/article/24/195/full/>

© Kawtar Nassar et al. The Pan African Medical Journal - ISSN 1937-8688. This is an Open Access article distributed under the terms of the Creative Commons Attribution License (<http://creativecommons.org/licenses/by/2.0>), which permits unrestricted use, distribution, and reproduction in any medium, provided the original work is properly cited.

Introduction

Aseptic necrosis, known as avascular necrosis, ischemic necrosis, or osteonecrosis, is a pathological process caused by impaired blood supply to the affected bone and resulted in the death of osteocytes and bone marrow cells [1]. That induces demineralization, trabecular thinning, and subsequent collapse of the joint surface with fracture of subchondral bone. The first report was made by Pfeiffer in 1957 [2]. A clinical diagnosis is made according to the patient's symptoms, physical findings, and imaging results compatible with the disease. In our patient, all other predisposing factors, apart pregnancy have been excluded. Because until now few cases have been described, little is known about the evolution and treatment of this disease in association with pregnancy. We report a case.

Patient and observation

We report a case of 38 year old, housewife without past medical history. There was no history of steroid usage, alcohol drinking, or trauma. She presented in 2009, during the third trimester of pregnancy, mechanical pain in the left hip, persistent postpartum, causing walking discomfort. Blood analysis was normal in postpartum, and radiographs showed the femoral head subtle loss of sphericity (Figure 1). T2-weighted sequence MRI of the femoral heads showed bilateral joint effusion with focal lesion at the anterior part of the left hip (Figure 2). Symptomatic treatment was introduced to avoid complications and elective caesarean section was indicated. By the way, she consulted five years ago in our department for the same but bilateral symptoms, and pain became more severe at left without extra-articular sign. Physical examination revealed a walking limp, weight at 65 kg, and 167.5 cm for size. There was a pain in left hip flexion with limitation at 100 degrees. Key sign was positive with positive Patrick's (flexion abduction external rotation) tests especially at left hip. Radiographs showed prominent osteoarthritis, which is especially at right, with collapse of the articular surface and minimal loss of sphericity at the left femoral head, compared to the radio after pregnancy (Figure 3). Laboratory tests were normal (ESR at 26 mm/first hour, Rheumatoid Factor and antinuclear antibodies were negative, Hemoglobin electrophoresis showed; A1 at 97 and A2 at 3, antiphospholipid antibodies were negative, and normal lipidic analysis). There wasn't any abdominal ultrasound abnormalities. Retained diagnosis was

aseptic osteonecrosis of the left femoral head and secondary osteoarthritis at right by hyperpression. Core decompression surgical treatment was suggested, but the patient wished to receive medical treatment only to date (symptomatic treatment, oral bisphosphonate), associated to shockwaves. The outcome marked clinical improvement (walk without limping and pain), the radiographs are expected six months after starting treatment.

Discussion

Pregnancy-associated femoral head osteonecrosis is rare. The first complaint is mostly unilateral, sudden or gradually increasing pain in the groin and radiating to the knee, thigh or back. Physical examination shows a painful limitation of active and passive movement of the joint, especially with rotation and less pronounced with abduction and flexion. Apart from traumatic forms, the exact causal link between supporting factors and aseptic necrosis occurrence is often uncertain which is only risk factors, clearly identified, rather than causes [3, 4]. A quarter to a third of aseptic necrosis is idiopathic, and occurs forty year-old men [5]. However, little is known about whether pregnancy is an etiological factor in femoral head osteonecrosis. Pregnancy is not considered as a risk factor of the disease or its recurrence in subsequent pregnancies. This association is a rare situation [6]. In 1999, Montella et al [7] reported the largest known series (13 cases), in all cases of which osteonecrosis affected the left hip and only 4 cases were bilateral. The pathogenetic mechanism of postpartum osteonecrosis of the femoral head are still controversial and probably multifactorial. Among mechanisms proposed, we found increased coagulability, mechanical stress, and impaired venous stasis. However, the high estrogen and progesterone production by the placenta can contribute to the development of osteonecrosis by fatty embolism. Also, the elevated non-protein bound cortisol and glucocorticoid activity of progesterone can be responsible [8]. The unbound maternal cortisol level is elevated to three times more among pregnant women than nonpregnant one. The pregnancy-related maternal parathyroid gland hyperplasia with high levels of parathyroid hormone may also contribute. Ischemia is frequent among pregnant women because pregnancy produces a hypercoagulable state, higher in the third trimester, with an overall monthly prevalence of 0.01 thrombotic events per 1,000 women [9]. Hypercoagulability may result in thromboembolism of vessels, which leads to vascular occlusion or venous congestion, and resulting

ischemic necrosis of the bone. From the results of current studies, ovulation induction may be a cause which activate both coagulation and fibrinolytic systems [10, 11]. Mechanical stress induced by excessive weight gain during pregnancy may be another etiological factor for osteonecrosis of the femoral head [12]. Direct injury to the femoral joint or the artery in the round ligament by compression of the growing uterus or during a difficult delivery have been mentioned [13]. In our patient, the biochemical and coagulation parameters showed no abnormalities. There are six stages of aseptic necrosis, with typical clinical and histological signs in each stage. X-rays and conventional tomography become pathological only in stage 2, often several months after the onset of clinical symptoms, showing arc-like subchondral radiolucent areas, patchy lucent areas, sclerosis, a 'crescent' sign and bone collapse [14]. Other techniques have to be used for early diagnosis: Bone scintigraphy, and resonance magnetic imaging (affected bone as early as 12-48 hours after the onset of the disease). The best way to treat the pregnant patient is not clear. The early diagnosis and advice are important. The prognosis after this conservative therapy seems to be good, although secondary degenerative or osteoarthritis changes eventually require surgical treatment at a later age.

Conclusion

Aseptic osteonecrosis of femoral head associated to pregnancy is rare. The early diagnosis of this condition is important. Pain due to nerve compression will be partly relieved at rest. However, contrary to the pain of aseptic necrosis, there is an obvious exacerbation of the neuralgic pain during the night. The patients should be treated early and adequately to prevent secondary degenerative changes in the hip joints in these young women.

Competing interests

The authors declare no competing interest.

Authors' contributions

All authors contributed to the writing and have read and approved the final manuscript.

Figures

Figure 1: Left femoral heads subtle loss of sphericity

Figure 2: T2-weighted sequence MRI of the femoral heads showed bilateral joint effusion with focal lesion at the anterior part of the left hip

Figure 3: Prominent osteoarthritis, which is bilateral, with collapse of the articular surface and minimal loss of sphericity at the left femoral head

References

1. Yu-Chun L, Wei-Shiu C, Chiung-Chiung C, Ming C, Chen-Tung Y. Aseptic necrosis of bilateral femoral heads after pregnancy. *Taiwanese Journal of Obstetrics & Gynecology*. 2011; 50 (1):111-113. **PubMed** | **Google Scholar**
2. Pfeifer W. Eine ungewöhnliche Form und Genese von symmetrischen osteonekrosen beider Femur und Humertiskophkappen. *Fortsch Geb Rontgenstr Nuklearmed Ergänzungsband*. 1957; 87 (3):346. **PubMed** | **Google Scholar**
3. Pierre Lafforgue. Osteonecrosis of the femoral head. *Revue du Rhumatisme*. 2009 ; 76(2) :166-172. **PubMed** | **Google Scholar**
4. Mehsen N, Barnetche T, Redonnet-Vernhet I, Guérin V, Bentaberry V, Gonnet-Gracia C, Schaeffer T. Coagulopathies frequency in aseptic osteonecrosis patients : *Joint Bone Spine*. *Joint Bone Spine* .2009; 76 (2):166-169. **PubMed** | **Google Scholar**
5. Ángeles Martínez-Ferrer, Pilar Peris, Núria Guañabens. Osteonecrosis, What Is New?. *Reumatología Clínica (English Edition)*. 2007; 2(3):78-84. **PubMed** | **Google Scholar**

6. Steib-Furno M, Luc T, Pham, et al. Pregnancy-related hip diseases: incidence and diagnoses. *Joint Bone Spine*. 2007; 74(3):373-8. **PubMed | Google Scholar**
7. Montella BJ, Nunley JA, Urbaniak JR. Osteonecrosis of the femoral head associated with pregnancy: a preliminary report. *J Bone Joint Surg Am*. 1999; 81(10):790-8. **PubMed | Google Scholar**
8. Gribble RK, Emanuel Berres L. Idiopathic osteonecrosis of the hip during pregnancy: outcome in a subsequent gestation. *Obstet Gynecol*. 2001; 98(6):911-3. **PubMed | Google Scholar**
9. Baumann P, Diedrich K. Thromboembolic complications associated with reproductive endocrinologic procedures. *Hematol Oncol Clin North Am*. 2000; 14(3):431-43. **PubMed | Google Scholar**
10. Chan WS, Dixon ME. The "ART" of thromboembolism: a review of assisted reproductive technology and thromboembolic complications. *Thromb Res*. 2008; 121(6):713-26. **PubMed | Google Scholar**
11. Marios G, Lykissas, Ioannis D, Gelalis, Ioannis P, Kostas-Agnantis, Georgios Vozonelos, Anastasios V. Korompilias : the role of hypercoagulability in the development of osteonecrosis of the femoral head. *Orthopedic Reviews*. 2012; 4(10):73-78. **PubMed | Google Scholar**
12. Pierre Lafforgue. Pathophysiology and natural history of avascular necrosis of bone. *Revue du Rhumatisme* .2006 ; 73(5)887-894. **PubMed | Google Scholar**
13. Mwale F, Wang H, Johnson AJ, Mont MA, Antoniou J. Abnormal vascular endothelial growth factor expression in mesenchymal stem cells from both osteonecrotic and osteoarthritic hips. *BullNYU Hosp Jt Dis*. 2011;69(1):56-61. **PubMed | Google Scholar**
14. Barille WF, McMahon CJ. Femoral head avascular necrosis: a frequently missed incidental finding on multidetector CT. *Clin Radiol*. 2014 Mar;69(3):280-5. **PubMed | Google Scholar**

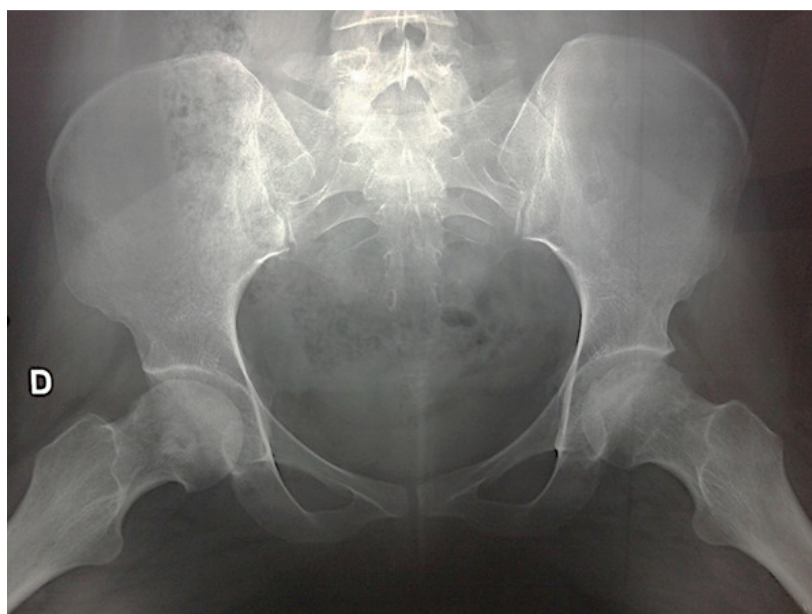

Figure 1: Left femoral heads subtle loss of sphericity

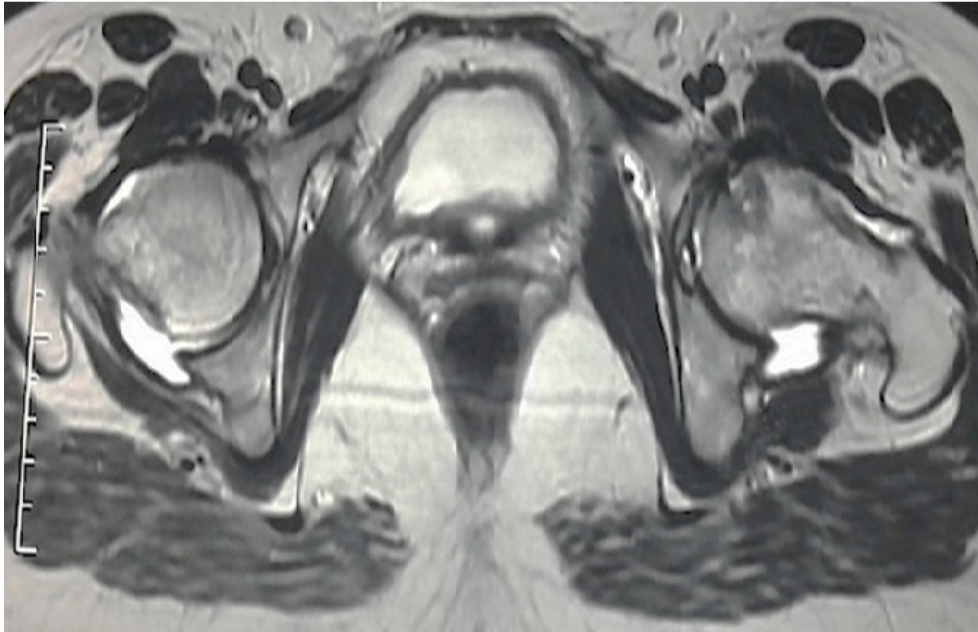


Figure 2: T2-weighted sequence MRI of the femoral heads showed bilateral joint effusion with focal lesion at the anterior part of the left hip

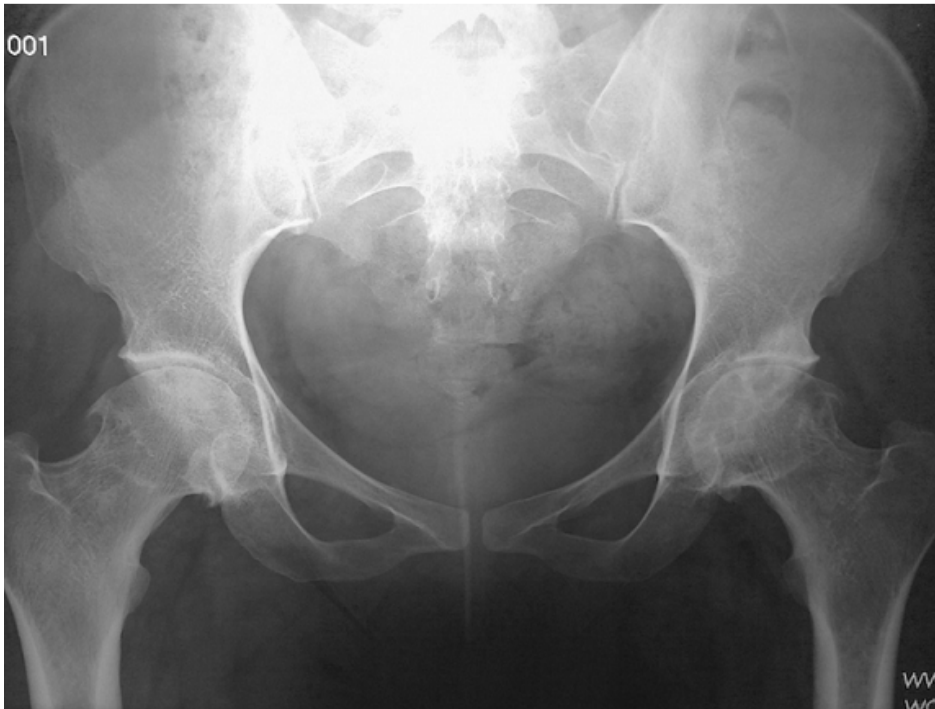

Figure 3: Prominent osteoarthritis, which is bilateral, with collapse of the articular surface and minimal loss of sphericity at the left femoral head